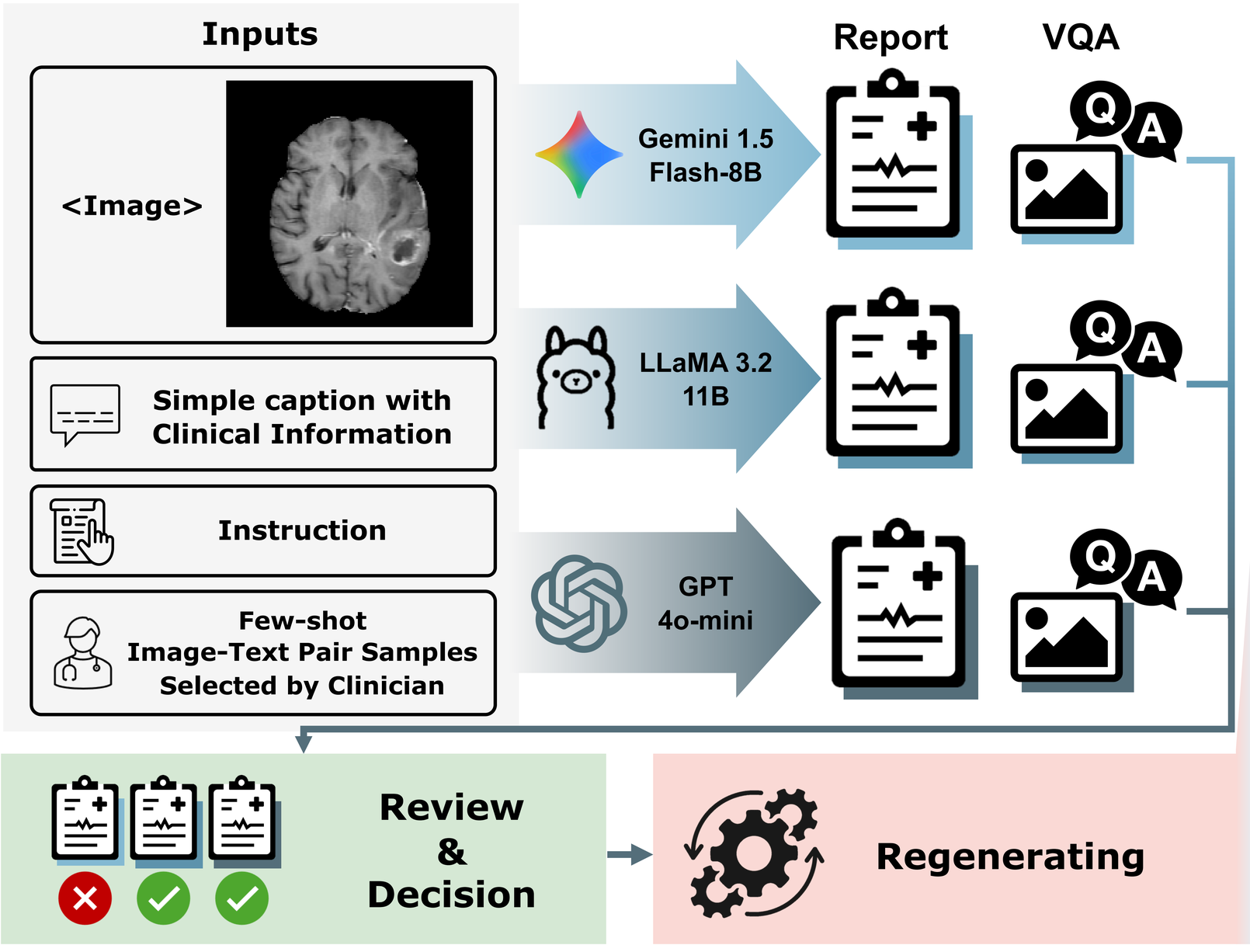

Report

The axial brain scan, acquired using the T1 contrast-enhanced modality, presents a glioma with a well-defined enhancing region, indicating tumor presence and activity. The tumor is characterized by a heterogeneous signal intensity, with a central core of low signal intensity and a peripheral rim of high signal intensity. A significant amount of surrounding edema is visible, evident as a bright, white area on the scan.

VQA

Q: What type of scan is used for this image?
A: The image appears to be a brain scan, and based on the visual details, it seems to be a magnetic resonance imaging (MRI) scan.
Q: What abnormality do you see in this image?
A: Upon examining the image, I notice a noticeable area of edema and enhancement, which could indicate the presence of a tumor. The tumor core appears to be the most prominent feature in the image.