"Generate a free-text radiology reports based on the provided brain MR image."

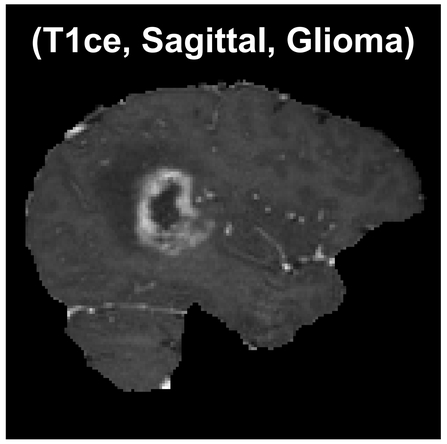

LLaVA 1.6: The image provided appears to be a brain magnetic resonance imaging (MRI) scan. The scan shows a lesion in the left frontal lobe of the brain. The lesion is hypointense on T1-weighted imaging and hyperintense on T2-weighted imaging, which suggests it may be a demyelinating lesion, such as a multiple sclerosis (MS) plaque. The lesion is surrounded by normal-appearing white matter, which is typical for MS lesions. **The rest of the brain appears normal**.

LLaMA 3.2 11B: A well-defined, round, **hypointense lesion is observed** in the right frontal lobe. **The lesion measures approximately 2.5 cm in diameter. The surrounding brain tissue appears normal. No significant edema or mass effect is noted**. **The lesion is likely a glioma**, **given its location and appearance on T1-weighted imaging**. ...

Gemini Flash-8B: Based on the single, limited-resolution image provided, a definitive diagnosis is not possible. **The image shows a poorly defined, slightly hyperintense lesion** in the supratentorial region. The signal characteristics are not sufficiently specific to determine if the lesion is cystic, solid, or mixed. Further imaging and clinical correlation are necessary to better characterize the lesion ...

Chat-GPT 4o mini: In the presented images, there is a noteworthy hyperintense lesion located in the parenchyma. The lesion demonstrates a central area of hyperintensity with a surrounding hypointense rim, suggesting a potential cystic formation. No midline shift or significant mass effect is observed. There are no acute hemorrhagic changes or abnormal enhancement patterns noted following contrast administration. The surrounding brain tissue appears unremarkable. The ventricles are normal in size and configuration. **No evidence of significant edema is seen in adjacent structures**. ...

LLaBIT (Ours): **The image presents a detailed sagittal view of the brain**, captured through a **T1-weighted contrast-enhanced scan**. **A notable feature is the presence of a glioma**, **characterized by a sizable enhancing tumor core surrounded by observable edema. The tumor core exhibits irregular margins and varying intensity**, **typical characteristics of gliomas**. The surrounding edema suggests the tumor's impact on adjacent brain tissue, indicating potential pressure and inflammation. ...

Modality | Plane | Abnormality | ROI | Inaccurate

"What type of scan is used for this image?"

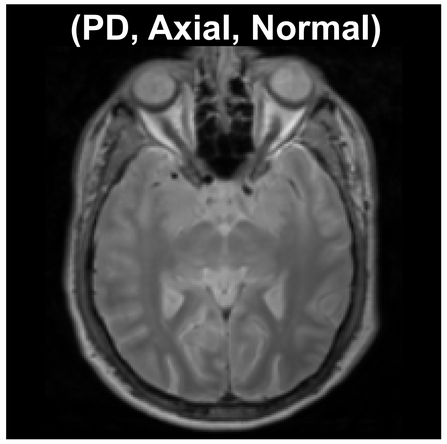

LLaVA-Med: T1-weighted

LLaVA 1.6: T1-weighted

LLaMA 3.2 11B: T2-weighted

Gemini Flash-8B: T2-weighted

GPT 4o mini: T2-weighted

LLaBIT (Ours): Proton density

"What abnormality do you see in this image?"

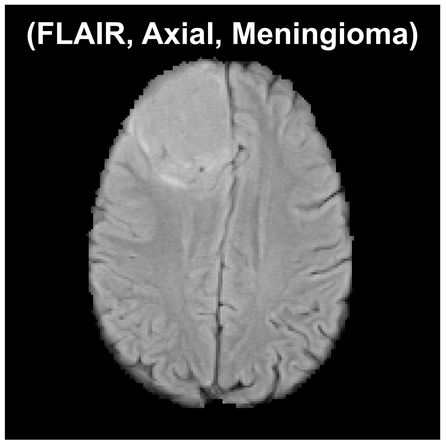

LLaVA-Med: Glioma

LLaVA 1.6: Normal

LLaMA 3.2 11B: Glioma

Gemini Flash-8B: Meningioma

GPT 4o mini: Glioma

LLaBIT (Ours): Meningioma