Journal Pre-proof



12-Months MRI after Anterior Cruciate Ligament Reconstruction Can Identify Risk Factors for Subsequent Graft Rupture and Used to Guide the Return to Sport. Results From a High-Volume Institution.

Christian Lutz, Fabio Mancino, David A. Parker

PII: S2059-7754(25)00611-X

DOI: https://doi.org/10.1016/j.jisako.2025.100994

Reference: JISAKO 100994

To appear in: *Journal of ISAKOS*

Received Date: 18 June 2025

Revised Date: 7 August 2025

Accepted Date: 8 August 2025

Please cite this article as: Lutz C, Mancino F, Parker DA, 12-Months MRI after Anterior Cruciate Ligament Reconstruction Can Identify Risk Factors for Subsequent Graft Rupture and Used to Guide the Return to Sport. Results From a High-Volume Institution., *Journal of ISAKOS*, https://doi.org/10.1016/j.jisako.2025.100994.

This is a PDF file of an article that has undergone enhancements after acceptance, such as the addition of a cover page and metadata, and formatting for readability, but it is not yet the definitive version of record. This version will undergo additional copyediting, typesetting and review before it is published in its final form, but we are providing this version to give early visibility of the article. Please note that, during the production process, errors may be discovered which could affect the content, and all legal disclaimers that apply to the journal pertain.

© 2025 The Author(s). Published by Elsevier Inc. on behalf of International Society of Arthroscopy, Knee Surgery and Orthopedic Sports Medicine.

Journal Pre-proof

Title

12-Months MRI after Anterior Cruciate Ligament Reconstruction Can Identify Risk Factors for Subsequent Graft Rupture and Used to Guide the Return to Sport. Results From a High-Volume Institution.

Authors

Christian Lutz [1,2], Fabio Mancino [1], David A. Parker [1]

[1] Sydney Orthopaedic Research Insitute (SORI), Landmark Orthopaedics, St. Leonards NSW, Australia

[2] Institut de Chirurgie Orthopédique et Sportive à Strasbourg (ICOSS), Strasbourg, France

Corresponding author:

Christian Lutz, Institut de Chirurgie Orthopédique et Sportive à Strasbourg, 35 avenue du Rhin, 67100 Strasbourg, France (email : lutzortho@wanadoo.fr)

OD : 0000-0001-8121-733X

Co-authors:

Fabio Mancino, Sydney Orthopaedic Research Insitute (SORI), Landmark Orthopaedics, St. Leonards NSW (email : fabio.mancino90@gmail.com)

OD : 0000-0003-3080-0052

David A. Parker, Sydney Orthopaedic Research Insitute (SORI), Landmark Orthopaedics, St. Leonards NSW (email : dparker@sydneyortho.com.au)

OD: 0000-0001-6930-8490

Authorship contributions:

Christian Lutz

Conception and design of the study, acquisition of data, analysis and interpretation of data, drafting the article.

Fabio Mancino

Analysis and interpretation of data, revising the article critically for important intellectual content.

Journal Pre-proof

Journal Pre-proof

David A. Parker

Final approval of the version to be submitted.

Acknowledgements

The authors acknowledge Dr James Linklater for contribution to MRI analysis.

Funding sources

This research did not receive any specific grant from funding agencies in the public, commercial, or not-for-profit sectors.

Conflict of interest disclosures

Support for the reported work

The authors declare that they have no known competing financial interests or personal relationships that could have appeared to influence the work reported in this paper.

Relevant support outside this work

Christian Lutz done consulting work for Arthrex, Zimmer-Biomet and Medacta.

Fabio Mancino declare no conflicts of interest.

David A. Parker is board membership of ISAKOS. He done consulting work for Smith & Nephew, Arthrex, Smith & Nephew and Corin.

Journal Pre-proof

Article Summary

This study investigated if post-operative Magnetic Resonance Imaging assessment, clinical outcomes, and return to sport test findings can help identify patients at higher risk of early graft re-rupture. Retrospective analysis of prospectively collected patients who underwent primary Anterior Cruciate Ligament Reconstruction using hamstring autograft between 2017 and 2022, with a minimum follow-up of 12 months.

Overall, 13 patients were included in the re-tear group and compared with 50 matched patients. The mean follow-up was 23.6±4.2 months (range, 18 to 36 months).

The 12-month Magnetic Resonance Imaging showed a greater Signal-to-Noise Quotient in case of re-tear (2.93 vs 2.02; p=0.029). Tunnel positioning was comparable between the groups, and not associated with re-tear. Similarly, tibial and femoral tunnel widening were comparable between the two groups and not associated with graft re-tear

(ANOVA, p=0.733 and p=0.190). A greater proportion of patients reported an anterior knee laxity >2mm at one year in the re-tear group (83.3% vs 38.8%, p=0.058). No differences were noted for clinical scores and return to sport testing.

Higher graft signal on Magnetic Resonance Imaging at 12-months, indicating poorer graft healing, is associated with early anterior cruciate ligament re-tear. Further research is required to confirm these preliminary findings.

Ethics approval statement

The Human Research Ethics Committee of Northern Sydney Local Health District (NSHLD) approved the study protocol (reference number HREC/17/HAWKE/140) on September 20th, 2017 and an amendment for a five years extension on October 13rd, 2022.

Patient approval statement

Each patient provided written consent for participation in the study prior to enrollment.

Social media tags

All authors agree to be tagged in any JISAKOS social media posts related to this article.

Journal Pre-proof

Journal Pre-proof

12-Months MRI after Anterior Cruciate Ligament Reconstruction Can Identify Risk Factors for Subsequent Graft Rupture and Used to Guide the Return to Sport. Results From a High-Volume Institution.

Journal Pre-proof

Journal Pre-proof

Abstract

Introduction

Re-tear after anterior cruciate ligament reconstruction has been reported between 6% and 31%, resulting in worse outcomes and increased risk of post-traumatic osteoarthritis. This study investigated if post-operative magnetic resonance imaging assessment, clinical outcomes, and return to sport test findings can help identify patients at higher risk of early graft re-tear.

Methods

Retrospective analysis of 430 patients who underwent primary anterior cruciate ligament reconstruction using hamstring autograft between 2017 and 2022, with a minimum follow-up of 12 months. Baseline characteristics, intraoperative and postoperative information were collected. Graft signal, tunnel widening and positioning were assessed through a 12-month magnetic resonance imaging. Patients who experienced early graft re-tear were compared with a matched cohort with a ratio of 1:4. Continuous variables were compared. Logistic regression and analysis of variance were used to identify risk factors and association with re-tear. P values <0.05 were considered significant.

Results

Of the 346 patients who met the inclusion/exclusion criteria, 19 experienced a graft rupture (5.4%) after the 12-months follow-up. Of those, six patients were excluded due to missing postoperative 1-year magnetic resonance imaging. Overall, 13 patients were included in the re-tear group and compared with 50 matched patients. The mean follow-up was 23.6±4.2 months (range, 18 to 36 months). The 12-month magnetic resonance imaging showed a greater signal-to-noise quotient in case of re-tear (2.93 vs 2.02; p=0.029). The analysis of variance showed a positive interaction between graft signal and re-tear (analysis of variance (ANOVA), p=0.028). Tunnel positioning was comparable between the groups, and not associated with re-tear. Similarly, tibial and femoral tunnel widening were comparable between the two groups and not associated with graft re-tear (ANOVA, p=0.733 and p=0.190). A greater proportion of patients had an anterior knee laxity >2mm at one year in the re-tear group (83.3% vs 38.8%, p=0.058). However, mean laxity was comparable (2.55 mm vs 1.35 mm; p=0.189). No differences were noted for clinical scores and return to sport testing.

Conclusion

Journal Pre-proof

Higher graft signal on magnetic resonance imaging at 12-months, indicating poorer graft healing, is associated with early anterior cruciate ligament re-tear. Resonance imaging after anterior cruciate ligament reconstruction could be used to guide the follow-up management. Further research is required to confirm these preliminary findings.

Level of evidence III; retrospective comparative study.

What are the new findings

- Patients who experienced an early rupture of the graft after anterior cruciate ligament reconstruction were found to have a higher graft signal at the 1-year magnetic resonance imaging
- Almost 70% of patients who experienced a graft tear within three years after index reconstruction had a graft signal greater than 2, indicative of poor graft healing
- Tunnel widening and tunnel positioning did not differ between patients who experienced an early graft rupture and the control group

Keywords: Anterior Cruciate Ligament Injury, ACL tear, revision ACL, re-tear ACL

Journal Pre-proof

INTRODUCTION

Graft re-tears following anterior cruciate ligament reconstruction (ACLR) affects the ability to return to pre-injury sports activity levels and often necessitates ACLR revision, which typically has less favorable outcomes than the primary ACLR[1]. Graft re-tears are associated with an increased risk of meniscal or cartilage damage, potentially leading to a higher incidence of knee osteoarthritis [2].

Multiple preoperative risk factors have been well documented and investigated, including younger age, high activity levels, and a tibial slope greater than 12° [3, 4, 5]. Surgical variables have been associated with an ACLR re-tear, with particular attention to accurate and reproducible tunnel positioning [6,7].

After ACLR, patients are regularly evaluated, aiming for a safe and timely return to sport (RTS). Despite extensive research on RTS [8,9], there remains a gap in understanding how these evaluations correlate with the risk of graft re-tear.

The current study aimed to establish a relationship between postoperative assessments and ACLR re-tear, and if so, what risk factors can be identified. Our hypothesis was therefore as follows: (1) postoperative assessments would help to identify risk factors of an early ACLR re-tear, and (2) this information might assist in timing of RTS.

METHODS

Participants

The study was performed in accordance with the ethical standards of the 1964 Declaration of Helsinki and with the Health Insurance Portability and Accountability Act of 1996 (HIPAA) regulations. The “to be named after blinding// XXBLINDEDXX” Ethics Committee approved the study protocol (reference number: “to be named after blinding// XXBLINDEDXX”). Each patient provided written consent for participation in the study prior to enrollment.

A total of 430 consecutive skeletally mature patients who underwent primary ACLR between January 2017 and December 2022 were retrospectively evaluated. All surgical procedures were performed by three experienced knee surgeons at a high-volume institution. All participants underwent hamstring autograft ACLR with double suspensory

Journal Pre-proof

fixation for a single-ligament primary anterior cruciate ligament (ACL) rupture. One-year magnetic resonance imaging (MRI) was part of the standard follow-up at the authors' institution to assess the healing of the graft after ACLR.

The inclusion criteria were patients >18 years of age with isolated ACL tear ± meniscal tear. The exclusion criteria were multiligamentous knee injury with concomitant posterolateral or posterior cruciate ligament reconstruction, bilateral ACLR, revision ACLR on the ipsilateral knee, rheumatoid arthritis, inflammatory arthritis, skeletally immature patients, history of septic arthritis, morbid obesity (body mass index (BMI) >40 kg/m²), inability to communicate in the English language, patients who did not undergo a 1-year postoperative MRI, patients who did not respond regarding graft rupture status when contacted, underwent additional knee surgeries (84 patients).

Patient records, including age, sex, side of the operation, height and weight, BMI at the time of surgery, and follow-up period, were reviewed. Intraoperative data, as well as postoperative and clinical data, were collected and reviewed.

Of the 346 patients who met the inclusion/exclusion criteria, 19 experienced a graft rupture (5.4%) after the 1-year follow-up. Of those, six patients were excluded due to missing postoperative 1-year MRI data, leaving 13 patients with complete data in the re-rupture group. Those patients were matched for age, sex, height, weight, and BMI with a control group of 50 patients using a 1:4 ratio to mitigate the impact of confounding variables and to minimise the statistical noise associated with the small sample size.

A study design flow chart is provided for reference (Figure 1).

Surgical Technique

The utilised surgical technique has already been described for hamstring primary ACLR [10]. The graft was secured with adjustable suspensory fixation, employing a TightRope RT (Arthrex, Naples, Florida, USA) for femoral fixation and a TightRope ABS (Arthrex, Naples, Florida, USA) for tibial fixation, where tensioning was applied against a cortical button. The graft consisted of a 4-strand quadrupled semitendinosus tendon or quadrupled semitendinosus plus doubled gracilis to create a 6-strand graft if necessary to achieve a graft diameter of minimum 8mm.

The femoral tunnel was prepared through the anteromedial portal aligning with the "IDEAL" principle (Isometric, in Direct fibers, Equidistant and Eccentric, Anatomic, and Low in tension) [11].

Postoperative Management

Journal Pre-proof

A standardised postoperative rehabilitation protocol was implemented, adjusted in case of meniscal repair. If rehabilitation criteria were met, straight-line running was initiated approximately three months postoperatively, with sport-specific training approximately at six months. Objective RTS testing was conducted between 9 and 12 months postoperatively.

RTS assessments included the ACL return to sport after injury scale (ACL-RSI) and hop tests. A limb symmetry index was calculated for all tests; the reconstructed limb needed to achieve at least 90% function relative to the contralateral limb to pass the RTS criteria [8]. The final decision regarding the resumption of competitive sports was taken by the consultant knee specialist based on physical therapy reports, RTS results, and Patient-reported outcome measures after the 1-year follow-up.

Clinical Evaluation

At the 1-year follow-up, patients underwent clinical evaluation, MRI scan and side-to-side knee laxity measurements using a GnRB® device (Genourob, Laval, France) with a pathological threshold difference set at 2 mm [12].

Patient reported outcome measures (PROMs) included the International Knee Documentation Committee (IKDC), the Lysholm Knee Scoring Scale and the Tegner Activity Scale. At a minimum of 18 months postoperatively, patients were contacted via email or telephone to report any concerns about knee stability, additional injuries or surgeries to determine if a graft rupture had occurred. Any suspected graft ruptures were subsequently confirmed via a new MRI.

MRI Evaluation

MRI examinations were performed using a high-resolution 3.0-T MRI system (Magnetom Skyra, Siemens AG Healthcare) equipped with a 15-channel phased-array knee coil. The imaging protocol, as outlined in previous studies [10,13], included volumetric and near-isotropic turbo spin echo sequences (0.5 × 0.5 × 0.65 mm), enabling multiplanar reconstructions along the ACLR graft and precise anatomical measurements previously validated against 3D computed tomography [14].

Graft Signal Intensity

Journal Pre-proof

Graft healing was assessed using the signal-to-noise quotient (SNQ), with higher graft signal intensity indicating a poorer healing outcome. The method for calculating and determining the SNQ has been published previously (10,13,15) (Figure 2).

For inter- and intra-observer reliability, SNQ values were recorded twice by a senior observer with a 1-month interval (Intraclass Correlation [ICC] 0.919) and a sample of 20 cases was cross-checked with another experienced fellowship-trained orthopaedic surgeon (ICC 0.812). In case of major discrepancies, a musculoskeletal specialised radiologist was consulted.

Tunnel Widening

Tunnel widening was assessed by measuring the femoral and tibial aperture sizes on images perpendicular to each aperture. Tunnel size was determined by calculating the area of the circle, and widening was assessed by comparing this with the area of the tunnel drilled during surgery. A widening of more than 50% was considered relevant [16].

Tunnel Positioning

Tibial tunnel location was evaluated in both the coronal (medio-lateral positioning) and sagittal planes (antero-posterior positioning) as previously described [14].

Femoral tunnel location was assessed in the sagittal plane using two methods. One method applied the Aglietti/Jonsson index [17], while the other measured the distance from the tunnel aperture epicentre to the chondro-cortical junction at the postero-superior border of the lateral femoral condyle, extending toward the notch.

An independent musculoskeletal radiologist analysed the tunnel locations: correct positioning was defined with a margin of ±2 mm to account for variations in graft sizes [14].

Statistical Analysis

Data obtained preoperatively, intraoperatively, nine months, and one year after surgery were subjected to statistical evaluation. Descriptive results are reported as mean, standard deviation (SD), and range. The normality of distributions was evaluated using the one-sample Kolmogorov–Smirnov test. Continuous variables were compared using the paired t-test or the Mann-Whitney U test, depending on data distribution. Discrete variables were compared using the Chi-squared test or Fisher's exact test. Analysis of variance (ANOVA) was used to test statistical significance differences between mean values of different groups after surgery. Data with a skewed distribution were investigated with the

Journal Pre-proof

one-way-ANOVA on ranks or non-parametric Kruskal-Wallis test. Postoperative parameters were analysed through logistic regression to identify significant association with re-tear. All differences were defined as significant at p-value < 0.05. All data were analysed using Jamovi for Mac Version 2.3 (Sydney, Australia).

RESULTS

Participants and Clinical Outcomes

The mean follow-up was 23.6 ± 4.2 months (median 24, range 18–36 months). The patients' mean age was 27.6 ± 11.1 years, and 44% were female (Table 1). Lateral extra-articular tenodesis (LET) was performed in one patient in the re-rupture group (7%) and in 10 patients in the control group (20%).

At the 1-year follow-up, not statistically significant difference was noted between the two groups, re-rupture group and control group when evaluating the clinical outcomes. The knee laxity at 200N was compared between the re-rupture group and the control group (2.5±0.9mm vs 1.3±1.9mm, p=0,189; 83.3% >2mm vs 38.8% >2mm, p=0.058). Sport activity, as measured by the Tegner level, was compared between re-rupture group and control group (7.0 vs 5.8, p=0.078), as well as the IKDC subjective and Lysholm scores (IKDC: 83.7 vs 87.2, p=0.347; Lysholm: 91.1 vs 94.4, p=0.300) (Table 2).

Return to Sport Tests

No statistically significant difference was noted in ACL-RSI scores between the re-rupture group and the control group (64.7 vs 61.5 points, p = 0.739), or in the return-to-sport tests (Table 2).

MRI Outcomes

The SNQ value for graft signal intensity was significantly higher in the re-rupture group compared to the control group (2.93 vs 2.02, Independent samples t-test p=0.029, Cohen's d effect size 0.44 [moderate]; 69.2% > 2 vs 38% > 2, χ^2 p=0.044) (Table 2). Tunnel widening greater than 50% was not statistically significantly different for either the femoral or tibial tunnel between the control group and re-rupture group groups (femur: 36% vs 7.7%; tibia: 10% vs 15.4%). Tunnel positioning was generally correct and did not show statistically significant differences between the groups (Table 2).

Risk Factors

Journal Pre-proof

The logistic regression analysis for the risk factors of graft rupture (R^2_N=0.28) did not show statistically significant difference for tibial tunnel widening (ref. <50%, p=0.995), femoral tunnel widening (ref. <50%, p=0.776), graft signal (ref. <2, p=0.244) and knee laxity <2mm (p=0.085).

The Kruskal-Wallis test for non-parametric data showed a positive interaction between graft signal and ACL re-tear (p=0.028, effect size ε^2=0.08 [moderate]). There was not statistically significant difference for knee laxity (p=0.183), femoral (p=0.190) or tibial tunnel widening (p=0.733).

DISCUSSION

The main finding of this study was that patients who sustained an early graft rupture after ACL reconstruction had a higher graft signal on MRI at 12 months (Figure 3). Among patients who experienced graft failure within three years of the index procedure, 69.2% had a signal intensity greater than 2, indicating suboptimal graft healing, compared to 38.8% in the control group. These results are consistent with previous studies that identified a high graft signal near the femoral tunnel aperture on 12-month MRI as a risk factor for subsequent rupture [15]. Similar findings were reported by Yau et al. [18], who demonstrated that a higher SNQ at one year was associated with a markedly increased risk of graft failure, with an odds ratio of 12.1 for heterogeneous hyperintense grafts compared to homogeneous hypointense grafts.

The clinical significance of this increased signal remains uncertain. It is not yet clear whether this represents biological failure of the graft or a delayed ligamentization process that may continue to improve over time. Prior studies have shown that hamstring autografts typically reach their final MRI appearance by 12 months [19,20], with little change thereafter [10]. However, it has also been reported that grafts with elevated signal at one year may show meaningful SNQ improvement by two years, suggesting ongoing maturation [21].

It is well established that re-tear within the first postoperative year can occur due to relative graft weakness during the remodeling process, which may extend up to three years [22]. Some studies have reported re-tear rates of up to 20%, with the highest risk occurring within the first two years after surgery [23,24]. These findings support the value of graft monitoring in the early postoperative period. Based on our data, a routine MRI at 12 months may be useful to guide follow-up. In cases of persistently high signal, repeat imaging could help inform decisions regarding return to sport.

Journal Pre-proof

Tunnel widening is a topic of current debate. It is influenced by a combination of biological and mechanical factors and has been considered a potential sign of poor graft-bone integration and adverse outcomes. However, despite the concern regarding the impact of different fixation types on tunnel widening [25,26], several studies suggest that tunnel enlargement does not correlate with poorer clinical outcomes or higher rates of graft rupture [27–29], which is consistent with our findings. Tunnel widening, particularly at the aperture, tends to occur in the early postoperative phase and may later stabilise or regress due to bone ingrowth. The role of the fixation system—especially suspensory fixation—may also influence tunnel morphology, but a direct association with graft failure remains unproven.

No significant differences were observed between the two groups when anatomical landmarks were used to assess tunnel positions. The femoral tunnel is often linked to graft rupture when malpositioned [7,30], usually either too high and/or too shallow in the femoral notch [7]. The MRI investigation showed that tunnels were mainly in the correct position between the two groups according to the pre-determined accepted criteria [17]. When investigating the cases that experienced an early re-rupture, only one patient had a suboptimal femoral tunnel position, whilst none were positioned too high on the notch. This likely explains the lack of proven correlation between tunnel position and graft re-rupture in this study, possibly reflecting adherence to the "IDEAL" femoral socket positioning criteria [11].

When analysing the clinical outcomes — PROMs (Tegner, Lysholm, KOOS, IKDC) and knee laxity — no statistically significant differences were noted between the groups. Goodwillie et al [31] investigated the effect of graft laxity on long-term clinical outcomes by comparing tight (<3 mm side-to-side difference, KT-1000 arthrometer) and loose grafts (>5 mm), showing that a loose graft did not adversely affect long-term outcomes or graft failure rates at 16 years' follow-up. Other studies have shown a correlation between postoperative laxity and high graft signal on MRI, although it has not consistently impacted outcomes or re-rupture rates [28,32]. Conversely, others have reported that residual laxity increased the risk of subsequent ACL revision surgery, shortened athletes' sports careers, and led to lower Lysholm scores [33]. Postoperative laxity may still develop due to various factors such as suboptimal rehabilitation, minor unreported trauma, smoking, or biological graft changes. Nevertheless, the literature remains, at times, conflicting regarding the impact of postoperative laxity in graft failure and long-term outcomes.

Journal Pre-proof

The efficacy of RTS testing in predicting graft failure and/or re-rupture remains a contentious issue. In this study, no significant association was noted between any of the four physical tests or the ACL-RSI scale and graft failure. These findings align with the current literature suggesting that while RTS testing is integral to the decision-making process for returning to sport, it may not reliably predict the risk of subsequent graft re-rupture [34,35,36]. Nevertheless, multiple studies have reported that passing RTS tests following ACLR is associated with lower rates of ACL graft rupture [24,37,38,39]. Conversely, others have reported no association between RTS testing and ACL re-injuries [40,41]. Despite these mixed results and inconclusive statements, we believe that RTS tests should remain a standard component of the post-ACLR protocol and decision-making process before returning to full sports activities.

This study has several limitations. The small sample size of ACL re-tear may have resulted in insufficient power to test certain variables as risk factors for re-rupture. We cannot exclude the possibility of a type II error suggesting that no significance is found when a larger sample size would enable different findings. Approximately one-third of the patients who sustained a rupture of the graft could not be included due to incomplete 12-months MRI data potentially adding a detection bias. Although data was collected prospectively, the study is limited by its retrospective design. Different assessors were used for clinical evaluations, RTS, and laxity assessment, potentially leading to a performance bias. A high number of variables may potentially affect the ACL re-tear. However, we tried to reduce the statistical noise by choosing a matched control group with a 1:4 ratio [42] and by limiting the surgical-related variables, including only patients with the same graft and fixation type. While MRI graft signal has been used as an objective criterion for assessing a safe return to sport since the 1990s [43,44], its value should be interpreted cautiously. Non-parametric one-way ANOVA proves the association between the two events showing that the graft signal intensity is not equally distributed among the groups and suggesting that higher signal intensity is associated with a higher likelihood of graft re-tear. However, it does not exclude for all the confounding variables. In addition, the SNQ used to gauge graft maturation depends on MRI acquisition parameters which vary widely across studies [45]. Therefore, while SNQ measurements are reliable within a single study with consistent parameters, comparing SNQ across different studies is challenging. Only ACLR performed with hamstring autografts with suspensory fixation was included therefore the findings may not be generalisable to other grafts and/or methods of fixation, which have different maturation patterns [46]. Finally, other factors that may potentially affect graft remodeling, such as preservation of the remnant, graft

Journal Pre-proof

angulation, distal attachment of the semitendinosus graft, or the time elapsed between injury and ACL reconstruction were not investigated [10,28,47,48].

The limited number of LET procedures in the selected cohort of patients prevented statistical comparisons between the two groups. LET procedures have been associated with lower graft rupture rates compared to isolated ACLR, particularly in young, high-demand athletes [49]. However, this aspect was not the primary focus of our study.

CONCLUSION

This study highlights that patients who experienced an early graft rupture after index ACLR presented significantly higher graft signal at the 1-year MRI than those without re-rupture. These findings suggest that MRI could be considered and accepted as a valuable tool and incorporated into the follow-up and management of ACLR to provide more appropriate and personalised management of the return to sports activity, especially when considering high-risk categories such as young and highly active patients.

List of Abbreviations

Anterior cruciate ligament (ACL), anterior cruciate ligament reconstruction (ACLR), anterior cruciate ligament return to sport after injury (ACL RSI), analysis of variance (ANOVA), body mass index (BMI), control group (CG), International Knee Documentation Committee (IKDC), lateral extra-articular tenodesis (LET), magnetic resonance imaging (MRI), patient-reported outcome measures (PROMs), re-rupture group (RG), return to sport (RTS), signal-to-noise quotient (SNQ).

References

1. Mohan R, Webster KE, Johnson NR, Stuart MJ, Hewett TE, Krych AJ. Clinical Outcomes in Revision Anterior Cruciate Ligament Reconstruction: A Meta-analysis. *Arthroscopy*. 2018;34(1):289-300. doi:10.1016/j.arthro.2017.06.029.
2. Thompson SM, Salmon LJ, Waller A, Linklater J, Roe JP, Pinczewski LA. Twenty-Year Outcome of a Longitudinal Prospective Evaluation of Isolated Endoscopic Anterior Cruciate Ligament Reconstruction With Patellar Tendon or Hamstring Autograft. *Am J Sports Med*. 2016;44(12):3083-3094. doi:10.1177/0363546516658041.
3. Barber-Westin SD, Noyes FR. One in 5 athletes sustain reinjury upon return to high-risk sports after ACL reconstruction: a systematic review in 1239 athletes younger than 20 years. Sports Health. 2020;12(6):587-97. doi:10.1177/1941738120912846.

Journal Pre-proof

4. Kaeding CC, Pedroza AD, Reinke EK, Huston LJ, MOON Consortium, Spindler KP. Risk factors and predictors of subsequent ACL injury in either knee after ACL reconstruction: prospective analysis of 2488 primary ACL reconstructions from the MOON cohort. *Am J Sports Med*. 2015;43(7):1583-90. doi:10.1177/0363546515578836.

5. Sanborn RM, Badger GJ, Fleming BC, Kiapour AM, BEAR Trial Team, Hulstyn MJ, Owens BD, Proffen B, Sant N, Portilla G, Freiberger C, Henderson R, Barnett S, Costa M, Chrostek C, Ecklund K, Micheli LJ, Murray MM, Yen YM, Kramer DE, Fadale PD. Preoperative Risk Factors for Subsequent Ipsilateral ACL Revision Surgery After an ACL Restoration Procedure. *Am J Sports Med*. 2023;51(1):49-57. doi:10.1177/03635465221137873.

6. Shi WL, Gao YT, Zhang KY, Liu P, Yang YP, Ma Y, Gong X, Wang JQ, Wang C. Femoral Tunnel Malposition, Increased Lateral Tibial Slope, and Decreased Notch Width Index Are Risk Factors for Non-Traumatic Anterior Cruciate Ligament Reconstruction Failure. *Arthroscopy*. 2024;40(2):424-434. doi:10.1016/j.arthro.2023.06.049.

7. Vermeijden HD, Yang XA, van der List JP, DiFelice GS, Rademakers MV, Kerkhoffs GMMJ. Trauma and Femoral Tunnel Position Are the Most Common Failure Modes of Anterior Cruciate Ligament Reconstruction: A Systematic Review. *Knee Surg Sports Traumatol Arthrosc*. 2020;28(11):3666-3675. doi:10.1007/s00167-020-06160-9.

8. Brinlee AW, Dickenson SB, Hunter-Giordano A, Snyder-Mackler L. ACL reconstruction rehabilitation: clinical data, biologic healing, and criterion-based milestones to inform a return-to-sport guideline. Sports Health. 2022;14(5):770-9. doi:10.1177/19417381211056873.

9. Rambaud AJM, Ardern CL, Thoreux P, Regnaux JP, Edouard P. Criteria for Return to Running After Anterior Cruciate Ligament Reconstruction: A Scoping Review. *Br J Sports Med*. 2018;52(22):1437-1444. doi:10.1136/bjsports-2017-098602.

10. Putnis SE, Klasan A, Oshima T, Grasso S, Neri T, Coolican MRJ, Fritsch BA, Parker DA. Magnetic Resonance Imaging Assessment of Hamstring Graft Healing and Integration 1 and Minimum 2 Years After ACL Reconstruction. *Am J Sports Med*. 2022;50(8):2102-2110. doi:10.1177/03635465221096672.

11. Pearle AD, McAllister D, Howell SM. Rationale for Strategic Graft Placement in Anterior Cruciate Ligament Reconstruction: I.D.E.A.L. Femoral Tunnel Position. *Am J Orthop*. 2015;44(6):253-258.

12. Klouche S, Lefevre N, Cascua S, Herman S, Gerometta A, Bohu Y. Diagnostic value of the GNRB® in relation to pressure load for complete ACL tears: A prospective case-control study of 118 subjects. *Orthop Traumatol Surg Res*. 2015;101(3):297-300. doi:10.1016/j.otsr.2015.01.008.

13. Oshima T, Putnis S, Grasso S, Klasan A, Parker DA. Graft Size and Orientation Within the Femoral Notch Affect Graft Healing at 1 Year After Anterior Cruciate Ligament Reconstruction. *Am J Sports Med*. 2020;48(1):99-108. doi:10.1177/0363546519885104.

14. Grasso S, Linklater J, Li Q, Parker DA. Validation of an MRI protocol for routine quantitative assessment of tunnel position in anterior cruciate ligament reconstruction. *Am J Sports Med*. 2018;46(7):1624-31. doi:10.1177/0363546518758950.

15. Putnis SE, Oshima T, Klasan A, Grasso S, Neri T, Fritsch BA, Parker DA. Magnetic Resonance Imaging 1 Year After Hamstring Autograft Anterior Cruciate Ligament Reconstruction Can Identify Those at Higher Risk of Graft Failure: An Analysis of 250 Cases. *Am J Sports Med*. 2021;49(5):1270-1278. doi:10.1177/0363546521995512.

16. Clatworthy MG, Annear P, Bulow JU, Bartlett RJ. Tunnel widening in anterior cruciate ligament reconstruction: a prospective evaluation of hamstring and patella tendon grafts. Knee Surg Sports Traumatol Arthrosc. 1999;7(3):138-45. doi:10.1007/s001670050138.

Journal Pre-proof

17. Aglietti P, Buzzi R, Giron F, Simeone AJ, Zaccherotti G. Arthroscopic-assisted anterior cruciate ligament reconstruction with the central third patellar tendon: A 5-8-year follow-up. Knee Surg Sports Traumatol Arthrosc. 1997;5(3):138-44. doi:10.1007/s001670050041.

18. Yau WP, Chan YC. Evaluation of Graft Ligamentization by MRI After Anterior Cruciate Ligament Reconstruction. *Am J Sports Med*. 2023;51(6):1466-1479. doi:10.1177/03635465231160790.

19. Orchard J, Seward H, McGivern J, Hood S. Intrinsic and extrinsic risk factors for anterior cruciate ligament injury in Australian footballers. *Am J Sports Med*. 2001;29(2):196-200. doi:10.1177/03635465010290021301.

20. Rougraff B, Shelbourne KD, Gerth PK, Warner J. Arthroscopic and histologic analysis of human patellar tendon autografts used for anterior cruciate ligament reconstruction. *Am J Sports Med*. 1993;21(2):277-284. doi:10.1177/036354659302100219.

21. Chu CR, Williams AA. Quantitative MRI UTE-T2* and T2* show progressive and continued graft maturation over 2 years in human patients after anterior cruciate ligament reconstruction. Orthop J Sports Med. 2019;7(8). doi:10.1177/2325967119863056.

22. Claes S, Verdonk P, Forsyth R, Bellemans J. The "ligamentization" process in anterior cruciate ligament reconstruction: what happens to the human graft? A systematic review of the literature. Am J Sports Med. 2011;39(11):2476-83. doi:10.1177/0363546511402662.

23. Morgan MD, Salmon LJ, Waller A, Roe JP, Pinczewski LA. Fifteen-Year Survival of Endoscopic Anterior Cruciate Ligament Reconstruction in Patients Aged 18 Years and Younger. *Am J Sports Med*. 2016;44(2):384-392. doi:10.1177/0363546515623032.

24. Webster KE, Hewett TE. What Is the Evidence for and Validity of Return-to-Sport Testing After Anterior Cruciate Ligament Reconstruction Surgery? A Systematic Review and Meta-Analysis. *Sports Med*. 2019;49(6):917-929. doi:10.1007/s40279-019-01093-x.

25. Colombet P, Graveleau N, Jambou S. Incorporation of hamstring grafts within the tibial tunnel after anterior cruciate ligament reconstruction: magnetic resonance imaging of suspensory fixation versus interference screws. Am J Sports Med. 2016;44(11):2838-45. doi:10.1177/0363546516656181.

26. Lin Y, Zhang L, Shen S, Chen Y, Xu L, Ji M, Guo Y, Wei J, Li Y, Wu X, Lu J. No Difference in Bone Tunnel Enlargement and Clinical Outcome Between Cortical Suspension and Hybrid Femoral Fixation in Hamstring Anterior Cruciate Ligament Reconstruction. *Orthop Surg*. 2024;16(4):902-911. doi:10.1111/os.14024.

27. Biset A, Douiri A, Robinson JR, Laboudie P, Colombet P, Graveleau N, Bouguennec N. Tibial tunnel expansion does not correlate with four-strand graft maturation after ACL reconstruction using adjustable cortical suspensory fixation. Knee Surg Sports Traumatol Arthrosc. 2023;31(5):1761-70. doi:10.1007/s00167-022-07051-x.

28. Bouguennec N, Robinson J, Douiri A, Graveleau N, Colombet PD. Two-year postoperative MRI appearances of anterior cruciate ligament hamstrings autografts are not correlated with functional outcomes, anterior laxity, or patient age. Bone Jt Open. 2021;2(8):569-75. doi:10.1302/2633-1462.28.BJO-2021-0104.R1.

29. Eichinger M, Ploner M, Degenhart G, Rudisch A, Smekal V, Attal R, Mayr R. Tunnel widening after ACL reconstruction with different fixation techniques: aperture fixation with biodegradable interference screws versus all-inside technique with suspensory cortical buttons. 5-year data from a prospective randomized trial. Arch Orthop Trauma Surg. 2023;143(11):6707-18. doi:10.1007/s00402-023-05001-x.

30. Li X, Yan L, Li D, Fan Z, Liu H, Wang G, Jiu J, Yang Z, Li JJ, Wang B. Failure modes after anterior cruciate ligament reconstruction: a systematic review and meta-analysis. *Int Orthop*. 2023;47(3):719-734. doi:10.1007/s00264-023-05687-z.

Journal Pre-proof

31. Goodwillie AD, Shah SS, McHugh MP, Nicholas SJ. The effect of postoperative KT-1000 arthrometer score on long-term outcome after anterior cruciate ligament reconstruction. Am J Sports Med. 2017;45(7):1522-8. doi:10.1177/0363546517690525.

32. Chiba D, Yamamoto Y, Kimura Y, Sasaki E, Sasaki S, Tsuda E, Ishibashi Y. Association between early postoperative graft signal intensity and residual knee laxity after anterior cruciate ligament reconstruction. Orthop J Sports Med. 2022;10(7). doi:10.1177/23259671221109608.

33. Lindanger L, Strand T, Mølster AO, Solheim E, Inderhaug E. Effect of Early Residual Laxity After Anterior Cruciate Ligament Reconstruction on Long-term Laxity, Graft Failure, Return to Sports, and Subjective Outcome at 25 Years. *Am J Sports Med*. 2021;49(5):1227-1235. doi:10.1177/0363546521990801.

34. Chona D, Eriksson K, Young SW, Denti M, Sancheti PK, Safran M, Sherman S. Return to sport following anterior cruciate ligament reconstruction: the argument for a multimodal approach to optimise decision-making: current concepts. J ISAKOS. 2021;6(6):344-8. doi:10.1136/jisakos-2020-000597.

35. Mancino F, Kayani B, Gabr A, Fontalis A, Plastow R, Haddad FS. Anterior cruciate ligament injuries in female athletes: risk factors and strategies for prevention. *Bone Jt Open*. 2024;5(2):94-100. doi:10.1302/2633-1462.52.BJO-2023-0166.

36. Marom N, Xiang W, Wolfe I, Jivanelli B, Williams RJ 3rd, Marx RG. High Variability and Lack of Standardization in the Evaluation of Return to Sport After ACL Reconstruction: A Systematic Review. *Knee Surg Traumatol Arthrosc*. 2022;30(4):1369-1379. doi:10.1007/s00167-021-06594-9.

37. Hurley ET, Mojica ES, Haskel JD, Mannino BJ, Alaia M, Strauss EJ, Jazrawi LM, Gonzalez-Lomas G. Return to play testing following anterior cruciate reconstruction - a systematic review & meta-analysis. *Knee*. 2022;34:134-40. doi:10.1016/j.knee.2021.11.010.

38. O'Dowd DP, Stanley J, Rosenfeldt MP, Walsh S, Twaddle B, De Ruiter L, Crua E, Monk AP, Walsh S. Reduction in Re-rupture Rates Following Implementation of Return-to-Sport Testing After Anterior Cruciate Ligament Reconstruction in 313 Patients With a Mean Follow-up of 50 Months. *J ISAKOS*. 2024;9(3):264-271. doi:10.1016/j.isakos.2024.01.005.

39. Zhou W, Liu X, Hong Q, Wang J, Luo X. Association Between Passing Return-to-Sport Testing and Re-Injury Risk in Patients After Anterior Cruciate Ligament Reconstruction Surgery: A Systematic Review and Meta-Analysis. *PeerJ*. 2024;12. doi:10.7717/peerj.17279.

40. Losciale JM, Zdeb RM, Ledbetter L, Reiman MP, Sell TC. The Association Between Passing Return-to-Sport Criteria and Second Anterior Cruciate Ligament Injury Risk: A Systematic Review With Meta-analysis. *J Orthop Sports Phys Ther*. 2019;49(2):43-54. doi:10.2519/jospt.2019.8190.

41. Paterno MV, Rauh MJ, Thomas S, Hewett TE, Schmitt LC. Return-to-Sport Criteria After Anterior Cruciate Ligament Reconstruction Fail to Identify the Risk of Second Anterior Cruciate Ligament Injury. *J Athl Train*. 2022;57(9-10):937-945. doi:10.4085/1062-6050-0608.21.

42. Iwagami M, Shinozaki T. Introduction to Matching in Case-Control and Cohort Studies. *Ann Clin Epidemiol*. 2022;4(2):33-40. doi:10.37737/ace.22005.

43. Howell SM, Clark JA, Blasier RD. Serial magnetic resonance imaging of hamstring anterior cruciate ligament autografts during the first year of implantation. A preliminary study. *Am J Sports Med*. 1991;19(1):42-7. doi:10.1177/036354659101900107.

44. Stöckle U, Hoffmann R, Schwedke J, Lubrich J, Vogl T, Südkamp NP, Haas N. Anterior Cruciate Ligament Reconstruction: The Diagnostic Value of MRI. *Int Orthop*. 1998;22(5):288-292. doi:10.1007/s002640050262.

Journal Pre-proof

45. Van Dyck P, Zazulia K, Smekens C, Heusdens CHW, Janssens T, Sijbers J. Assessment of Anterior Cruciate Ligament Graft Maturity With Conventional Magnetic Resonance Imaging: A Systematic Literature Review. *Orthop J Sports Med*. 2019. doi:10.1177/232596711984912.

46. Panos JA, Webster KE, Hewett TE. Anterior Cruciate Ligament Grafts Display Differential Maturation Patterns on Magnetic Resonance Imaging Following Reconstruction: A Systematic Review. *Knee Surg Sports Traumatol Arthrosc*. 2020;28(7):2124-2138. doi:10.1007/s00167-019-05685-y.

47. Park SY, Cho JH, Ho JPY, Tu NT, Kim YB, Lee YS. Graft Impingement Increases Anterior Cruciate Ligament Graft Signal More Than Acute Graft Bending Angle: Magnetic Resonance Imaging-Based Study in Outside-In Anterior Cruciate Ligament Reconstruction. *Knee Surg Sports Traumatol Arthrosc*. 2023;31(10):4379-4389. doi:10.1007/s00167-023-07491-z.

48. Vari N, Marot V, Cavaignac M, Vieira TD, Bérard É, Cavaignac E. Factors Affecting Graft Remodeling and Anterior Cruciate Ligament Reconstruction: MRI Study of 180 Knees. *Am J Sports Med*. 2023;51(8):2073-2078. doi:10.1177/03635465231171947.

49. Pioger C, Gousopoulos L, Hopper GP, Vieira TD, Campos JP, El Helou A, Philippe C, Saithna A, Sonnery-Cottet B. Clinical Outcomes After Combined ACL and Anterolateral Ligament Reconstruction Versus Isolated ACL Reconstruction With Bone-Patellar Tendon-Bone Grafts: A Matched-Pair Analysis of 2018 Patients From the SANTI Study Group. *Am J Sports Med*. 2022;50(13):3493-3501. doi:10.1177/03635465221128261.

Journal Pre-proof

Figure legend

Figure 1. Flowchart of study recruitment.

ACLR = anterior cruciate ligament reconstruction; MRI = magnetic resonance imaging; RTS = return to sport;

*groups matched based on age, sex, height, weight and BMI

Figure 2. Sagittal magnetic resonance imaging scan of the knee shows the positions of the 5 regions of interest. 1 = distal site; 2 = proximal site; 3 = midsubstance; 4 = posterior cruciate ligament; 5 = background site (approximately 2 cm anterior to the patellar tendon).

Figure 3. Examples of different SNQ values

a = low SNQ; b= high SNQ

SNQ = signal noise to quotient

Journal Pre-proof

Journal Pre-proof

Tables

	Entire Cohort	**Control Group**	**Re-rupture Group**
No. of patients	63	50	13
Age, year, mean ± SD	27.6 ± 11.1	28.5 ± 11.5	24.4 ± 9.3
Sex, % female	44.4	46	38.5
BMI(kg/m²), mean ± SD	23.6 ± 2.7	23.7 ± 2.8	23 ± 2.1

Table 1. Patient Characteristics (BMI = body mass index; SD = standard deviation)

Journal Pre-proof

Journal Pre-proof

	Control group (n=50)	Re-rupture group (n=13)	P Value
ΔLaxity			
Mean	1.3±1.9 mm	2.5±0.9 mm	0.189*
% > 2 mm	38.8%	83.3%	0.058$^{\Delta}$
Clinical outcomes			
IKDC	83.6 (54-100)	87.2 (79-100)	0.347$^{\#}$
Lysholm	91.1 (55-100)	94.4 (90-100)	0.300$^{\#}$
Tegner	5.8 (3-10)	7 (6-9)	0.078$^{\#}$
ACL RSI	64.7 (6.25-99.8)	61.5 (27-100)	0.739*
RTS tests			
Leg length (ACLR/Healthy*100)	100.05	100.07	0.759*
Hop dist (ACLR/Healthy*100)	90.1	91.7	0.939*
Hop height (ACLR/Healthy*100)	77.5	78.9	0.915*
Side hop (ACLR/Healthy*100)	85.1	93.9	0.418*
Graft signal (SNQ)			
Mean	2.02	2.93	0.029*
% > 2	38%	69.2%	0.044$^{\Delta}$
Tunnel widening > 50%			
number of *patients (%)*			
Femur	18 (36%)	1 (7.7%)	0.155$^{\Delta}$
Tibia	5 (10%)	2 (15.4%)	0.582$^{\Delta}$
Tunnel positioning			
number of *patients (%)*			
Tibia			
Sagittal (correct = 9+/-2 mm)			
Anterior (>11 mm)	4 (8%)	1 (8%)	0.971$^{\Delta}$
Correct (7-11 mm)	35 (70%)	12 (92%)	0.100$^{\Delta}$

Journal Pre-proof

Posterior (<7 mm)	11 (22%)	0 (0%)	0.063$^{\Delta}$
Mediolateral (correct = 5 +-/2 mm)			
Medial (>7 mm)	17 (34%)	1 (8%)	0.061$^{\Delta}$
Correct (3-7mm)	33 (66%)	12 (92%)	0.061$^{\Delta}$
Lateral (<3 mm)	0	0	-
Femur			
A-P (correct = 7 +/- 2 mm)			0.079$^{\Delta}$
Anterior (>9 mm)			0.079$^{\Delta}$
Correct (5-9 mm)	16 (32%)	1 (8%)	-
Posterior (<5 mm)	34 (68%)	12 (92%)	
H-L (correct = 6 +/-2 mm)	0	0	-
High (<4 mm)			0.957$^{\Delta}$
Correct (4-8 mm)	0	0	0.957$^{\Delta}$
Low (>8 mm)	35 (70%)	9 (69%)	
Aglietti method *(mean %)*	15 (30%)	4 (31%)	0.569*
	73.4	72	

Table 2. Clinical and MRI outcomes comparison between the control group and the re-rupture group (ACL RSI = anterior cruciate ligament return to sport after injury scale; RTS = return to sport; SNQ = signal noise quotient; A-P = antero-posterior; H-L = high-low; * = Mann-Whitney U; $^{\Delta}$= Chi Squared; $^{\#}$= Student's test)

Journal Pre-proof

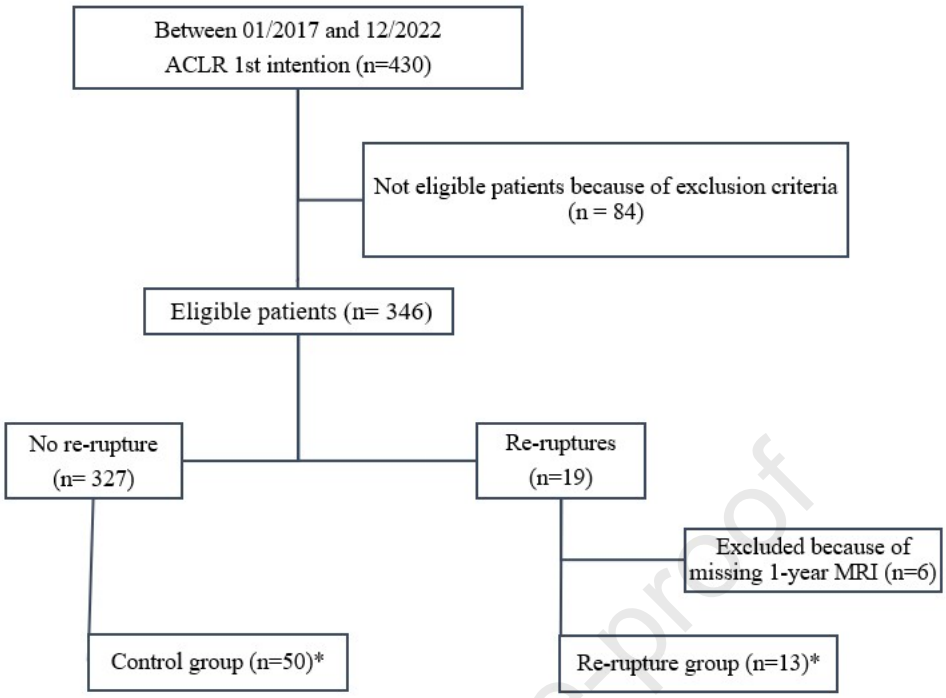

Figure 1

Journal Pre-proof

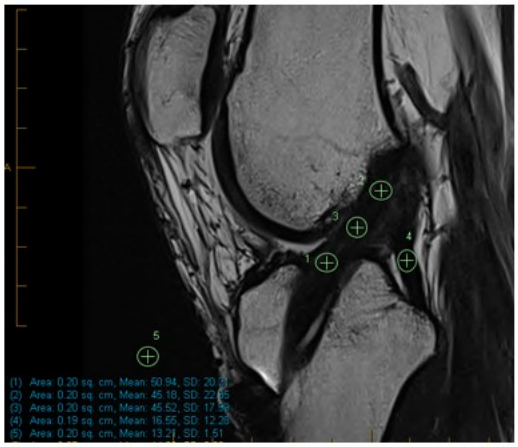

Figure 2

Journal Pre-proof

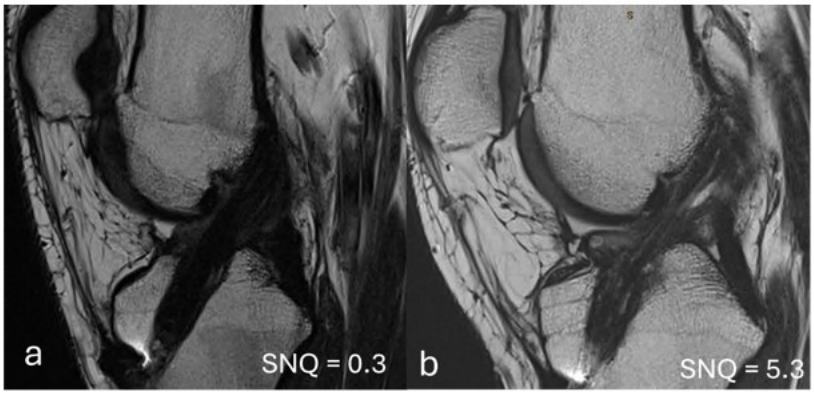

Figure 3

Journal Pre-proof

Journal Pre-proof

Declaration of interests

☐ The authors declare that they have no known competing financial interests or personal relationships that could have appeared to influence the work reported in this paper.

☒ The authors declare the following financial interests/personal relationships which may be considered as potential competing interests:

LUTZ reports a relationship with Zimmer Biomet that includes: consulting or advisory, paid expert testimony, and travel reimbursement. LUTZ reports a relationship with Arthrex GmbH that includes: consulting or advisory, paid expert testimony, and travel reimbursement. LUTZ reports a relationship with Medacta International SA that includes: consulting or advisory, paid expert testimony, and travel reimbursement. PARKER reports a relationship with International Society of Arthroscopy Knee Surgery and Orthopaedic Sports Medicine that includes: board membership. PARKER reports a relationship with Zimmer Biomet that includes: consulting or advisory, paid expert testimony, and travel reimbursement. PARKER reports a relationship with Smith & Nephew Inc that includes: consulting or advisory, paid expert testimony, and travel reimbursement. PARKER reports a relationship with Arthrex GmbH that includes: consulting or advisory, paid expert testimony, and travel reimbursement. PARKER reports a relationship with Corin Group that includes: consulting or advisory, paid expert testimony, and travel reimbursement. If there are other authors, they declare that they have no known competing financial interests or personal relationships that could have appeared to influence the work reported in this paper.

Journal Pre-proof