AJR American Journal of Roentgenology

Pitfalls in Interpretive Applications of Artificial Intelligence in Radiology

Shima Behzad, MD[1], Seyed M. Hossein Tabatabaei, MD[2], Max Y. Lu, BS[3], Liesl S. Eibschutz, MD[4], Ali Gholamrezanezhad, MD[5,6]

Policy, Quality, and Practice Management · Clinical Perspective

Keywords

accuracy, artificial intelligence developers, diagnostic radiology, interpretive artificial intelligence, pitfalls, workflow

Submitted: May 18, 2024
Revision requested: Jun 3, 2024
Revision received: Jun 27, 2024
Accepted: Jul 11, 2024
First published online: Jul 24, 2024
Version of record: Oct 9, 2024

The authors declare that there are no disclosures relevant to the subject matter of this article.

Interpretive artificial intelligence (AI) tools are poised to change the future of radiology. However, certain pitfalls may pose particular challenges for optimal AI interpretative performance. These include anatomic variants, age-related changes, postoperative changes, medical devices, image artifacts, lack of integration of prior and concurrent imaging examinations and clinical information, and the satisfaction-of-search effect. Model training and development should account for such pitfalls to minimize errors and optimize interpretation accuracy. More broadly, AI algorithms should be exposed to diverse and complex training datasets to yield a holistic interpretation that considers all relevant information beyond the individual examination. Successful clinical deployment of AI tools will require that radiologist end users recognize these pitfalls and other limitations of the available models. Furthermore, developers should incorporate explainable AI techniques (e.g., heat maps) into their tools, to improve radiologists' understanding of model outputs and to enable radiologists to provide feedback for guiding continuous learning and iterative refinement. In this article, we provide an overview of common pitfalls that radiologists may encounter when using interpretive AI products in daily practice. We present how such pitfalls lead to AI errors and offer potential strategies that AI developers may use for their mitigation.

Artificial intelligence (AI) tools for the interpretation of radiologic imaging have seen growing adoption into radiologists' clinical workflows. These tools show strong promise for improving diagnostic accuracy and/or workflow efficiency. However, a range of pitfalls make these tools prone to rendering both false-positive and false-negative interpretations. Successful clinical deployment of AI tools requires that radiologist end users understand such pitfalls along with other limitations of the available models. In this article, we provide an overview of common pitfalls that radiologists may encounter when using interpretive AI products in daily practice. We present how such pitfalls lead to AI errors and offer potential strategies that AI developers may use for their mitigation. All presented case examples reflect output from AI software with U.S. FDA approval.

General Issues in AI Model Training and Development

Developers create interpretative AI models using training sets of imaging examinations that have been designed to portray the pathology of interest. However, AI programs have commonly been trained using datasets with limited sample sizes or that contain limited distributions of radiologic findings, impairing models' generalizability to new data [1]. AI models are particularly prone to these generalizability issues when the training data exclude certain imaging features (e.g., certain pathologies or artifacts) or when the training data are biased (e.g., only reflect specific patient populations or equipment types) [2]. These dataset characteristics can lead to overfitting, whereby the model learns irrelevant noise within the dataset [3]. Overfitting can be mitigated by ensuring that the training set is sufficiently large and diverse and by validating the model on unseen data [3]. Specifically, datasets should encompass a diverse range of examples across anatomic locations, imaging modalities, and patient populations [1–3].

ARRS is accredited by the Accreditation Council for Continuing Medical Education (ACCME) to provide continuing medical education activities for physicians.
The ARRS designates this journal-based CME activity for a maximum of 1.00 AMA PRA Category 1 Credit™. Physicians should claim only the credit commensurate with the extent of their participation in the activity.
Use the "Claim Credit" link to access the CME activity.

doi.org/10.2214/AJR.24.31493
AJR 2024; 223:e2431493
ISSN-L 0361-803X/24/2234–e2431493
© American Roentgen Ray Society

[1]Independent researcher, Tehran, Iran.
[2]Department of Radiology, Massachusetts General Hospital, Harvard Medical School, 55 Fruit St, Boston, MA 02114. **Address correspondence to** S. M. H. Tabatabaei (smtabatabaei@mgh.harvard.edu, tabatabaei_smh).
[3]Department of Radiology, Keck School of Medicine, University of Southern California, Los Angeles, CA.
[4]University of Virginia Hospital, Charlottesville, VA.
[5]Department of Radiology, Los Angeles General Hospital, Los Angeles, CA.
[6]Department of Radiology, Cedars Sinai Hospital, Los Angeles, CA.

Downloaded from www.ajronline.org by Chung Shan Medical University on 12/24/25 from IP address 61.218.155.215. Copyright ARRS. For personal use only; all rights reserved

Downloaded from www.ajronline.org by Chung Shan Medical University on 12/24/25 from IP address 61.218.155.215. Copyright ARRS. For personal use only; all rights reserved

In certain instances, AI models may exhibit suboptimal performance due to the presence of particular pathologies or other imaging features that have distinct relevance to the finding that the model seeks to detect. For example, in an AI model for pulmonary embolus detection on pulmonary CT angiography, accuracy may be suboptimal in regions of the CT images that are affected by lung consolidation. Figure 1 shows a small nonobstructive pulmonary embolus missed by AI, probably due to obscuring of vessel borders by adjacent airspace opacities [4]. Training datasets should be tailored to the identified challenges, ensuring adequate representation of problematic cases to effectively target such issues [2]. Developers can adjust algorithm parameters or use other technical methods to improve accuracy in areas of images in which AI shows weak performance because of issues of this nature, to further fine-tune performance.

When learning to analyze radiologic images, AI-based algorithms may develop shortcuts or spurious correlations, particularly in the context of deep learning models [5]. This phenomenon occurs when an AI system learns to make decisions through features that are not relevant to the actual diagnostic criteria but rather are imaging artifacts or incidental findings [6]. For example, an AI system may inadvertently learn to assess chest radiographs for the presence or absence of pneumonia by focusing on text markers that indicate the patient's position (e.g., supine position) rather than focusing on radiographic signs of pneumonia. Such hindrances may occur if the AI model is exposed to a training dataset in which most images labeled with pneumonia also had supine markers, whereas those images without pneumonia did not, causing the model to confuse the presence of a supine marker as a predictor of pneumonia [5, 7–10]. In this example, the model's identified shortcut happens to correlate with labels in the training data, yielding high accuracy during training and validation but poor performance when the model is exposed to new and unseen data for which the correlation does not generalize or hold true. Thus, the AI model may be unable to recognize the presence of pneumonia on a patient's chest radiograph without a supine marker [5–10]. This issue is mitigated by curation of diverse and representative training datasets designed to minimize biases that could cause the algorithm to focus too heavily on certain features. Data augmentation and other techniques can be used to further increase the training data's variability and aid the algorithm in focusing on relevant features. Regularization methods can also be used to prevent models from relying too heavily on any one feature [5–10].

Highlights

- *Various pitfalls affect the performance of interpretative AI models in radiology practice. Radiologists and developers must recognize these pitfalls and adopt strategies for their mitigation.*

AI model performance must be continually monitored and decisions validated against expert human interpretations to ensure that the models make accurate and clinically relevant predictions [6]. Iterative refinement may remain needed throughout this ongoing evaluation [2]. The continuous improvement process seeks to optimize model performance by assessing drawbacks, modifying parameters, and retraining with datasets that account for relevant imaging and clinical factors discovered during development and deployment, to mitigate the likelihood of these factors leading to ongoing errors.

AI tools and humans process information differently, leading to different kinds of errors. Through their training via extensive datasets, AI models develop their own pattern recognition rules that may be inconsistent with human comprehension and existing diagnostic criteria [11, 12]. Thus, when evaluating AI model

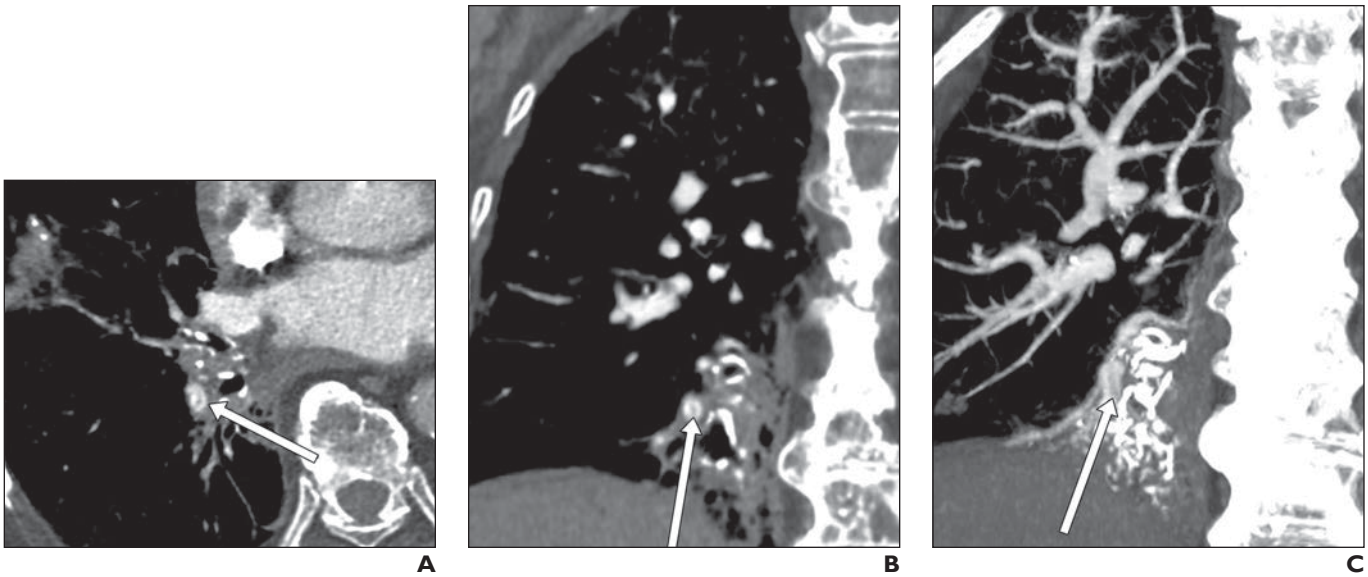

Fig. 1—94-year-old man presenting with dyspnea who underwent pulmonary CTA.
A–C, Axial (**A**) and coronal (**B** and **C**) images show nonobstructive filling defects (*arrows*) in segmental branches of right lower lobe, highly suggestive of pulmonary embolism. Finding was detected by radiologist but missed by artificial intelligence algorithm.

Downloaded from www.ajronline.org by Chung Shan Medical University on 12/24/25 from IP address 61.218.155.215. Copyright ARRS. For personal use only; all rights reserved

TABLE 1: Examples of Studies Reporting Sources of FN or FP Results of AI Algorithms for Interpretation of Radiologic Examinations

First Author [Reference]	Year	Detection Outcome of AI Tool	No. of Total Cases	Results (no.)		Reported Sources of FN or FP Results
				FN	FP	
Okada [53]	2024	COVID-19 on chest CT	406 Patients	12	16	FP: bacterial, viral, or atypical pneumonia; interstitial lung disease; lung tumor
Ruitenbeek [56]	2024	Fracture on cervical spine CT	2974 Patients	22	92	FP: vascular canals, ossifications or calcifications of LLs, degenerative changes
Kiefer [58]	2023	Intracranial hemorrhage on head CT	432 Patients	1	39	FP: head position (e.g., tilting), beam-hardening or motion artifacts, chronic defects in the brain parenchyma
Motohashi [59]	2023	Osteolytic bone metastasis on thoracolumbar CT	91 Lesions; 330 slices	Slices: 36; Lesions: 12	Slices: 61; Lesions: 55	FN: lesion location in the posterior elements of the spine FP: Schmorl nodes, degenerated intervertebral disks, Hahn clefts
Weikert [60]	2020	PE on CTPA	1465 CTPA examinations	17	55	FN: segmental or subsegmental PE location FP: contrast agent–related flow artifact, pulmonary vein, intrapulmonary lymph node, pulmonary infiltrate, beam-hardening artifact, pulmonary metastasis, breathing artifact, hilar soft tissue

Note—FN = false-negative, FP = false-positive, AI = artificial intelligence, LL = longitudinal ligament, PE = pulmonary embolism, CTPA = CT pulmonary angiography.

performance, developers and radiologists should be prepared to encounter errors that are distinct from the typical perceptual or cognitive errors expected from human radiologists.

In summary, many errors in interpretive AI products can largely be attributed to limitations in the training process, including biases related to the diversity, quantity, and quality of the training data [1, 3]. Nonetheless, improvement of model performance involves more than just broader training data [3]. Rather, the model must account for particular challenges relevant to the given interpretive task. Table 1 provides examples from the literature of factors that may lead to false-positive or false-negative AI results in certain settings. Table 2 summarizes key pitfalls and associated strategies for improvement.

Anatomic Variants and Age-Related Changes

Radiologists learn to be familiar with the imaging manifestations of anatomic variants and age-related changes. AI must also recognize such patterns to avoid misinterpreting these findings as pathology. Examples of such findings include calcifications of costal cartilages and the tracheobronchial tree [13], age-related bone density loss (particularly in the spine) [14], age-related mild widening of cerebral sulci and brain parenchymal volume loss [15], and degenerative joint disease.

Figure 2 shows a patient in whom AI misclassified a calcification on the anterior falx cerebri as a hemorrhage. This error could have been potentially prevented through more diverse training data that would have educated the AI algorithm to recognize

TABLE 2: Summary of Common Pitfalls and Other Limitations of Interpretive AI Algorithms in Diagnostic Radiology

Limitation or Pitfall	Description
Anatomic variants, age-related changes, postoperative findings, medical devices, and image artifacts	Absence of such findings in the training data may result in biased model with suboptimal performance across diverse sets of findings or patient populations. This lack of generalizability to new or unseen data leads to false-negative or false-positive results.
Lack of integration with prior or concurrent imaging examinations and with relevant clinical information	AI renders an incorrect diagnosis because it has incomplete access to prior or concurrent imaging examinations or to patient history, or because it is unable to analyze such information as a whole. Accordingly, AI evaluates a single imaging examination without a holistic consideration of crucial contextual information that could substantially impact interpretation.
Satisfaction-of-search effect	As occurs for human radiologists, detection of an initial pathology can stop the AI algorithm from searching for additional abnormalities, resulting in a false-negative result for a potentially significant finding.
Lack of explainability	The black box nature of some AI models may make it difficult for human users to understand how the algorithm makes decisions as well as create challenges in understanding and correcting model errors.
Communication gap	Insufficient communication between AI developers and radiologists can result in misunderstandings about clinical requirements and data interpretation.

Note—Based on information in [16–21, 25–30, 34–36, 46, 54]. AI = artificial intelligence.

Downloaded from www.ajronline.org by Chung Shan Medical University on 12/24/25 from IP address 61.218.155.215. Copyright ARRS. For personal use only; all rights reserved

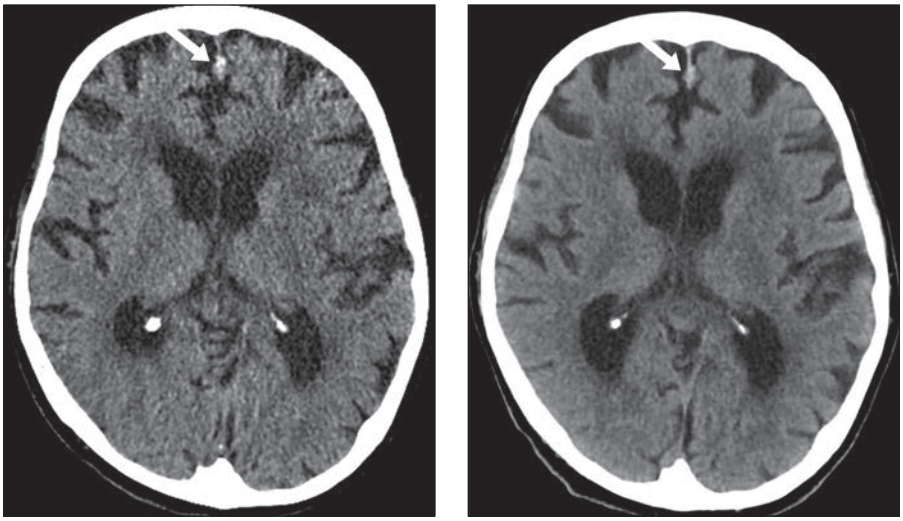

A B

Fig. 2—94-year-old woman who presented to emergency department with left facial droop after fall with head trauma.
A, Axial image from head CT shows small calcified focus on anterior falx cerebri (*arrow*). Artificial intelligence algorithm interpreted finding as intracranial hemorrhage.
B, Axial image from head CT performed approximately 1 year prior shows similar appearance of finding (*arrow*). Given finding's stability, radiologist interpreted finding as most likely calcification of anterior falx cerebri.

Fig. 3—85-year-old man who was admitted to emergency department after fall. Sagittal CT image shows compression fracture of T1 vertebral body (*arrow*) as well as prominent osteophyte formation along anterior border of cervical and upper thoracic spine. Artificial intelligence tool failed to identify age-indeterminate compression fracture deformity of T2 vertebral body, characterized by loss of approximately 50% of anterior vertebral body height with intact posterior cortex. Presence of osteophytes at anteroinferior aspect of fractured vertebral body likely contributed to this vertebral body's anterior border appearing potentially similar in size to posterior cortex.

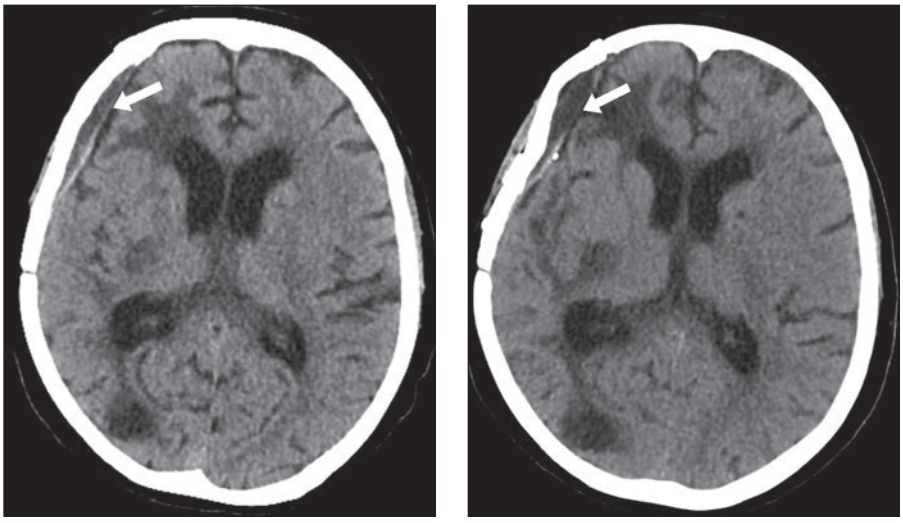

A B

Fig. 4—63-year-old woman with history of craniectomy who presented with right facial droop and left upper arm weakness.
A, Axial image from head CT shows subdural fluid accumulation in right frontal area (*arrow*). Artificial intelligence algorithm interpreted finding as intracranial hemorrhage.
B, Axial image from head CT performed 8 months prior shows similar appearance of finding (*arrow*). Given stability, radiologist interpreted finding as representing likely subdural hygroma.

Downloaded from www.ajronline.org by Chung Shan Medical University on 12/24/25 from IP address 61.218.155.215. Copyright ARRS. For personal use only; all rights reserved

age-related changes such as calcifications [16]. In addition, AI algorithms may fail to detect vertebral fractures in the presence of anterior vertebral body osteophytes or calcifications along the anterior longitudinal ligament. Figure 3 shows a patient with a posttraumatic compression fracture of the second thoracic vertebral body and concomitant spondylosis in whom AI failed to identify the fracture due to misinterpretation of vertebral body dimensions. Once the error is identified, the AI algorithm could potentially be refined to learn to correctly recognize this finding.

Postoperative Findings and Medical Devices

Postoperative changes also impact image interpretation, and AI algorithms that are not properly trained to account for such changes may yield false-positive results [17, 18]. The spectrum of postoperative alterations that may confound AI tools includes sequela of surgeries that alter anatomy (e.g., craniectomy, laminectomy) and the presence of surgical clips or other surgical instruments [17]. As a more subtle example, a patient may have hemidiaphragm elevation after cardiothoracic surgery due to iatrogenic phrenic nerve injury. Figure 4 shows a patient with a postcraniectomy subdural hygroma in whom AI interpreted postoperative dural thickening as intracranial hemorrhage.

The performance of AI algorithms can also be affected by the presence of medical devices such as catheters, implants, prosthetics, or pacemakers. These devices may cause adjacent artifacts or distortions, obscure anatomic structures or pathologies, or be misinterpreted as an abnormality [19–21]. Figure 5 shows a patient in whom AI misinterpreted a ventriculopleural shunt on chest CT as a rib fracture. The hyperattenuating catheter's curved trajectory in proximity to a rib mimicked a rib fracture on axial images. Models should thus be trained on image sets containing such devices. The incorporation of scout images can also improve model accuracy, as scout images provide a comprehensive view of the body that may assist in medical device identification and localization [22].

Image Artifacts

Beam hardening occurs when a polychromatic x-ray passes through an object, selectively attenuating lower-energy photons, resulting in a higher-energy beam [23]. This hardened beam manifests on imaging as distinct hypoattenuating bands or as a combination of hyper- and hypoattenuating bands traversing through tissues [24]. When presenting as hyper- and hypoattenuating bands, beam-hardening artifact presents a major pitfall for AI-based detection of hemorrhage on head CT, because such models learn to assess for the presence of hyperattenuation [25]. Moreover, beam-hardening artifacts are especially prevalent in the brain's convexities and in the anterior or middle cranial fossa, regions prone to hemorrhage, especially after trauma [24]. Figures 6A through 6C show a patient in whom AI misinterpreted beam-hardening artifact on head CT as intracranial hemorrhage. Beam-hardening artifact can also lead to false-negative AI results for intracranial hemorrhage [26, 27].

Motion artifacts are an additional cause of false-negative AI results for detection of intracranial hemorrhage. Figures 6D and 6E show a patient in whom motion artifact resulted in numerous irregular hyperattenuating foci by the skull base, causing AI to miss pontine hemorrhage. Historically, the presence of motion artifact has been a common exclusion criterion for image selection within AI training sets, such that the developed models could not sufficiently account for this artifact [25, 26, 28].

Integration of Prior and Concurrent Imaging Examinations

Comparison with prior and concurrent imaging examinations is a key aspect of radiologic interpretation, and failure to perform such comparison contributes to approximately 5% of radiologists' missed findings [29]. AI models may learn only to interpret a single imaging examination, without consideration of other available potentially relevant imaging examinations. This

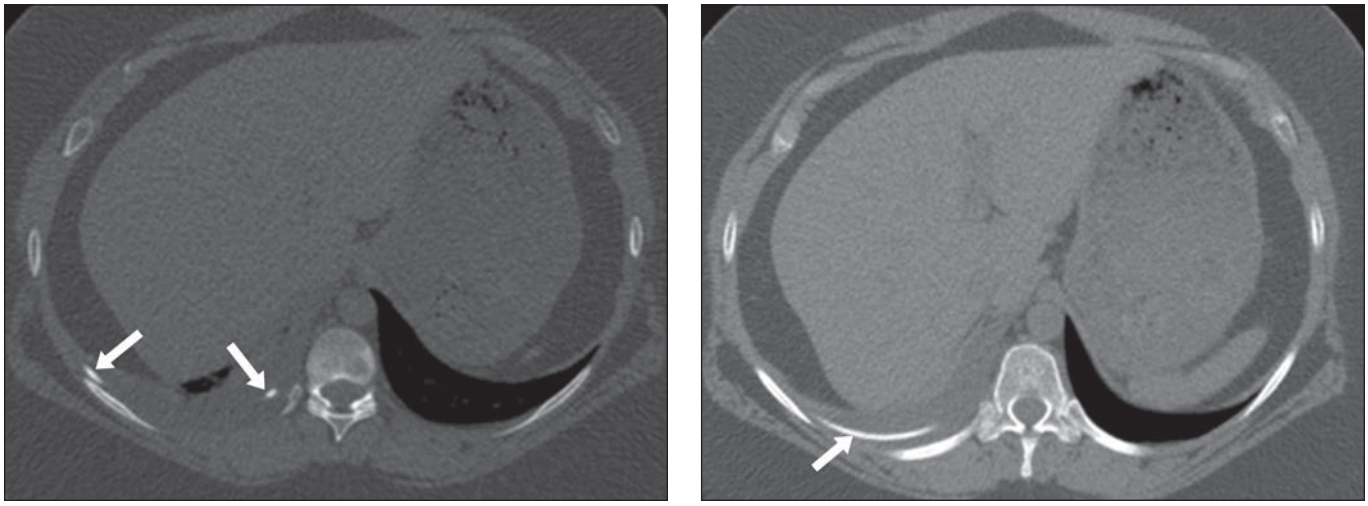

Fig. 5—24-year-old woman with history of ventriculopleural shunt placement who presented with chest pain.
A, Axial image from chest CT shows two small linear hyperattenuating structures (*arrows*), with larger hyperattenuating structure oriented parallel and very close to rib. Artificial intelligence algorithm interpreted finding as rib fracture.
B, Additional axial image from same examination indicates that finding relates to patient's ventriculopleural shunt (*arrow*) passing alongside rib. Radiologist made correct interpretation on assessment of entire examination.

Downloaded from www.ajronline.org by Chung Shan Medical University on 12/24/25 from IP address 61.218.155.215. Copyright ARRS. For personal use only; all rights reserved

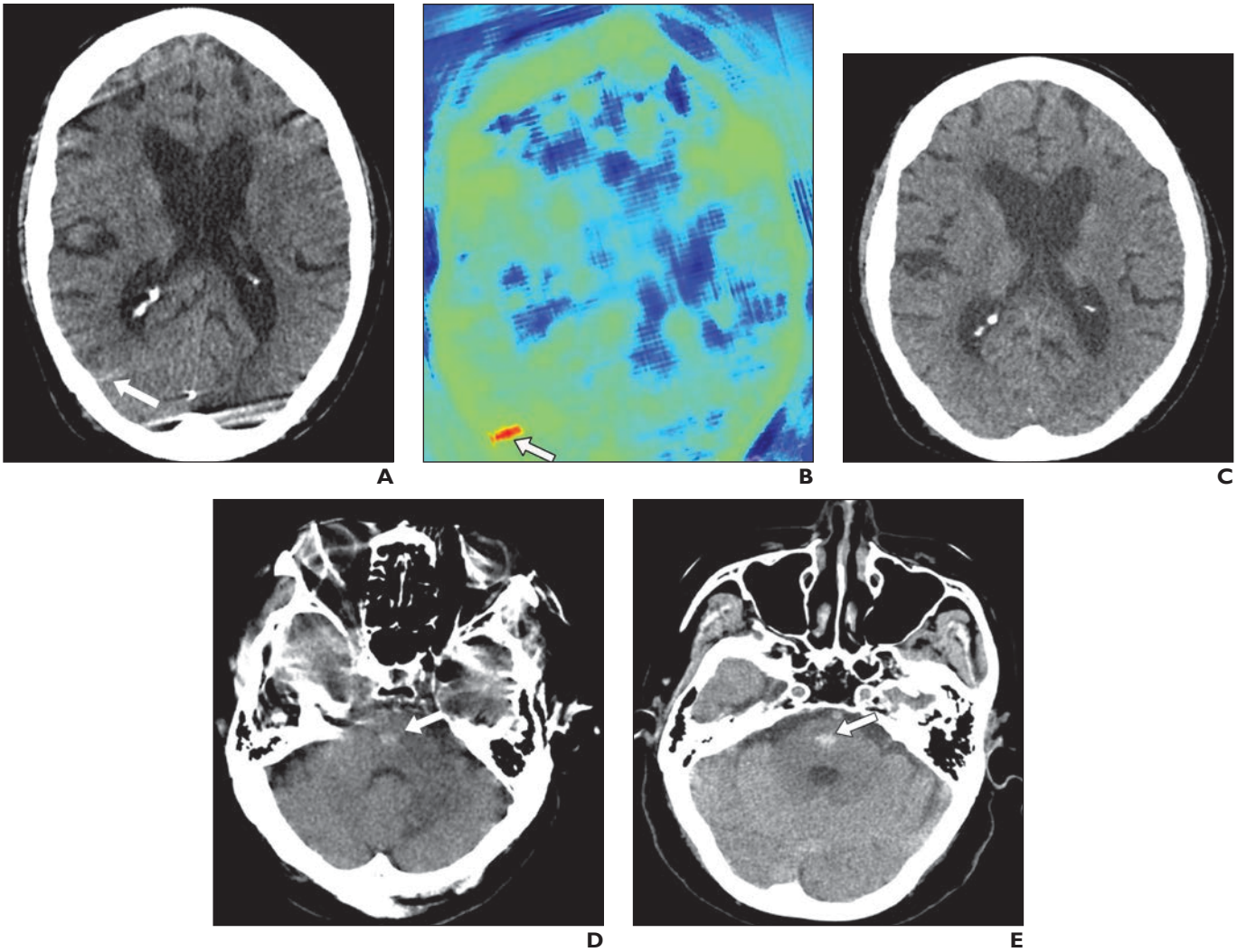

Fig. 6—Imaging artifacts causing challenges in artificial intelligence (AI) diagnosis.
A–C, 68-year-old man who presented with fall after syncope. Axial image from head CT (**A**) shows linear hyperattenuating structure in right parietooccipital area (*arrow,* **A** and **B**). AI tool interpreted image as showing intracranial hemorrhage. Heat map (**B**) indicates that right parietooccipital region was primary area of concern for AI assessment. Image's bottom portion has been cropped to remove embedded information about name of AI product. Axial image from repeat head CT (**C**) does not show finding that had been identified on initial head CT. Initial finding was attributed to beam-hardening artifact rather than intracranial hemorrhage.
D and **E,** 84-year-old woman who presented after fall. Axial image from head CT (**D**) shows 8-mm parenchymal hematoma in pons (*arrow*, **D**). AI algorithm did not detect hemorrhage, possibly due to presence of motion artifact. Axial image from follow-up head CT (**E**) again shows hematoma in pons (*arrow*, **E**). Motion artifact is not present on follow-up CT, and AI algorithm detected presence of hemorrhage.

limitation in model development can lead to diagnostic errors. AI models should therefore be trained to integrate and register into their interpretation process prior and concurrent imaging examinations, including those of different modalities.

Figure 7 shows a patient in whom AI erroneously interpreted a colloid cyst of the third ventricle on head CT as hemorrhage. Figure 8 shows another patient in whom AI erroneously interpreted a parafalcine meningioma on head CT as hemorrhage. In both patients, subsequent human review of a prior brain CT examination and identification of the finding's long-term stability proved critical in determining the correct diagnosis and uncovering the AI misinterpretation. Potentially, AI could learn to similarly compare findings with earlier examinations.

Figure 9 shows a patient in whom AI detected restricted diffusion in the right thalamus and opercular cortex on brain MRI but missed occlusion of the M2 segment of the right middle cerebral artery on later brain CTA. This error could potentially have been avoided through integration of knowledge of the acute ischemic stroke on DWI into the AI model for CTA analysis, in addition to targeted fine-tuning of the large-vessel occlusion detection algorithm itself.

Integration of Patient Medical History and Other Clinical Information

AI models could receive as input not only radiologic images but additional relevant clinical data. The model could then perform an integrated analysis, combining these various modalities of information, to provide more effective diagnoses in comparison with single-modality models (i.e., models evaluating images alone) [30]. For example, along with imaging findings, factors

Downloaded from www.ajronline.org by Chung Shan Medical University on 12/24/25 from IP address 61.218.155.215. Copyright ARRS. For personal use only; all rights reserved

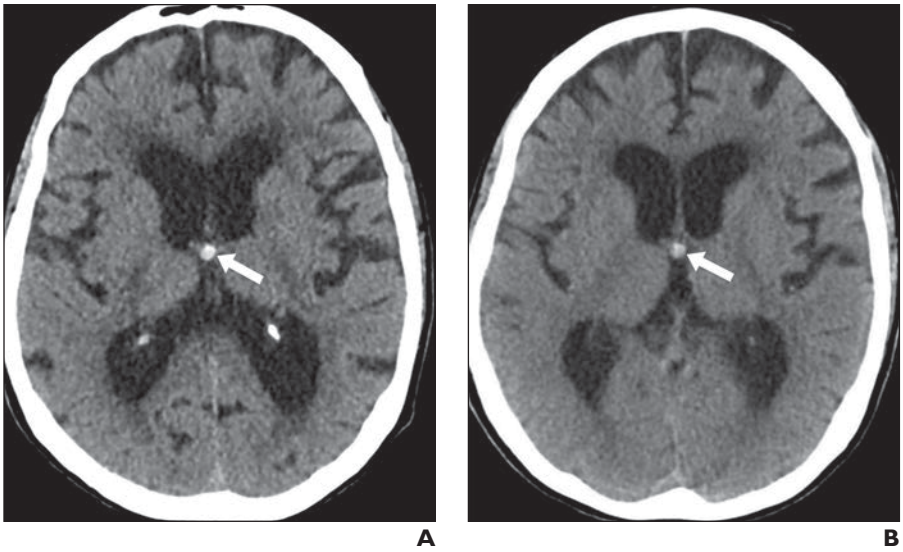

Fig. 7—77-year-old man who presented with altered mental status after fall.
A, Axial image from head CT shows round hyperattenuating intraventricular focus (*arrow*). Artificial intelligence algorithm interpreted focus as focal intracranial hemorrhage.
B, Axial image from head CT performed 2 years prior shows similar appearance of finding (*arrow*). Radiologist therefore deemed hemorrhage to be unlikely and characterized finding as colloid cyst of foramen of Monro.

such as age, sex, BMI, fracture history, weight, and laboratory tests, among others, have proven efficacious in predicting osteoporosis risk [28]. Figure 10 shows a patient in whom an AI tool failed to detect a hyperextension-type lumbar spine fracture. This error may have been caused by the presence of diffuse demineralization and osteopenia and the absence of wedging or vertebral body height loss. An understanding by the AI tool of the trauma mechanism may have aided fracture identification. Age, in particular, is an important model input, given its strong association with a wide range of pathologies. Although incorporation of additional clinical factors into models can have benefit, developers of multimodal models must be careful to avoid overfitting of an excess number of model variables, as occurs when models become excessively complex [3]. As previously mentioned, the use of sufficiently large training sets and thorough validation can also help counteract the risk of overfitting [3].

Through the integration of medical history and other clinical information (along with other available imaging examinations), AI tools may learn to provide a holistic interpretation of the patient's pathology, analogous to a human radiologist's assessment. We have encountered cases in which AI initially detected a finding such as a fracture but failed to detect the same finding on a subsequent imaging examination of the same or a different modality, even though the finding's appearance remained consistent across

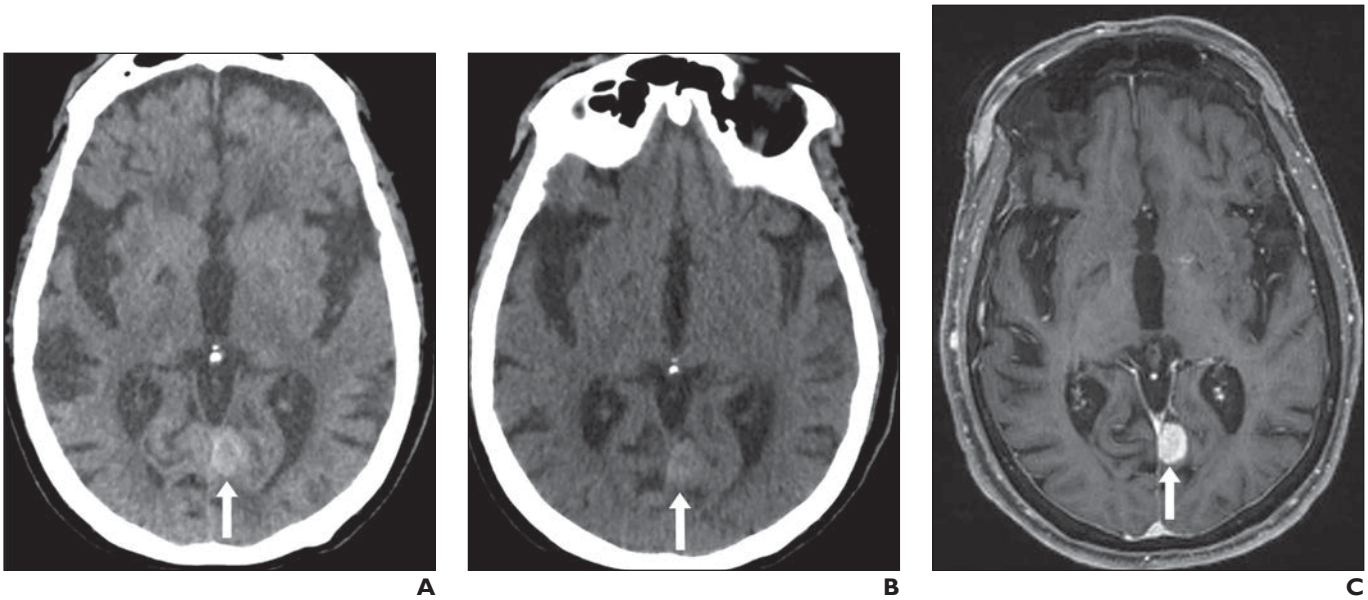

Fig. 8—78-year-old woman who presented to emergency department for aphasia.
A, Axial image from head CT shows oval hyperattenuating structure along left side of posterior falx cerebri (*arrow*). Artificial intelligence algorithm interpreted finding as intracranial hemorrhage.
B, Axial image from head CT performed 8 months prior shows similar size and location of finding (*arrow*). Radiologist therefore deemed hemorrhage to be unlikely.
C, Axial contrast-enhanced fat-saturated T1-weighted image from MRI performed after CT examination in **A** shows solid extraaxial mass with intense homogeneous contrast enhancement (*arrow*), highly suggestive of parafalcine meningioma.

Downloaded from www.ajronline.org by Chung Shan Medical University on 12/24/25 from IP address 61.218.155.215. Copyright ARRS. For personal use only; all rights reserved

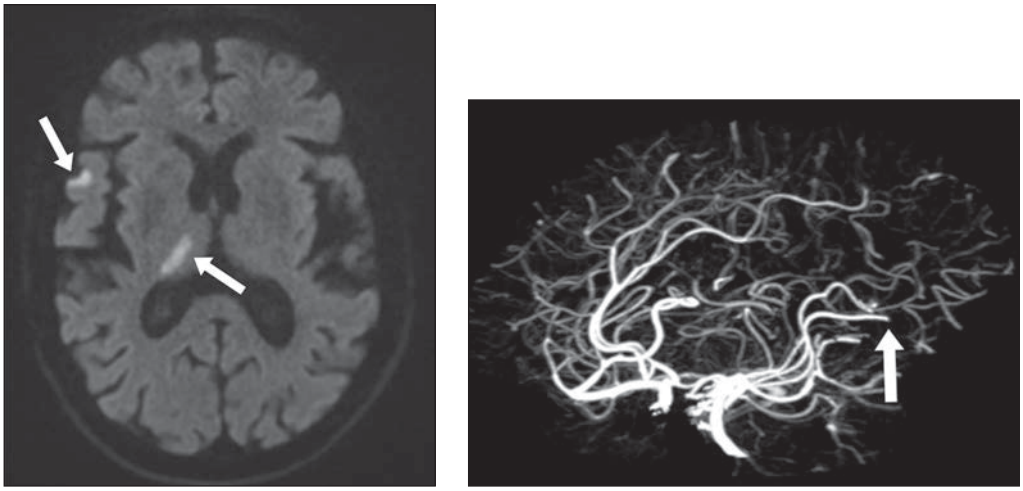

Fig. 9—82-year-old man who presented with symptoms of acute stroke.
A, DWI shows hyperintense foci in right thalamus and insular cortex (*arrows*). ADC map showed corresponding hypointensity (not shown). Finding is highly suggestive of acute ischemic stroke.
B, Three-dimensional maximum-intensity-projection image from brain CTA shows complete occlusion of M2 segment of right middle cerebral artery (*arrow*), which was not identified by artificial intelligence algorithm for detection of large-vessel occlusion.

studies. Such cases highlight how contextual information beyond the image itself may influence AI interpretations.

Satisfaction-of-Search Effect

The satisfaction-of-search effect is a widely reported phenomenon in radiology of failure to detect an additional abnormality after an initial abnormality has already been identified [31, 32]. Radiologists may be predisposed to this error when concurrently searching for multiple pathologies, whereby detection of one target inadvertently causes oversight of the others [31]. Even highly experienced radiologists are prone to satisfaction-of-search effect [33]. Berbaum et al. [34] reported this effect in the context of a pulmonary nodules, whereby nodule detection decreased the accuracy for detection of various additional abnormalities.

The satisfaction-of-search effect is not exclusive to human cognition but has also been observed for AI algorithms. Figure 11 shows a patient in whom an AI algorithm failed to identify a second hemorrhage after successfully detecting an initial hemorrhage. Thus, AI algorithms must be developed to continue to thoroughly scan each image even after detecting an initial pathology.

Explainable AI Techniques

Deep learning–based AI techniques acquire knowledge of patterns in images, without explicit or direct human programming. Additionally, different models for a given task learn to conduct image analysis in different manners, relying on distinct sets of features and classification patterns that may be too complex for humans to easily understand [35]. Indeed, AI may perceive patterns in images that humans cannot [35]. Thus, how AI models have reached their decisions is typically unclear to radiologists. This lack of transparency in models' decision-making process, described as the "black box problem" [36], poses a challenge in AI adoption.

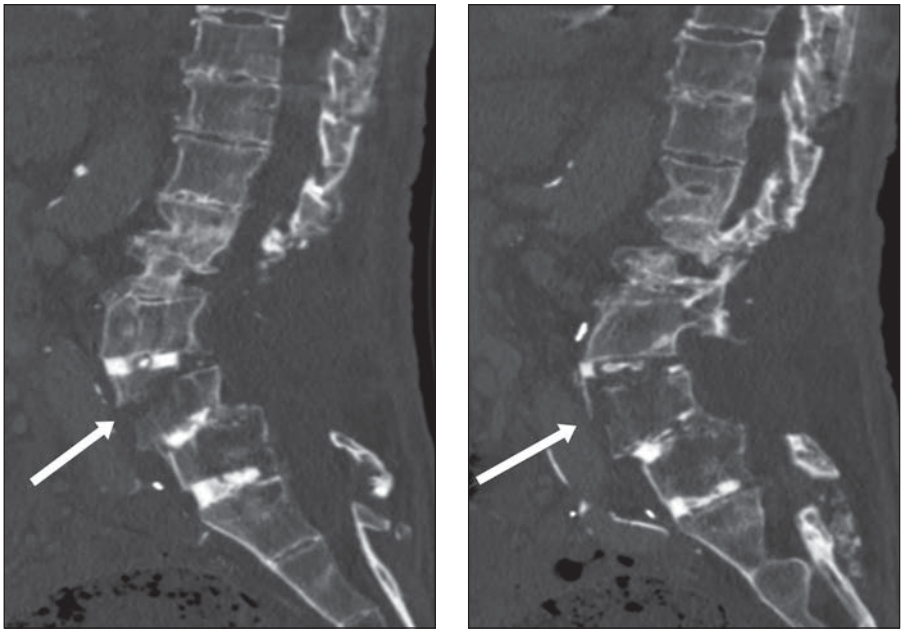

Fig. 10—79-year-old man with prior lumbar spine posterior decompression and fixation.
A and **B,** Sagittal reconstructed images from lumbar spine CT show hyperextension-type fracture involving superior end plate of L4 vertebral body (*arrows*). Artificial intelligence algorithm failed to identify fracture.

Downloaded from www.ajronline.org by Chung Shan Medical University on 12/24/25 from IP address 61.218.155.215. Copyright ARRS. For personal use only; all rights reserved

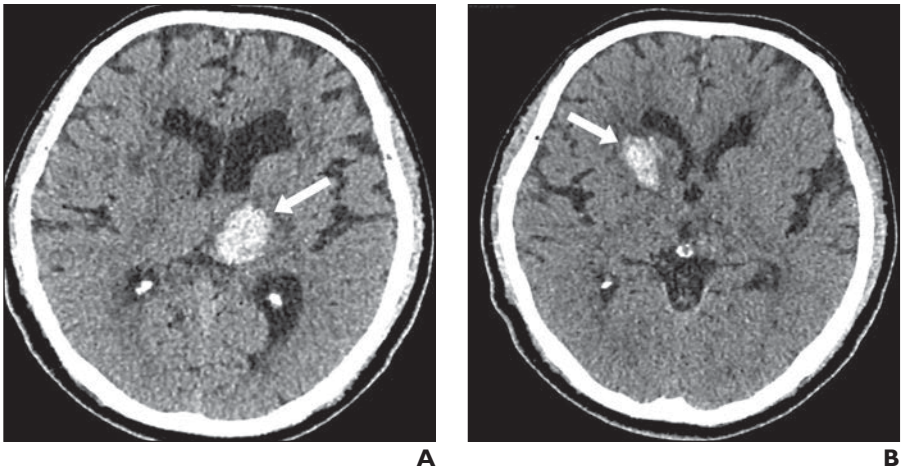

Fig. 11—69-year-old man who presented with altered mental status.
A, Axial image from head CT shows parenchymal hemorrhage in left thalamus (*arrow*). Artificial intelligence (AI) algorithm interpreted image as showing parenchymal hemorrhage.
B, Additional axial image from same examination shows secondary parenchymal hemorrhage in right lentiform nucleus (*arrow*). Secondary hemorrhage was detected by radiologist but not by AI algorithm, possibly due to satisfaction-of-search effect.

Explainable AI (XAI) techniques reveal the processes by which AI tools reach their decisions, promoting model transparency [37–42] and improving radiologists' understanding of the AI results [43]. The use of XAI techniques helps radiologists to gain trust and confidence in the AI tool and to recognize the tool's benefits, limitations, and biases [43]. In certain scenarios, XAI techniques may aid radiologists in learning to perceive new patterns in images themselves [35].

Heat maps are a common XAI technique used in the context of interpretive AI and may aid radiologists in uncovering sources of AI errors. Figure 12 shows a lumbar spine CT image in which AI erroneously marked the majority of vertebrae as fractured. The

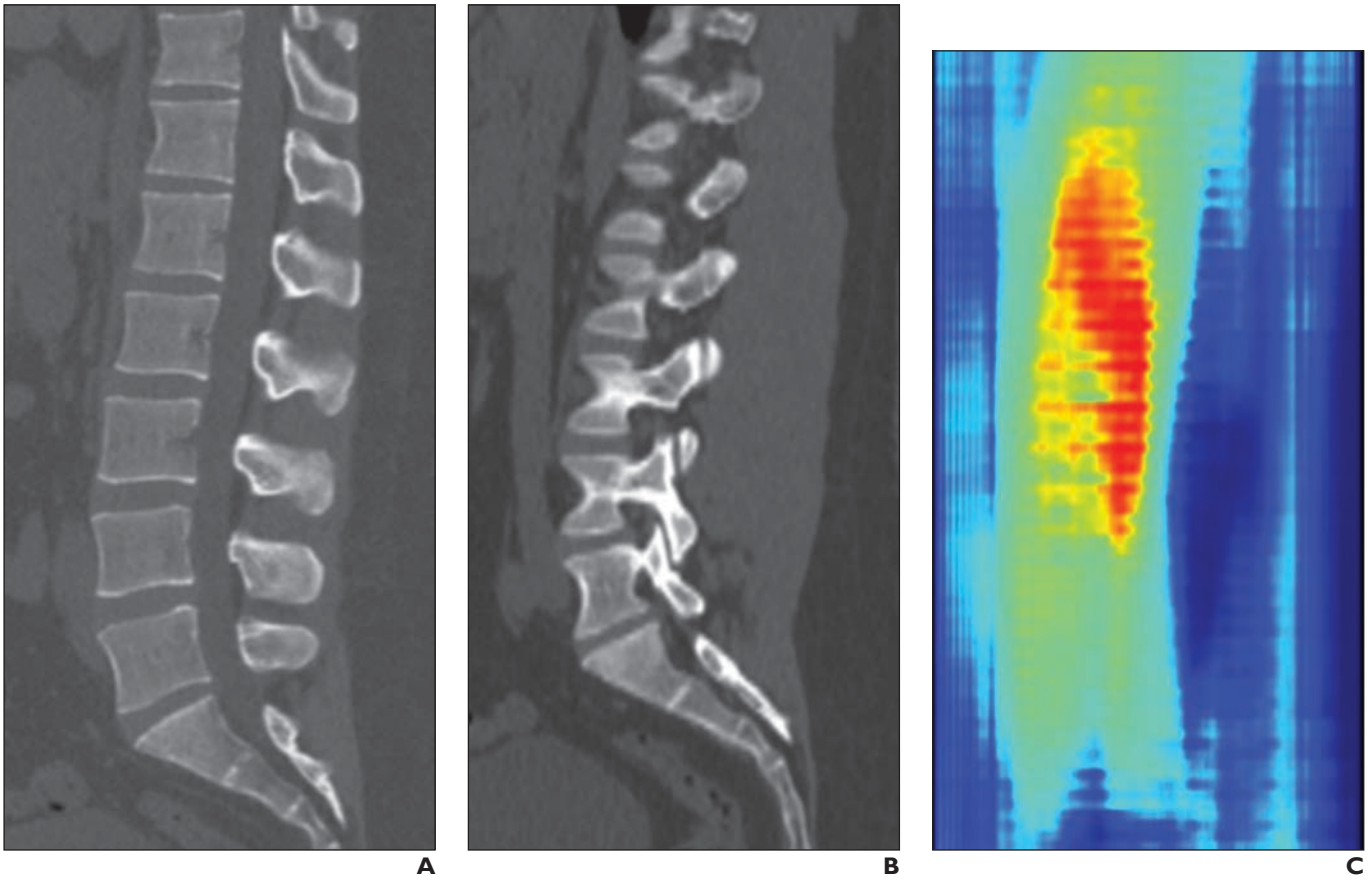

Fig. 12—33-year-old man who presented to emergency department with intense lower back pain after squatting 2 days earlier.
A and **B,** Sagittal reconstructed images from lumbar spine CT at level of vertebral bodies (**A**) and facet joints (**B**) show no evidence of fracture. Radiologist interpreted examination as negative for fracture. However, artificial intelligence (AI) tool reported presence of fracture.
C, Heat map shows localized erroneous fracture detection by AI to large area of spine, possibly corresponding to normal facet joints.

Downloaded from www.ajronline.org by Chung Shan Medical University on 12/24/25 from IP address 61.218.155.215. Copyright ARRS. For personal use only; all rights reserved

heat map indicates the portion of the spine on which the AI model focused in reaching this determination. This information provided the radiologist with insight into the process behind the algorithm's decision that would not have been apparent from the positive AI result alone.

AI developers should embrace XAI techniques and create models that effectively communicate their image analysis process. XAI techniques may also aid the developers in better understanding their own models' processes, to guide model development and refinement. For example, heat maps may help pinpoint the causes of model errors and improve the efficacy of attempted solutions.

Workflows for Clinical Deployment of Interpretive AI Models

Given the described pitfalls, AI tools should currently be used solely as a second opinion and not as an autonomous tool for image interpretation. Radiologists must continue to provide close oversight of interpretive AI models and cross-check AI output to identify possible false-positive or false-negative results. When an inconsistency is identified, radiologists should closely examine any available AI-generated heat maps to gain further insight.

When deploying AI models, a key consideration is the timing of presentation of AI results to the radiologist, as awareness of AI results may bias human readers' interpretations and search patterns [44]. Radiology practices may choose to implement systems whereby radiologists first interpret imaging examinations on their own before being presented with AI results. This sequence reflects the currently preferred approach for mammography interpretation [45]. On the other hand (as described in the next section), practices may choose to alert radiologists of AI findings up front in select situations, for example, when using AI to expedite the reporting of potentially urgent findings.

Use of AI for Additional Tasks Related to Image Interpretation

AI tools can be used to address additional tasks that radiologists perform during image interpretation. For example, the hanging protocol refers to the set of guidelines for presentation of a given imaging examination and governs such factors as screen layout; sequence placement; and window width, zoom, and pan [46]. In one study, AI helped to optimize hanging protocols for lumbar spine radiographs [47]. AI may also be used to develop hanging protocols that adjust to individual users' preferences. The use of AI for hanging protocol optimization could improve radiologists' workflow efficiency by reducing the time spent sorting or manipulating images.

An additional aspect of hanging protocols is the incorporation of relevant comparison studies within the display [29]. Currently, this process is facilitated by DICOM metadata, but such information is prone to error and lacks precision [48]. Filice et al. [48] developed a federated deep learning pixel-based model that identified an imaging examination's body part (chest, abdomen, or pelvis) without use of DICOM metadata, achieving an overall accuracy of 96.6%. This use of AI to optimize the retrieval and display of relevant prior examinations can also reduce radiologist workload.

AI tools can additionally be used to optimize radiologists' reading worklists. For example, AI tools can screen examinations for the presence of important actionable imaging findings (e.g., intracranial hemorrhage or pulmonary embolus) and then move these cases to the top of the reading worklist. This AI-facilitated worklist reprioritization can decrease report turnaround times for examinations with findings possibly requiring urgent intervention [49].

Finally, AI could assist radiologists by analyzing patients' medical records and streamlining the retrieval and organization of clinically relevant information that may aid diagnosis. In a survey of radiologists, 72% reported often needing more clinical information than they received, and 87% reported that additional clinical information could have modified their interpretation [50]. Radiologists' most common sources of clinical information include outside radiology reports, hospital admission notes, and progress notes [50]. Integration of AI-based natural language processing tools into radiologists' workflow could potentially enhance the summarization of pertinent clinical information from these disparate sources [51]. For example, when interpreting a postoperative lumbar spine CT examination, an AI algorithm could provide the radiologist with a consolidated summary containing information on the trauma mechanism, the region in which the patient is experiencing pain, and physical examination findings such as areas of tenderness. Such tools could also be used to help to address imaging requisitions that are incomplete or discordant with referring physician notes [52]. Finally, large language models or other generative AI tools could be developed that would synthesize large amounts of clinical data into summaries with potentially novel insights and predictions based on patterns identified in patient records, to further guide radiologists' interpretations.

Communication Between AI Developers and Radiologists

Successful AI deployment requires that developers examine model shortcomings and mistakes and that radiologists understand model limitations and pitfalls, with collaboration between both groups. Close integration and communication between AI developers and radiologists facilitate exchange of technical expertise and domain-specific knowledge, harnessing each group's strengths to bridge the gap between algorithm capabilities and clinical requirements to optimize AI accuracy [53]. In particular, radiologists should provide feedback to AI developers regarding model performance. Although many AI products offer options to enable users to provide this feedback, radiologists may not consistently use such features [54]. Nonetheless, radiologists should actively identify and report false-positive and false-negative AI results, highlighting discrepancies between AI output and clinical observations. Through this feedback, radiologists can play a pivotal role in helping to refine models to address deficiencies, improve performance, and best suit clinical needs [54, 55]. Further, close collaboration enables AI developers to gain a deeper understanding of radiologists' interpretation patterns and also provide radiologists with insights into AI product development [56]. This mutual exchange of knowledge allows both groups to introduce novel ideas and suggestions for future model development [57].

Conclusion

Interpretive AI tools are poised to change the future of radiology. However, certain issues must be addressed before these algorithms are fully integrated into clinical practice. In this article, we

Downloaded from www.ajronline.org by Chung Shan Medical University on 12/24/25 from IP address 61.218.155.215. Copyright ARRS. For personal use only; all rights reserved

have presented pitfalls that may pose particular challenges for optimal AI interpretative performance. These include anatomic variants, age-related changes, postoperative changes, medical devices, image artifacts, lack of integration of prior and concurrent imaging examinations and clinical information, and the satisfaction-of-search effect. Model training and development should account for such pitfalls to minimize errors and optimize interpretation accuracy. More broadly, AI algorithms should be exposed to diverse and complex multimodal training datasets to yield a holistic interpretation that considers all relevant information. Moreover, developers should incorporate XAI techniques into their tools to improve radiologists' understanding of and confidence in the AI output. The evolution of AI's diagnostic capabilities will require continuous learning through an iterative feedback loop. Throughout this process, developers and radiologists must maintain close communication to foster an adaptive yet precise AI framework that will ultimately advance radiology practice.

Provenance and review: Not solicited; externally peer reviewed.

Peer reviewers: Antonio Luna, HTmedica; additional individual(s) who chose not to disclose their identity.

References

1. Thrall JH, Li X, Li Q, et al. Artificial intelligence and machine learning in radiology: opportunities, challenges, pitfalls, and criteria for success. *J Am Coll Radiol* 2018; 15(3 pt B):504–508
2. Rubin DL. Artificial intelligence in imaging: the radiologist's role. *J Am Coll Radiol* 2019; 16(9 pt B):1309–1317
3. Eche T, Schwartz LH, Mokrane FZ, Dercle L. Toward generalizability in the deployment of artificial intelligence in radiology: role of computation stress testing to overcome underspecification. *Radiol Artif Intel*l 2021; 3:e210097
4. Chambon P, Cook TS, Langlotz CP. Improved fine-tuning of in-domain transformer model for inferring COVID-19 presence in multi-institutional radiology reports. *J Digit Imaging* 2023; 36:164–177
5. Yang Y, Mei G, Piccialli F. A deep learning approach considering image background for pneumonia identification using explainable AI (XAI). *IEEE/ACM Trans Comput Biol Bioinformatics* 2022 Jul 12 [published online]
6. Banerjee I, Bhattacharjee K, Burns JL, et al. "Shortcuts" causing bias in radiology artificial intelligence: causes, evaluation, and mitigation. *J Am Coll Radiol* 2023; 20:842–851
7. Kwon T, Lee SP, Kim D, et al. Diagnostic performance of artificial intelligence model for pneumonia from chest radiography. *PLoS One* 2021; 16:e0249399
8. Rueckel J, Kunz WG, Hoppe BF, et al. Artificial intelligence algorithm detecting lung infection in supine chest radiographs of critically ill patients with a diagnostic accuracy similar to board-certified radiologists. *Crit Care Med* 2020; 48:e574–e583
9. Becker J, Decker JA, Römmele C, et al. Artificial intelligence-based detection of pneumonia in chest radiographs. *Diagnostics (Basel)* 2022; 12:1465
10. Kaviani P, Digumarthy SR, Bizzo BC, et al. Performance of a chest radiography AI algorithm for detection of missed or mislabeled findings: a multicenter study. *Diagnostics (Basel)* 2022; 12:2086
11. Najjar R. Redefining radiology: a review of artificial intelligence integration in medical imaging. *Diagnostics (Basel)* 2023; 13:2760
12. Marcus E, Teuwen J. Artificial intelligence and explanation: how, why, and when to explain black boxes. *Eur J Radiol* 2024; 173:111393
13. Jo SH, Choi YJ, Cho GY, Kim HS, Jung KS, Rhim CY. Tracheal calcification. *CMAJ* 2008; 179:291
14. Demontiero O, Vidal C, Duque G. Aging and bone loss: new insights for the clinician. *Ther Adv Musculoskelet Dis* 2012; 4:61–76
15. Yamada S, Otani T, Ii S, et al. Aging-related volume changes in the brain and cerebrospinal fluid using artificial intelligence-automated segmentation. *Eur Radiol* 2023; 33:7099–7112
16. Acosta JN, Falcone GJ, Rajpurkar P. The need for medical artificial intelligence that incorporates prior images. *Radiology* 2022; 304:283–288
17. Cardoso O, Adly M, Hamade M, Saigal K, Saigal G. False positives in artificial intelligence prioritization software for intracranial hemorrhage identification in the postoperative period: a report of two cases. *Cureus* 2023; 15:e44215
18. Seyam M, Weikert T, Sauter A, Brehm A, Psychogios MN, Blackham KA. Utilization of artificial intelligence-based intracranial hemorrhage detection on emergent noncontrast CT images in clinical workflow. *Radiol Artif Intell* 2022; 4:e210168
19. Lee EM, Ibrahim EH, Dudek N, et al. Improving MR image quality in patients with metallic implants. *RadioGraphics* 2021; 41:E126–E137
20. Fowler KJ, Maxwell J, Saad NE, et al. Magnetic resonance imaging of iatrogeny: understanding imaging artifacts related to medical devices. *Abdom Imaging* 2014; 39:411–423
21. Buckwalter KA, Lin C, Ford JM. Managing postoperative artifacts on computed tomography and magnetic resonance imaging. *Semin Musculoskelet Radiol* 2011; 15:309–319
22. Lee MH, Lubner MG, Mellnick VM, Menias CO, Bhalla S, Pickhardt PJ. The CT scout view: complementary value added to abdominal CT interpretation. *Abdom Radiol* (NY) 2021; 46:5021–5036
23. Barrett JF, Keat N. Artifacts in CT: recognition and avoidance. *RadioGraphics* 2004; 24:1679–1691
24. Morales H. Pitfalls in the imaging interpretation of intracranial hemorrhage. *Semin Ultrasound CT MR* 2018; 39:457–468
25. Angkurawaranon S, Sanorsieng N, Unsrisong K, et al. A comparison of performance between a deep learning model with residents for localization and classification of intracranial hemorrhage. *Sci Rep* 2023; 13:9975
26. Heit JJ, Coelho H, Lima FO, et al. Automated cerebral hemorrhage detection using RAPID. *AJNR* 2021; 42:273–278
27. Kundisch A, Hönning A, Mutze S, et al. Deep learning algorithm in detecting intracranial hemorrhages on emergency computed tomographies. *PLoS One* 2021; 16:e0260560
28. Liu L, Si M, Ma H, et al. A hierarchical opportunistic screening model for osteoporosis using machine learning applied to clinical data and CT images. *BMC Bioinformatics* 2022; 23:63
29. Lange MB, Petersen LJ, Lausen M, Bruun NH, Nielsen MB, Zacho HD. Influence of prior imaging information on diagnostic accuracy for focal skeletal processes: a retrospective analysis of the consistency between biopsy-verified imaging diagnoses. *Diagnostics (Basel)* 2022; 12:1735
30. Mohsen F, Ali H, El Hajj N, Shah Z. Artificial intelligence-based methods for fusion of electronic health records and imaging data. *Sci Rep* 2022; 12:17981
31. Smith MJ. *Error and variation in diagnostic radiology.* C.C. Thomas,
32. Tuddenham WJ. Visual search, image organization, and reader error in roentgen diagnosis: studies of the psycho-physiology of roentgen image perception. *Radiology* 1962; 78:694–704
33. Park E, Branch F, Hegdé J. Satisfaction of search can be ameliorated by perceptual learning: a proof-of-principle study. *Vision (Basel)* 2022; 6:49
34. Berbaum KS, Krupinski EA, Schartz KM, et al. Satisfaction of search in chest radiography 2015. *Acad Radiol* 2015; 22:1457–1465
35. Degnan AJ, Ghobadi EH, Hardy P, et al. Perceptual and interpretive error in diagnostic radiology: causes and potential solutions. *Acad Radiol* 2019; 26:833–845

Downloaded from www.ajronline.org by Chung Shan Medical University on 12/24/25 from IP address 61.218.155.215. Copyright ARRS. For personal use only; all rights reserved

36. Gallée L, Kniesel H, Ropinski T, Götz M. Artificial intelligence in radiology: beyond the black box [in German]. *Röfo* 2023; 195:797–803
37. Votto AM, Valecha R, Najafirad P, Rao HR. Artificial intelligence in tactical human resource management: a systematic literature review. *Int J Inf Manage Data Insights* 2021; 1:100047.
38. Floridi L, Cowls J, Beltrametti M, et al. An ethical framework for a good AI society: opportunities, risks, principles, and recommendations. In: Floridi L, ed. *Ethics, governance, and policies in artificial intelligence*. Springer International Publishing, 2021:19–39
39. Yelne S, Chaudhary M, Dod K, Sayyad A, Sharma R. Harnessing the power of AI: a comprehensive review of its impact and challenges in nursing science and healthcare. *Cureus* 2023; 15:e49252
40. Minkkinen M, Laine J, Mäntymäki M. Continuous auditing of artificial intelligence: a conceptualization and assessment of tools and frameworks. *Digital Soc* 2022; 1:21
41. Kim B, Park J, Suh J. Transparency and accountability in AI decision support: explaining and visualizing convolutional neural networks for text information. *Decis Support Syst* 2020; 134:113302
42. Novelli C, Taddeo M, Floridi L. Accountability in artificial intelligence: what it is and how it works. *AI & Soc* 2023 Feb 7 [published online]
43. Borys K, Schmitt YA, Nauta M, et al. Explainable AI in medical imaging: an overview for clinical practitioners—beyond saliency-based XAI approaches. *Eur J Radio*l 2023; 162:110786
44. Philpotts LE. Can computer-aided detection be detrimental to mammographic interpretation? *Radiology* 2009; 253:17–22
45. Hendrix N, Lowry KP, Elmore JG, et al. Radiologist preferences for artificial intelligence-based decision support during screening mammography interpretation. *J Am Coll Radiol* 2022; 19:1098–1110
46. Moise A, Atkins MS. Workflow oriented hanging protocols for radiology workstation. In: *Medical imaging 2002: PACS and integrated medical information systems: design and evaluation—proceedings of SPIE*, vol. 4685. SPIE, 2002:467006
47. Kitamura G. Hanging protocol optimization of lumbar spine radiographs with machine learning. *Skeletal Radiol* 2021; 50:1809–1819
48. Filice RW, Stein A, Pan I, Shih G. Federated deep learning to more reliably detect body part for hanging protocols, relevant priors, and workflow optimization. *J Digit Imaging* 2022; 35:335–339
49. Cellina M, Cè M, Irmici G, et al. Artificial intelligence in emergency radiology: where are we going? *Diagnostics (Basel)* 2022; 12:3223
50. Boonn WW, Langlotz CP. Radiologist use of and perceived need for patient data access. *J Digit Imaging* 2009; 22:357–362
51. Agatstein K. Chart review is dead; long live chart review: how artificial intelligence will make human review of medical records obsolete, one day. *Popul Health Manag* 2023; 26:438–440
52. Lacson R, Laroya R, Wang A, et al. Integrity of clinical information in computerized order requisitions for diagnostic imaging. *J Am Med Inform Assoc* 2018; 25:1651–1656
53. Okada N, Umemura Y, Shi S, et al. "KAIZEN" method realizing implementation of deep-learning models for COVID-19 CT diagnosis in real world hospitals. *Sci Rep* 2024; 14:1672
54. Brady AP, Allen B, Chong J, et al. Developing, purchasing, implementing and monitoring AI tools in radiology: practical considerations—a multi-society statement from the ACR, CAR, ESR, RANZCR & RSNA. *Insights Imaging* 2024; 15:16
55. Pianykh OS, Langs G, Dewey M, et al. Continuous learning AI in radiology: implementation principles and early applications. *Radiology* 2020; 297:6–14
56. Ruitenbeek HC, Oei EHG, Schmahl BL, Bos EM, Verdonschot RJCG, Visser JJ. Towards clinical implementation of an AI-algorithm for detection of cervical spine fractures on computed tomography. *Eur J Radiol* 2024; 173:111375
57. Recht MP, Dewey M, Dreyer K, et al. Integrating artificial intelligence into the clinical practice of radiology: challenges and recommendations. *Eur Radiol* 2020; 30:3576–3584
58. Kiefer J, Kopp M, Ruettinger T, et al. Diagnostic accuracy and performance analysis of a scanner-integrated artificial intelligence model for the detection of intracranial hemorrhages in a traumatology emergency department. *Bioengineering (Basel)* 2023; 10:1362
59. Motohashi M, Funauchi Y, Adachi T, et al. A new deep learning algorithm for detecting spinal metastases on computed tomography images. *Spine* 2024; 49:390–397
60. Weikert T, Winkel DJ, Bremerich J, et al. Automated detection of pulmonary embolism in CT pulmonary angiograms using an AI-powered algorithm. *Eur Radiol* 2020; 30:6545–6553

(Editorial Comment starts on next page)

Editorial Comment: Navigating the Pitfalls of Interpretative Artificial Intelligence in Radiology—Ensuring Accuracy Through Collaboration and Iteration

Interpretive artificial intelligence (AI) solutions have increasingly been integrated into radiologists' clinical workflows. Indeed, most radiology practices have likely considered investing in AI software solutions in recent years. The potential benefits, such as enhanced diagnostic accuracy and improved institutional workflow efficiency, are well-supported by extensive scientific literature. Nevertheless, various challenges remain that may lead to false-positive and false-negative interpretations by AI tools in clinical practice.

The article by Behzad et al. [1] highlights critical pitfalls of interpretive AI software of which practicing radiologists need to be aware and provides recommendations for developers to mitigate misinterpretations in future models. Major factors potentially limiting the robustness and interpretative accuracy of AI tools include dataset diversity and complexity during model training, as well as the tools' inherent lack of knowledge of medical history, clinical information, and prior examinations. Consequently, challenging anatomy, postoperative findings, image artifacts, medical devices, and other factors that might mimic or obscure pathology can introduce misinterpretations that radiologists need to recognize.

A potential solution is to expose AI tools to complex and multimodal datasets that also contain clinical information. Additionally, consistent iterative feedback loops are essential to refine future versions of these AI models, ensuring their accuracy and reliability in the ever-evolving landscape of medical imaging.

As the authors describe, a desirable future direction for interpretive AI tools would be to provide a holistic and transparent interpretation of the patient's pathology, similar to the assessment by a radiologist. The development and successful implementation of explainable and adaptive interpretive AI frameworks, however, require close collaboration between developers and radiologists and an in-depth understanding of a radiologist's image interpretation process. When these and other perspectives outlined by Behzad et al. [1] are incorporated, the precision of AI frameworks will increase and advance radiology practice.

Jan Vosshenrich, MD
University Hospital Basel
Basel, Switzerland

Address correspondence to *jan.vosshenrich@usb.ch, @Voss_MD*

First published online: Jul 24, 2024 ▪ Version of record: Oct 9, 2024

The author declares that there are no disclosures relevant to the subject matter of this article.

doi.org/10.2214/AJR.24.31793 ▪ *AJR* 2024; 223:e2431793

ISSN-L 0361-803X/24/2234–e2431793 ▪ © American Roentgen Ray Society

Provenance and review: Solicited; not externally peer reviewed.

Reference

1. Behzad S, Tabatabaei SMH, Lu MY, Eibschutz LS, Gholamrezanezhad A. Pitfalls in interpretive applications of artificial intelligence in radiology. *AJR* 2024; 223:e2431493

(Editorial Comment starts on next page)

Downloaded from www.ajronline.org by Chung Shan Medical University on 12/24/25 from IP address 61.218.155.215. Copyright ARRS. For personal use only; all rights reserved

Editorial Comment: Radiologists Must Recognize the Limitations of Current Interpretative Artificial Intelligence Applications

The number of FDA-approved artificial intelligence (AI) applications in health care has shown unstoppable growth. Radiology solutions account for more than 75% of these applications, and this proportion is growing [1]. Interpretative AI models are by far the most common radiology AI application in clinical practice. However, a discrepancy remains between the number of radiology AI applications available and the number of institutions that decide to invest in them. Furthermore, even when these kinds of solutions are available, many radiologists are reluctant to use them [2]. These gaps have multiple explanations, including a lack of seamless workflow integration, the inherent deficits of current AI technology, and limited transparency (i.e., the black box effect).

This Clinical Perspective [3] analyzes various pitfalls in interpretative applications of AI in radiology; such pitfalls hamper these solutions' performance in the clinical arena. Behzad et al. clearly identify and showcase these problems using illustrative case studies. The authors also emphasize the importance of diverse and complex training datasets, explaining how training set limitations may be common reasons interpretative AI solutions fail to reach their desired clinical performance.

Radiologists must recognize these potential pitfalls to avoid erroneously interpreting an imaging examination on the basis of an AI solution's result. As the authors highlight, expanding the explainability of AI software will allow radiologists to better understand how these models were developed and the features on which their results are based. Such explainability provides radiologists with a greater opportunity to identify the explored pitfalls. Radiology departments adopting interpretative AI solutions should also create an active two-way communication with AI vendors. Such communication will help to ensure optimal workflow integration according to specific clinical uses and allow practices to provide vendors with feedback on their tools' limitations, errors, and pitfalls, to hone the tools' later results.

Antonio Luna, MD, PhD
HTmedica
Jaen, Spain

Address correspondence to *aluna70@htmedica.com, @Alunaalcala*

First published online: Aug 7, 2024 ▪ Version of record: Oct 9, 2024

The author declares that there are no disclosures relevant to the subject matter of this article.

doi.org/10.2214/AJR.24.31842 ▪ *AJR* 2024; 223:e2431842

ISSN-L 0361-803X/24/2234–e2431842 ▪ © American Roentgen Ray Society

Provenance and review: Solicited; not externally peer reviewed.

References

1. Joshi G, Jain A, Araveeti SR, Adhikari S, Garg H, Bhandari M. FDA-approved artificial intelligence and machine learning (AI/ML)-enabled medical devices: an updated landscape. *Electronics* 2024; 13:498
2. Allen B, Agarwal S, Coombs L, Wald C, Dreyer K. 2020 ACR Data Science Institute artificial intelligence survey. *J Am Coll Radiol* 2021; 18:1153–1159
3. Behzad S, Tabatabaei SMH, Lu MY, Eibschutz LS, Gholamrezanezhad A. Pitfalls in interpretive applications of artificial intelligence in radiology. *AJR* 2024; 223:e2431493

Downloaded from www.ajronline.org by Chung Shan Medical University on 12/24/25 from IP address 61.218.155.215. Copyright ARRS. For personal use only; all rights reserved