Article published online: 2026-02-27

Robotic-assisted esophageal endoscopic submucosal dissection in a compact and extensive early Barrett's cancer lesion

OPEN ACCESS

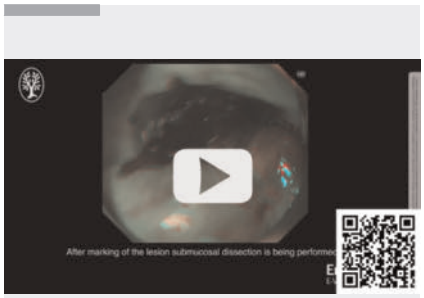

Video 1 Alligator-assisted esophageal endoscopic submucosal dissection in a compact and extensive early Barrett's cancer lesion provides multidirectional tissue movement, enabling the excellent visualization of the dissection plane and robust, flexible, repositionable traction.

Endoscopic submucosal dissection (ESD) of large and compact esophageal lesions is technically demanding, especially in the later stages of the procedure [1, 2]. The partially dissected specimen often becomes floppy and obscures the dissection field. This loss of visualization and traction limitation makes dissection challenging. Conventional traction methods provide only limited axis movements and cannot be easily repositioned [3, 4].

A novel EndoRobotics Alligator (ROBOPERA & TraCloser) device is designed for flexible multipoint traction [5]. The device provides true four-axis independent movements, enabling multidirectional traction. The operator can lift, rotate, pull, or push the lesion in multiple directions and reposition at any time, maintaining continuous exposure of the submucosal layer and preventing the partially dissected specimen from obstructing the field. This multidirectional control improves visualization, optimizes tissue tension and facilitates dissection (▶ **Video 1**).

We report the first case of an EndoRobotics Alligator-assisted esophageal ESD of an 11 cm early Barrett's adenocarcinoma extending over 70 % of the circumference, with a 5 cm compact component (▶ **Fig. 1**). The use of this novel device was authorized by the Institutional Review Board. After circumferential incision and completing dissection of 70 % of the lesion, visualization and access to the dissection plane worsened. The alligator device was used at this later stage of the procedure (▶ **Fig. 2**) to lift the compact specimen in order to revisualize the dissection plane, maintain tension, and finalize the dissection (▶ **Fig. 3** and ▶ **Fig. 4**).

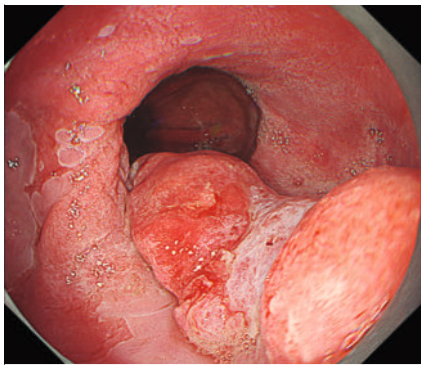

▶ **Fig. 1** An 11 cm Barrett's adenocarcinoma lesion with a 5 cm compact component (0-Is + IIb Paris classification) and signs of deep submucosal invasion.

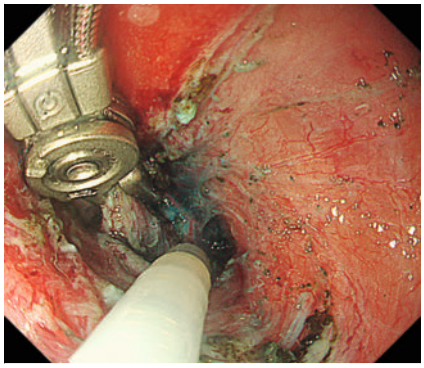

▶ **Fig. 2** The alligator device grasping the partially resected lesion, which is currently obscuring the dissection plane.

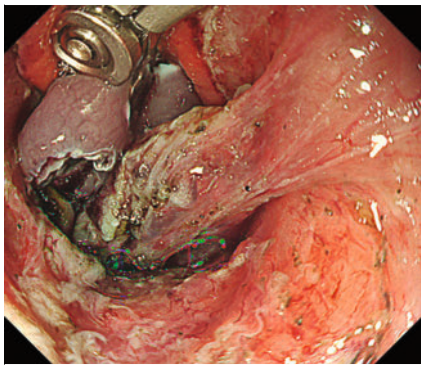

▶ **Fig. 3** After three-axis movements (grip, wrist, and arm movements), the lesion is lifted, the submucosa is exposed, and clear visualization of the submucosal dissection plane with adequate working space is achieved.

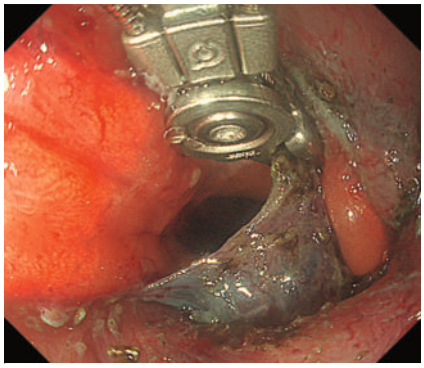

▶ **Fig. 4** Repositioning of the alligator device with the application of the rotational movement (fourth axis movement) enables the visualization of the non-resected submucosal layer and allows safe continuation of the dissection.

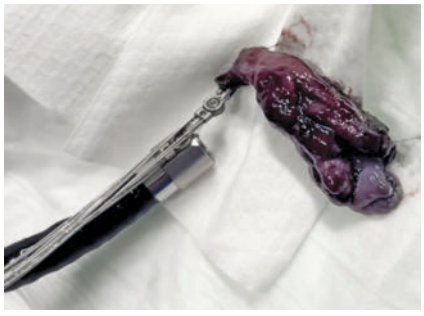

▶ **Fig. 5** Retrieval of the resected specimen using the alligator device.

The lesion was successfully resected en bloc (▶ **Fig. 5**). R0 resection was histologically confirmed, and no intra- or post-procedural adverse events occurred.

Alligator-assisted robotic traction is a valuable tool during esophageal ESD, particularly in challenging cases involving compact lesions. By providing dynamic multidirectional traction, it complements conventional ESD techniques and enhances visualization, stability, and dissection efficiency. This case demonstrates that integrating robotic traction into ESD enables a safer and more controlled tissue handling.

Endoscopy_UCTN_Code_TTT_1AO_2AG_3AD
Endoscopy_UCTN_Code_CCL_1AB_2AC_3AC

Contributors' Statement

Giorgi Tvaradze: Conceptualization, Writing – original draft, Writing – review & editing. Mayo Tanabe: Formal analysis. Kazuki Yamamoto: Formal analysis. Stefan Groth: Validation. Ewerton Marques Maggio: Formal analysis. Haruhiro Inoue: Supervision. Stefan Seewald: Conceptualization, Writing – original draft, Writing – review & editing.

Conflict of Interest

The authors declare that they have no conflict of interest.

The authors

Giorgi Tvaradze[1], Mayo Tanabe[2], Kazuki Yamamoto[2], Stefan Groth[1], Ewerton Marques Maggio[3], Haruhiro Inoue[2], Stefan Seewald[1]

1 Center for Gastroenterology, Klinik Hirslanden, Zürich, Switzerland
2 Digestive Disease Center, Showa Medical University Koto Toyosu Hospital, Tokyo, Japan
3 Medica Medical Laboratories Dr. F. Kaeppeli AG, Zürich, Switzerland

Corresponding author

Stefan Seewald
Center for Gastroenterology, Klinik Hirslanden, Witellikerstraße 40, 8032 Zürich, Switzerland
Stefan.Seewald@gastrozentrum.ch

References

[1] Oyama T, Tomori A, Hotta K et al. Endoscopic submucosal dissection of early esophageal cancer. Endoscopy 2005; 37: 111–114. doi:10.1016/s1542-3565(05)00291-0
[2] Jeon HJ, Keum B, Lee B et al. A novel robotic arm–assisted endoscopic submucosal dissection platform with augmented traction for gastric neoplasms: a first-in-human prospective pilot study (with videos). Gastrointest Endosc 2025. [Online ahead of print] doi:10.1016/j.gie.2025.09.012
[3] Sakamoto T, Matsuda T, Nakajima T et al. Effective traction methods for endoscopic submucosal dissection. Endoscopy 2009; 41: 845–850
[4] Inoue H, Ikeda H, Hosoya T et al. Endoscopic submucosal dissection for esophageal neoplasms. Endoscopy 2001; 33: 687–690
[5] Fujiyoshi Y, Shimamura Y, Mosko JD et al. Endoscopic submucosal dissection using a new super-soft hood and the multipoint traction technique. VideoGIE 2020; 5: 274–277. doi:10.1016/j.vgie.2020.03.010

Bibliography

Endoscopy 2026; : –
DOI 10.1055/a-2802-4223
ISSN 0013-726X
© 2026. The Author(s).
This is an open access article published by Thieme under the terms of the Creative Commons Attribution License, permitting unrestricted use, distribution, and reproduction so long as the original work is properly cited.
(https://creativecommons.org/licenses/by/4.0/)
Georg Thieme Verlag KG, Oswald-Hesse-Str. 50, 70469 Stuttgart, Germany