Surgical Endoscopy
https://doi.org/10.1007/s00464-025-12182-6

DYNAMIC MANUSCRIPT

Dual-function robotic gripper for traction and closure in gastric endoscopic submucosal dissection: an in vivo porcine model study (with video)

Sang Hyun Kim[1] · Ye Chan Seo[2] · Bora Keum[1] · Han Jo Jeon[1] · Jae Min Lee[1] · Hyuk Soon Choi[1] · Eun Sun Kim[1] · Yoon Tae Jeen[1] · Hong Sik Lee[1] · Joo Ha Hwang[3] · Hoon Jai Chun[1]

Received: 23 June 2025 / Accepted: 24 August 2025
© The Author(s), under exclusive licence to Springer Science+Business Media, LLC, part of Springer Nature 2025

Abstract

Objectives Endoscopic submucosal dissection (ESD) is a technically complex procedure associated with prolonged operative duration and a heightened risk of complications. To enhance procedural efficiency and safety, various adjunctive techniques have been introduced, particularly for tissue traction and mucosal defect closure. This study aimed to assess the feasibility and efficacy of a novel robotic dual-function gripper capable of performing both tissue traction and defect approximation in an in vivo model.

Methods A dual-function robotic gripper was developed to facilitate submucosal dissection and post-ESD closure. Comparative experiments were conducted using robot-assisted ESD (RESD) and conventional ESD (CESD) on 24 gastric lesions created in six live pigs. In the RESD group, mucosal defects were closed using the robotic gripper in combination with through-the-scope (TTS) clips, whereas closure in the CESD group was performed using standard TTS clips alone. Primary outcomes included total procedure time, dissection speed, blind dissection rate, and success rate of defect closure. Endoscopic and histological evaluations were conducted on postoperative day 14.

Results All lesions were resected without adverse events. Specimen sizes were comparable between groups (928.1 ± 74.5 mm^2 vs. 937.2 ± 54.8 mm^2, $p = 0.53$). However, the RESD group demonstrated significantly shorter procedure times (10.2 ± 1.7 min vs. 15.8 ± 2.1 min, $p < 0.05$) and faster dissection speeds (157.6 ± 33.3 mm^2/min vs. 91.4 ± 23.7 mm^2/min, $p < 0.05$). Complete defect closure was achieved in all RESD cases, compared to 66.6% in the CESD group. The RESD group also exhibited fewer clip requirements and superior wound healing, as evidenced by narrower zones of epithelial absence and significantly reduced neovascular and fibroblast infiltration.

Conclusion The robotic dual-function gripper significantly enhanced technical performance and mucosal healing in gastric ESD within a porcine model, suggesting its potential as an effective adjunct for gastric therapeutic endoscopy.

Sang Hyun Kim and Ye Chan Seo have contributed equally to the manuscript.

✉ Bora Keum
borakeum@hanmail.net

[1] Division of Gastroenterology and Hepatology, Department of Internal Medicine, Korea University College of Medicine, 73 Goryeodae-Ro, Seongbuk Gu, Seoul 02841, South Korea

[2] Department of Mechanical Engineering, Korea University, Seoul, South Korea

[3] Division of Gastroenterology and Hepatology, Stanford University, Stanford, CA, USA

Published online: 18 September 2025

Graphical abstract

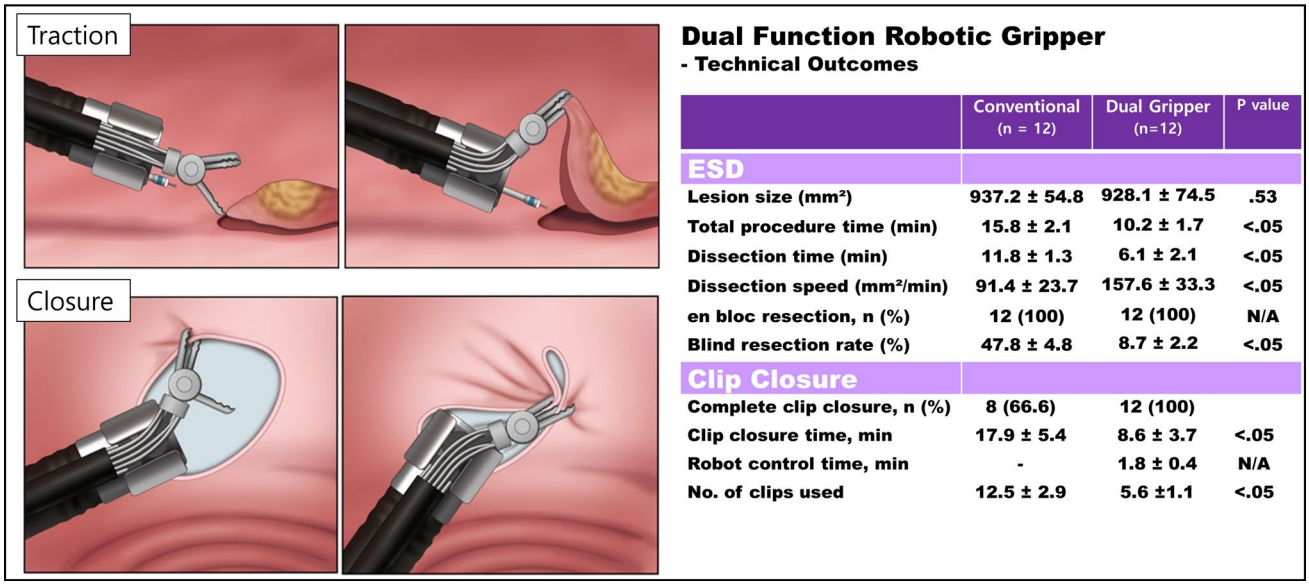

	Conventional (n = 12)	Dual Gripper (n=12)	P value
ESD			
Lesion size (mm²)	937.2 ± 54.8	928.1 ± 74.5	.53
Total procedure time (min)	15.8 ± 2.1	10.2 ± 1.7	<.05
Dissection time (min)	11.8 ± 1.3	6.1 ± 2.1	<.05
Dissection speed (mm²/min)	91.4 ± 23.7	157.6 ± 33.3	<.05
en bloc resection, n (%)	12 (100)	12 (100)	N/A
Blind resection rate (%)	47.8 ± 4.8	8.7 ± 2.2	<.05
Clip Closure			
Complete clip closure, n (%)	8 (66.6)	12 (100)	
Clip closure time, min	17.9 ± 5.4	8.6 ± 3.7	<.05
Robot control time, min	-	1.8 ± 0.4	N/A
No. of clips used	12.5 ± 2.9	5.6 ±1.1	<.05

Keywords ESD · Robot · Traction · Closure

Endoscopic submucosal dissection (ESD) has been increasingly recognized as an effective therapeutic modality for gastrointestinal tumors, owing to its minimally invasive nature and high rates of en bloc resection and curative outcomes in appropriately selected lesions [1]. This technique requires significant technical skill, involves lengthy operation times, and is associated with a high risk of complications, including perforation and bleeding [2]. To address these challenges, numerous ESD tissue traction and defect closure techniques have been developed. Currently, widely used ESD traction methods include the S–O clip, ring thread, multiloop, double clip with rubber band, and clip with line method [3]. Despite their effectiveness, these approaches often lack the flexibility to dynamically adjust the direction of traction as dissection progresses. Robotic-assisted ESD, such as the MASTER system [4], has emerged as a promising approach to overcome these limitations, offering multi-degree-of-freedom instrument control that enables dynamic traction adjustment, improved triangulation, and enhanced visualization of the dissection plane [5]. However, compared with current ESD techniques, such systems require the use of entirely new surgical platforms and necessitate learning new operational methods, which may pose an additional barrier to adoption [6]. Following ESD, mucosal defects expose the deep submucosal layer and, in some cases, the muscularis propria. Recently, increasing evidence suggests that closing these defects can reduce postoperative adverse events, including delayed bleeding and perforation [7, 8]. The need for reliable traction and closure devices is increasingly emphasized to enhance the efficiency and safety of ESD. To address these challenges, we developed the first novel dual-function robotic gripper that attaches to a conventional endoscope, enabling both tissue traction and mucosal defect closure to be performed sequentially within a single platform. Unlike previously reported robotic systems that assist only in submucosal dissection, this system allows dynamic, controllable tissue manipulation followed by immediate defect approximation, eliminating the need for separate closure devices or endoscope reinsertion. In this study, we aimed to evaluate the technical feasibility, procedural efficiency, and wound healing efficacy of this robotic system in comparison with conventional ESD and closure techniques using a live porcine stomach model.

Materials and methods

Dual-function robotic gripper for traction and closure

In collaboration with EndoRobotics (Seoul, Korea), we developed a dual-function robotic gripper system (ROB-OPERA–TraCloser; EndoRobotics, Seoul, Korea) designed to assist with both tissue traction and defect approximation during endoscopic procedures. The system comprises three primary components: a dual-function robotic gripper, controllers, and a driver unit (Fig. 1a). The robotic gripper is compatible with conventional endoscopes and



Fig. 1 Overview of the robotic assistive system. (**a**) The device consists of 3 parts: a dual-function robotic gripper, controllers, and a driver unit. (**b**) Image of dual-function robotic gripper attached to conventional endoscope. The robotic gripper has two side jaws which can be opened and closed independently and a fixed support column jaw in the center

is mounted at the distal tip. It features two independently controlled side jaws and a centrally positioned fixed support column, allowing for precise tissue manipulation and approximation (Fig. 1b). During ESD, the robotic gripper facilitates tissue traction by opening one of its side jaws to grasp and elevates the tissue, thereby exposing the submucosal dissection plane (Fig. 2a). The gripper is capable of 270-degree circumferential rotation around the distal end of the endoscope, and its wrist segment allows vertical movement, enabling fine adjustment of the dissection field (Video 1). For defect closure, the robotic gripper assists in approximating the edges of the mucosal defect. Using one jaw, the edge of the defect is grasped and pulled toward the opposite side to facilitate approximation (Fig. 2b). The opposing edge is then grasped with the other jaw. Once both sides are approximated, closure is easily completed using conventional through-the-scope (TTS) clips.

Experiment protocol

Robot gripper-assisted ESDs (RESD) and conventional ESDs (CESD) were performed at two locations in the in vivo porcine stomach: the greater curvature of the antrum and the greater curvature of the mid-gastric body, using a total of six pigs. Each technique was applied once at the same location within each animal to enable paired comparisons. In the RESD group, post-ESD mucosal defect closure was achieved using TTS clips (ROCC-F-26–235-C; Micro-Tech Co., Ltd., Nanjing, China) in conjunction with the robotic gripper. In the CESD group, the same TTS clips were employed using the conventional zipper closure technique [9]. Prior to performing robotic-assisted ESD, the operator received a brief 10-min explanation and hands-on tutorial on handling the robotic gripper system, including its control interface and basic articulation maneuvers. Follow-up endoscopy was conducted on postoperative day (POD) 14 to evaluate wound healing, after which all animals were euthanized and the stomachs were harvested. Tissue specimens from both RESD and CESD groups were collected for histological analysis. This study was approved by the Institutional Animal Care and Use Committee (IACUC) of the College of Medicine, Korea University (Approval No. KOREA-2022–0136).

Endoscopic submucosal dissection

All procedures were conducted by an experienced endoscopist who had performed > 500 ESD procedures. In each stomach, four simulated gastric lesions were created. Using a dual knife (KD-650L; Olympus, Tokyo, Japan), we marked artificial lesions approximately 35 mm in diameter. One lesion at each site underwent ESD using the conventional method, while the other was treated using the robotic gripper. CESD and RESD were performed as follows: a transparent cap (FM-EC0002; Finemedix, Seoul, Korea) or robotic gripper was attached to the distal end of a standard endoscope (GIF-HQ290; Olympus, Tokyo, Japan) and advanced to the target lesion. In the conventional group, submucosal dissection was performed in the usual manner. In the robotic group, conventional submucosal dissection was performed until the mucosa had sufficient space for grasping. At this stage, the robotic gripper approached the lesion and the dissected mucosal flap was grasped by the gripper. The mucosal flap was then lifted by the gripper and the submucosal plane was exposed (Fig. 2a). The endoscopist manipulated the robotic arm using a controller attached to the endoscope. The endoscopist completed the submucosal dissection using the robotic gripper. The resected mucosa was retrieved by the robotic gripper or by suction into a cap in the conventional group. The following parameters were recorded for all ESD procedures: location, total procedure

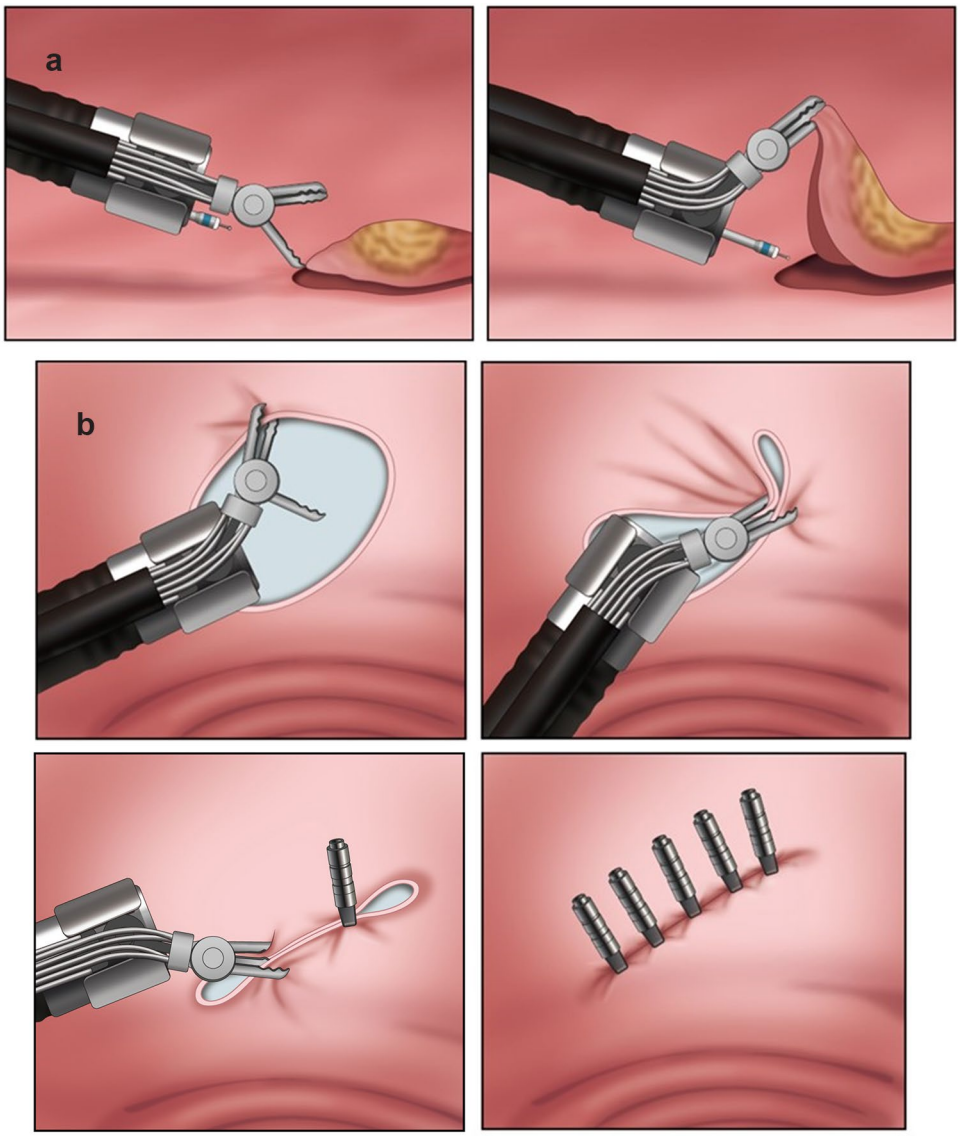

Fig. 2 Schematic illustration of robotic gripper-assisted ESD and defect closure. (**a**) Schema of ESD using the robotic gripper. One jaw of the gripper is opened to grasp and lift the tissue, thereby exposing the submucosal dissection plane. (**b**) Schema of ESD defect closure using the robotic gripper. One jaw grasps the edge of the mucosal defect and pulls it toward the opposite side to facilitate tissue approximation. The other jaw then grasps the opposite edge. Once approximated, the defect is closed using conventional TTS clips. ESD, endoscopic submucosal dissection. TTS, through the scope

time, size of the resected tissue, complete resection, blind dissection time, and adverse events.

Endoscopic defect closure

The conventional and robotic groups each underwent defect closure immediately after completing ESD. In the conventional group, defect closure was performed using the zipper closure method with TTS clips. The defect was closed as much as technically possible until no visible defect remained. In the robotic group, the dual-function robotic gripper was employed to grasp both edges of the mucosal defect, as previously described. Upon achieving tissue approximation, a TTS clip was deployed (Fig. 2b and Video 1). Additional tissue approximation and clip placement were then performed using the robotic gripper, according to the endoscopist's discretion (Fig. 2b). Complete defect closure was defined as closure of the mucosal defect without substantial visible submucosal areas (< 5 mm) in the closure line [10]. The following parameters were recorded for all clip closure procedures: total procedure time, robotic control time, number of clips used, and whether complete closure was achieved.

Evaluation of outcomes

We conducted a comparative analysis of the conventional and robotic groups from a technical perspective, evaluating both the ESD procedure and subsequent defect closure. The parameters analyzed included area of the resected specimen, ESD procedure time, dissection speed, blind dissection rate, closure time, complete closure success rate, number of clips used, and the occurrence of adverse events. The area of the resected specimen was calculated using the formula

for an ellipse, based on the longest and shortest diameters of the specimen measured immediately after resection: Area = π × (long axis/2) × (short axis/2). Total procedure time was defined as the time from the initiation of submucosal injection to the completion of defect closure. Blind dissection rate was defined as the proportion of dissection time during which the submucosal layer was not clearly visualized due to inadequate traction or suboptimal visualization angle, expressed as a percentage of total dissection time. Blind dissection time for each procedure was determined by reviewing recorded endoscopic videos. Two experienced endoscopists, who were not involved in the procedures, independently recorded the timing, and any discrepancies were resolved through consensus. Adverse events were defined as any intraoperative or postoperative complications, including bleeding, perforation, or tissue damage. Intraoperative events were monitored endoscopically in real time during the procedure, while postoperative events were evaluated through follow-up endoscopy and clinical observation up to postoperative day 14. Postoperative wound healing was evaluated using two previously described methods by Akimoto et al. [11]. Only cases in which complete closure was successfully achieved were included in the wound healing analysis. For endoscopic evaluation, the primary outcome was the healing status of mucosal defects on POD 14, with dehiscence assessed endoscopically. For histological and immunohistochemical evaluation, resected defect closure specimens from both groups were analyzed. Tissues were fixed in 10% neutral-buffered formalin, embedded in paraffin, sectioned at 4μm, and stained with hematoxylin and eosin (H&E) and anti-αSMA antibody. The width of absent epithelium between mucosal rims in H&E-stained sections was measured and compared between the robotic and conventional complete closure groups. Neovascular and fibroblast areas were quantified as αSMA-positive regions in the submucosa beneath the lesion site. For each section, three randomly selected fields (×400 magnification) in the middle submucosal layer were analyzed using ImageJ software. As a reference, samples of normal gastric tissue from non-lesion sites were also obtained from each pig on POD 14 [11].

Statistical analysis

All statistical analyses were performed using R software (version 3.5.0; R Foundation for Statistical Computing, Vienna, Austria). Data are expressed as mean ± standard deviation for continuous variables and as counts and percentages for categorical variables. The normality of continuous variables was assessed using the Shapiro–Wilk test. For paired comparisons of continuous variables, the paired *t* test was used for normally distributed data, and the Wilcoxon signed-rank test was used for non-normally distributed data. Paired binary outcomes, such as en bloc resection rate and complete defect closure rate, were analyzed using McNemar's test. Statistical significance was set at $P < 0.05$.

Results

Technical outcomes of RESD vs. CESD

Overall, 24 target lesions were created in the greater curvature in the antrum and greater curvature in the middle gastric body, in a total of six pigs. ESD was successfully performed using either robot-assisted ($n = 12$) or a conventional method ($n = 12$). Complete resection was achieved in all procedures without any adverse events. Table 1 summarizes the outcomes of RESD compared to those of CESD. No significant difference was noted in the specimen size (928.1 ± 74.5 mm^2 vs 937.2 ± 54.8 mm^2, $p = 0.53$). Total procedure times were significantly lower in the RESD group compared to those in the CESD group (10.2 ± 1.7 min vs 15.8 ± 2.1 min, $p < 0.05$) (Table 1). The submucosal dissection speed was significantly higher in the RESD than in the CESD group (157.6 ± 33.3 mm^2/min vs 91.4 ± 23.7 mm^2/min, $p < 0.05$).

Technical outcomes of robot-assisted defect closure vs. conventional defect closure

In the conventional group, 12 ESD defect closures were performed using the zipper closure method with TTS clips following CESD (Fig. 3a). Complete closure was achieved in

Table 1 Comparison of technical outcomes in in vivo ESD experiments: robotic dual gripper vs. conventional method

	Robot assisted ($n = 12$)	Conventional ($n = 12$)	p-value
ESD			
Lesion size (mm^2)	928.1 ± 74.5	937.2 ± 54.8	0.53
Total procedure time (min)	10.2 ± 1.7	15.8 ± 2.1	< 0.05
Dissection time (min)	6.1 ± 2.1	11.8 ± 1.3	< 0.05
Dissection speed (mm^2/min)	157.6 ± 33.3	91.4 ± 23.7	< 0.05
Robot control time (min)	2.7 ± 0.4	-	N/A
En bloc resection, n (%)	12 (100)	12 (100)	N/A
Blind resection rate (%)	8.7 ± 2.2	47.8 ± 4.8	< 0.05
Adverse events	0	0	N/A
Clip closure			
Complete clip closure, n (%)	12 (100)	8 (66.6)	< 0.05
Clip closure time, min	8.6 ± 3.7	17.9 ± 5.4	< 0.05
No. of clips used	5.6 ± 1.1	12.5 ± 2.9	< 0.05
Adverse events	0	0	N/A

ESD, endoscopic submucosal dissection

Values are means ± standard deviation

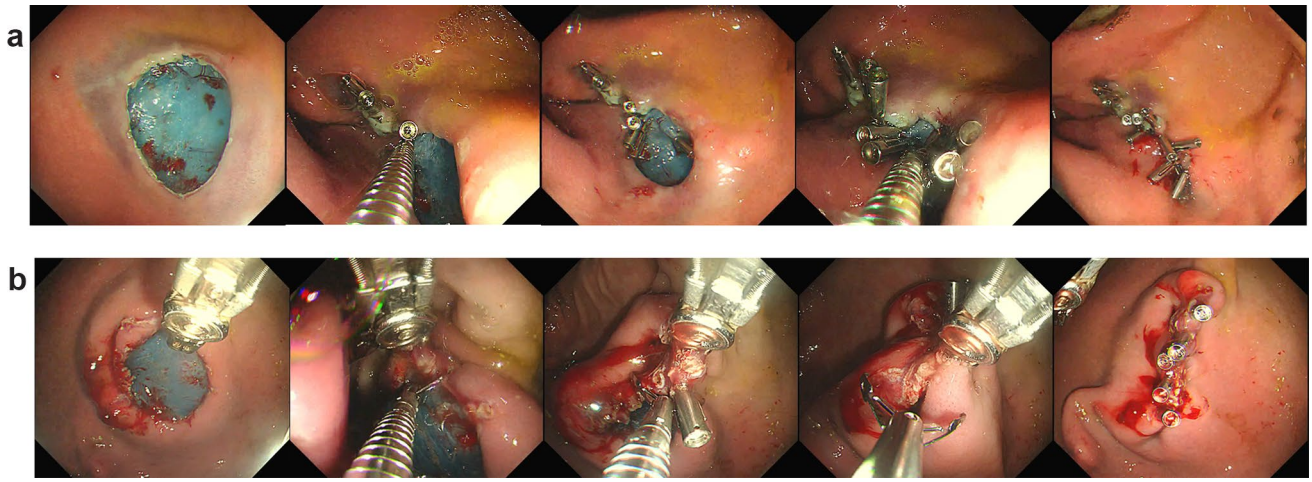

Fig. 3 Representative images of ESD defect closure in a porcine stomach. (**a**) Defect closure in the conventional group using the zipper technique with TTS clips. (**b**) Defect closure in the robotic group using a robotic gripper to approximate the defect edges, followed by closure with TTS clips. *ESD*, endoscopic submucosal dissection. *TTS*, through the scope

8 cases (66.6%) (Table 1). In the remaining 4 cases, defects remained visible despite continued clip application; three in the greater curvature of the antrum and one in the greater curvature of the mid-gastric body. In contrast, the robotic group achieved complete closure in all 12 cases using TTS clips (Fig. 3b). Closure time was significantly shorter in the robotic group compared to the conventional group (8.6 ± 3.7 min vs. 17.9 ± 5.4 min, $p < 0.05$), and the number of clips required was significantly lower (5.6 ± 1.1 vs. 12.5 ± 2.9, $p < 0.05$) (Table 1).

Endoscopic outcomes

On POD 14, follow-up endoscopy was performed in each pig for endoscopic evaluation of lesions that had initially achieved complete closure. In the conventional closure group ($n = 8$), wound dehiscence was observed in 6 cases, presenting as ulcer-like defects (Fig. 4a), while only 2 cases remained fully closed. In contrast, in the robotic group ($n = 12$), 10 cases maintained complete closure without dehiscence, and only 2 cases showed small, focal dehiscence (Fig. 4a).

Histological and immunohistological outcomes

We conducted a histological analysis of the epithelial regeneration in ESD defects from the robotic and conventional closure groups. In the robotic group, most mucosal defects were fully covered with regenerated epithelium (Fig. 4b). In contrast, the conventional group showed relatively larger areas of epithelial absence. The mean width of absent epithelium was significantly shorter in the robotic group compared to the conventional group (1.4 ± 0.8 mm vs. 5.4 ± 2.1 mm, $p < 0.05$) (Fig. 5a). Immunohistochemical analysis of neovascular and fibroblast areas is presented in Fig. 5b. The mean αSMA-positive area in the robotic group was significantly smaller than that observed in the conventional group (11,210 ± 4850 μm^2 vs. 19,610 ± 4530 μm^2, $p < 0.05$), suggesting a more favorable wound healing response in the robotic group.

Discussion

The primary benefit of ESD is its ability to achieve en bloc resection of large or complex gastrointestinal lesions, including early-stage cancers, with minimal invasiveness [12]. Traction in ESD improves the efficiency and safety of the procedure, leading to better outcomes and more complete resections. Closure of the ESD defect is another critical element in the ESD procedure, essential for preventing delayed bleeding, perforation, or post-ESD electrocoagulation syndrome. Recent studies have shown that closing large ESD defects protects exposed tissue, reducing the risk of post-procedure complications such as bleeding and perforation [13]. It also promotes faster healing and minimizes the risk of delayed perforation [14].

Our robotic dual-function gripper was developed to address two critical needs in ESD procedures: providing effective tissue traction and facilitating reliable defect closure. Previous studies, including those conducted by our team, have shown that robotic traction devices can significantly enhance the speed and safety of ESD procedures [15, 16]. Our study builds upon this foundation by introducing and validating a novel dual-function robotic gripper that uniquely integrates real-time traction with defect closure

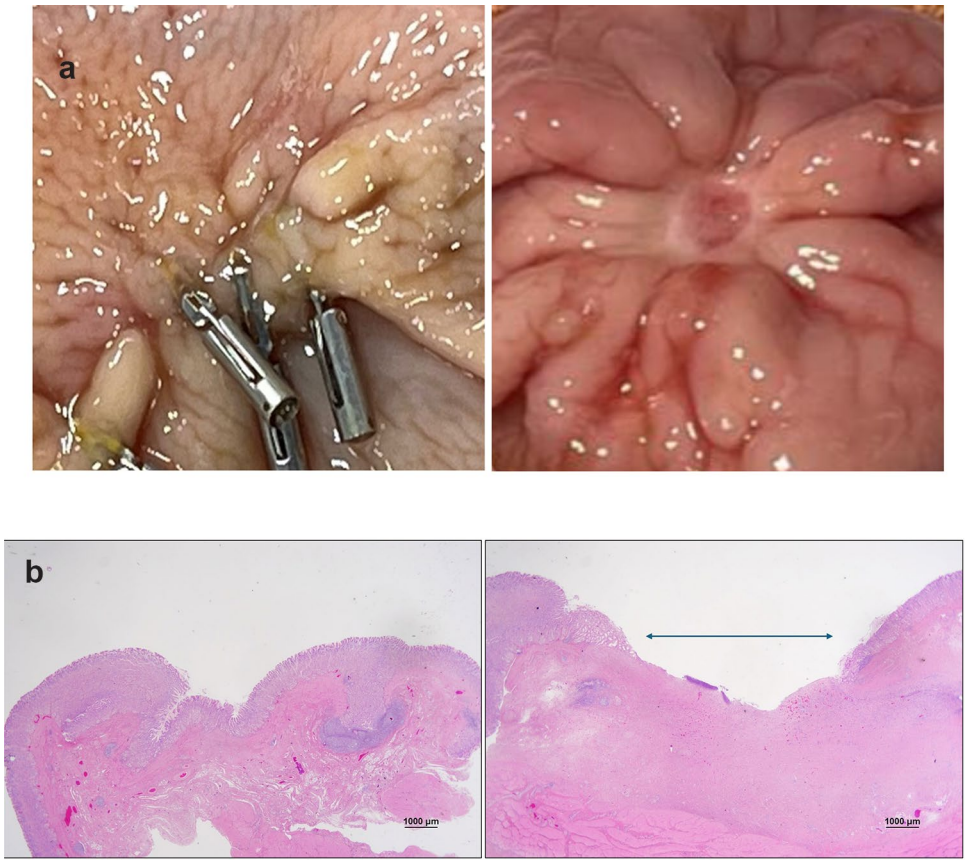

Fig. 4 Evaluation of postoperative wound healing comparing closure methods. (**a**) Gross images of ESD wounds on POD 14. Left: Completely healed wound in the robotic closure group, with residual clips still in place. Right: Wound in the conventional closure group, exhibiting dehiscence with all clips detached. (**b**) Histological evaluation of hematoxylin and eosin stained sections on POD 14. Left: The surface of the mucosal defect in the robotic closure group is fully covered with regenerated epithelium. Right: An area of absent epithelium between the edges of the mucosal defect is observed in the conventional closure group (indicated by an arrow). *ESD*, endoscopic submucosal dissection. *POD*, postoperative day

capability. This integration enhances procedural efficiency and continuity while reducing the need for multiple accessory exchanges or complex closure setups. In the present study, the use of our robotic gripper resulted in reduced procedure times, increased dissection speed, and a lower rate of blind dissection compared to conventional techniques. We also assessed its performance in closing large mucosal defects. While endoscopic closure is most commonly performed using TTS clips, the limited span of TTS clips often makes complete closure difficult for large or irregular defects. To overcome these challenges, various assistive devices have been developed. The instruments for defect closure during flexible endoscopy include endoscopic purse-string sutures using an endoloop [17], over-the-scope clips [18], and advanced suturing devices such as X-Tack (Apollo Endosurgery, Austin, Tex, USA) [19] and OverStitch Sx (Apollo Endosurgery) [20]. Although these methods have shown relatively high complete closure rates, they are technically demanding, require substantial experience, and are not widely accessible in many regions where ESD is performed. In our study, all 12 large gastric ESD defects were successfully closed using a robotic gripper in combination with TTS clips. The robotic gripper led to shorter closure times, fewer clips used, and a higher success rate compared to the conventional method. Additionally, closure with the robotic system provided a more secure closure. Endoscopic evaluation on POD 14 revealed minimal wound dehiscence in the RESD group, whereas dehiscence was frequently observed in the conventional closure group. Histological analysis also revealed reduced neovascularization and fibroblast presence in the submucosa of the robotic group, closely resembling results seen with hand-sutured closures [11]. These results are likely due to the robotic gripper's ability to minimize the submucosal dead space (SDS). Closure of a large wound by simple clipping usually results in closing only the mucosal layer, creating a SDS under the mucosa, which could be unreliable [21]. With our robotic gripper, one side jaw is used to clamp one side of the wound, while the other clamps the opposite side. This method aligns the tissue precisely around the central support column, effectively minimizing SDS. A strong and stable closure can then be achieved by applying TTS clips over the approximated tissue. Similar efforts to approximate large defects and enhance closure strength have led to the development of devices, such as the Dual-Action Tissue (DAT) clip (Micro-Tech Endoscopy, Ann Arbor, MI, USA)[22], Twin Grasper (Ovesco, Tubingen, Germany) [23], and the MANTIS Closure Device (Boston Scientific, MA, USA) [24]. Twin Grasper and DAT clip, due to their inability to rotate, can be limited in effectively grasping the mucosal

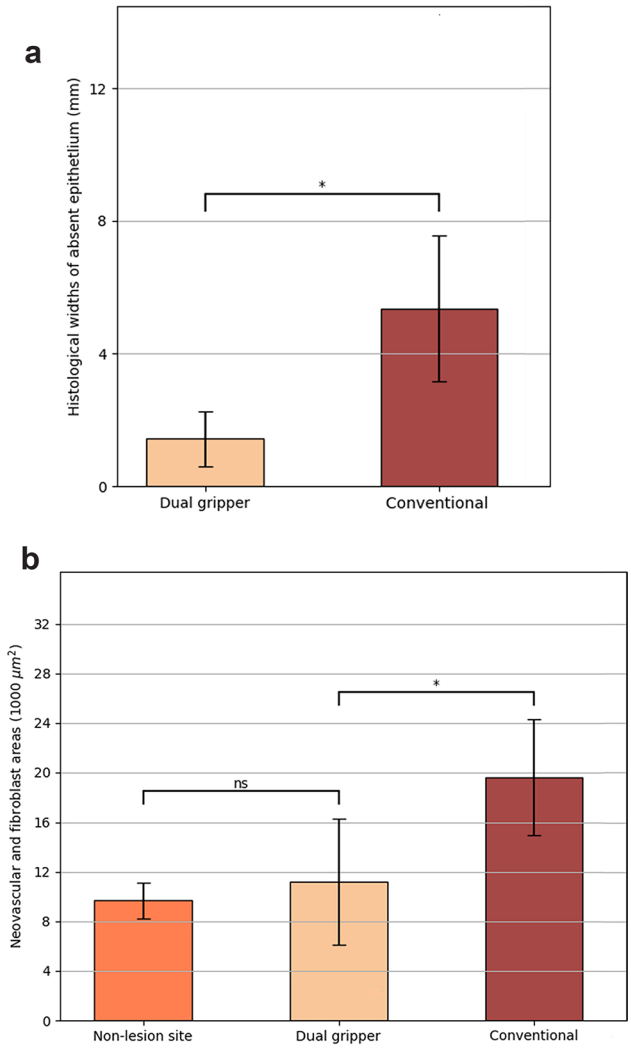

Fig. 5 Histological comparison of wound healing between the robotic and conventional closure groups. (**a**) Comparison of the width of absent epithelium between the robotic dual gripper group and the conventional closure group. The mean width of absent epithelium was significantly shorter in the robotic group compared to the conventional group. (**b**) Comparison of mean neovascular and fibroblast areas between the robotic and conventional closure groups. The robotic group showed significantly lower neovascular and fibroblast areas compared to the conventional group. These values in the robotic group were comparable to those observed at non-lesion sites, suggesting stabilized tissue remodeling. $*p < 0.05$. ns, not significant

edge, particularly in unstable or hard-to-reach positions. Our robotic gripper can move left and right and perform a circumferential roll at the end of the endoscope, enabling optimal closure. Our device is equipped with robotic technology that provides a strong grasping force, ensuring that the tissue is securely held without slipping. This study represents the first in vivo ESD experiment to employ a single robotic platform capable of performing both traction and closure in a sequential manner, allowing for continuous workflow without the need for device exchange.

This study has several limitations. First, it was a single-center pilot study conducted in an in vivo porcine model with a small sample size and a limited number of lesion sites. All procedures were performed at the greater curvature of the antrum and mid-gastric body, which are relatively favorable locations for ESD. Second, all procedures were performed by a single expert endoscopist who was already familiar with similar robotic systems, limiting our ability to assess the reproducibility and usability of the device in the hands of less experienced operators. Although our findings demonstrated technical feasibility and enhanced performance with robotic assistance, they may not fully reflect the learning curve or procedural challenges that novice users might face.

Future studies should evaluate the applicability of this robotic system in anatomically more challenging sites and also assess its usability among less experienced endoscopists to confirm its broader clinical utility and generalizability. Although the success rate of the conventional closure method in this study was relatively low at 66%, this may overestimate the true failure rate, given the substantially greater thickness of the porcine stomach compared to that of humans. This anatomical difference may impact closure performance in clinical practice and should be evaluated in human trials. In this study, conventional clipping was applied to a large defect measuring approximately 3.5 cm. It is well recognized that clipping large mucosal defects (> 3 cm) with standard methods is technically difficult. Therefore, direct comparisons with other advanced closure techniques such as modified double-layered suturing [25], DAT clips, or the MANTIS closure device may be warranted.

In conclusion, this study demonstrates that the robotic dual gripper is a feasible and safe tool for tissue traction and the closure of large gastric defects during ESD in a porcine model. Its use was associated with reduced procedure time and improved procedural outcomes. While further clinical studies in humans are warranted, the robotic dual gripper shows promise as a future solution for facilitating advanced gastric endoscopic procedures.

Supplementary Information The online version contains supplementary material available at https://doi.org/10.1007/s00464-025-12182-6.

Acknowledgements ENDOROBOTICS collaborated in the development of the robotic gripper used in this study by providing technical support during device prototyping and refinement.

Funding This research was supported by a grant of the Korea Health Technology R and D Project through the Korea Health Industry Development Institute (KHIDI), funded by the Ministry of Health and Welfare, Republic of Korea (Grant number: HI22C0935). This work was supported by the Technology development Program (RS-2023-00321839) funded by the Ministry of SMEs and Startups (MSS, Korea) and by the Korea Medical Device Development Fund grant funded by the Korea government (the Ministry of Science and ICT) (RS-2023-00228946).

Disclosures

Conflict of interest Hyuk Soon Choi, Bora Keum, and Hoon Jai Chun hold stocks for ENDOROBOTICS. Joo Ha Hwang is a consultant for Olympus, Medtronic, Boston Scientific, Micro-Tech, Fujifilm, ERBE, LumenDi, Neptune, Noah, and ENDOROBOTICS. Sang Hyun Kim, Ye Chan Seo, Han Jo Jeon, Jae Min Lee, Eun Sun Kim, Yoon Tae Jeen, and Hong Sik Lee have no conflicts of interest or financial ties to disclose.

References

1. Libanio D, Pimentel-Nunes P, Bastiaansen B, Bisschops R, Bourke MJ, Deprez PH, Esposito G, Lemmers A, Leclercq P, Maselli R, Messmann H, Pech O, Pioche M, Vieth M, Weusten B, Fuccio L, Bhandari P, Dinis-Ribeiro M (2023) Endoscopic submucosal dissection techniques and technology: European Society of Gastrointestinal Endoscopy (ESGE) technical review. Endoscopy 55:361–389
2. Kotzev AI, Yang D, Draganov PV (2019) How to master endoscopic submucosal dissection in the USA. Dig Endosc 31:94–100
3. Nagata M (2022) Optimal traction direction in traction-assisted gastric endoscopic submucosal dissection. World J Gastrointest Endosc 14:667–671
4. Chiu PWY, Yip HC, Chu S, Chan SM, Lau HSL, Tang RSY, Phee SJ, Ho KY, Ng SSM (2025) Prospective single-arm trial on feasibility and safety of an endoscopic robotic system for colonic endoscopic submucosal dissection. Endoscopy 57:240–246
5. Kaan HL, Ho KY (2020) Robot-assisted endoscopic resection: current status and future directions. Gut Liver 14:150–152
6. Cui Y, Thompson CC, Chiu PWY, Gross SA (2022) Robotics in therapeutic endoscopy (with video). Gastrointest Endosc 96:402–410
7. Zhang QS, Han B, Xu JH, Gao P, Shen YC (2015) Clip closure of defect after endoscopic resection in patients with larger colorectal tumors decreased the adverse events. Gastrointest Endosc 82:904–909
8. Kobara H, Tada N, Fujihara S, Nishiyama N, Masaki T (2023) Clinical and technical outcomes of endoscopic closure of postendoscopic submucosal dissection defects: literature review over one decade. Dig Endosc 35:216–231
9. Takeuchi Y, Shigita K, Asayama N, Aoyama T, Fukumoto A, Mukai S, Nagata S (2023) Clinical usefulness of the hold-and-drag closure using the SB clip for large mucosal defects after colorectal endoscopic submucosal dissection. Surg Endosc 37:5719–5725
10. Farha J, Ramberan H, Aihara H, Zhang LY, Mehta A, Hage C, Schlachterman A, Kumar A, Shinn B, Canakis A, Kim RE, D'Souza LS, Buscaglia JM, Storm AC, Samarasena J, Chang K, Friedland S, Draganov PV, Qumseya BJ, Jawaid S, Othman MO, Hasan MK, Yang D, Khashab MA, Ngamruengphong S, group ES-Cw (2023) A novel through-the-scope helix tack-and-suture device for mucosal defect closure following colorectal endoscopic submucosal dissection: a multicenter study. Endoscopy 55:571–577
11. Akimoto T, Goto O, Sasaki M, Mizutani M, Tsutsumi K, Kiguchi Y, Nakayama A, Kato M, Fujimoto A, Ochiai Y, Maehata T, Kaise M, Iwakiri K, Yahagi N (2020) Endoscopic suturing promotes healing of mucosal defects after gastric endoscopic submucosal dissection: endoscopic and histologic analyses in in vivo porcine models (with video). Gastrointest Endosc 91:1172–1182
12. Ono H, Kondo H, Gotoda T, Shirao K, Yamaguchi H, Saito D, Hosokawa K, Shimoda T, Yoshida S (2001) Endoscopic mucosal resection for treatment of early gastric cancer. Gut 48:225–229
13. Jiang W, Cen L, Dong C, Zhu S, Shen Z, Li D (2022) Prophylactic clipping to prevent delayed bleeding and perforation after endoscopic submucosal dissection and endoscopic mucosal resection: a systematic review and meta-analysis. J Clin Gastroenterol 56:643–653
14. Ali O, Canakis A, Huang Y, Patel H, Alizadeh M, Kim RE (2023) Closure of mucosal defects using endoscopic suturing following endoscopic submucosal dissection: a single-center experience. Tech Innov Gastrointest Endosc 25:46–51
15. Kim SH, Kim BG, Choi HS, Hong D, Jang SH, Hong K, Choi JW, Kim SH, Lee JM, Kim ES, Keum B, Jeen YT, Lee HS, Chun HJ (2021) Endoscopic submucosal dissection using a detachable assistant robot: a comparative in vivo feasibility study (with video). Surg Endosc 35:5836–5841
16. Kim SH, Kim C, Keum B, Im J, Won S, Kim BG, Kim K, Kwon T, Hong D, Jeon HJ, Choi HS, Kim ES, Jeen YT, Chun HJ, Hwang JH (2024) A novel retractable robotic device for colorectal endoscopic submucosal dissection. Gut Liver 18:677–685
17. Ego M, Abe S, Nonaka S, Suzuki H, Yoshinaga S, Oda I, Saito Y (2021) Endoscopic closure utilizing endoloop and endoclips after gastric endoscopic submucosal dissection for patients on antithrombotic therapy. Dig Dis Sci 66:2336–2344
18. Nishiyama N, Mori H, Kobara H, Rafiq K, Fujihara S, Kobayashi M, Oryu M, Masaki T (2013) Efficacy and safety of over-the-scope clip: including complications after endoscopic submucosal dissection. World J Gastroenterol 19:2752–2760
19. Agnihotri A, Mitsuhashi S, Holmes I, Kamal F, Chiang A, Loren DE, Kowalski TE, Schlachterman A, Kumar AR (2024) Randomized trial of gastric and colorectal endoscopic submucosal dissection defect closure comparing a novel through-the-scope suturing system with an over-the-scope suturing system (with video). Gastrointest Endosc 99(237–244):e231
20. Keihanian T, Zabad N, Khalaf M, Abdel-Jaber W, Kim YI, Jawaid SA, Abidi WM, Marginean EC, Othman MO (2023) Safety and efficacy of a novel suturing device for closure of large defects after endoscopic submucosal dissection (with video). Gastrointest Endosc 98:381–391
21. Motomura D, Toyonaga T, Takayama H, Kodama Y (2024) Endoscopic double-layered suturing: an updated technique for clip closure of large mucosal defects after endoscopic submucosal dissection. VideoGIE 9:95–98
22. Mohammed A, Gonzaga ER, Hasan MK, Saeed A, Friedland S, Bilal M, Sharma N, Jawaid S, Othman M, Khalaf MA, Hwang JH, Viana A, Singh S, Hayat M, Cosgrove ND, Jain D, Arain MA, Kadkhodayan KS, Yang D (2024) Low delayed bleeding and high complete closure rate of mucosal defects with the novel through-the-scope dual-action tissue clip after endoscopic resection of large nonpedunculated colorectal lesions (with video). Gastrointest Endosc 99(83–90):e81
23. Cai Q, Fu H, Zhang L, Shen M, Yi S, Xie R, Lan W, Dong W, Chen X, Zhang J, Hou X, He Y, Yang D (2023) Twin-grasper assisted mucosal inverted closure achieves complete healing of large perforations after gastric endoscopic full-thickness resection. Dig Endosc 35:736–744
24. Yoshida N, Hirose R, Dohi O, Inagaki Y, Murakami T, Inada Y, Morimoto Y, Kobayashi R, Inoue K, Ghoneem E, Itoh Y (2025) A novel reopenable clip with sharp claw for complete closure of mucosal defects after colorectal endoscopic submucosal dissection. Endoscopy 57:354–360
25. Masunaga T, Kato M, Sasaki M, Iwata K, Miyazaki K, Kubosawa Y, Mizutani M, Takatori Y, Matsuura N, Nakayama A, Takabayashi K, Yahagi N (2023) Modified double-layered suturing for a mucosal defect after colorectal endoscopic submucosal

dissection (origami method) (with video). Gastrointest Endosc 97:962–969

Publisher's Note Springer Nature remains neutral with regard to jurisdictional claims in published maps and institutional affiliations.

Springer Nature or its licensor (e.g. a society or other partner) holds exclusive rights to this article under a publishing agreement with the author(s) or other rightsholder(s); author self-archiving of the accepted manuscript version of this article is solely governed by the terms of such publishing agreement and applicable law.