Probing the tumour microenvironment with non-invasive MRI techniques

Department of Physics & Astronomy, UBC

Departmental Defence

Supervisory Committee

Dr. Stefan Reinsberg (Supervisor)
Dr. Corree Laule
Dr. Andrew Minchinton
Dr. Piotr Kozlowski

July 29, 2019

Firas Moosvi

I. Introduction

Implications of abnormal tumour vasculature

Normal blood vessels

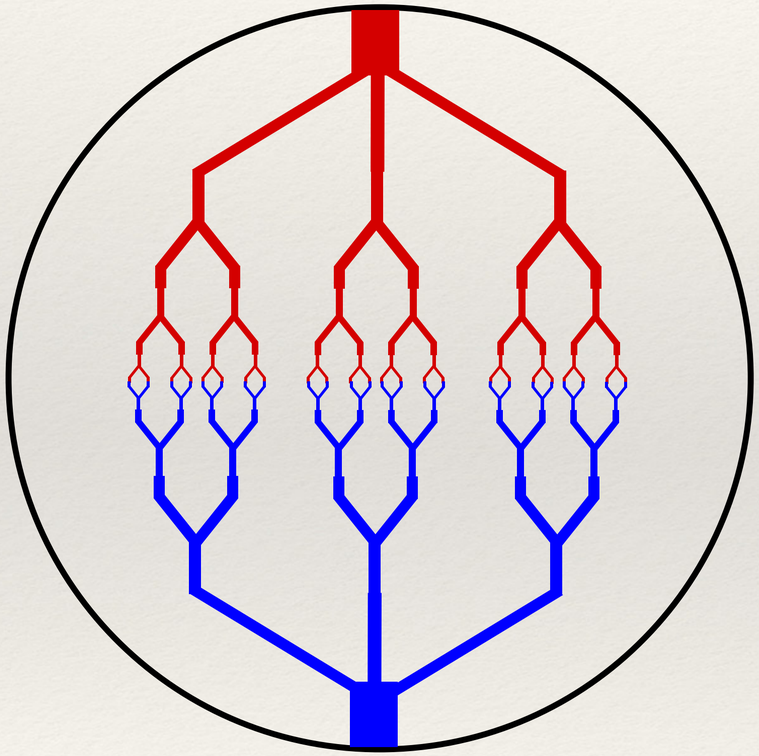

Implications of abnormal tumour vasculature

Normal blood vessels

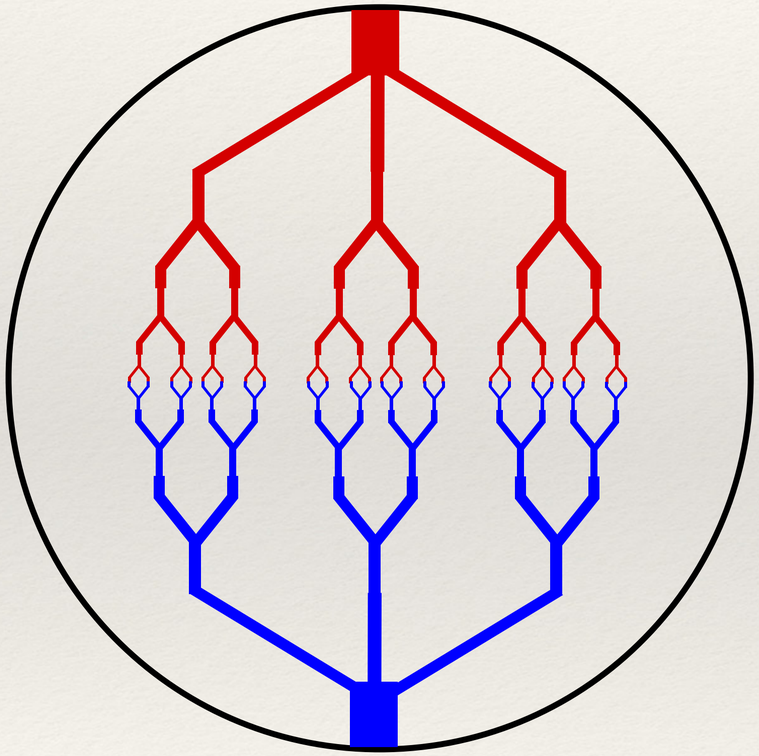

Tumour vessels

- Hypoxic and acidic environments significantly affect treatment and progression of cancer
- Abnormal perfusion patterns in the tumour limits delivery of drugs to target regions
- This necessitates higher doses that increases toxicity

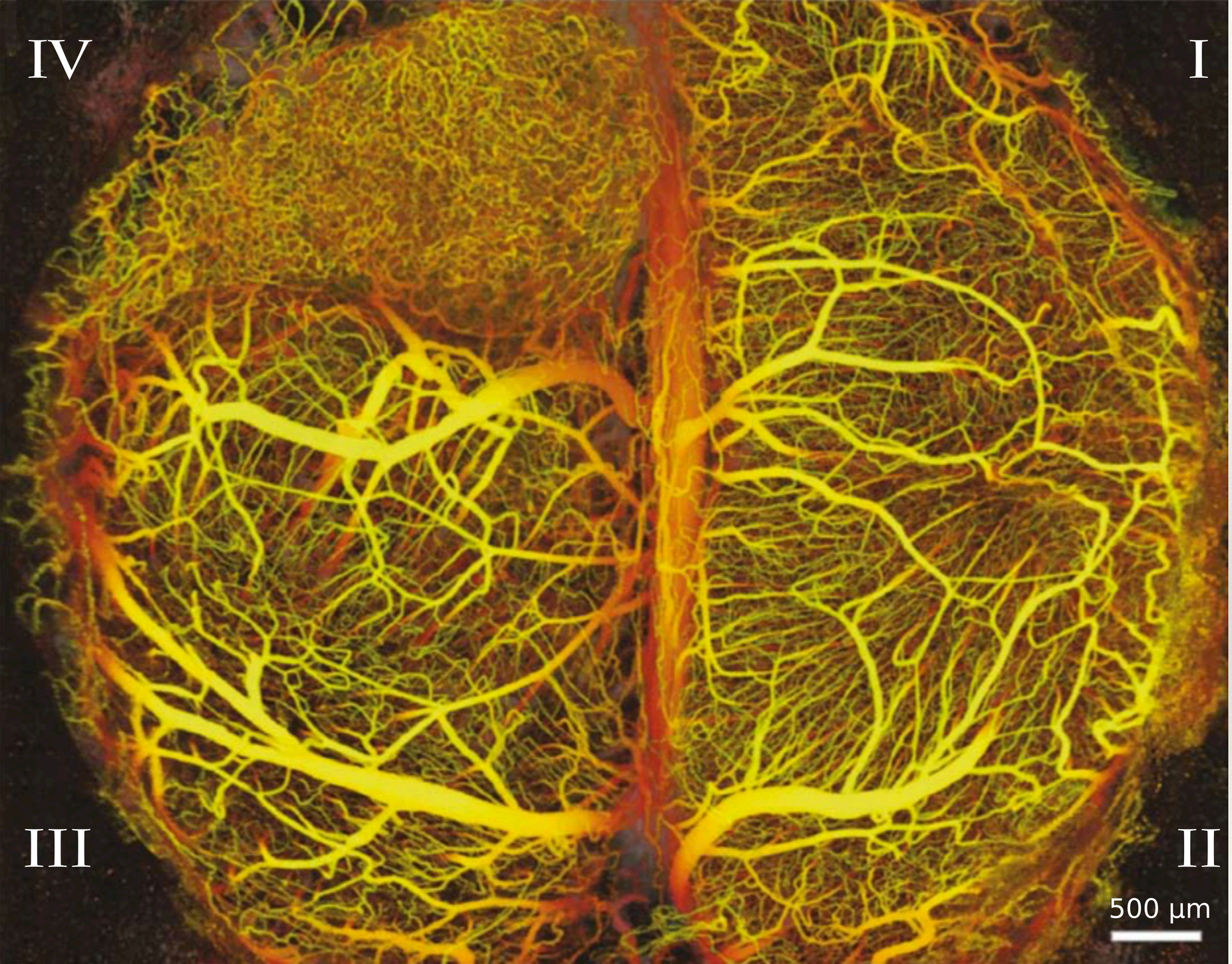

Optical Frequency Domain Imaging (OFDI)

- Anaesthetized mouse brain imaged through **cranial windows** using optical imaging techniques
- Vessel colour encodes **depth**; closer vessels are yellow and further vessels are red
- Note the normal brain vascular branching patterns in quadrants I, II, and II compared to the chaotic network of the **U87 tumour** in quadrant IV

Vakoc et al (2009). *Nature Medicine Technical Reports*

Vascular Normalization Hypothesis

ABNORMAL VESSELS

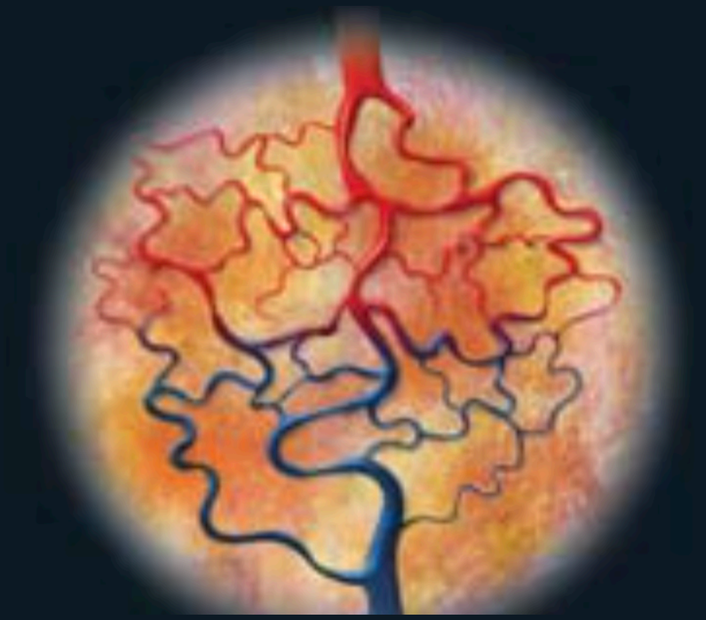

Treatment with Antiangiogenic Drug

Jain et al (2007). *Scientific American*

Vascular Normalization Hypothesis

NORMALIZED VESSELS

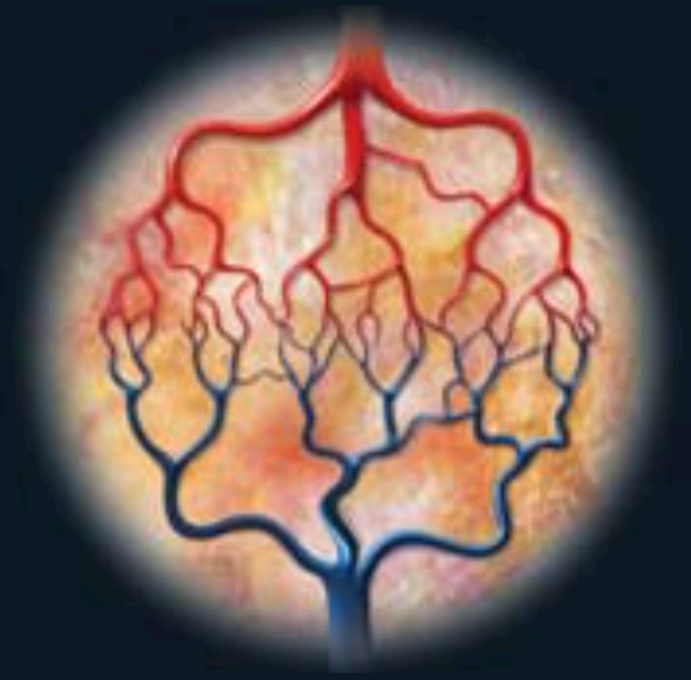

ABNORMAL VESSELS

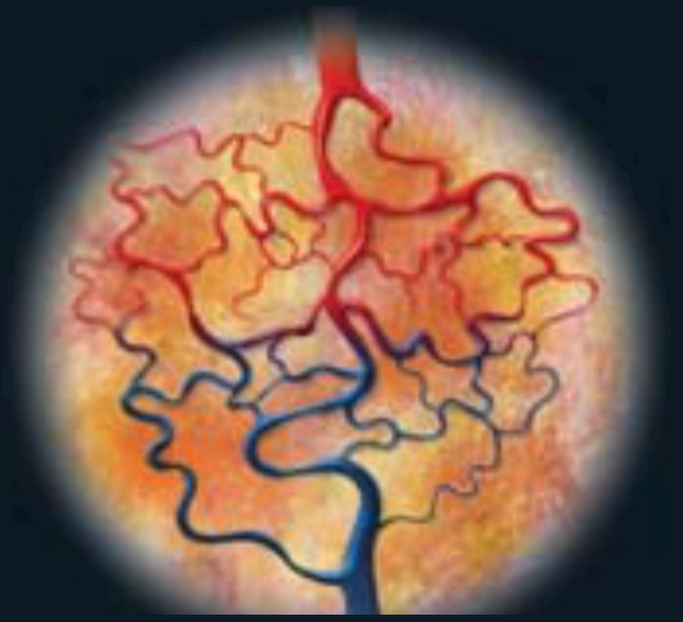

Treatment with Antiangiogenic Drug

Jain et al (2007). *Scientific American*

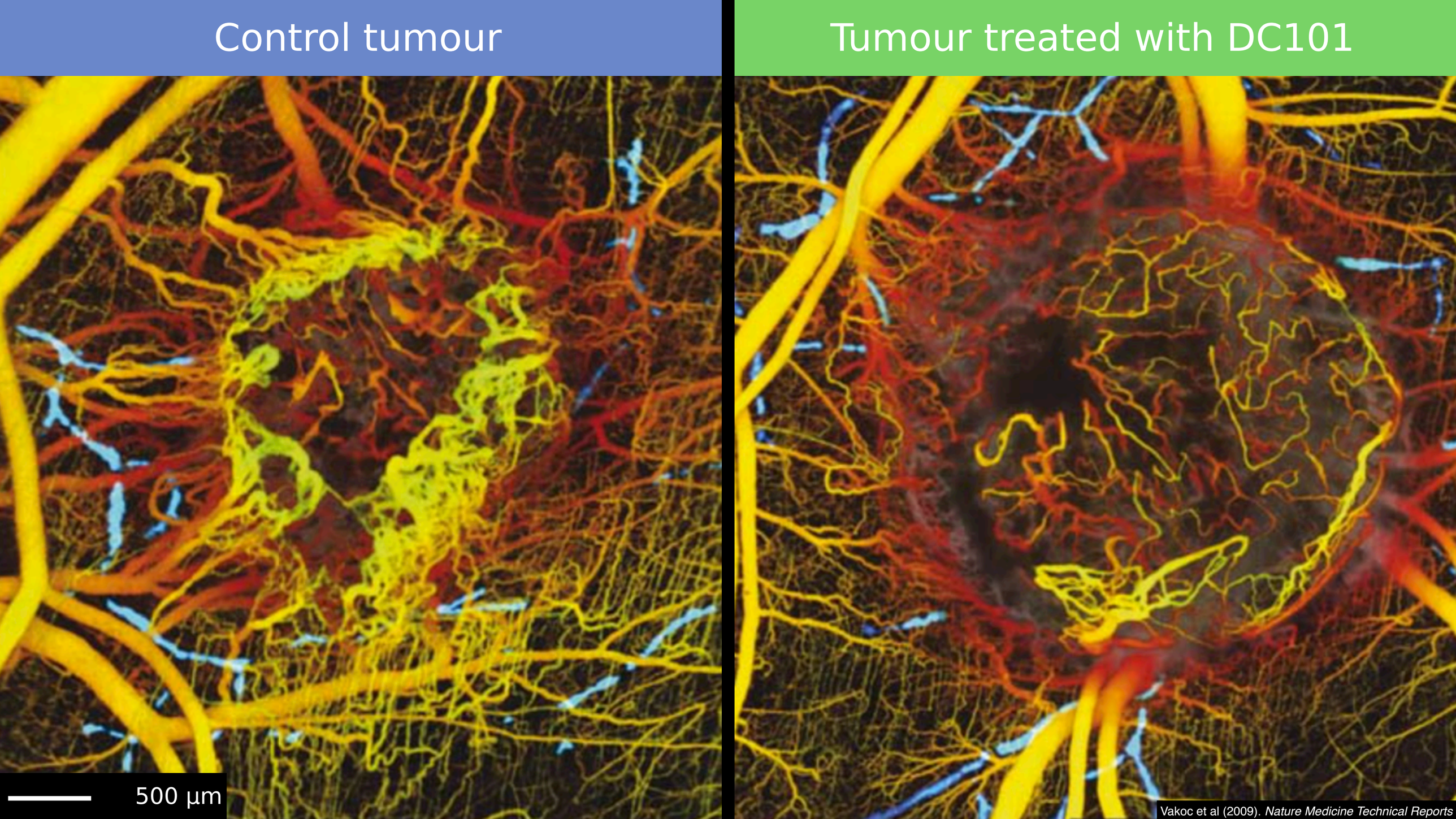

Vakoc et al (2009). *Nature Medicine Technical Reports*

Vascular Normalization Hypothesis

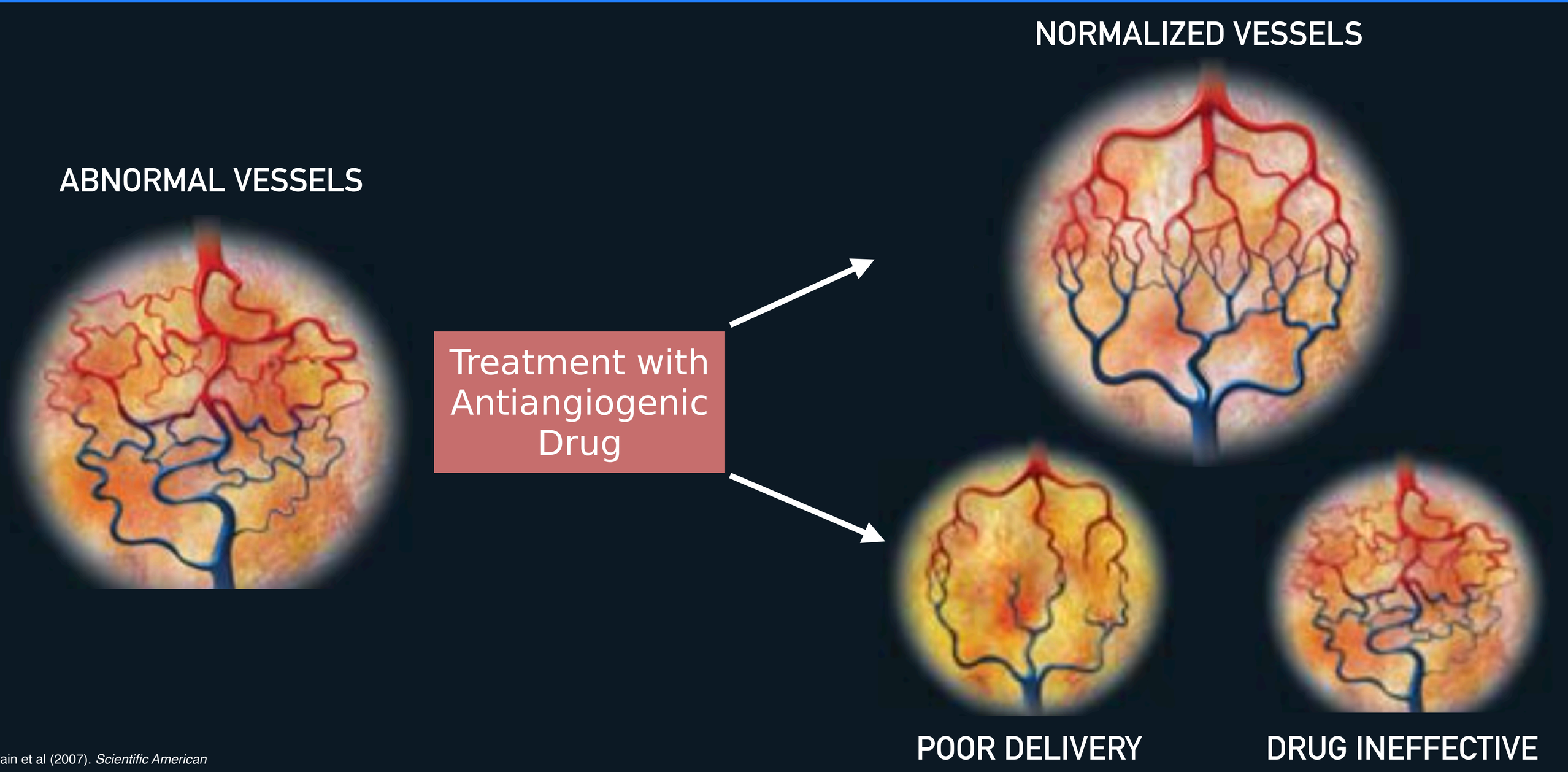

Jain et al (2007). *Scientific American*

II. Exploring vascular function with HPG

Introduction to HPG

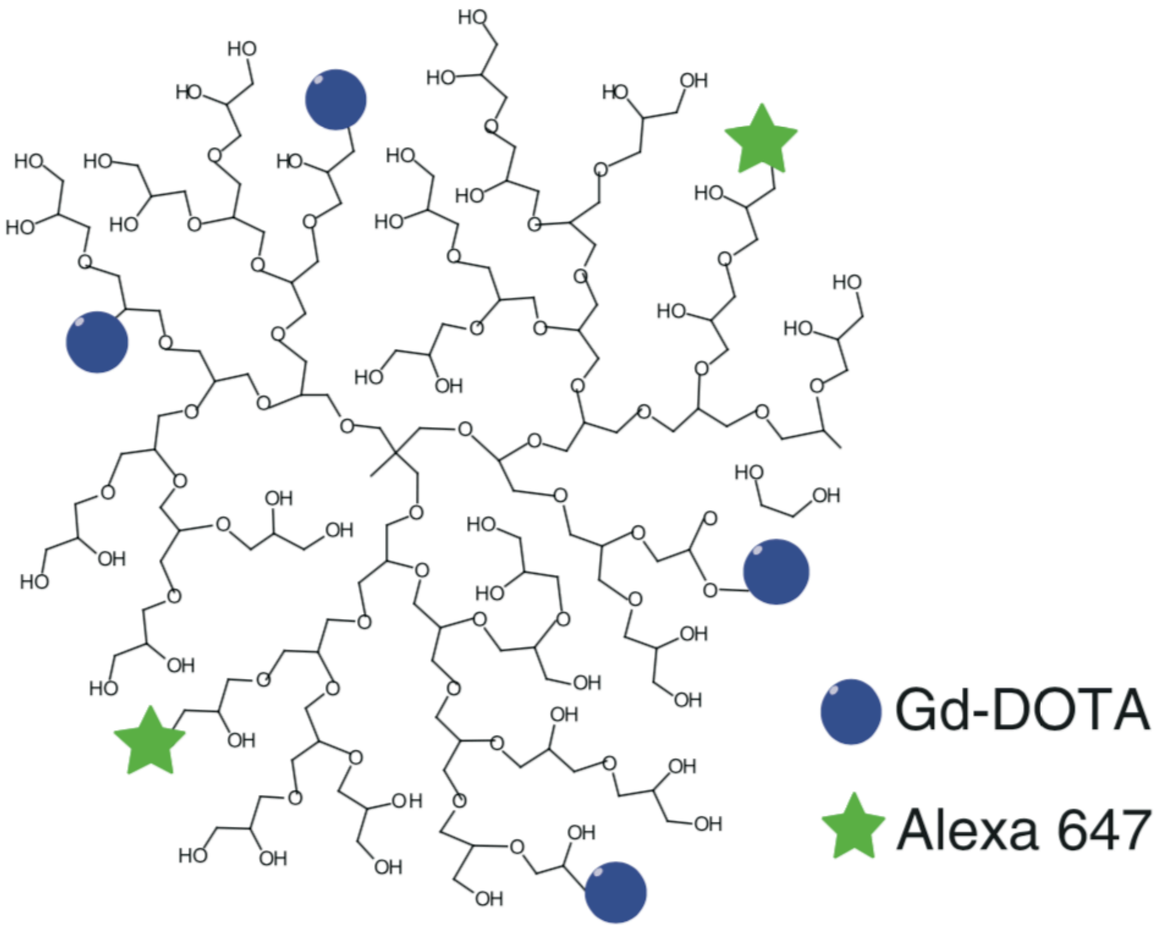

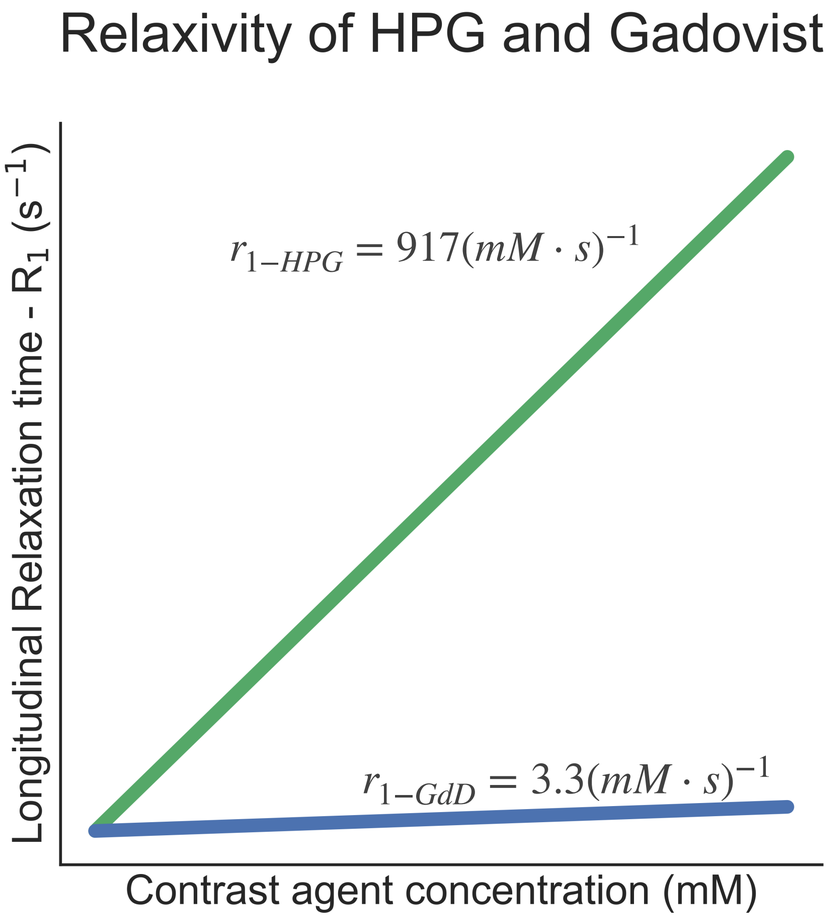

In collaboration with the Hafeli lab, a novel macromolecular biocompatible contrast agent was developed for use in pre-clinical imaging. Its' relaxivity is 300x that of Gd-DOTA

Comparing Kinetics of HPG and Gd



Contrast kinetics of two contrast agents: low-molecular weight Gd-DOTA and a high molecular weight HPG-GdF

Comparing Kinetics of HPG and Gd

Gd-DOTA

Before

After



HPG

Before

After

Contrast kinetics of two contrast agents: low-molecular weight Gd-DOTA and a high molecular weight HPG-GdF

Comparing Kinetics of HPG and Gd

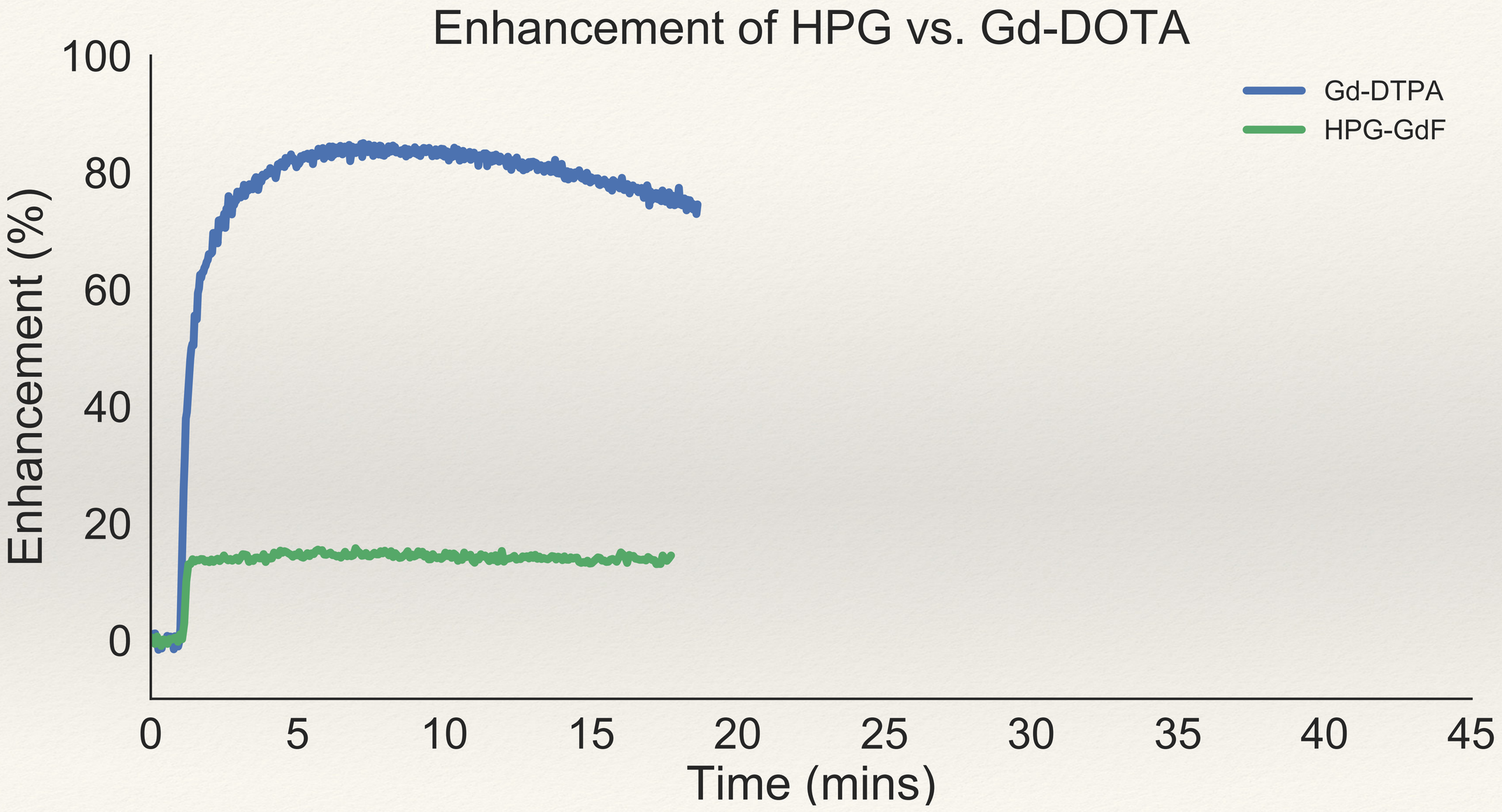

Comparing Kinetics of HPG and Gd

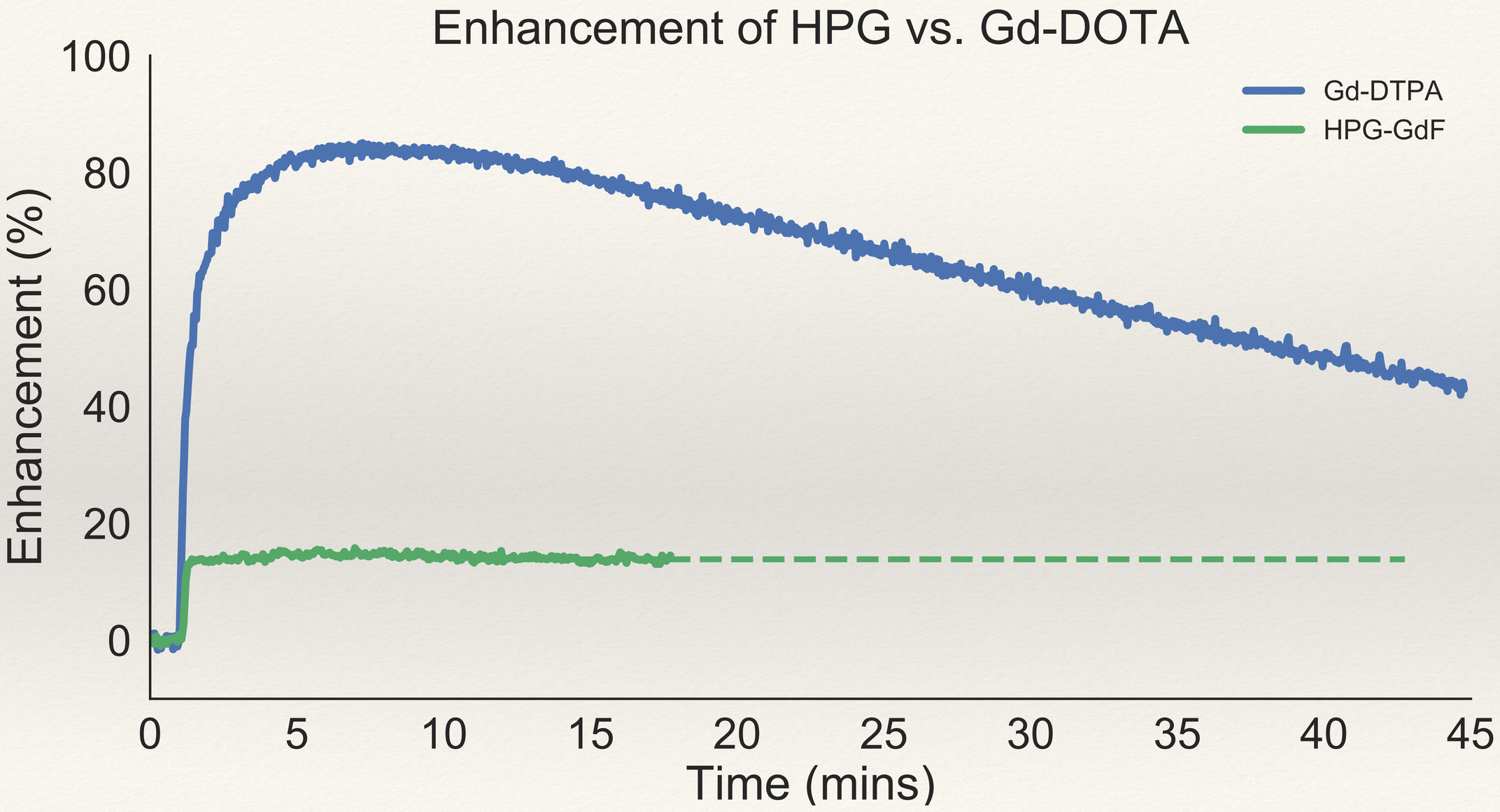

Results

Accumulation and distribution of HPG

A) HPG-GdF accumulation in HT29 xenografts; RARE images

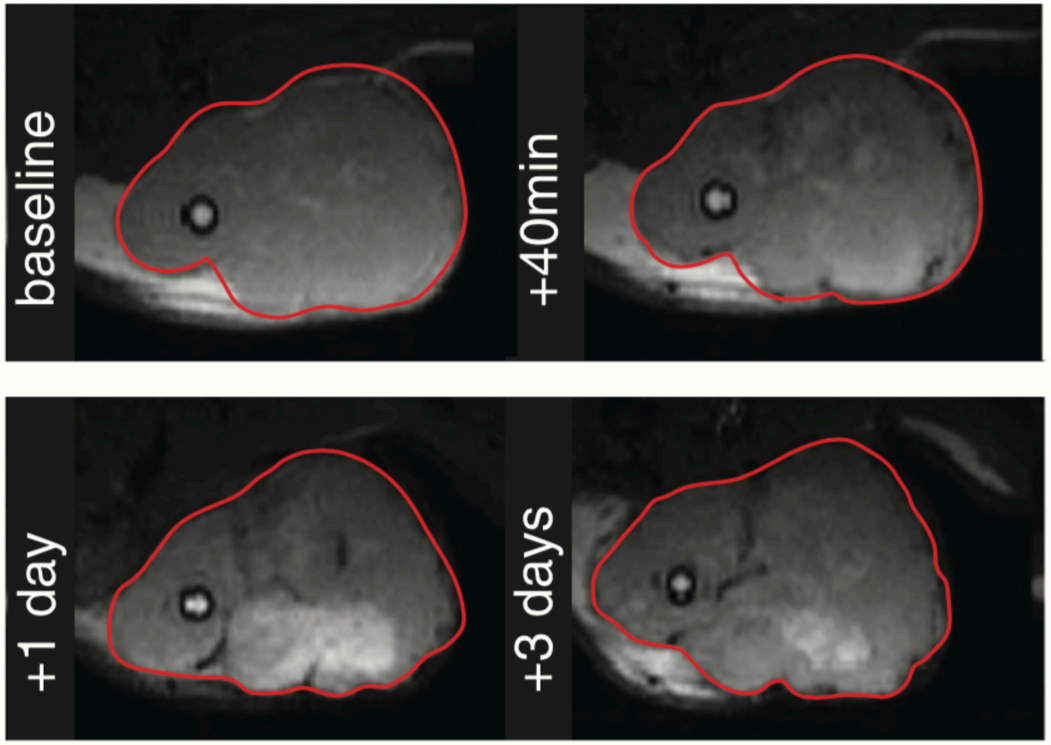

B) HPG-GdF distribution from vessels in HT29 xenografts

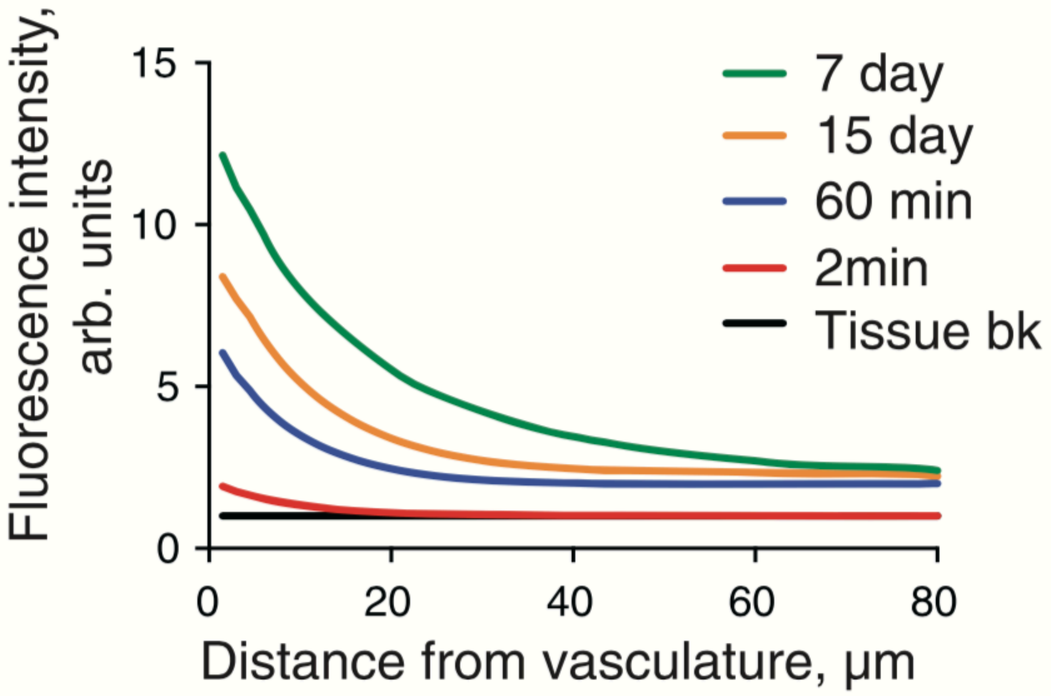

Both MRI and histology data show that HPG-GdF remains within the tumour up to 3 days (MRI) and 7 days (histology). After two weeks post-injection, fluorescence intensity is reduced.

Quantifying kinetics of HPG

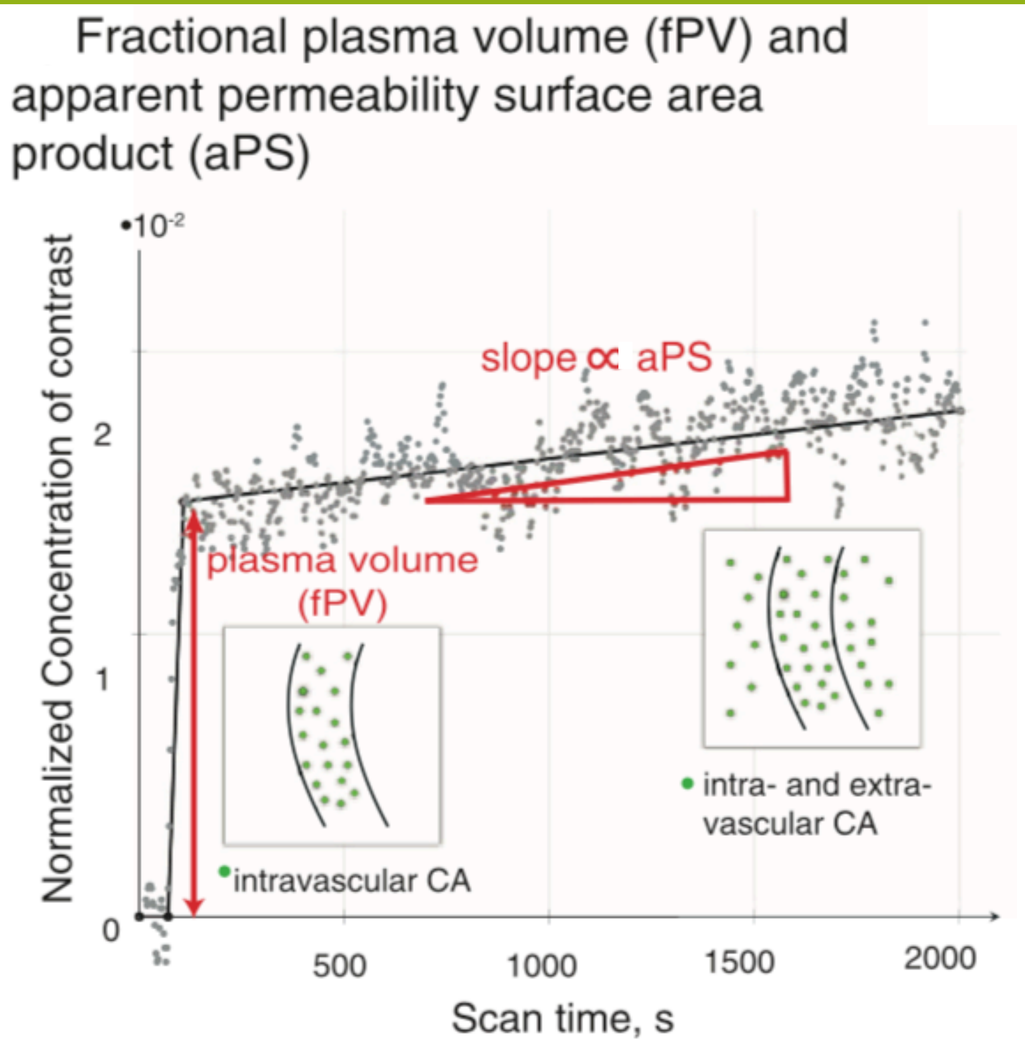

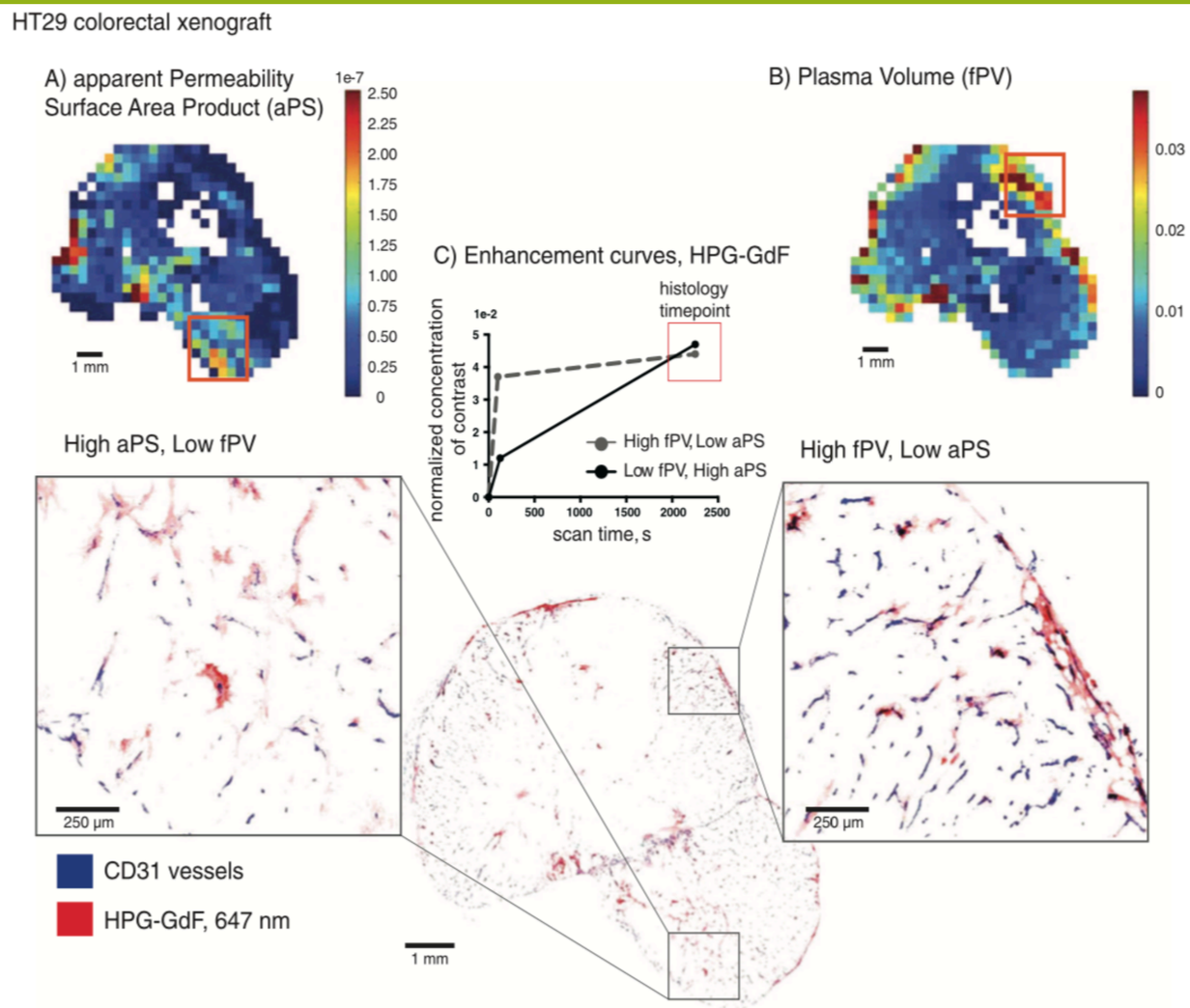

A two-parameter (aPS and fPV) linear model was applied to the HPG-GdF contrast kinetics. The high fPV region has greater vascular density in histology compared to the low fPV region.

Experiment 2: Treating tumours with bevacizumab (B20) [MRI]

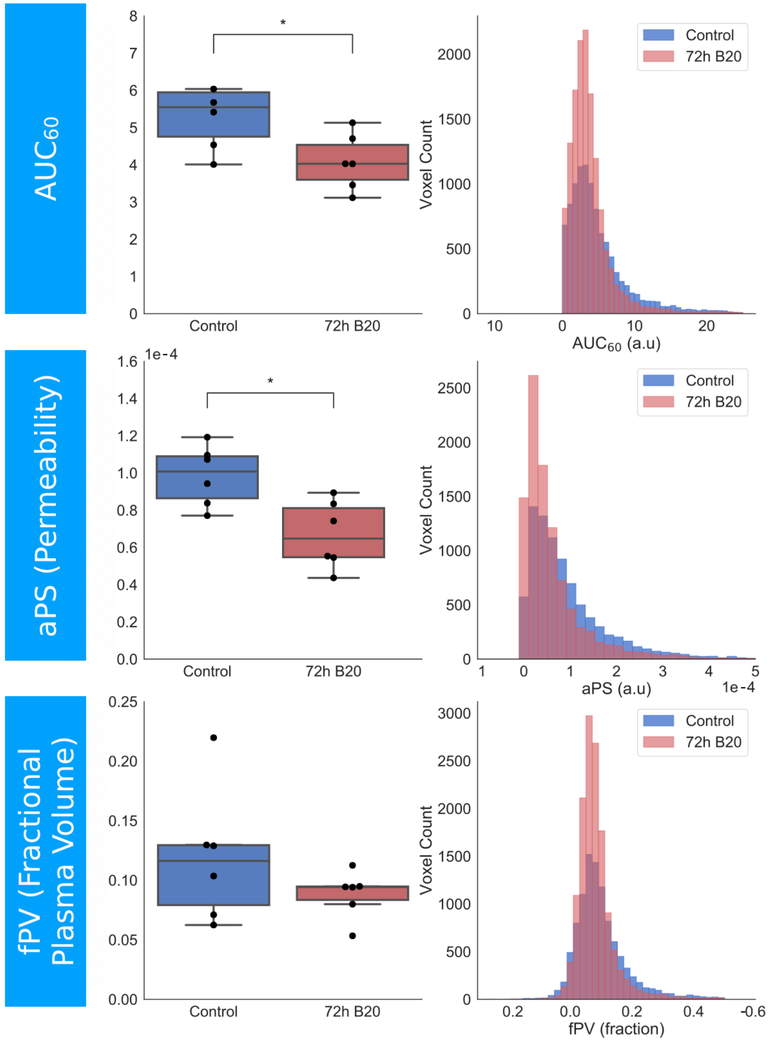

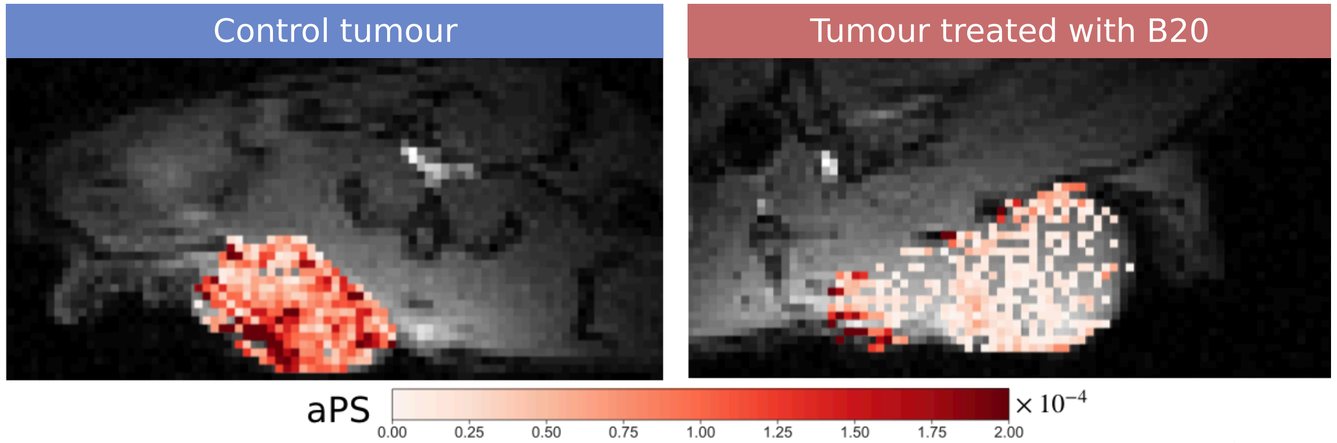

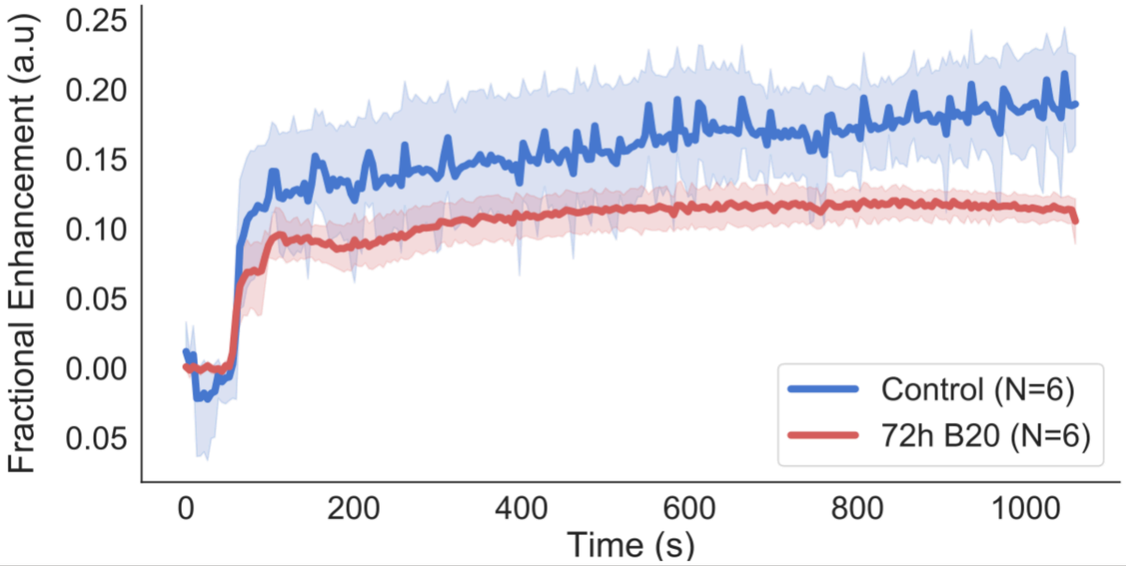

After Bevacizumab, AUC_{60} and aPS both showed a significant decrease. This is consistent with DCE-MRI contrast enhancement curves and parameter maps for control and treated tumours.

Conclusions

Development of model to quantify HPG kinetics (aPS and fPV)

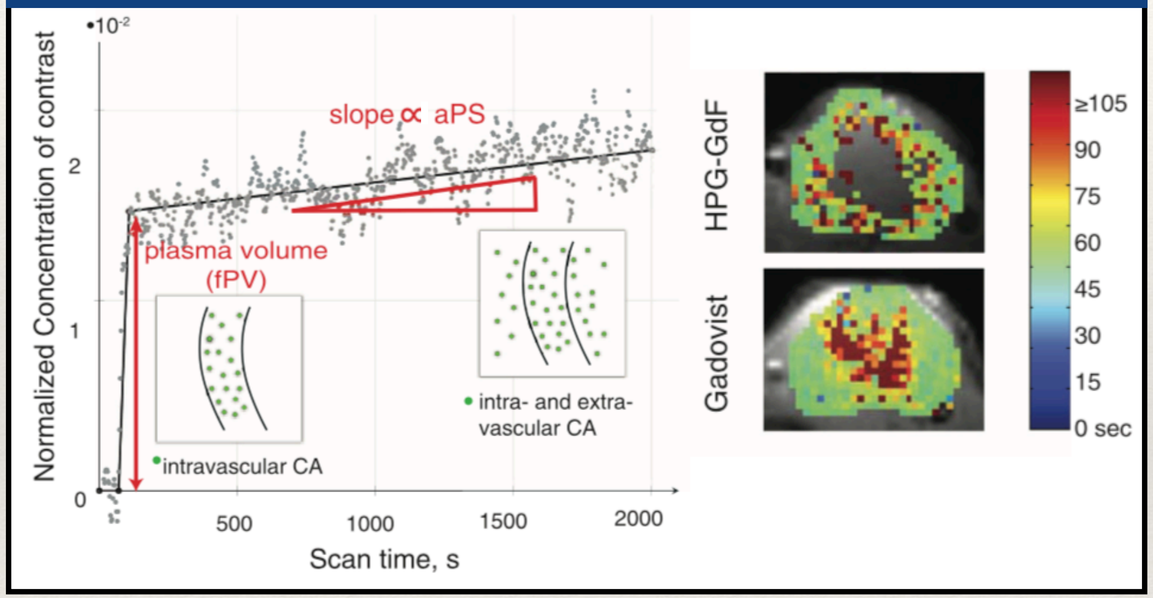

Treatment with B20 reduces permeability in tumours

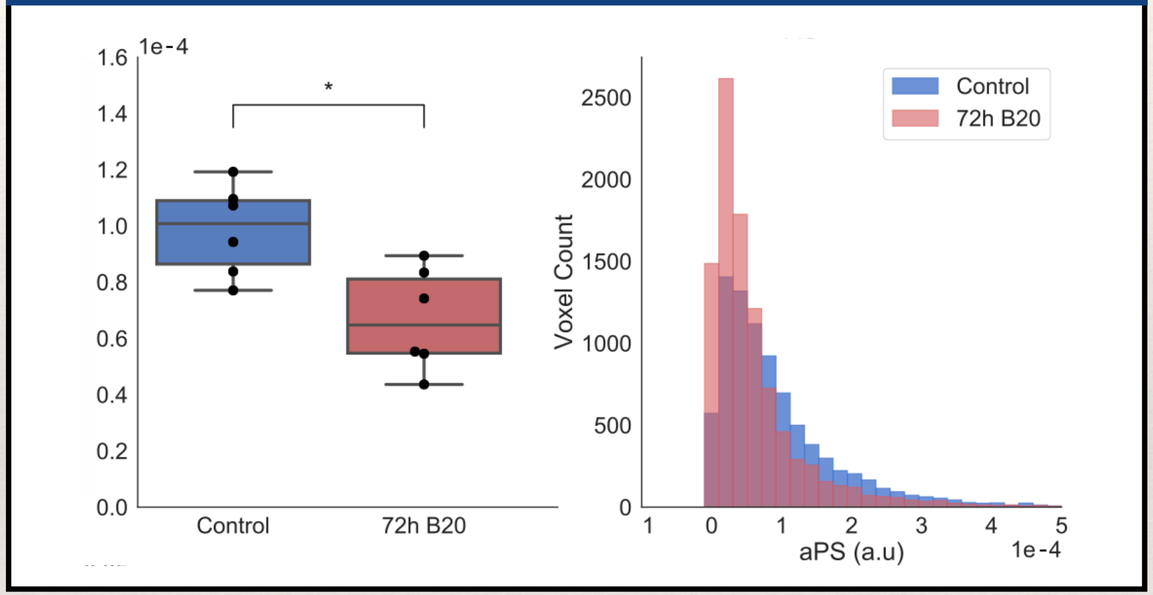

Experiment 2: Treating tumours with bevacizumab (B20) [Histology]

Control tumour

Treated tumour
(72h 5mg/kg B20)

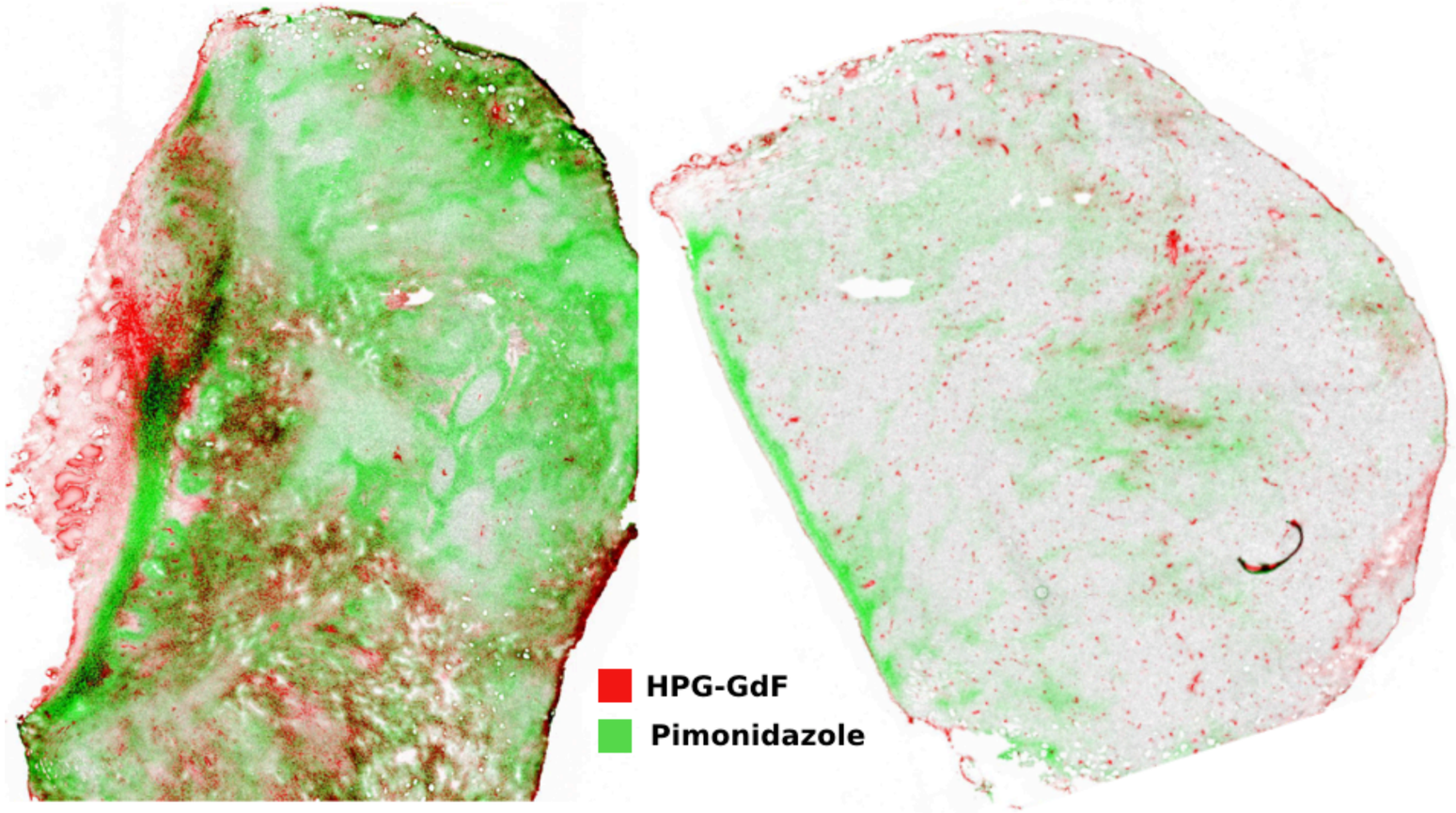

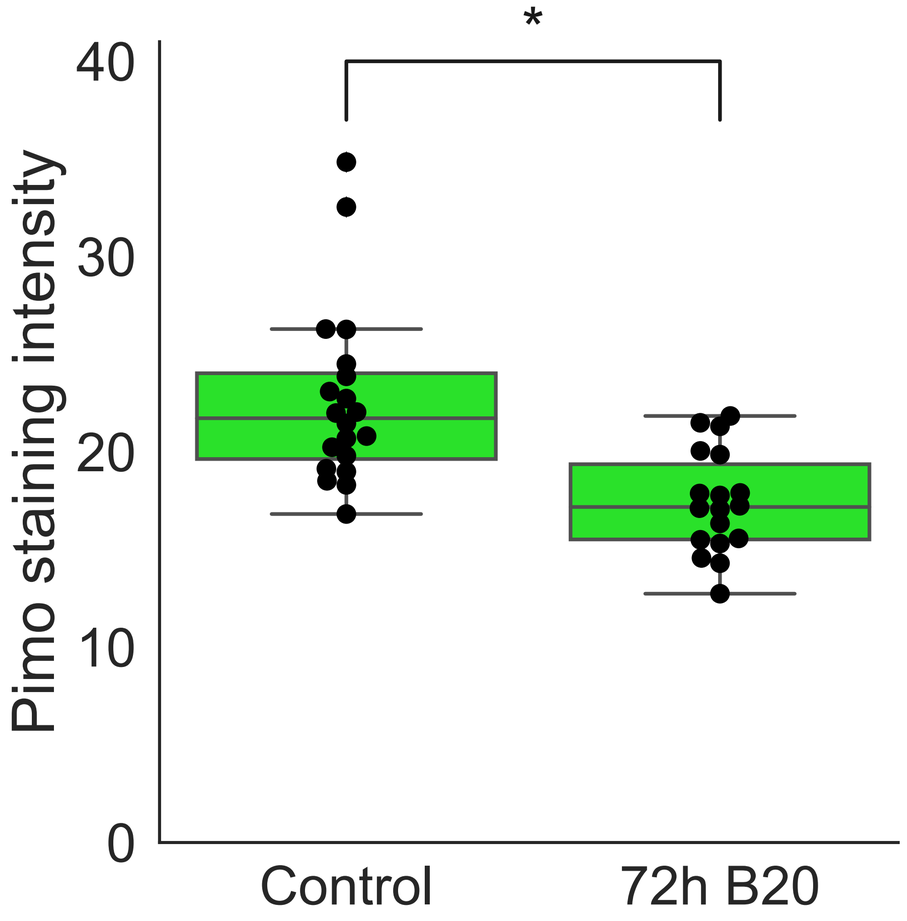

There was a significant decrease in pimonidazole (green) staining after 72h of treatment with Bevacizumab. Unfortunately, we could not assess tumour hypoxia with MRI at the time…

III. Oxygen enhanced MRI

Introduction to OEMRI

RED BLOOD CELLS CARRY 98% OF OXYGEN IN THE BODY

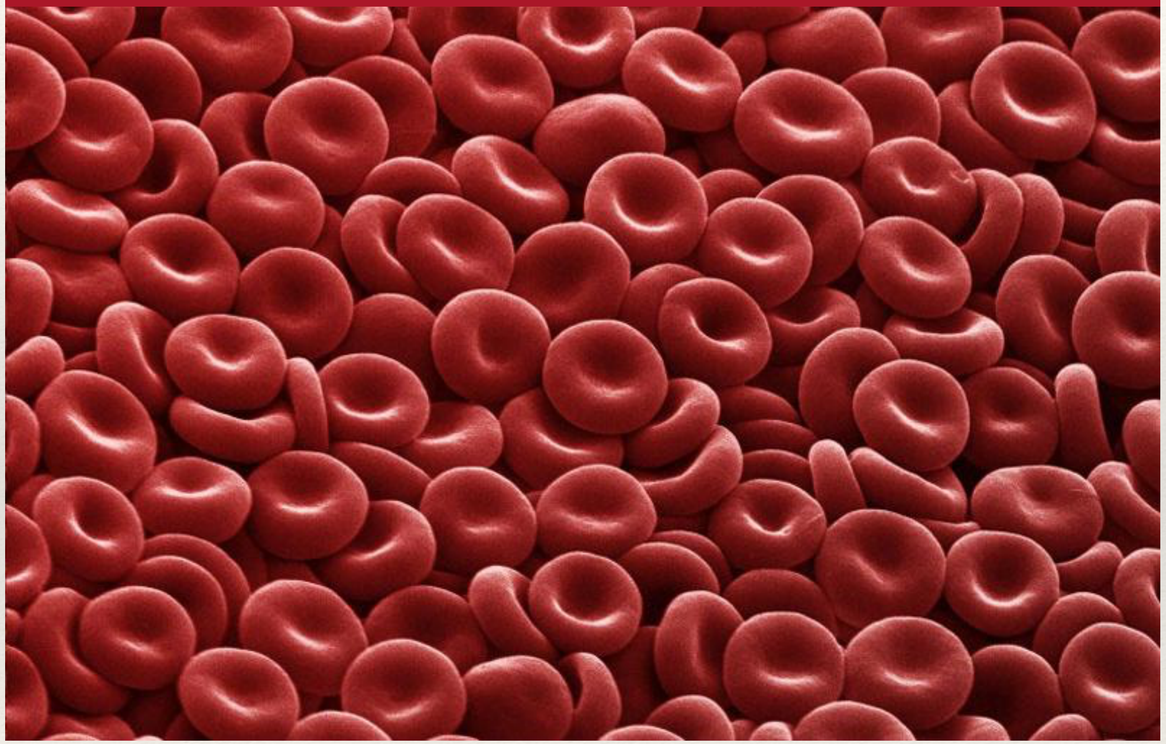

HAEMOGLOBIN MOLECULE HAS 4 BINDING SITES FOR OXYGEN

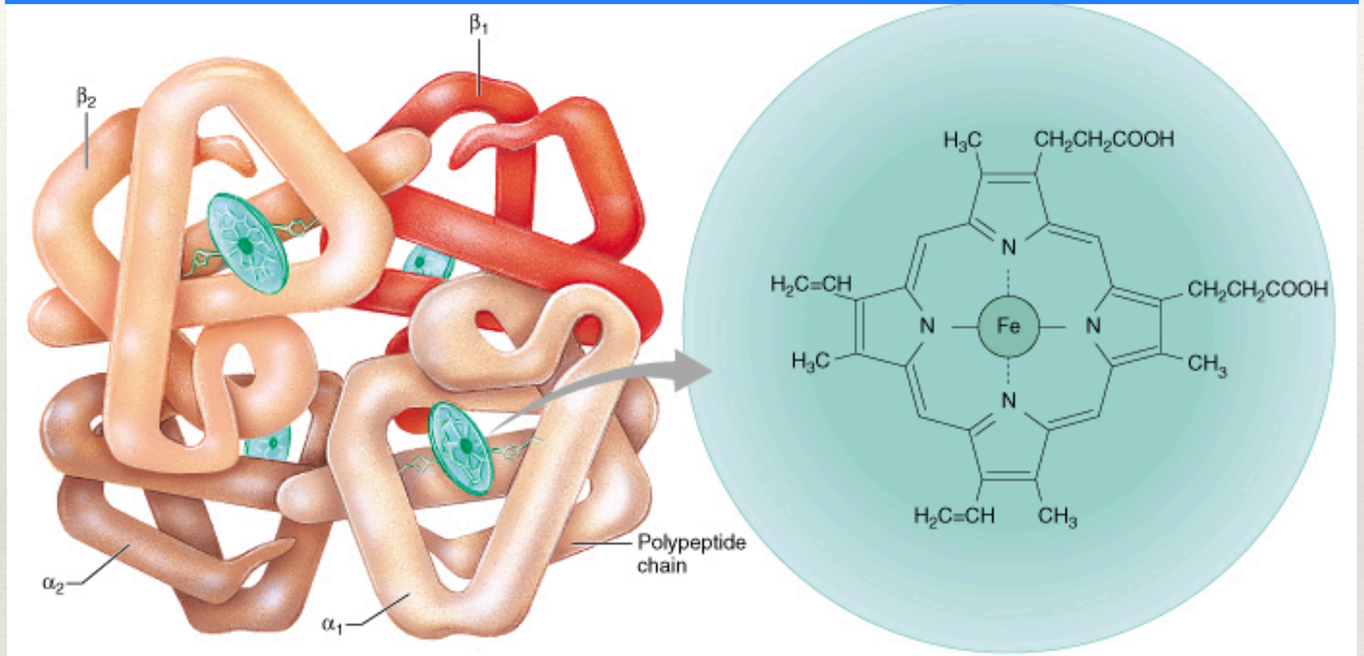

(a) Hemoglobin (b) Iron-containing heme group

Copyright © 2001 Benjamin Cummings, an imprint of Addison Wesley Longman, Inc.

Oxygen-enhanced MRI relies on measuring the signal changes that arise from excess oxygen dissolved in the plasma and the interstitial tissue fluid.

Introduction to OEMRI

Anatomical Scan

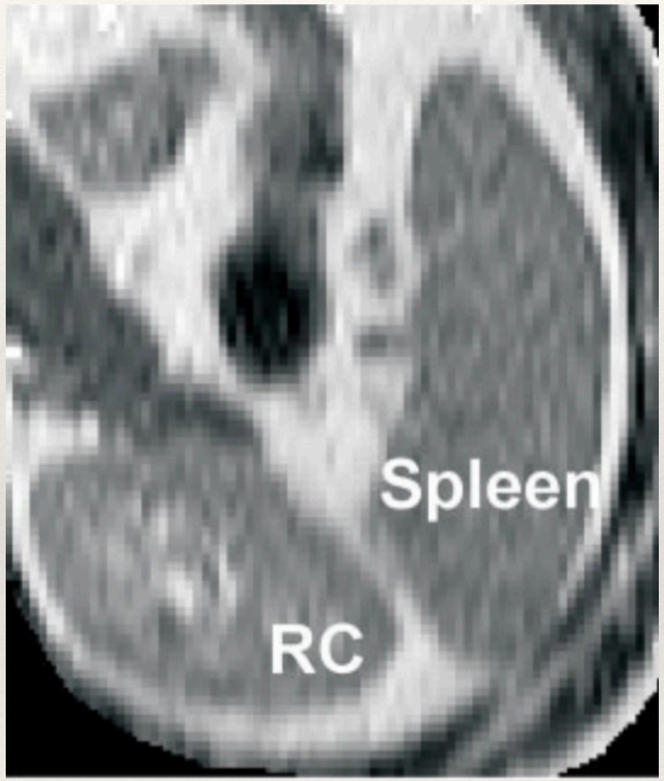

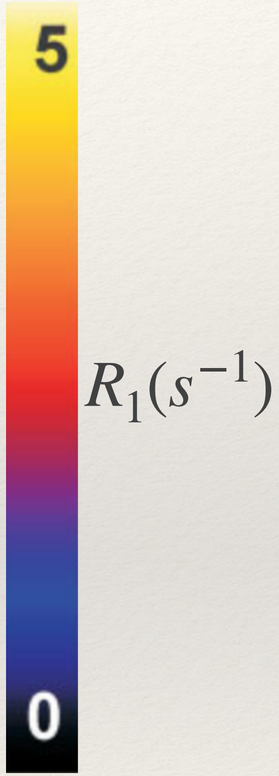

O'Connor et al (2009). Magnetic Resonance in Medicine

Oxygen is slightly paramagnetic molecule and acts as a T1-shortening agent. In this human scan, the kidney's renal cortex (RC) and spleen are marked on an anatomical scan.

Introduction to OEMRI

Anatomical Scan **Room Air** **100% Oxygen**

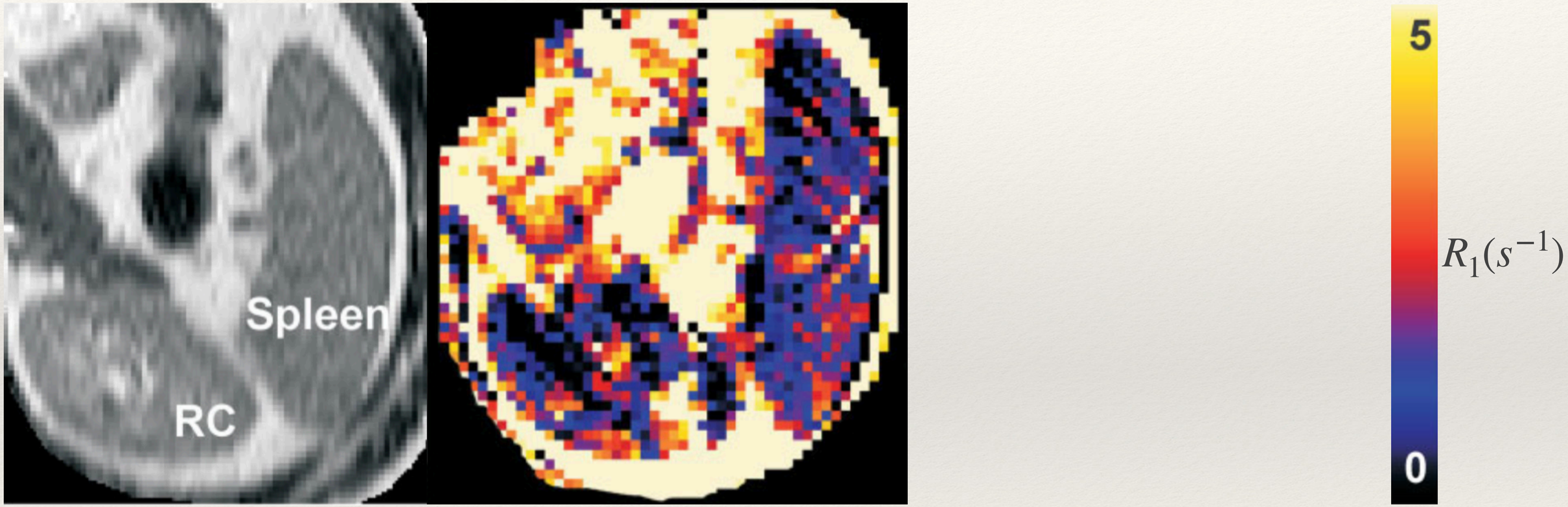

O'Connor et al (2009). Magnetic Resonance in Medicine

Here is an R1 map of the region - notice the spleen is darker (lower R1) compared to the surrounding regions while the individual is breathing air.

Introduction to OEMRI

Anatomical Scan **Room Air** **100% Oxygen**

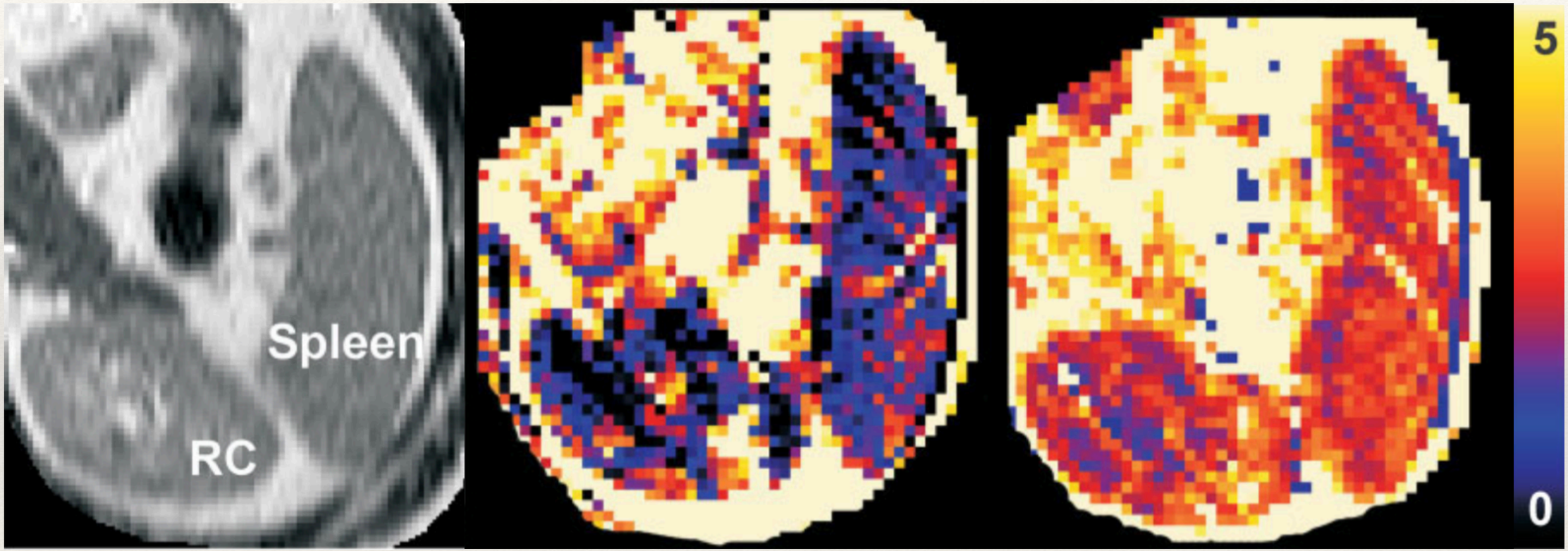

$R_1(s^{-1})$

O'Connor et al (2009). Magnetic Resonance in Medicine

Upon inhalation of 100% oxygen, there is a significant R1 increase in the spleen and RC.

Dynamic Oxygen-Enhanced MRI

1

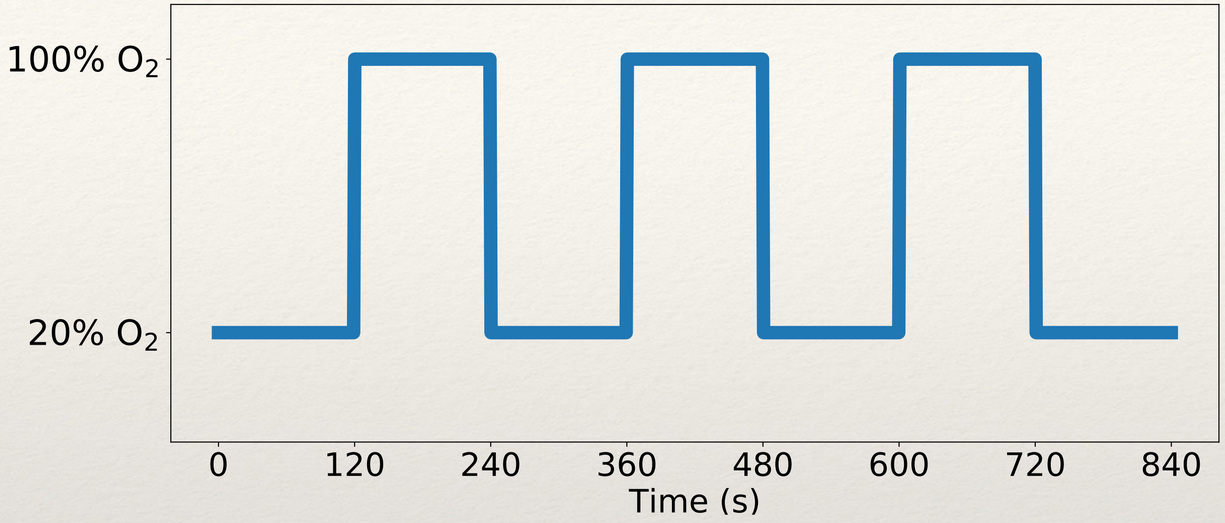

2

Independent Component Analysis

Our technique uses oxygen cycling and independent component analysis (ICA) to isolate the oxygen-enhancing component from the signal trace.

Dynamic Oxygen-Enhanced MRI

A. T_2-weighted Image

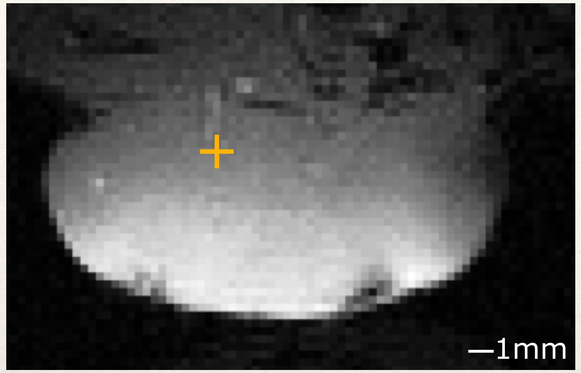

B. Signal Intensity Traces

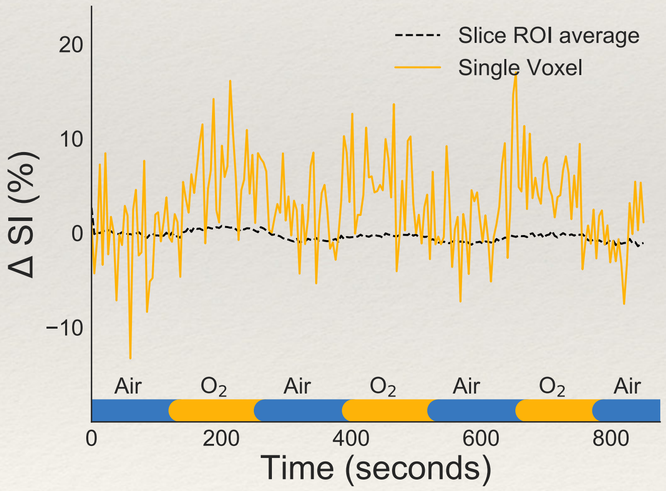

Independent Component Analysis (ICA)

C. ICA Components

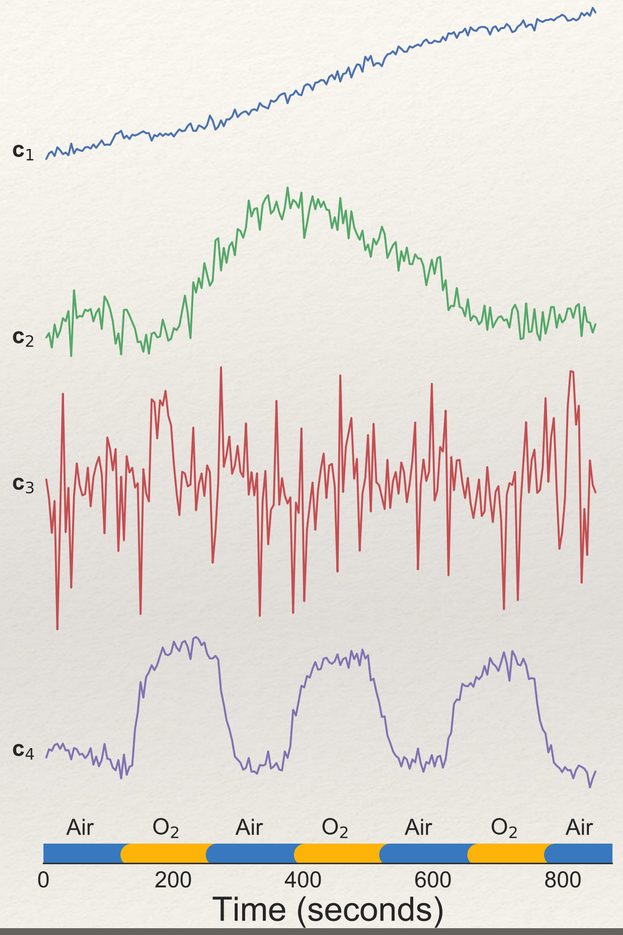

Our technique uses oxygen cycling and independent component analysis (ICA) to isolate the oxygen-enhancing component from the signal trace.

Dynamic Oxygen-Enhanced MRI

A. T_2-weighted Image

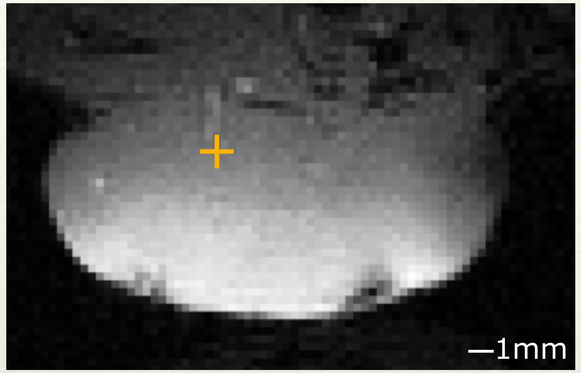

Independent Component Analysis (ICA)

C. ICA Components

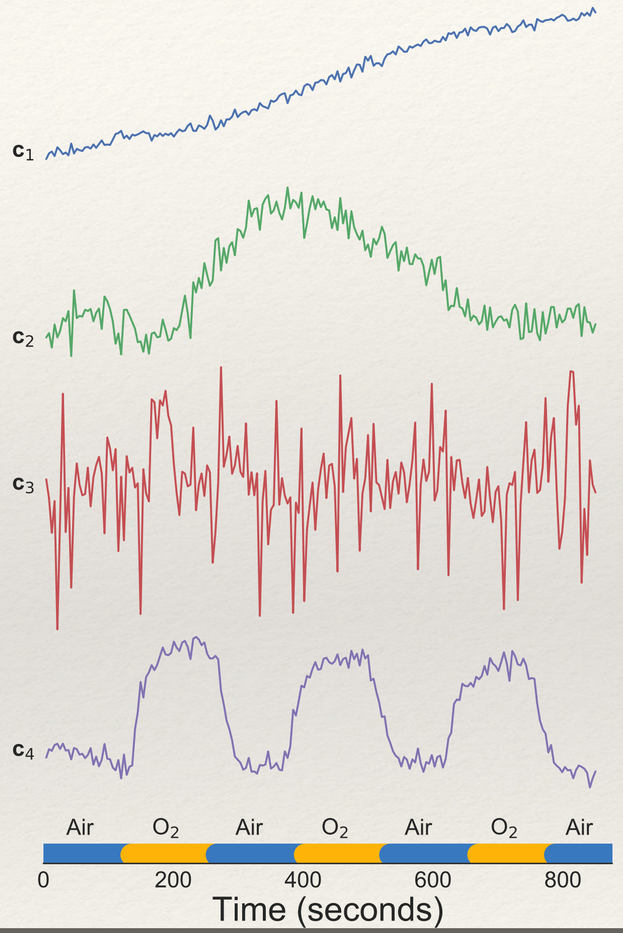

B. Signal Intensity Traces

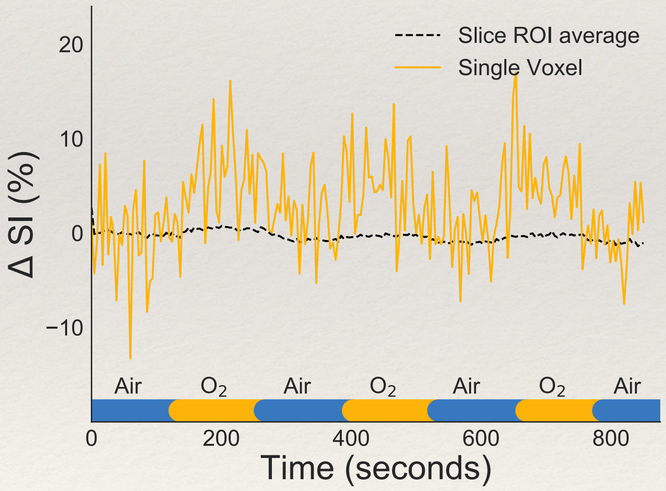

dOE-MRI map

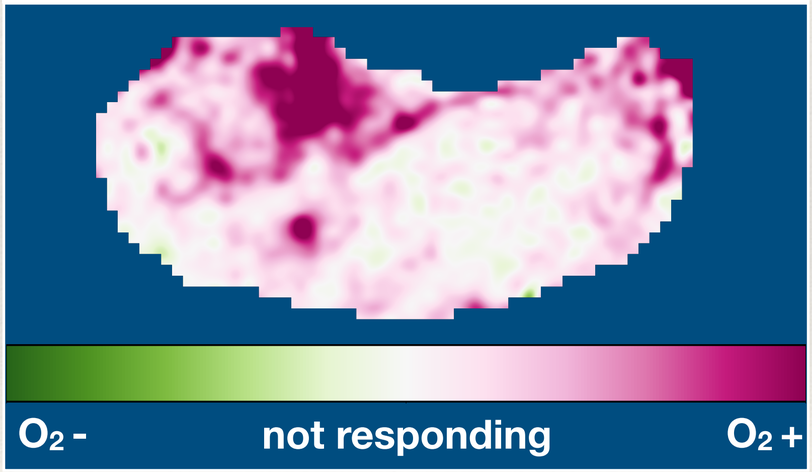

A weighting factor map is produced from ICA; this is the dOE-MRI map that we use to assess the oxygenation status in tumours.

Results

Validation of dOE-MRI with histology

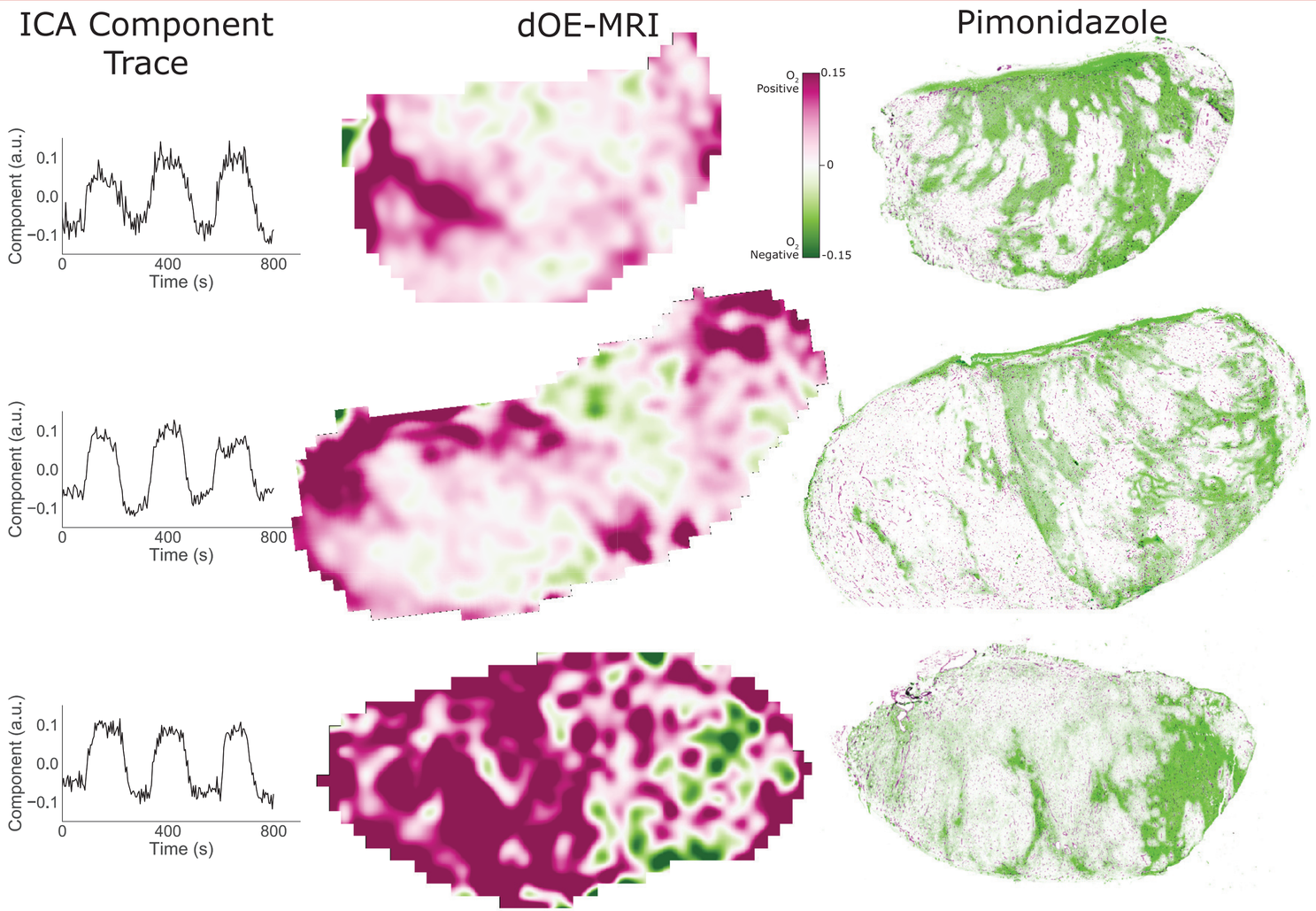

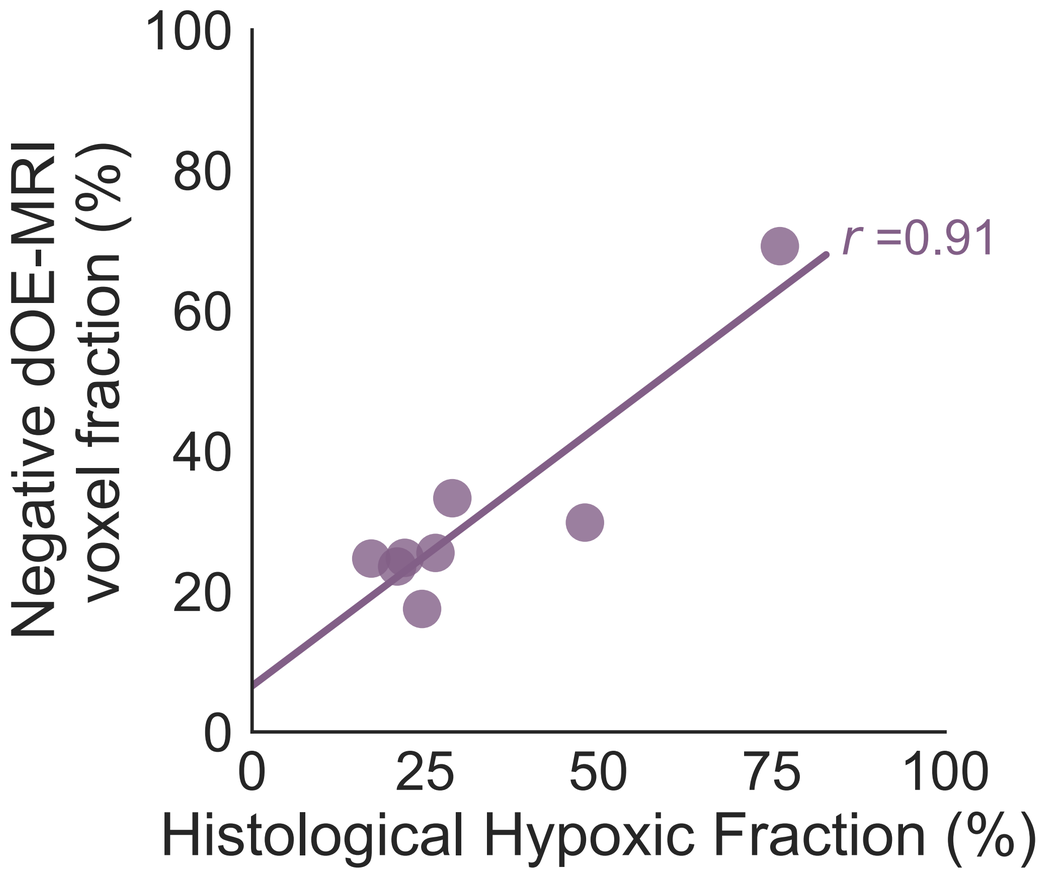

dOE-MRI maps are compared to slice-matched histology sections. Good correspondence is seen between areas of more positive oxygenation response (purple) and non-hypoxic regions.

Using dOE-MRI to measure oxygenation increase after treatment with B20

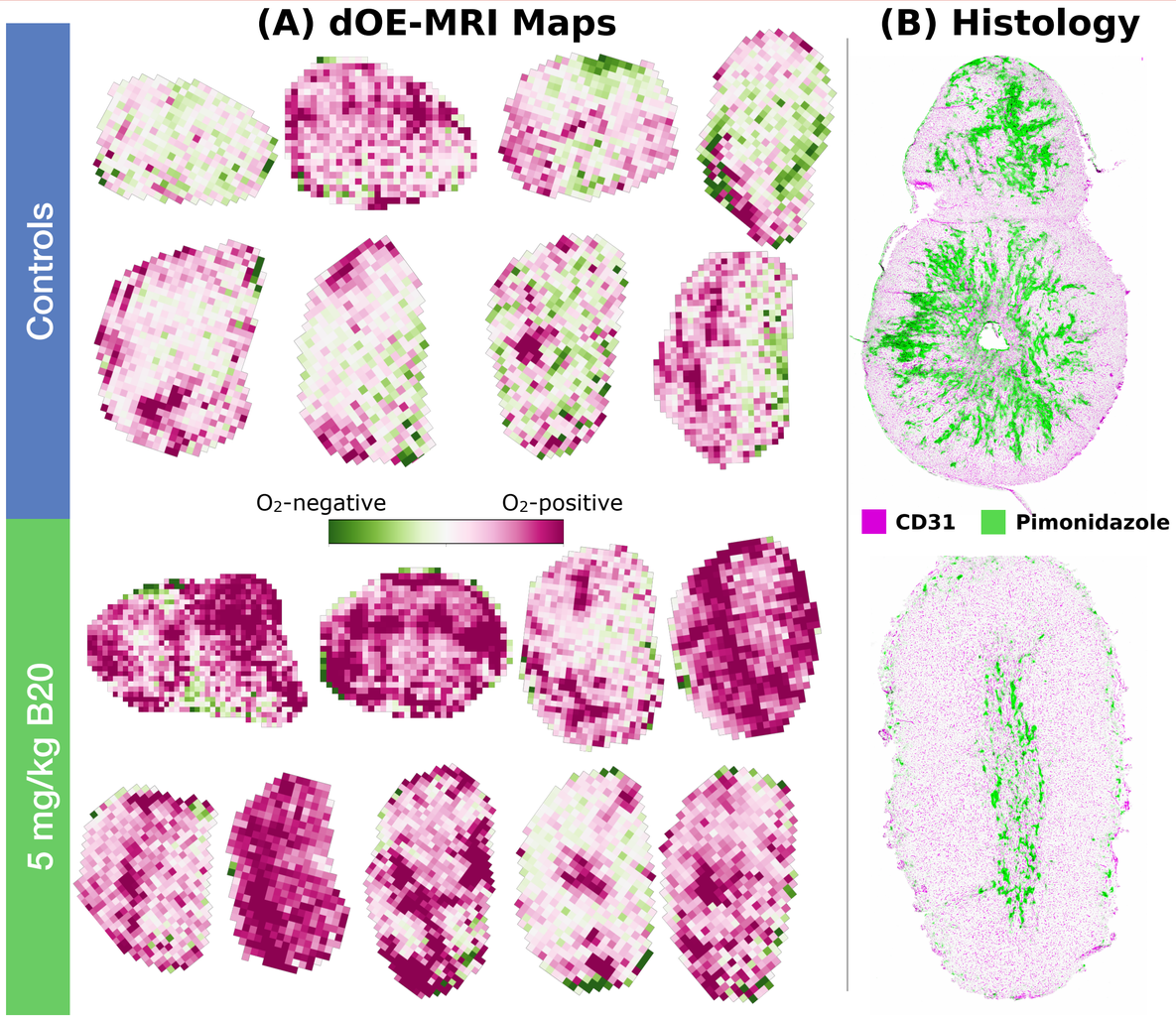

dOE-MRI maps indicate a significant increase in oxygenation for the B20-treated tumours. Representative histological sections match this observation: reduced hypoxia in treated tumours.

Using dOE-MRI to measure oxygenation increase after treatment with B20

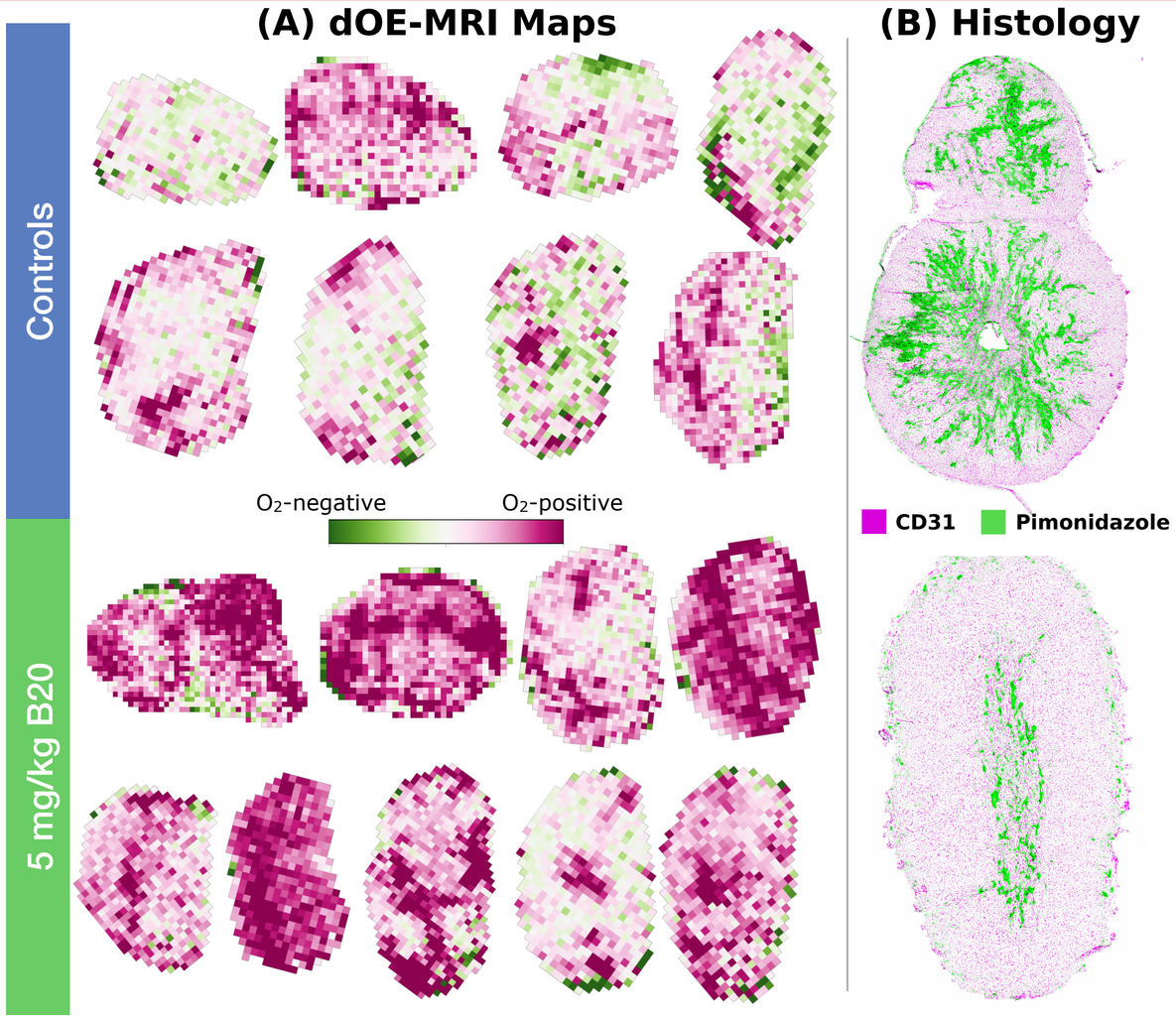

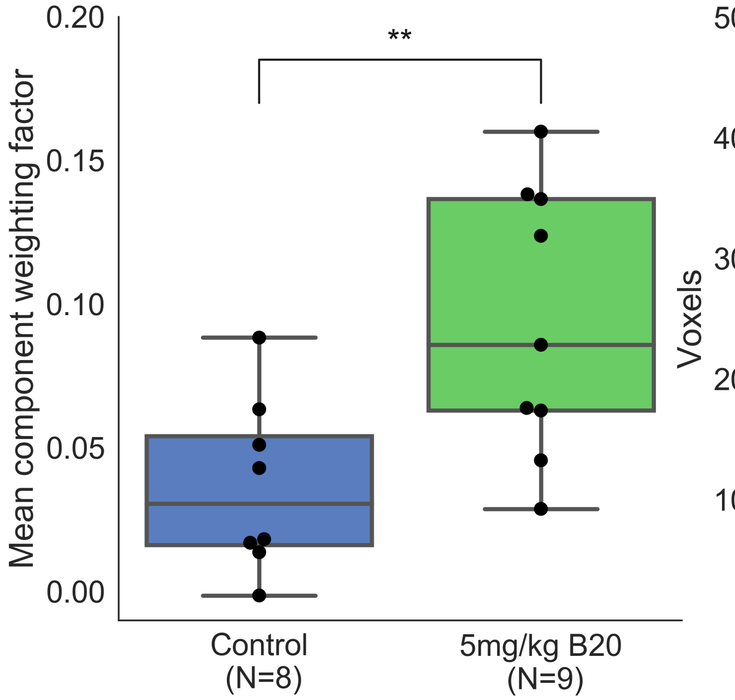

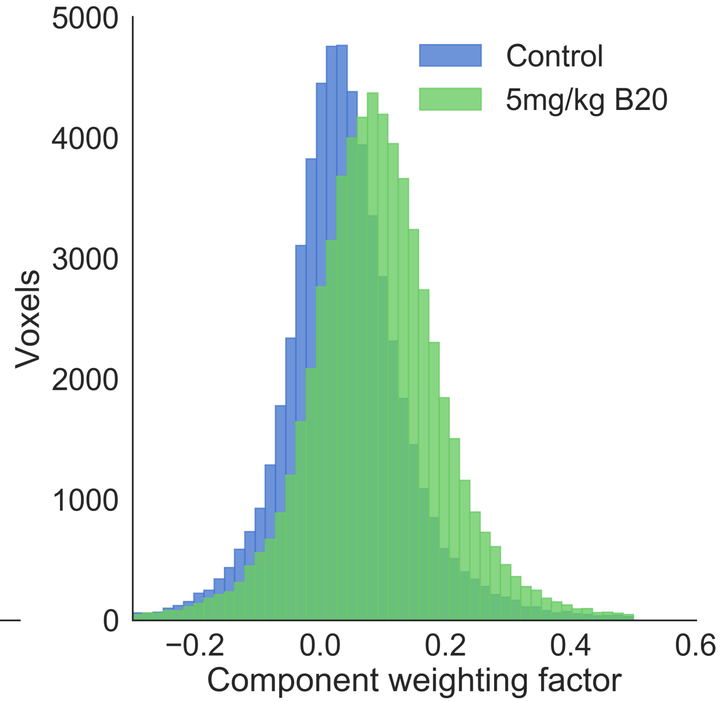

dOE-MRI maps indicate a significant increase in oxygenation for the B20-treated tumours. Representative histological sections match this observation: reduced hypoxia in treated tumours.

Conclusions

dOE-MRI to measure tumour oxygenation with just inhaled gas

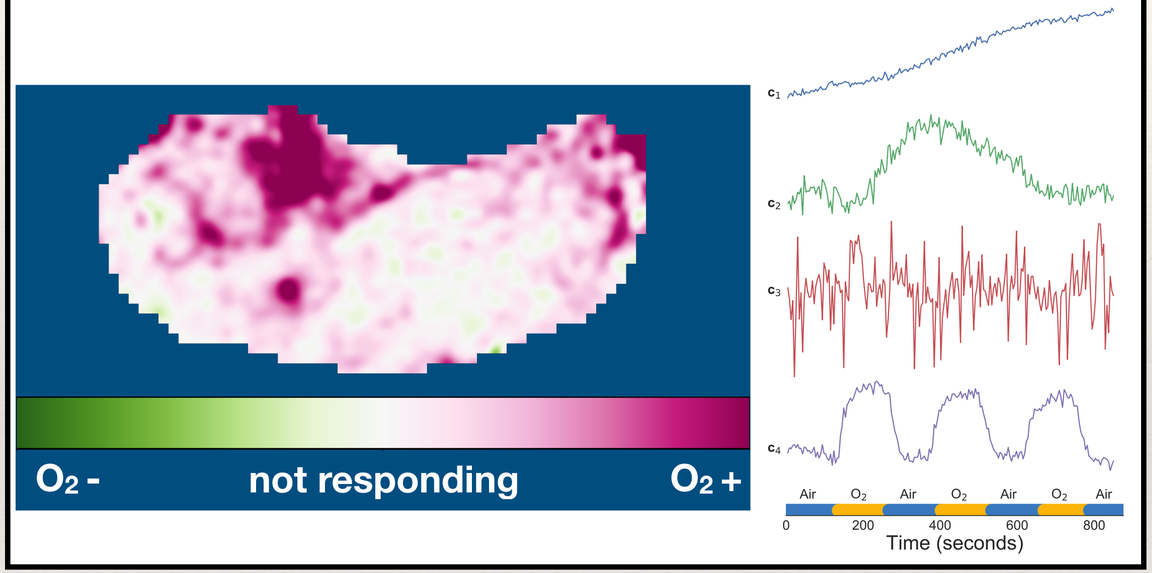

Treatment with B20 improves oxygenation in tumours

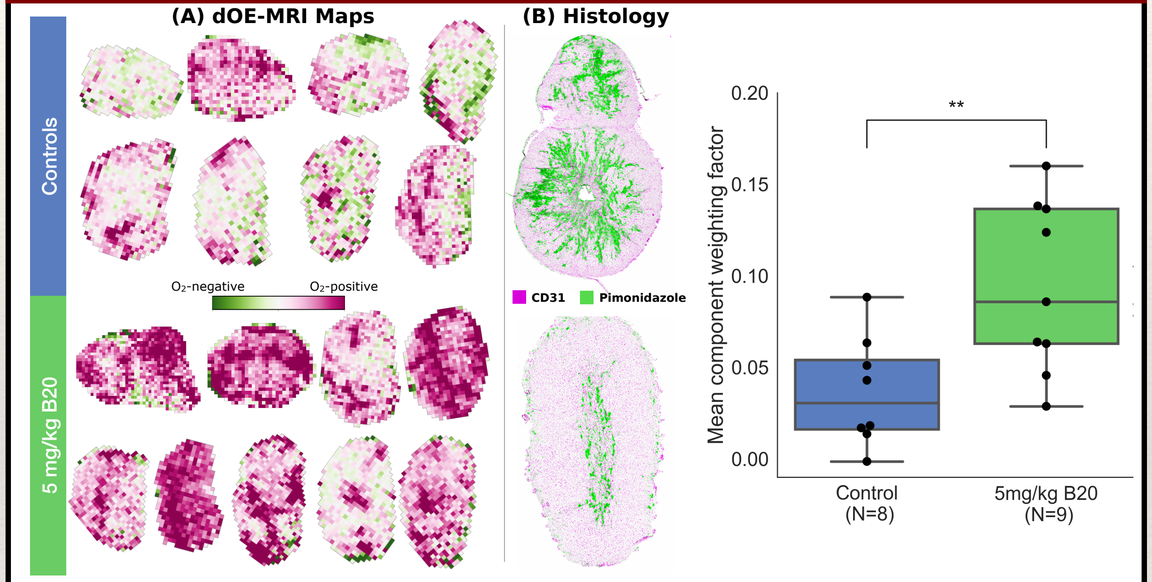

Future Work

ICA

Animals

$$\left[D\left(x, y, z, t \right) \right]_{n=1}^{n=10}$$

Spatial, Temporal

Apply ICA separately

10 sets of independent components

Group ICA

$$D\left(x, y, z, n, t \right)$$

Spatial Concatenation

Apply ICA once

1 set of independent components

Group ICA permits analysis of all animals at once to assess group behaviour.

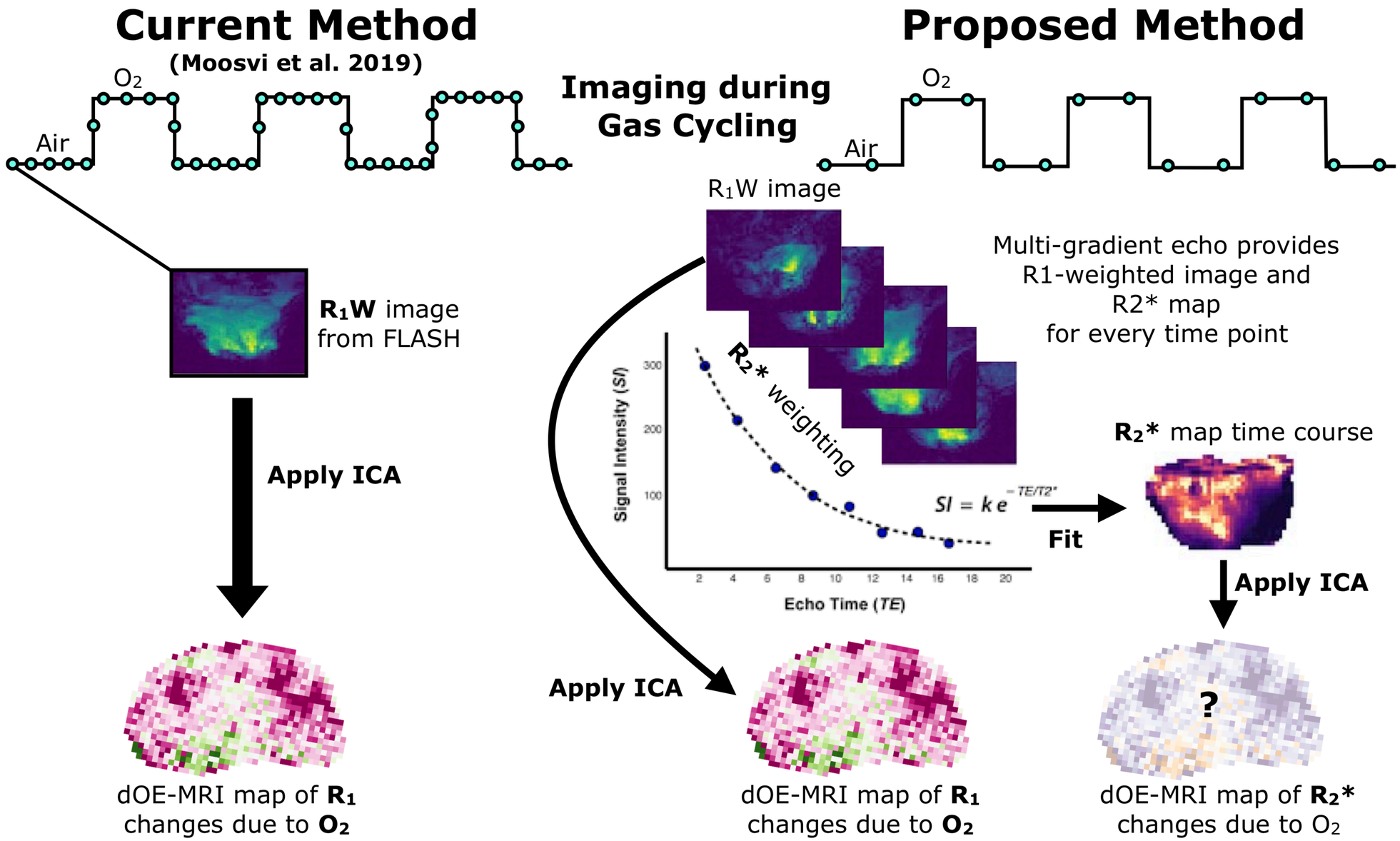

Adding R2* to our dOE-MRI method will improve our understanding of the oxygenation response in tumours with additional information (from the BOLD effect)

Brain

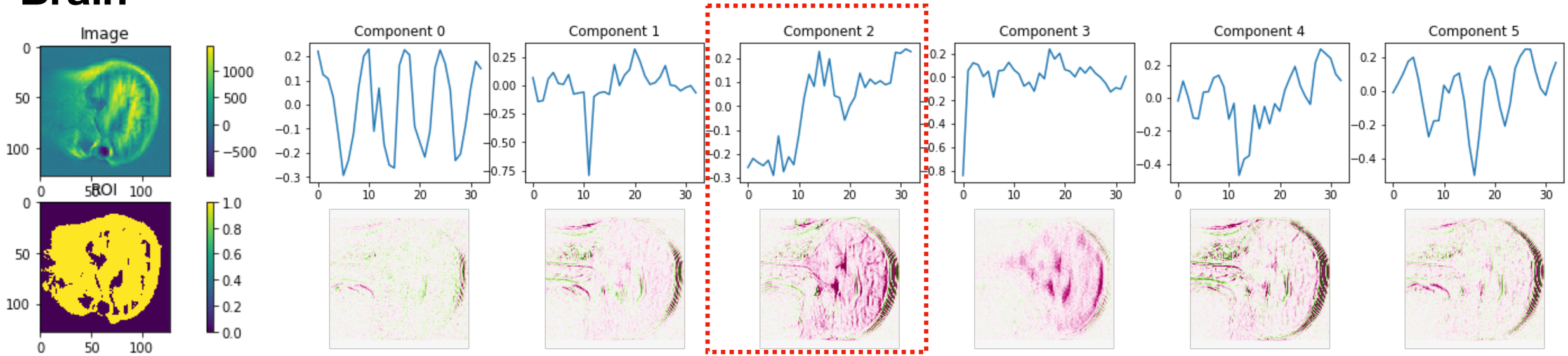

Lung

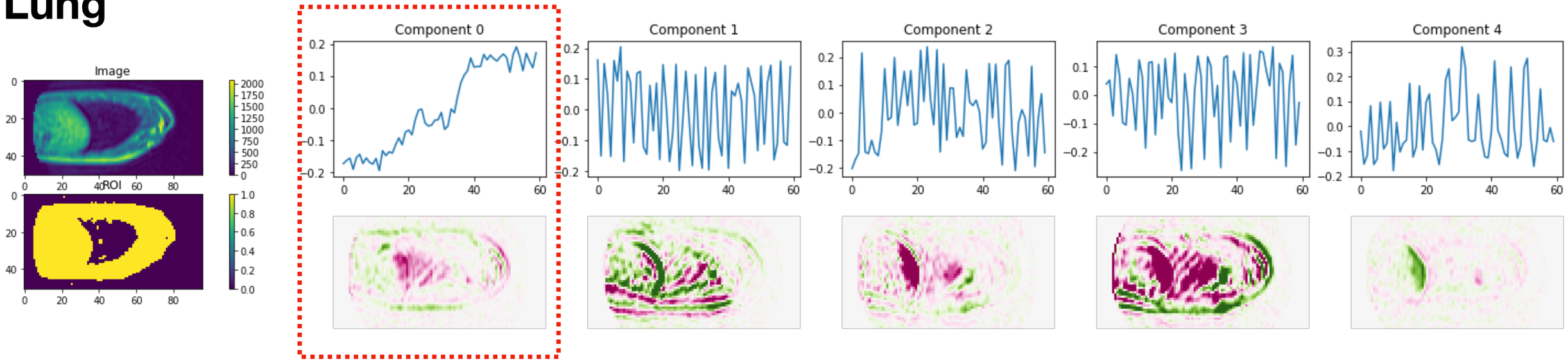

Data courtesy of Drs. Parker, O'Connor, & Lloyd from Manchester University

ACKNOWLEDGEMENTS

SAR Lab

- Dr. Stefan Reinsberg
- Jennifer Moroz
- Tammo Rukat
- Kelly McPhee
- Lauren Bains

AIM Lab

- Dr. Jennifer Baker
- Dr. Alastair Kyle
- Dr. Andrew. Minchinton

UBC MRI 7T Centre

- Dr. Piotr Kozlowski
- Andrew Yung

Funding provided by National Science and Engineering Research Council (NSERC) and the Canadian Institutes for Health Research (CIHR)

Summary

Development of model to quantify HPG kinetics (aPS and fPV)

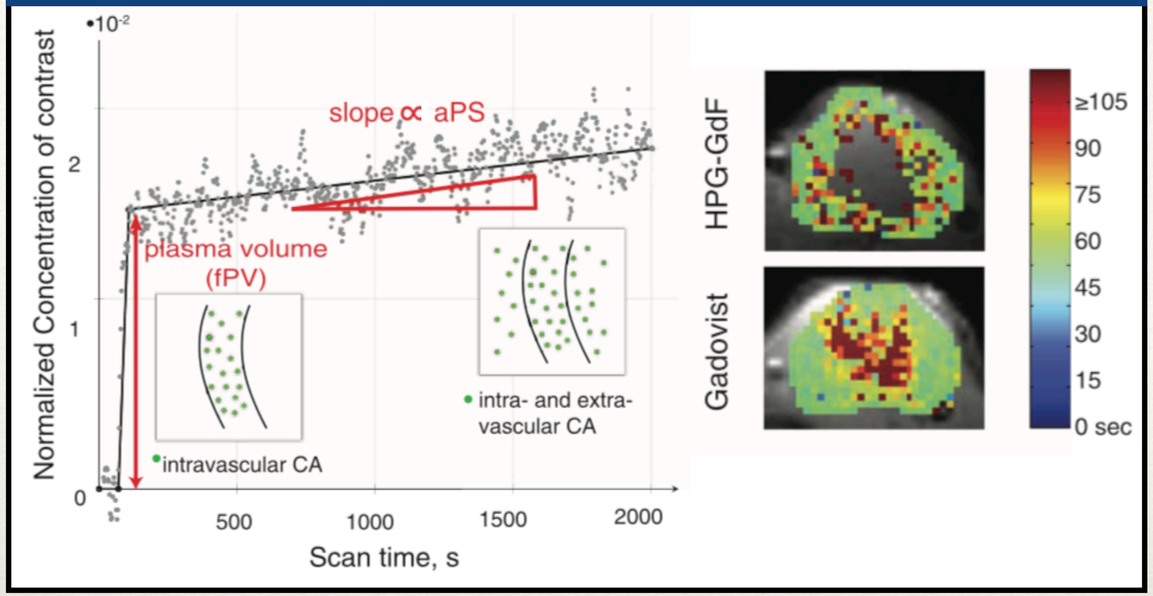

Treatment with B20 reduces permeability in tumours

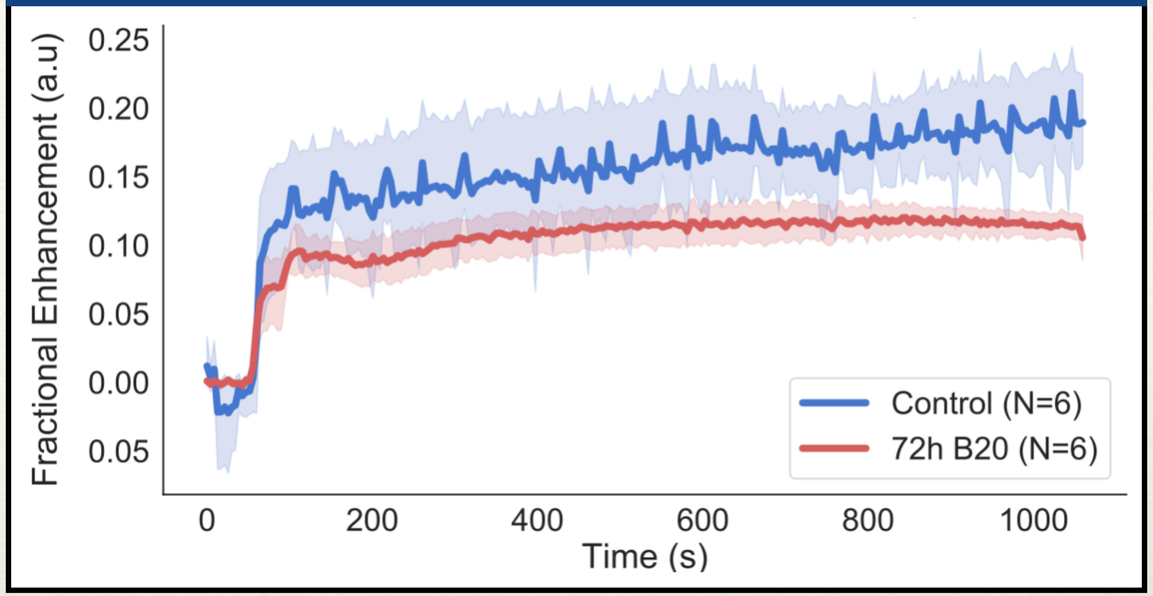

dOE-MRI to measure tumour oxygenation with just inhaled gas

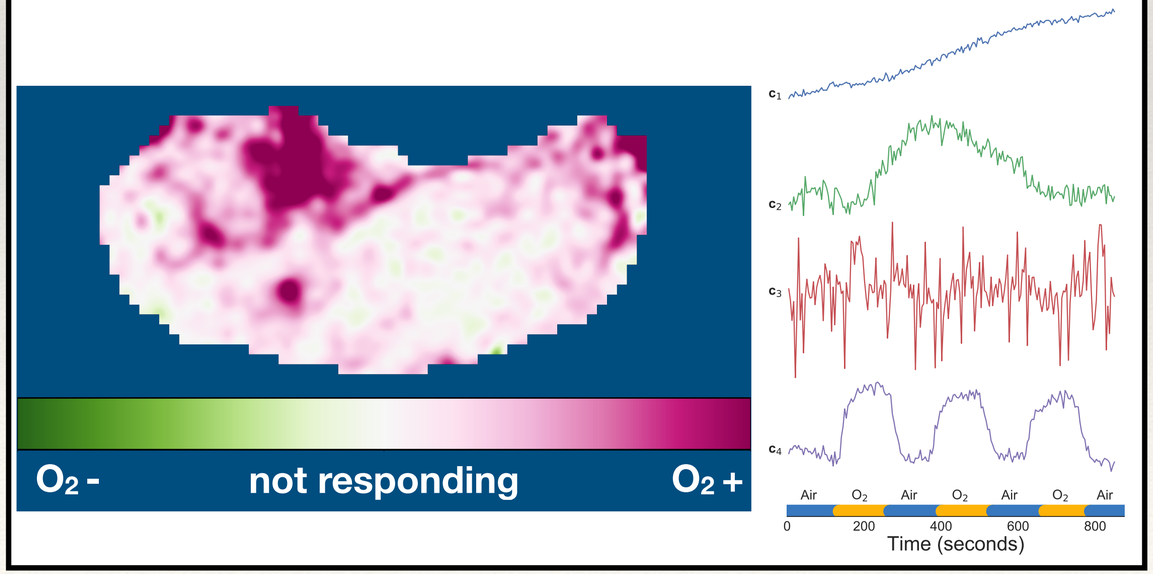

Treatment with B20 improves oxygenation in tumours

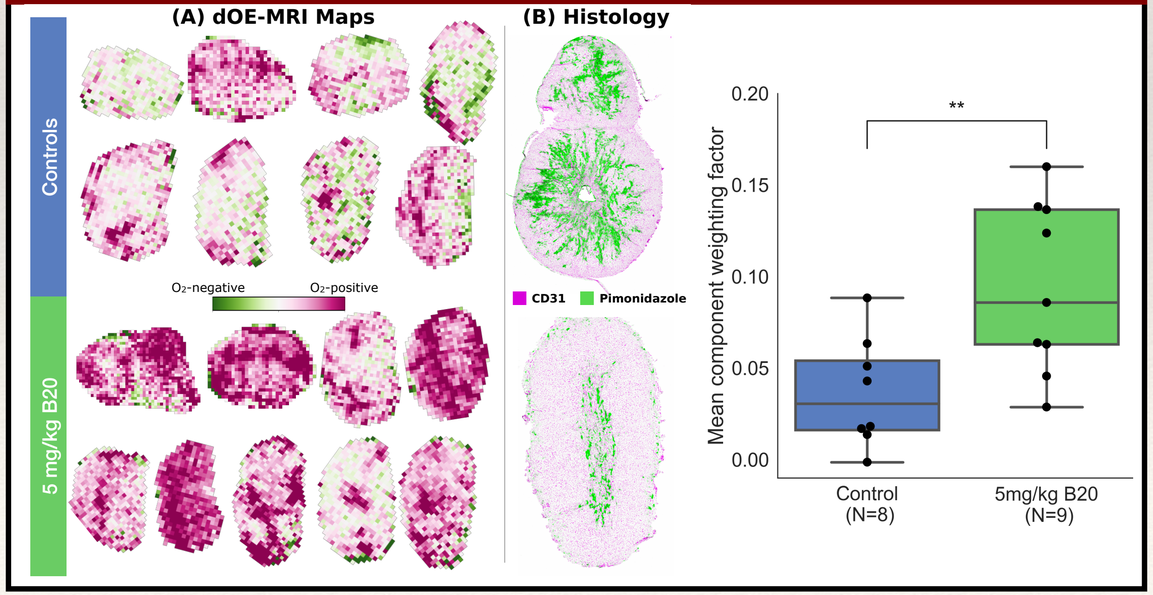

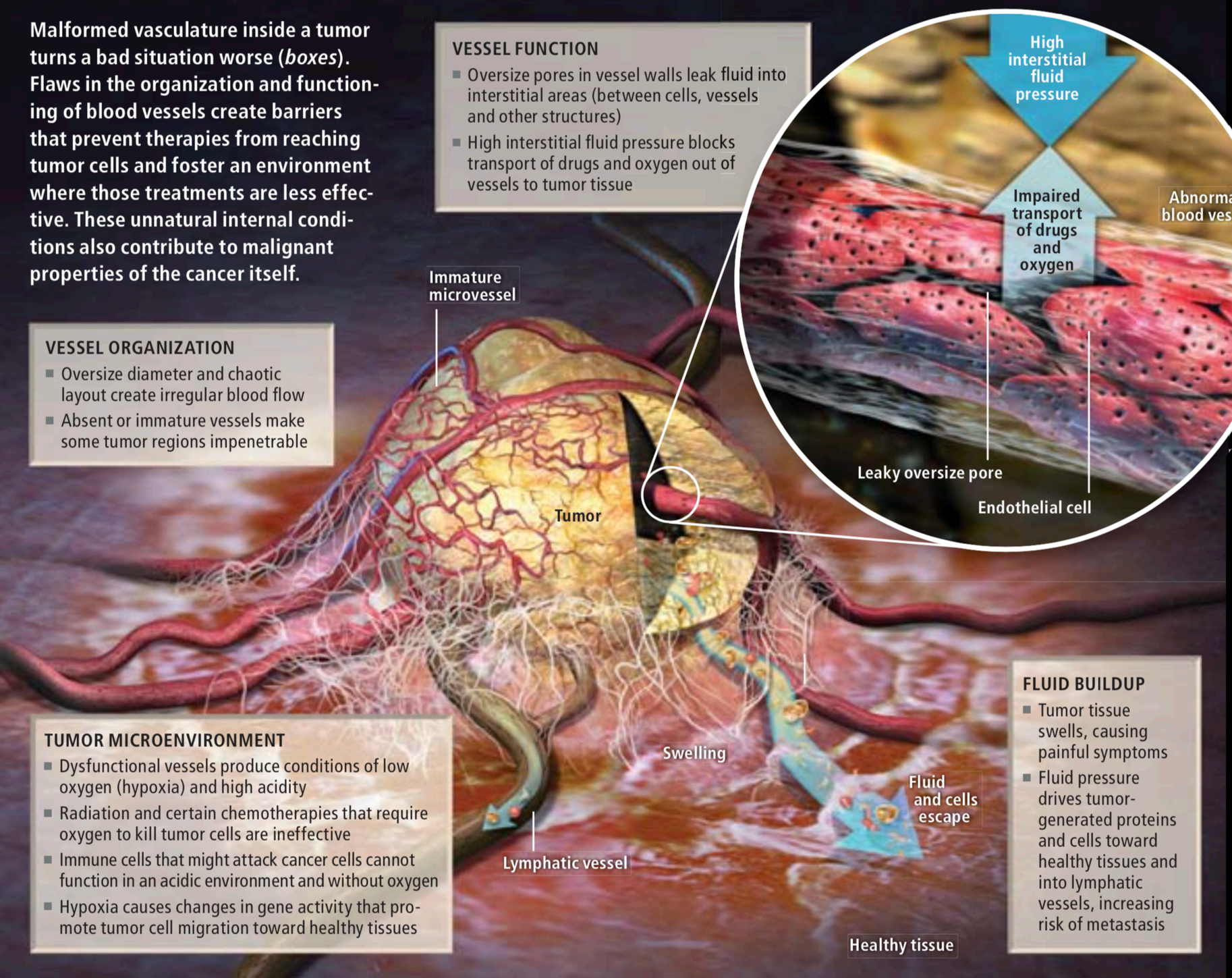

Consequence of abnormal vessels

- In this thesis, we focus on the hallmark of 'inducing angiogenesis'
- This hallmark is particularly well-suited for probing using non-invasive MR-based imaging techniques
- Drugs we use **bevacizumab** (Avastin) and **trastuzumab** (Herceptin)

Reference: Jain: Scientific American

Repeatability of dynamic oxygen-enhanced MRI

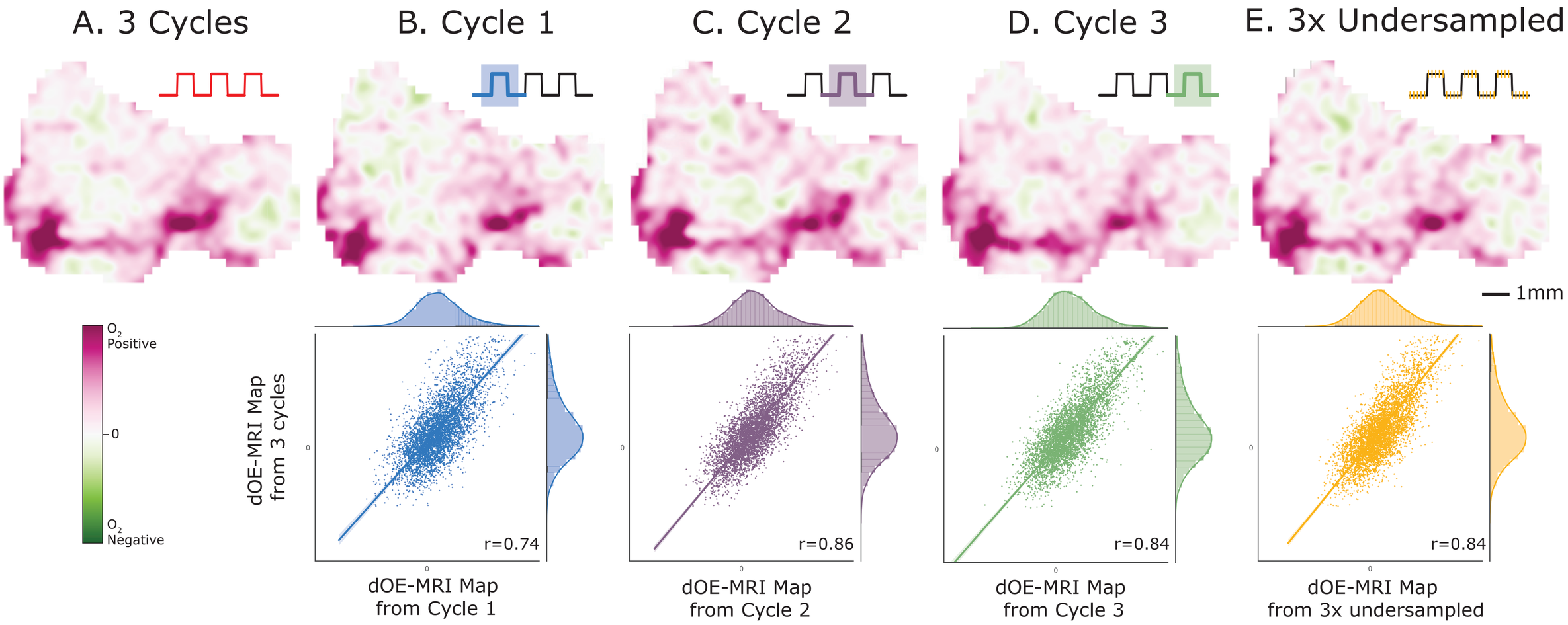

dOE-MRI is a repeatable measure of tumour oxygenation status and the similarity of the dOE-MRI map from the 3x under sampled time-series suggests there is room for higher efficiency

Introduction to OEMRI

Breathing 100% Oxygen increases Hb Saturation

Air | 100% Oxygen

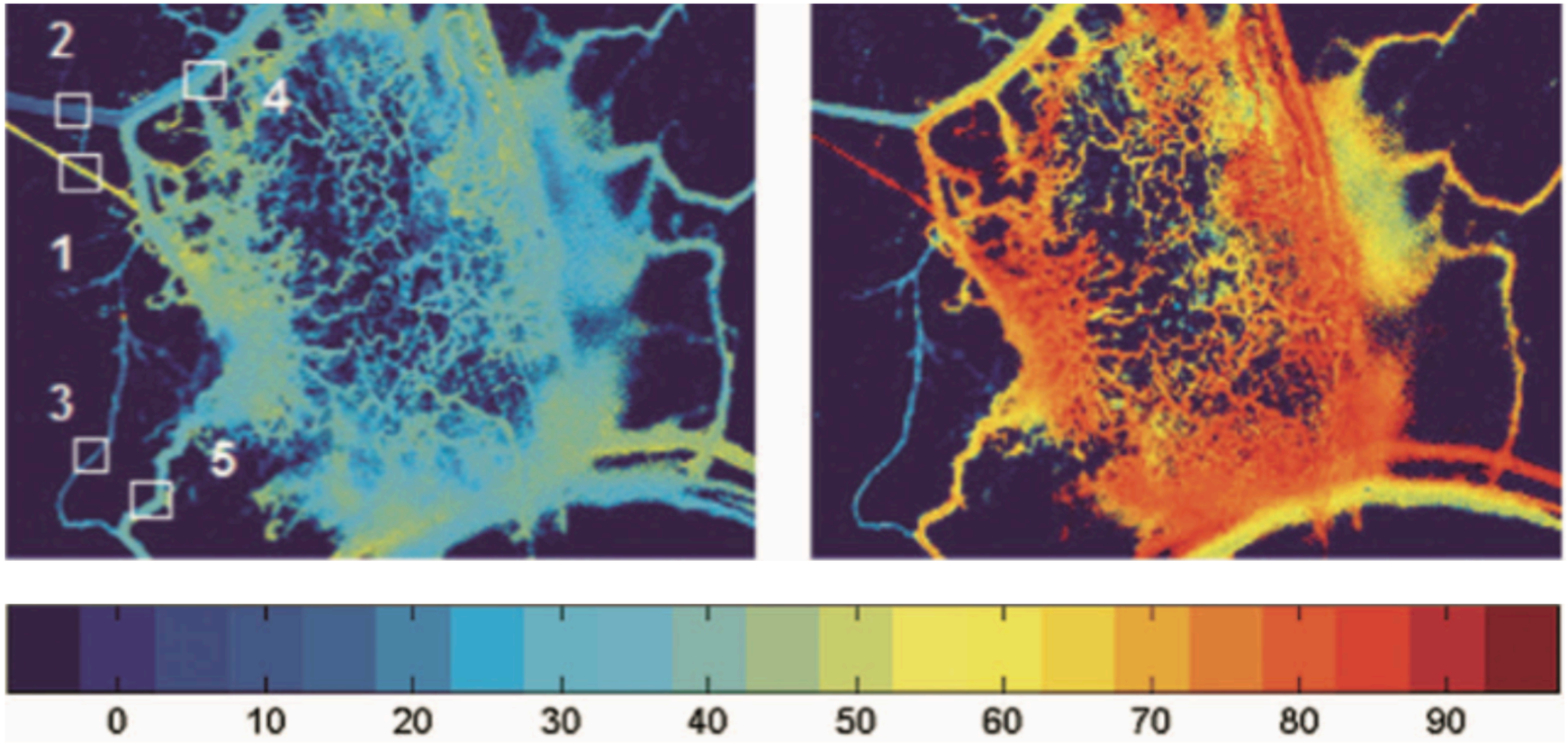

Spectral Imaging

- Images obtained via optical techniques in window chamber experiments
- Breathing 100% oxygen significantly increases oxygen saturation in some tumours
- Normal tissue vessels are largely unaffected by excess oxygen because of a high O_2 saturation

Sorg, B. S. et al. (2008). *Journal of Biomedical Optics*

Physiology of breathing

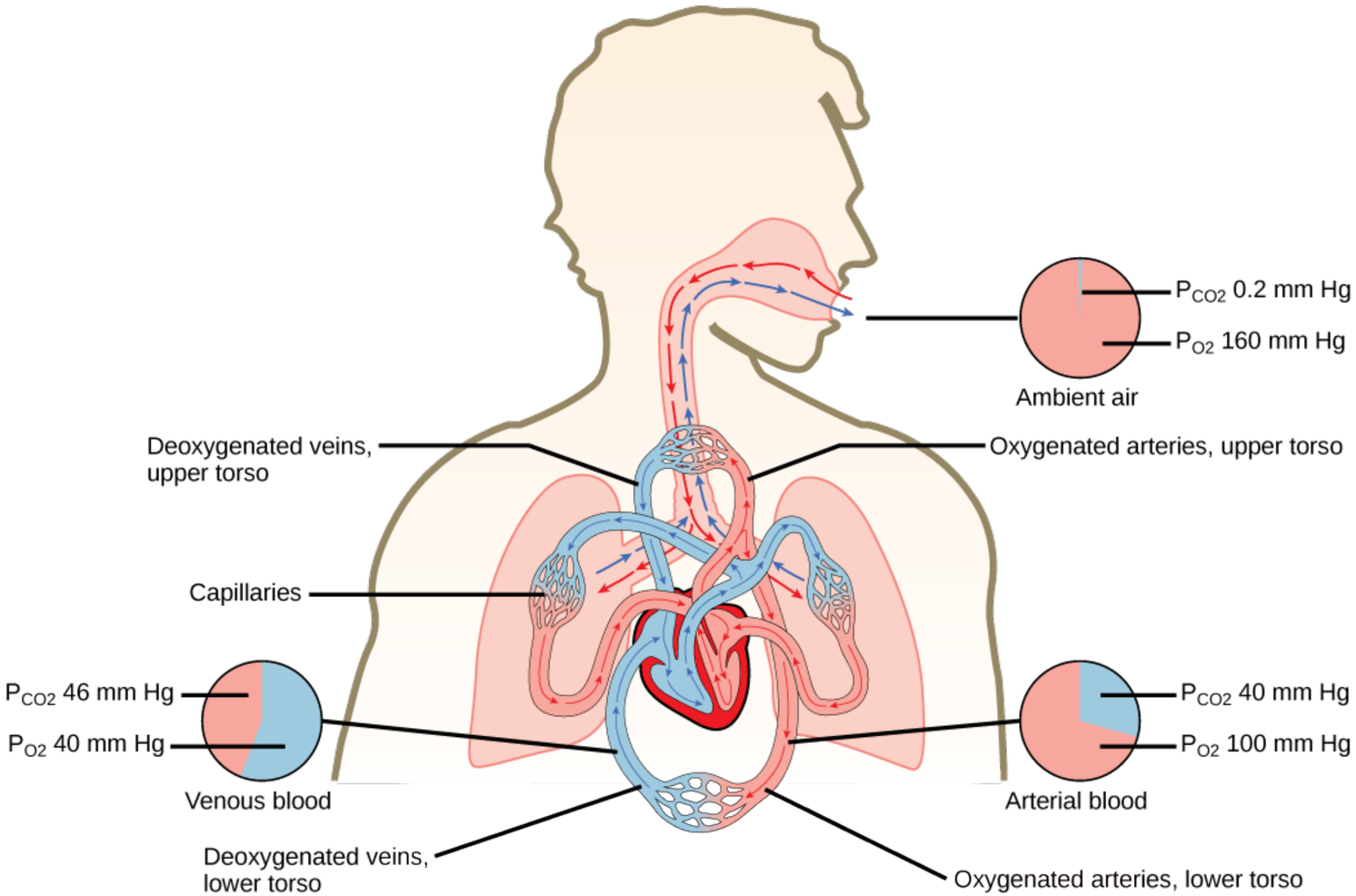

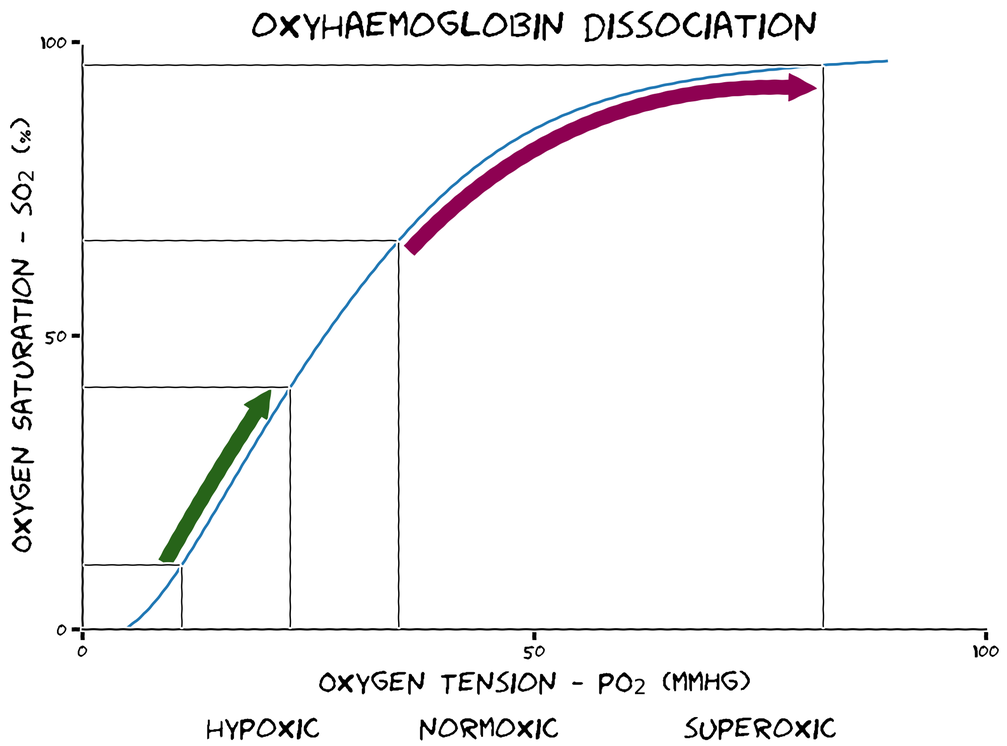

Introduction to OEMRI

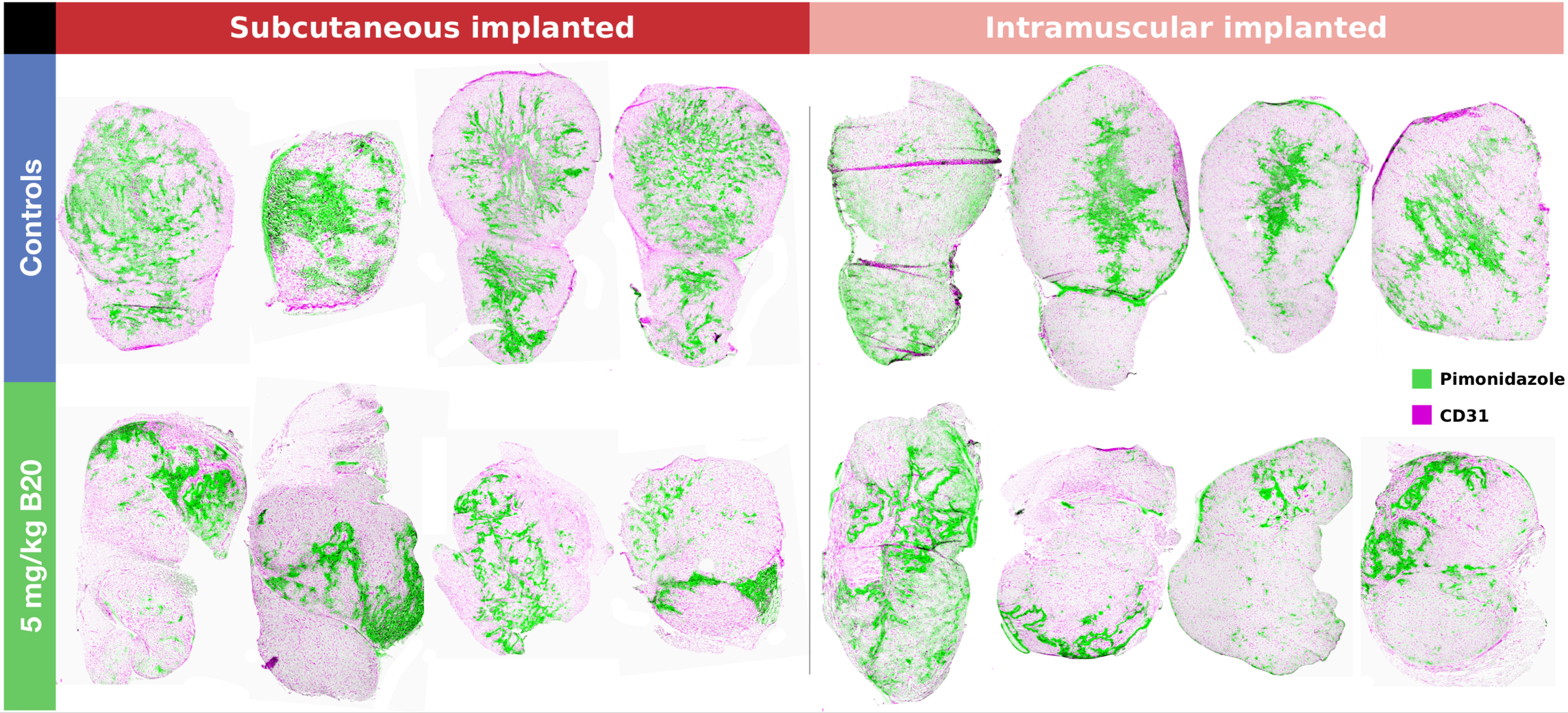

Introduction to OEMRI

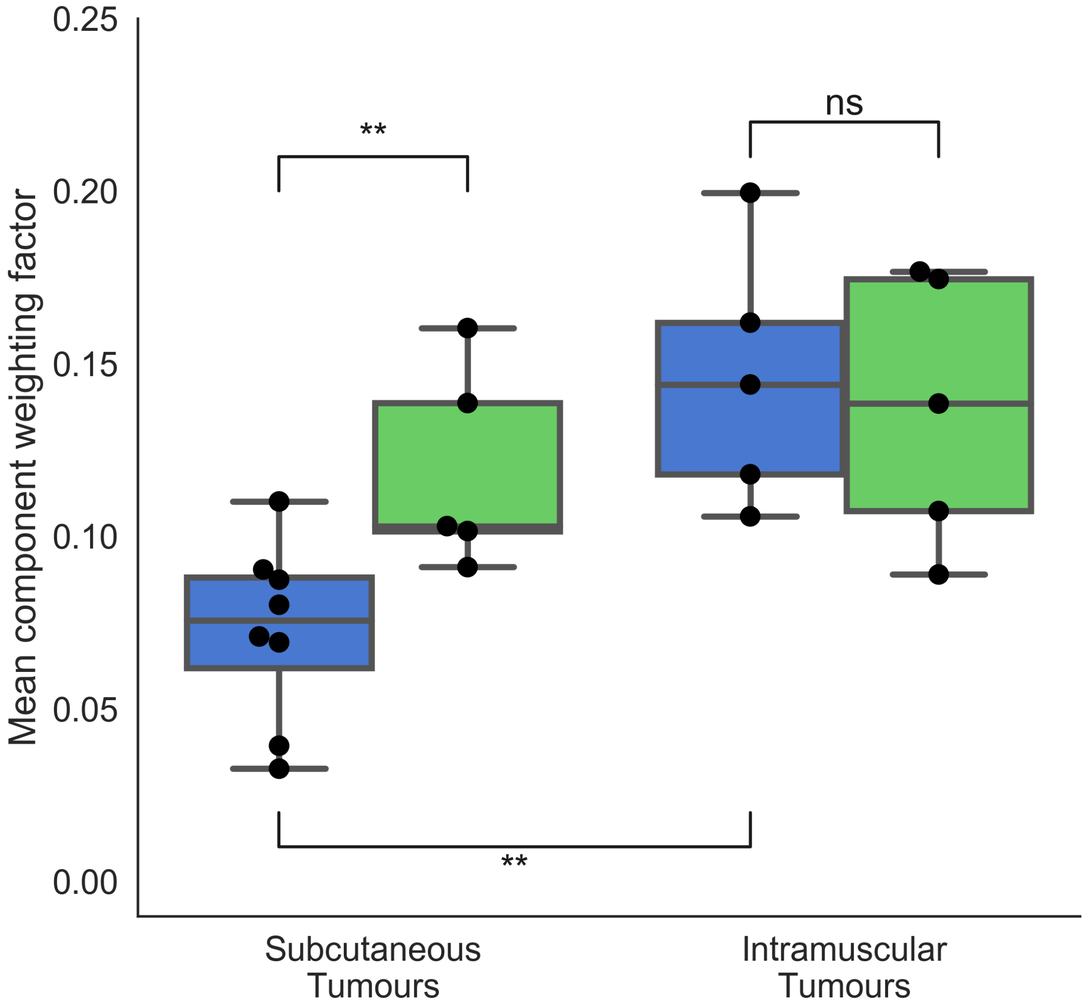

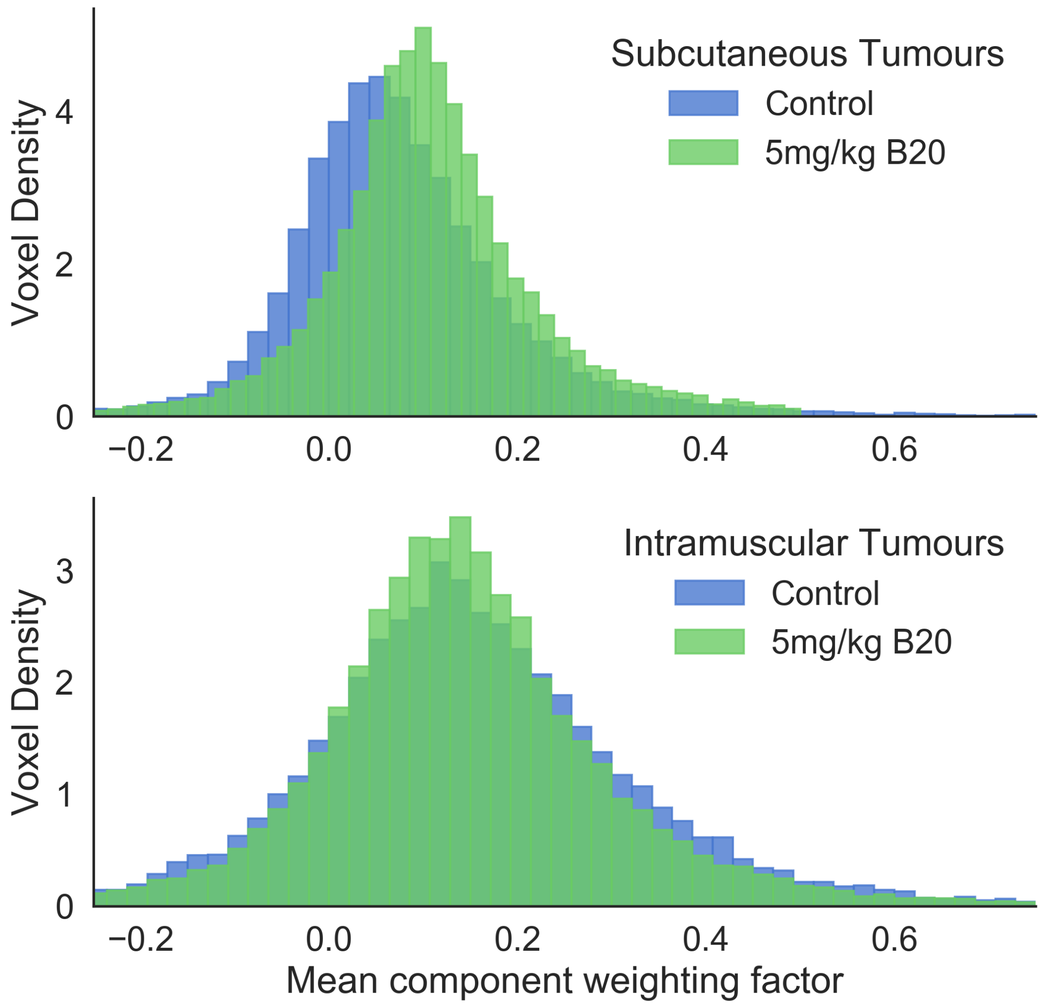

Control tumour

Tumour treated with DC101

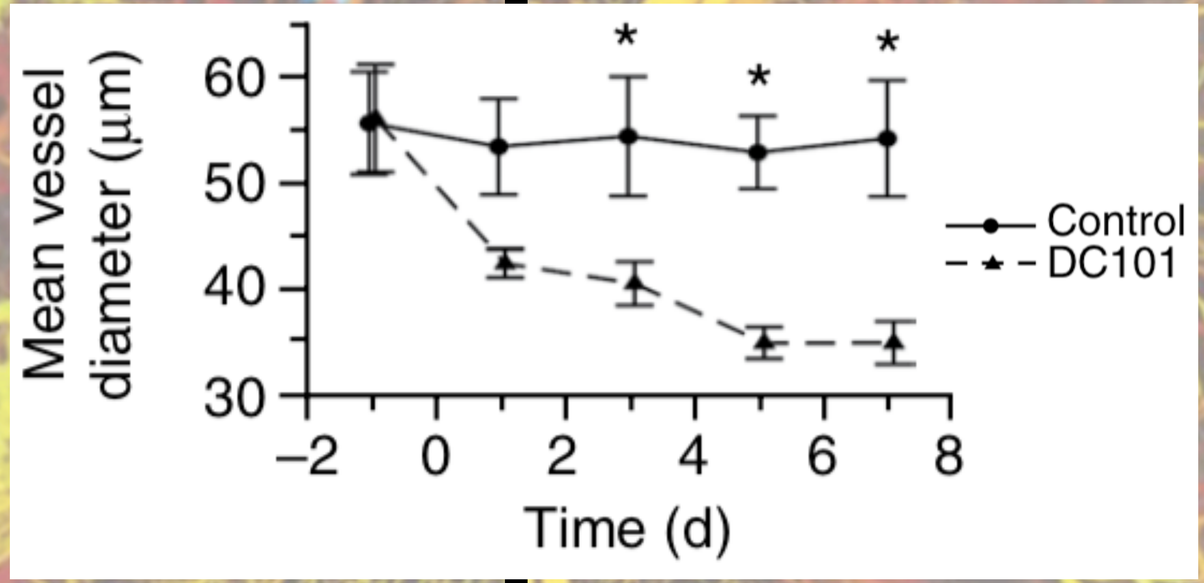

500 µm

Reference: Vakoc

Quantifying kinetics of HPG

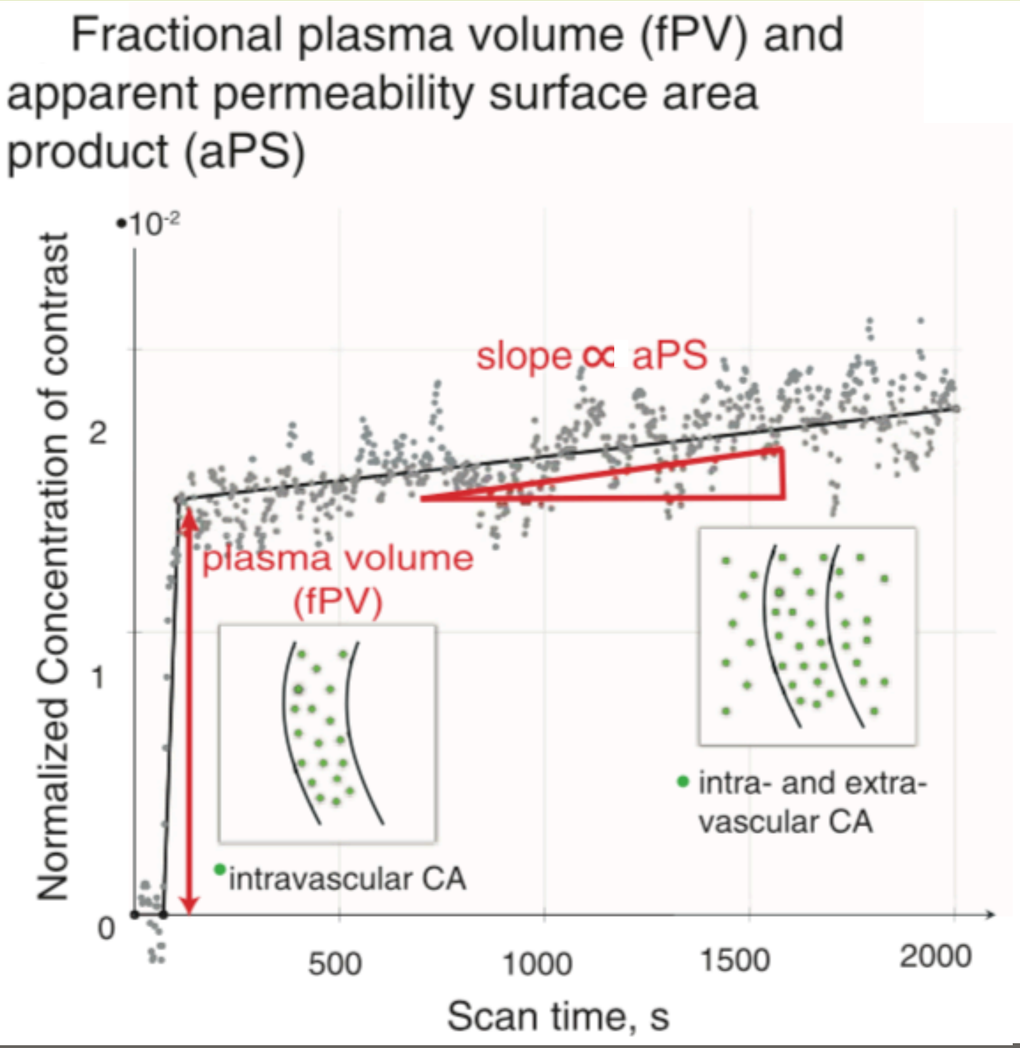

A two-parameter (aPS and fPV) linear model was applied to the HPG-GdF contrast kinetics.