ACP
American College of Physicians

Principles and Practice of

HOSPITAL MEDICINE

SECOND EDITION

Mc Graw Hill Education

SYLVIA McKEAN | DAN D. DRESSLER | JOHN J. ROSS | DANIELLE SCHEURER

Principles and Practice of Hospital Medicine

Second Edition

Editors

Sylvia C. McKean, MD, SFHM, FACP
Deputy Editor for Editorial Projects, UpToDate
Formerly:
Leave of absence:
Associate Professor of Medicine,
Harvard Medical School
Hospitalist
Brigham and Women's Hospital
Boston, Massachusetts

John J. Ross, MD, CM, FIDSA
Assistant Professor of Medicine
Harvard Medical School
Hospitalist Service
Brigham and Women's Hospital
Boston, Massachusetts

Daniel D. Dressler, MD, MSc, SFHM, FACP
Professor of Medicine
Director, Internal Medicine Teaching Services
Emory University Hospital
Associate Program Director
J. Willis Hurst Internal Medicine Residency Program
Co-Director, Semmelweis Society
Emory University School of Medicine
Atlanta, Georgia

Danielle B. Scheurer, MD, MSCR, SFHM
Chief Quality Officer and Hospitalist
Associate Professor of Medicine
Medical University of South Carolina
Charleston, South Carolina

New York Chicago San Francisco Athens London Madrid Mexico City
Milan New Delhi Singapore Sydney Toronto

Principles and Practice of Hospital Medicine, Second Edition

Copyright © 2017 by McGraw-Hill Education. All rights reserved. Printed in the United States of America. Except as permitted under the United States Copyright Act of 1976, no part of this publication may be reproduced or distributed in any form or by any means, or stored in a data base or retrieval system, without the prior written permission of the publisher. Previous edition copyright © 2012 by The McGraw-Hill Companies, Inc.

1 2 3 4 5 6 7 8 9 DOW 21 20 19 18 17 16

ISBN 978-0-07-184313-3
MHID 0-07-184313-2

This book was set in Myriad pro by Cenveo® Publisher Services.
The editors were Amanda Fielding and Kim J. Davis.
The production supervisor was Richard Ruzycka.
Project management was provided by Vastavikta Sharma, Cenveo Publisher Services.
The designer was Alan Barnett; the cover designer was Dreamit, Inc.

RR Donnelley was printer and binder.

Library of Congress Cataloging-in-Publication Data

Names: McKean, Sylvia C., editor. | Ross, John J. (John James), 1966-editor. | Dressler, Daniel D., editor. | Scheurer, Danielle, editor.
Title: Principles and practice of hospital medicine / editors, Sylvia C. McKean, John J. Ross, Daniel D. Dressler, Danielle B. Scheurer.
Description: Second edition. | New York : McGraw-Hill Education Medical, [2017] | Includes bibliographical references and index.
Identifiers: LCCN 2016022668 (print) | LCCN 2016023825 (ebook) | ISBN 9780071843133 (hardcover : alk. paper) | ISBN 0071843132 (hardcover : alk. paper) | ISBN 9780071843140 (ebook)
Subjects: | MESH: Hospital Medicine—methods | Hospitalization | Inpatients | Hospitalists Classification: LCC RA972 (print) | LCC RA972 (ebook) | NLM WX21 | DDC 362.11—dc23
LC record available at https://lccn.loc.gov/2016022668

McGraw-Hill Education books are available at special quantity discounts to use as premiums and sales promotions, or for use in corporate training programs. To contact a representative, please visit the Contact Us pages at www.mhprofessional.com.

CHAPTER 236

Pleural Diseases

Carlos E. Kummerfeldt, MD
Nicholas J. Pastis, MD
John T. Huggins, MD

1. When does a pleural effusion require drainage?
2. Why make the distinction between transudates and exudates?
3. How does the pleural fluid analysis assist in guiding your differential diagnosis?
4. When is a chest tube placement indicated?
5. When should a pulmonary consultation be obtained?

EPIDEMIOLOGY

The seven leading causes of pleural effusions in the United States, in descending order include: (1) congestive heart failure; (2) bacterial pneumonia; (3) malignancy; (4) pulmonary embolism; (5) viral disease; (6) postcoronary artery bypass surgery; and (7) cirrhosis with ascites. Pneumothorax in the hospitalized patient is most commonly found in (1) blunt trauma (35%); (2) transthoracic needle aspiration biopsies (25%); (3) pleural biopsies (8%); (4) transbronchial lung biopsies (6%); (5) mechanically ventilated patients (4%); (6) thoracentesis (2%); and (7) central line insertions (1%-2%). Spontaneous pneumothorax occurs in about 15,000 cases per year in the United States: primary spontaneous pneumothorax occurs in adults with no underlying lung disease, whereas secondary spontaneous pneumothorax occurs in older adults with underlying lung disease, most commonly with chronic obstructive pulmonary disease.

PLEURAL EFFUSIONS

A thoracentesis should be performed in most patients with a pleural effusion (Table 236-1). Thoracentesis should be performed in patients with likely heart failure if the pleural effusion is unilateral, if one side is greater than the other, or if there is suspicion for a dual diagnosis. The major risks and complications of thoracentesis include the following: (1) pneumothorax; (2) bleeding; (3) infection; and (4) procedural related pain. There are no evidence based guidelines in patients with coagulopathies, and there are reports of thoracentesis being performed in patients with an elevated international normalized ratio, uremia, thrombocytopenia or on oral antiplatelet or anticoagulation therapies. The benefits of correcting coagulopathy with transfusions or by withholding antiplatelet or anticoagulation medications should be weighed against the risks in the individual patient and should always be discussed with the patient. Ultrasound should be performed in all patients undergoing thoracentesis to less the risk of complications associated with a blind tap. Ultrasound can identify the pleural fluid and other underlying anatomical structures, estimate the size of the effusion, and determine the presence of underlying septations or complexity that may indicate the presence of loculations (Figure 236-1) (see Chapter 124 [Thoracentesis]).

■ PLEURAL FLUID ANALYSIS

Pleural fluid analysis is essential to determine the cause of the effusion. The hospitalist should familiarize themselves with the pleural fluid tests routinely ordered and the diagnostic clues they provide. The pleural fluid appearance, color, and even its smell may provide clues as to the diagnosis. Table 236-2 shows the differential diagnosis based on the appearance of the fluid. The following tests should always be obtained: protein, lactate dehydrogenase (LDH), pH, glucose, white cell count and differential, cytology and cultures. Other fluid tests that may assist in confirming a suspected diagnosis in selected patients include fluid amylase, triglyceride, cholesterol, adenosine deaminase (ADA), rheumatoid factor, and antinuclear antibody. Tables 236-3 through 236-5 summarize the use of these tests to narrow the differential diagnosis.

■ LIGHT'S CRITERIA

Distinction between whether the effusion is an exudate or transudate these two categories may assist in determining the etiology

TABLE 236-1 Indications for Thoracentesis

1. Pleural effusion size ≥1 cm on chest radiography, ultrasound or computed tomography (CT)
2. Fever
3. Pleuritic chest pain
4. Dyspnea
5. Suspected hospital acquired infection
6. Evidence of loculation, complexity, or septations on imaging
7. Evidence of mediastinal shift, complete hemithorax opacification or large effusion on imaging

of the effusion (Figure 236-2). Light's criteria is a set of three characteristics that compare the following:

1. pleural fluid to serum protein ratio >0.5;
2. pleural fluid to serum lactate dehydrogenase >0.6; or
3. pleural fluid LDH > two-thirds of the upper normal limit for serum using an "or" rule.

The pleural fluid is classified as an exudate if one of the three criteria is met. The pleural fluid is a transudate if none of the three criteria are met.

Light's criteria may misclassify some transudates as exudates. This commonly occurs in patients with pleural effusions due to congestive heart failure that have received diuretic therapy. In this setting, correct classification may be possible by applying the serum to pleural fluid protein and albumin gradients. If the difference between the serum to pleural fluid protein is >3.1 g/dL or the serum to pleural fluid albumin is >1.2 g/dL, then the effusion is reclassified as a transudate (see Figure 236-2).

Transudates occur as a consequence of changes in the hydrostatic or oncotic forces within the pleural space. The resulting pleural fluid is low in protein and LDH content. The two most commonly encountered transudates in the hospital are congestive heart failure and liver cirrhosis with ascites resulting in hepatic hydrothorax.

■ HEART FAILURE

Systolic and diastolic heart failure represents the most common cause of pleural effusion encountered in the hospital. Fluid accumulates in the pleural space by moving from the lung interstitium across leaky mesothelial cells. The triad of clinical signs and symptoms (dyspnea, orthopnea, lower-extremity edema), bilateral pleural effusions, and cardiomegaly on chest radiography establish the diagnosis. The majority of these effusions resolve with diuretic therapy and do not require thoracentesis for diagnosis (see Chapter 129 [Heart Failure]).

A thoracentesis is indicated if no cardiomegaly is appreciated on chest radiography, if the effusion is unilateral, or if the patient meets one of the criteria listed in Table 236-1. Thoracentesis may be indicated if dyspnea does not resolve with diuretic therapy after a few days or the effusion is large or does not appear to resolve. Thoracentesis should be performed if another concomitant cause for an effusion (dual diagnosis) is suspected or if one of the effusions is significantly greater than the other. The hospitalist should keep in mind that about 80% of patients have bilateral effusions, 15% to 20% a unilateral right side effusion, and only 5% to 10% have a unilateral left side effusion. Pulmonary consultation should be considered in the above settings or if a patient presents with refractory

TABLE 236-2 Differential Diagnosis of Pleural Fluid Based on Appearance

Fluid Appearance	Differential Diagnosis
Light yellow	Transudate Urinothorax (smells like urine) Exudate
Dark yellow or serous	Exudate
Turbid	Parapneumonic effusion, chylothorax, cholesterol effusion
Purulent	Empyema (putrid smell)
Milky	Chylothorax
Bloody	Parapneumonic, malignancy, hemothorax
Clear or watery	Cerebrospinal fluid leak, peritoneal dialysis, extravascular migration of central venous catheter
Satin sheen	Cholesterol effusion

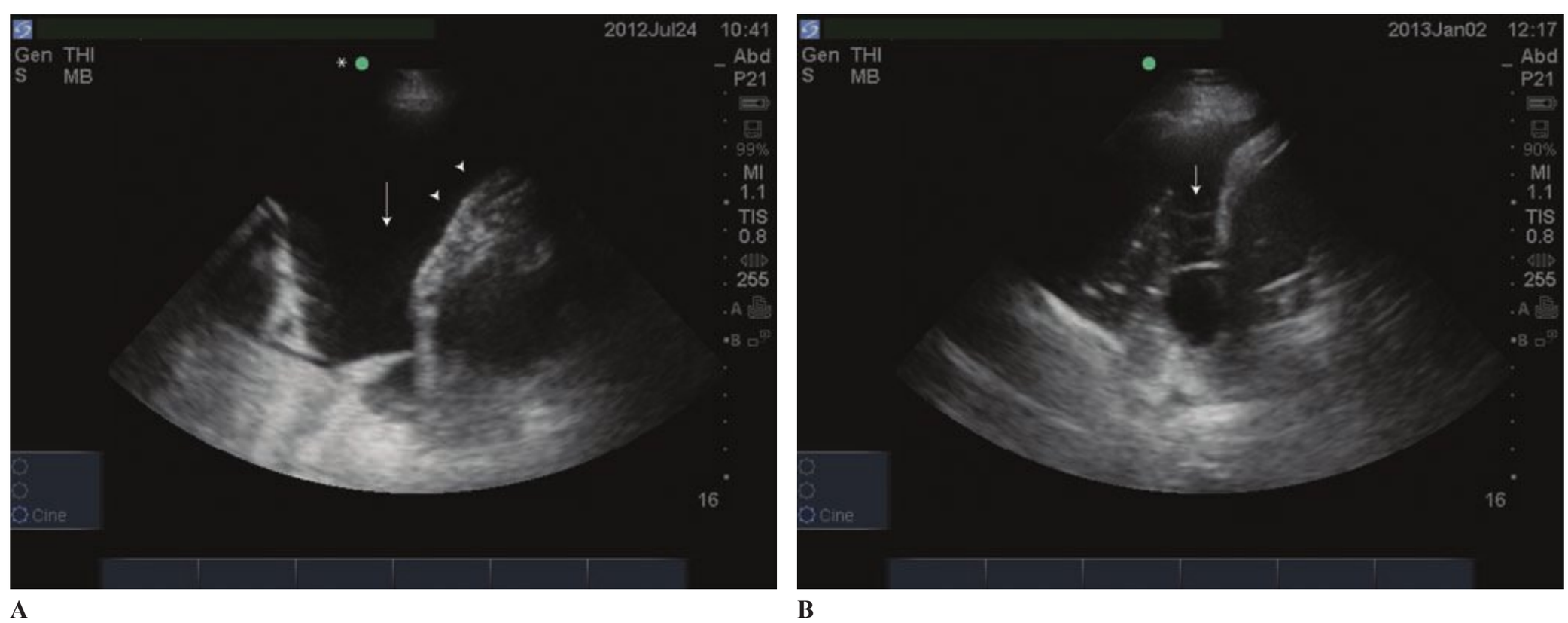

A B

Figure 236-1 Ultrasound images show a large simple pleural effusion and a complex pleural effusion with septations. (A) Large simple anechoic pleural effusion causing atelectasis of the right lower lobe (arrow). The bright white line on the right (arrowheads) represents the diaphragm; the atelectatic lung is on the left and lower parts of the image. (B) Complex pleural effusion with septations demonstrating loculations and complexity (arrow). The small lines between the diaphragm and consolidated lung represent septations. (Images courtesy of John T Huggins, MD.)

TABLE 236-3 Routine Pleural Fluid Tests Used for Analyzing Pleural Fluid

Test	Comment
Protein	Elevated in exudates; >5.0 g/dL associated with tuberculosis; very low <0.5 g/dL seen in urinothorax, CSF leak, or extravascular migration of central venous catheter
Lactate dehydrogenase	Elevated in exudates; if increasing with serial thoracentesis, indicates worsening degree of pleural space inflammation
pH*	Low pH >7.2-7.3 associated with: (1) complicated parapneumonic effusion; (2) esophageal rupture; (3) rheumatoid and lupus pleuritis; (4) tuberculosis; (5) malignancy; (6) hemothorax; (7) urinothorax
Glucose	Low glucose typically <60 mg/dL associated with: (1) parapneumonic effusion; (2) malignancy; (3) tuberculosis; (4) rheumatoid pleuritis (lupus has normal glucose); (5) hemothorax. When <40 mg/dL and presence of infection, chest tube insertion is indicated
Cytology	Positive for malignancy in up to 60%; yield increases with repeat thoracentesis
Culture	Yield increases when using blood culture bottles (aerobic and anaerobic); mycobacterial and fungal cultures useful when undiagnosed exudate present

*The pH should ideally be measured in a heparinized syringe, placed on ice if not immediately processed and analyzed in a blood gas machine.

symptomatic pleural effusions despite optimal diuretic therapy. In such extreme cases, an indwelling pleural catheter or talc pleurodesis may be considered for palliative measures.

■ HEPATIC HYDROTHORAX

Hepatic hydrothorax is the second most commonly encountered cause of a transudate in the hospitalized patient. It is estimated that about 6% of patients with cirrhosis develop this complication. About 80% of the effusions develop on the right side, 17% on the left, and 3% occur bilaterally. Ascitic fluid moves via diaphragmatic pores and defects into the pleural space resulting in fluid accumulation. In addition, the negative pressure gradient between the pleural and peritoneal cavities favors movement of fluid into the pleural space. Hepatic hydrothorax may occur in patients without ascites if all the ascites has moved into the pleural cavity.

Thoracentesis should always be performed to exclude spontaneous bacterial pleuritis, defined as the presence of a positive bacterial culture, a pleural fluid neutrophil count >250 cells/μL, and absence of empyema or pneumonia with parapneumonic effusion. Culture negative spontaneous bacterial pleuritis occurs if pleural fluid cultures do not grow any microorganisms and the fluid neutrophil count is >500 cells/μL. A diagnostic thoracentesis should be performed in all cases of ascites and hepatic hydrothorax in patients presenting with fever, even when spontaneous bacterial peritonitis is excluded, due to the presence of hematogenous spread. Antibiotic therapy is the treatment of choice. Chest tube insertion or indwelling pleural catheters should be avoided as they result in persistent fluid drainage and protein loss that leads to malnourishment and higher rates of infection.

Definitive treatment of hepatic hydrothorax should target control of the ascites in consultation with both pulmonary and liver specialists (see Chapter 160 [Cirrhosis and Its Complications]).

TABLE 236-4 Differential Diagnosis Based on the Pleural Fluid Cell Count Differential

Neutrophil Predominance	Lymphocyte Predominance	Eosinophil Predominance
Parapneumonic	Tuberculosis	Pulmonary embolism
Empyema	Malignancy	Asbestos exposure
Pulmonary embolism	Lymphoma	Hemothorax
Acute pancreatitis	Sarcoidosis	Drug induced
Intra-abdominal abscess	Rheumatoid pleuritis	Fungal infections
Bilio-pleural fistula	Postcoronary artery bypass surgery	Eosinophilic granulomatosis with polyangiitis (formerly Churg-Strauss)
	Uremia	Parasite infections
	Chylothorax	

TABLE 236-5 Special Pleural Fluid Tests Used for Analyzing Pleural Fluid

Test	Comment
Albumin	Useful when suspected transudate is misclassified as exudate (see Figure 236-2); if SF-A gradient >1.2 g/dL, re-classify effusion as transudate
Amylase	Elevated in: (1) esophageal perforation; (2) pancreatitis (3) pancreatico-pleural fistulas; (4) malignancy
Triglyceride	Elevated to >110 mg/dL in chylothorax
Cholesterol	Elevated to >250 mg/dL in cholesterol effusion due to tuberculosis, rheumatoid pleuritis, trauma, or parasitic infection
Hematocrit	Hemothorax if fluid to peripheral blood hematocrit ratio >50%
Adenosine deaminase	Elevated in patients with tuberculosis; tuberculosis excluded if <40 U/L
Rheumatoid factor	May be elevated to ≥1:320 in rheumatoid pleuritis
Antinuclear antibody	Elevated to >1:40 in lupus pleuritis
Creatinine	Elevated to higher level than serum in urinothorax

SF-A, serum to fluid albumin gradient.

■ OTHER TRANSUDATES

Less common transudates include nephrotic syndrome, urinothorax, peritoneal dialysis, trapped lung, myxedema, pericarditis, and cerebrospinal fluid leak (Table 236-6). Pulmonary consultation should be sought whenever the cause of a transudate remains unclear.

■ EXUDATES

Exudates occur as a consequence of pleural membrane inflammation and disruption. The resulting pleural fluid is high in protein and LDH content. Exudates result from disruption of the pleural membranes due to inflammation (parapneumonic effusions), direct injury, or invasion as with malignancy (Table 236-7). Initial diagnosis will not establish a diagnosis in about 20% of exudates. When the

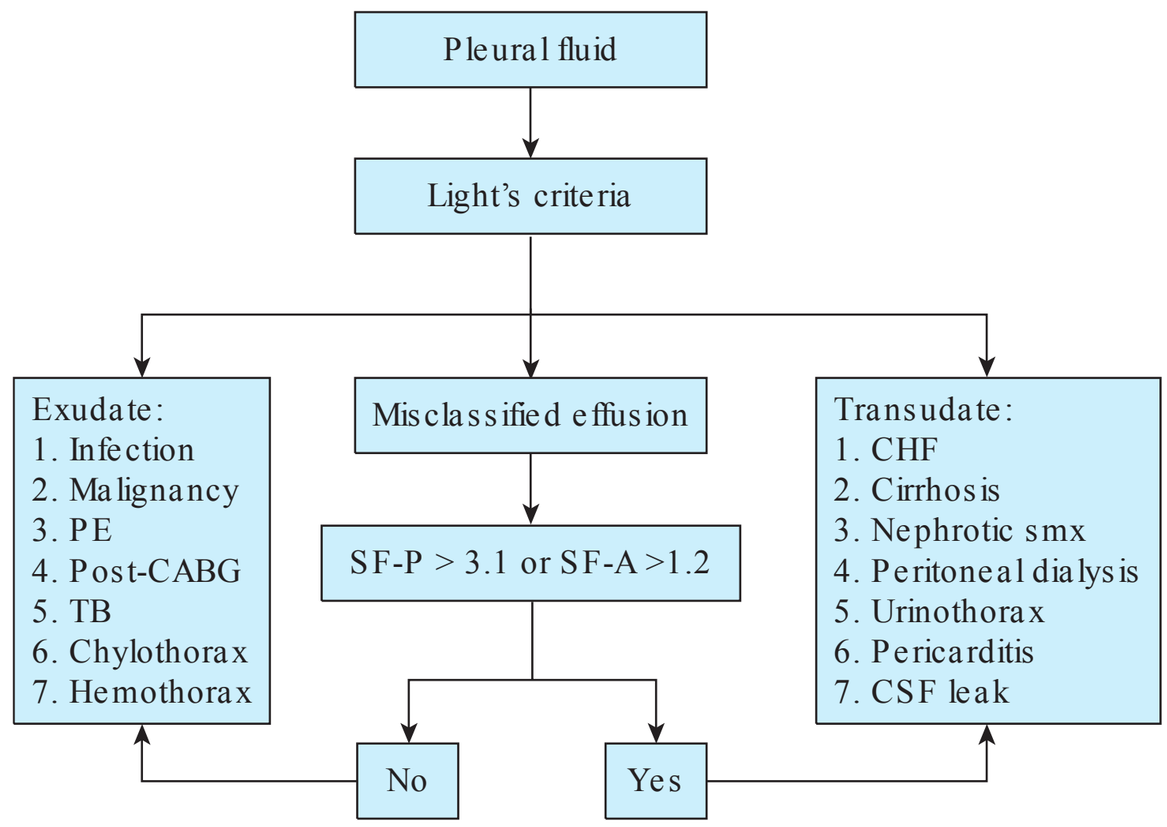

Figure 236-2 Approach to the hospitalized patient with a pleural effusion.
CABG, coronary artery bypass graft; CHF, congestive heart failure; CSF, cerebrospinal fluid; SF-A, serum to pleural fluid albumin gradient; SF-P, serum to pleural fluid protein gradient; smx, syndrome; TB, tuberculosis.

exudate does not resolve spontaneously or if malignancy is being considered, pulmonary consultation should be obtained to assist with appropriate workup that may include pleural biopsy by either medical or surgical thoracoscopy.

■ PARAPNEUMONIC EFFUSIONS

About 40% of bacterial pneumonias are complicated by the development of a parapneumonic effusion. Three stages develop: (1) exudative; (2) fibrinopurulent; and (3) organized. During the first exudative stage, increased permeability in the visceral pleura results in pleural fluid formation characterized by high protein content but normal glucose, pH, and LDH. Bacterial invasion during the second fibrinopurulent stage results in leukocyte, bacteria and cell debris accumulation. Pleural fluid continues to accumulate, and fibrin deposits in the visceral and parietal pleura with resulting loculations. Anaerobic utilization of glucose results in a lower glucose and pH levels, and cell lysis results in increased LDH levels. During the third and final organized stage, pus formation occurs from cellular debris resulting in empyema formation and pleural thickening.

Unless the effusion is small in size (<1 cm when measured from the inner border of the chest wall), the majority of parapneumonic or suspected parapneumonic effusions require thoracentesis. Pleural fluid analysis will determine if chest tube drainage is required (see Figure 236-3). Complicated parapneumonic effusions and all empyemas require chest tube drainage. Pulmonary consultation is recommended when chest tube drainage is indicated for evaluation of intrapleural tissue plasminogen activator (t-PA) combined with DNase administration. Intrapleural t-PA with DNase has been shown to reduce hospital stay as well as surgical referrals. Surgical drainage via video-assisted thoracoscopic surgery (VATS) or open thoracotomy should be considered when there is ongoing sepsis, fever and infection despite appropriate antibiotics or chest tube drainage.

■ MALIGNANT EFFUSIONS

Malignant effusions represent the second most common cause of exudates after parapneumonic effusions, affecting about 200,000 persons per year in the United States. Most patients present with dyspnea, cough and less often chest pain. In order of frequency, the most common causes of tumors leading to development of malignant pleural effusion include: (1) lung, most commonly adenocarcinoma (38%); (2) breast (17%); (3) lymphoma (12%); (4) genitourinary (9%); (5) gastrointestinal (7%); other (7%) and unknown cause (10%).

Malignant effusions develop as a consequence of both an increased amount of fluid entry and a decreased amount of fluid exit from the pleural cavity. Factors that lead to an increased amount of fluid entry include: (1) direct pleural and pulmonary vessel invasion with increased permeability; (2) increased hydrostatic pressures due to venous obstruction; (3) increased vascular endothelial growth factor (VEGF) formation by some tumors; and (4) in some occasions, disruption of lymphatic vessels leading to chyle accumulation. Factors that lead to a decreased amount of fluid exit include: (1) lymphatic obstruction in the parietal pleura or mediastinal lymph nodes; (2) decreased intrapleural pressure from atelectasis formation; and (3) increased central venous pressure if underlying thrombosis is present.

Pleural fluid may demonstrate a serous appearing or bloody effusion. Fluid analysis varies but typically shows an elevated LDH due to a high cell turnover with lysis, a differential showing lymphocyte predominance, and glucose and pH may be low. Fluid cytology may be positive in up to 60% of cases. If measured, amylase may be elevated in about 10% of the cases. A chylothorax may be present. If pleural fluid cytology is negative or indeterminate on initial thoracentesis and a malignant diagnosis is highly suspected, a repeat thoracentesis with cytology is recommended to increase the diagnostic yield. Pulmonary consultation should be sought at this time in order to assist with diagnosis.

Malignant effusions are the most common cause of near complete hemithorax opacification on chest imaging (see Figure 236-4). Contralateral shift of the mediastinum usually indicates a large effusion rather than a large mass. If a large effusion does not result in contralateral mediastinal shift, then the lung may be unable to expand. Unexpandable lung or the inability of the lung to fully expand to the chest wall results from the following: (1) trapped lung; (2) visceral pleural inflammation or invasion causing lung entrapment; (3) endobronchial obstruction; and/or (4) chronic atelectasis. Tumor causing endobronchial obstruction and atelectasis may require bronchoscopy; visceral pleural thickening from direct tumor invasion can be better visualized via a contrast chest CT (see Figure 236-5).

The goal of therapy of malignant pleural effusions is directed toward palliation of symptoms. Due to rapid reaccumulation and symptom recurrence, repeated thoracentesis is not recommended in the majority of cases. A chest physician should be consulted to

TABLE 236-6 Other Less Common Causes of Transudates

Cause	Characteristics	Imaging
Nephrotic syndrome	Due to decreased oncotic pressure from urine protein loss and increased intravascular hydrostatic pressure from salt retention	Usually bilateral effusions
Urinothorax	Due to renal obstruction resulting in retroperitoneal urine collection and drainage across pressure gradient into pleural cavity; creatinine level in pleural fluid higher than serum	Effusion on same side as obstruction
Peritoneal dialysis	Leakage of dialysate rich in glucose from peritoneal cavity through diaphragmatic defects into pleural space; high glucose and low protein fluid	Usually right sided; may be bilateral
Trapped lung	Old inflammation resulting in fibrous membrane with visceral pleural thickening that causes inability of lung to fully re-expand, increasing negative pressure within pleural space; pleural manometry recommended to establish diagnosis	Unilateral effusion; chest CT with air contrast shows visceral pleural thickening
Myxedema	Forms from decreased lymphatic drainage	Bilateral; concomitant pericardial effusion many times
Constrictive pericarditis	Increased pulmonary and systemic capillary pressures result in fluid formation	Bilateral; may be unilateral
Cerebrospinal fluid leak	Fistula formation between CSF and pleural cavity from surgery, trauma, or shunts; low protein and LDH in fluid; measurement of β_2-transferrin virtually diagnostic	Unilateral

CT, computed tomography; LDH, lactate dehydrogenase.

recommend the most appropriate treatment, based on the individual circumstances:

1) Breast, small cell lung cancer and lymphoma are chemosensitive and respond well to chemotherapy.
2) Talc pleurodesis via chest tube or thoracoscopy may be considered if no evidence of unexpandable lung.
3) Indwelling pleural catheter insertion (such as PleurX® catheters) if unexpandable lung present; about 50% to 60% of effusions resolve after indwelling catheter has been inserted, with subsequent catheter removal and no evidence of recurrence.
4) Thoracic duct ligation or a pleuroperitoneal shunt with pump system is recommended in the presence of chylothorax; indwelling pleural catheters may result in protein and lymphocyte depletion with subsequent malnourishment and infections.

■ PULMONARY EMBOLISM

It is estimated that about 30% of patients with pulmonary embolism have an associated pleural effusion. The effusion may be unilateral or bilateral. Computed tomography imaging with contrast can identify segmental or subsegmental filling defects consistent with embolic disease. Treatment of the pulmonary embolism results in resolution of the associated effusion (see Chapter 115 [Advanced Cardiothoracic Imaging]).

TABLE 236-7 Causes of Pleural Effusions

Exudates	Transudates
Common	Common
Parapneumonic	Congestive heart failure
Malignancy	Liver cirrhosis
Less common	Less common
Tuberculosis	Nephrotic syndrome
Pulmonary embolism	Urinothorax
Postcoronary artery bypass surgery	Peritoneal dialysis
Chylothorax	Trapped lung
Pseudo-chylothorax	Atelectasis
Hemothorax	
Uremia	
Rheumatoid pleuritis	
Lupus (drug induced or systemic)	
Uncommon	Uncommon
Asbestos exposure	Cerebrospinal fluid leak
Drug induced	Constrictive pericarditis
Yellow-nail syndrome	Myxedema
Esophageal perforation	Pulmonary veno-occlusive disease
Pancreatitis	Central venous occlusion
Postabdominal surgery	Extravascular migration of central venous catheter
Bilio-pleural fistula	Glycinothorax
Sarcoidosis	

■ POSTCORONARY ARTERY BYPASS SURGERY

About 10% of patients who undergo CABG develop a large pleural effusion within 1 month after the surgery most commonly in the left hemithorax, although it may be bilateral with the left effusion usually larger than the right. The effusion is typically bloody as the result of bleeding from the internal mammary harvest site. The cell count has a lymphocyte predominance. One or two therapeutic thoracentesis are required as treatment. Persistence of pleural effusion for greater than 6 months post-CABG is usually due to the presence of a trapped lung. Most often the effusions are transudative and are not associated with respiratory symptoms. However, surgical decortication should be considered if the trapped lung causes a large effusion.

■ POSTCARDIAC INJURY SYNDROME

Postcardiac injury syndrome (previously known as Dressler syndrome) occurs after myocardial infarction, cardiac surgery, pacemaker implantation or blunt chest trauma. It is characterized by the presence of fever, chest pain, a new pericardial friction rub and effusion, and in about 70% of cases small bilateral pleural effusions. Postcardiac injury syndrome may develop between 3 weeks and up to a year after cardiac injury. Postcardiac injury syndrome is usually treated with aspirin, colchicine, or indomethacin and in severe cases corticosteroids.

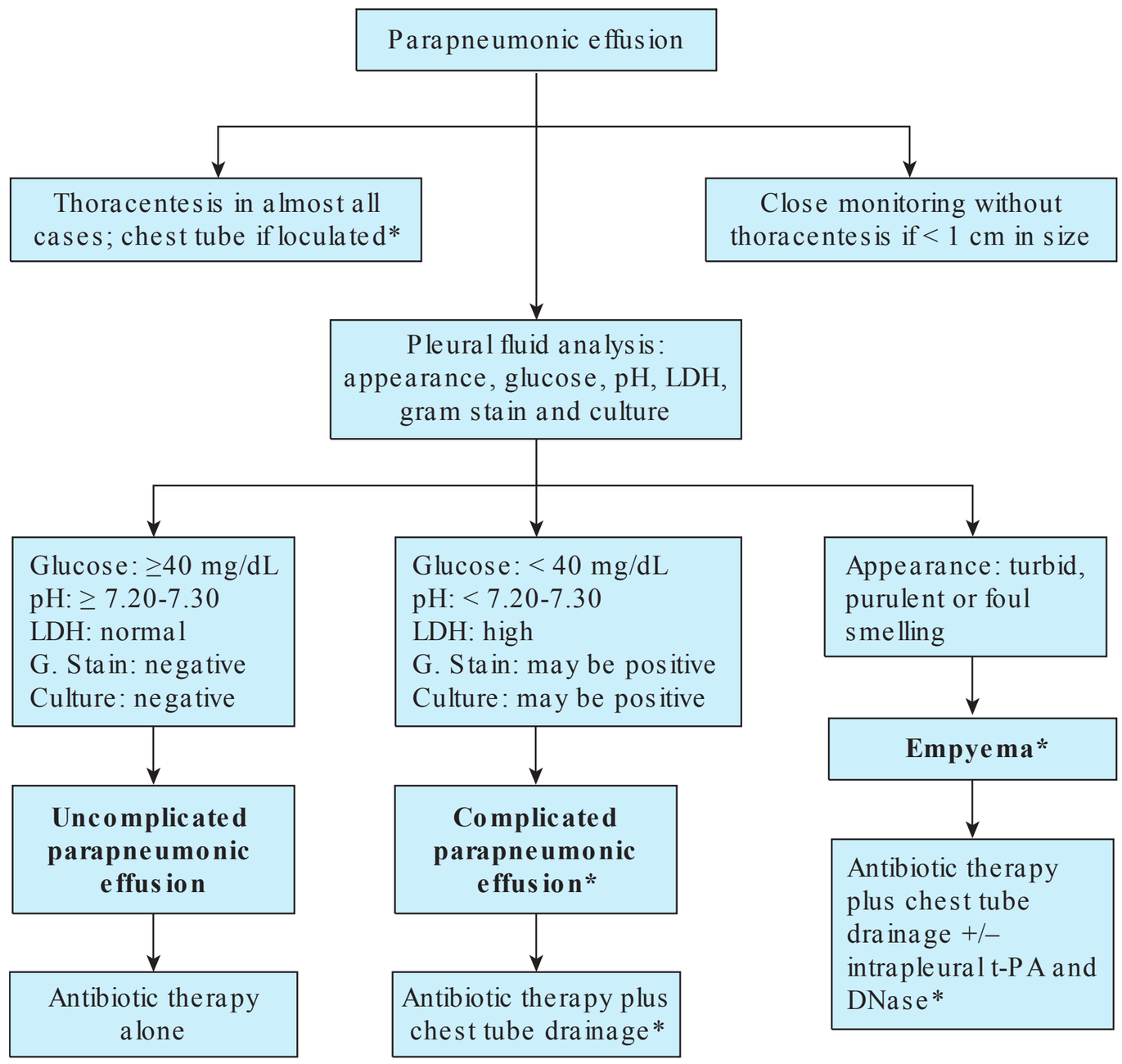

*Pulmonary consultation is recommended in these situations. Surgery consultation may be needed if persistent fever, sepsis or ongoing infection despite antibiotics and chest tube drainage.

Figure 236-3 Management of parapneumonic effusions.

Figure 236-4 Postero-anterior chest imaging shows a large left-sided pleural effusion with mediastinal shift to the contralateral side. Note the right tracheal deviation, near-complete left hemithorax opacification. The patient had a malignant bloody effusion due to lung adenocarcinoma. (Image courtesy of Sharon Jessie, Radiology Department, TJ Samson Community Hospital.)

■ TUBERCULOSIS

Although uncommon in the United States, tuberculous pleuritis may result in serious health consequences both to the patient and from a public health perspective if not recognized. There is a 50% probability of developing active tuberculosis within 5 years if the patient does not receive antituberculous therapy. Tuberculous

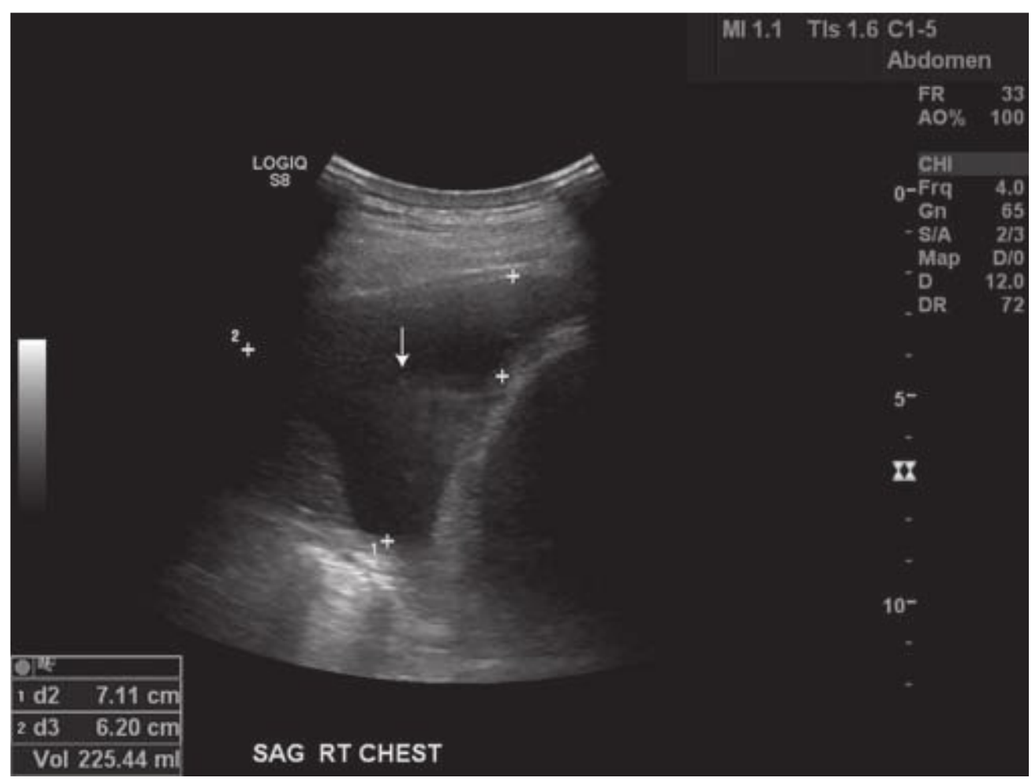

Figure 236-5 Chest ultrasound shows a pleural opacity consistent with tumor invasion (arrow). (Image courtesy of Sharon Jessie, Radiology Department, TJ Samson Community Hospital.)

pleuritis may be a consequence of primary infection that occurred 3 to 6 months prior, or due to reactivation. Pleural fluid cultures are negative nearly 80% of the time, and a tuberculin skin test may be negative in up to one-third of patients.

About 67% of patients present with an acute clinical presentation that includes cough, dyspnea and chest pain; these symptoms may be confused with pneumonia and a parapneumonic effusion. Less commonly, patients may present with a chronic illness and a unilateral effusion. Pleural fluid analysis shows lymphocyte predominance. If thoracentesis is done in early stages, pleural fluid may show neutrophil predominance. A very high protein level of greater than 5.0 g/dL is highly suggestive of the diagnosis (Table 236-4). Pulmonary consultation may assist in recommending specific diagnostic pleural tests such as adenosine deaminase (see Table 236-6), polymerase chain reaction for mycobacterial DNA and pleural fluid interferon-γ. Induced sputum smear and culture will be positive in half of the patients. Pleural biopsy should be obtained if suspicion is high and exudative effusion has not resolved. Tuberculous pleuritis typically resolves in several months regardless if tuberculosis treatment is given; however, if tuberculosis treatment is not provided, these patients have a high risk for relapse (see Chapter 200 [Tuberculosis]).

■ HEMOTHORAX

Hemothorax or the presence of blood in the pleural cavity is defined as a pleural fluid hematocrit that is at least 50% that of blood. Table 236-8 summarizes the causes of hemothorax encountered in the hospital. Bleeding may be significant and lead to hemodynamic compromise and cardiovascular collapse if not recognized quickly. Clinicians should always consider hemothorax in the situations listed in Table 236-8. Management requires chest tube insertion in all cases in order to quantify the rate of bleeding and prevent any of the following complications: (1) retention of clot; (2) infection; and (3) fibrothorax. Thoracic surgical consultation is recommended if chest tube output is greater than 200 mL/h and there are no signs of slowing. Persistence of blood in the pleural space increases the risk for fibrothorax or trapped lung.

■ CHYLOTHORAX AND CHOLESTEROL EFFUSIONS

Chylothorax is the accumulation of lipid from chyle in the pleural space due to disruption or obstruction of the thoracic duct. Chylothoraces may be unilateral or bilateral, depending on the level at which the thoracic duct disruption occurs: right sided if the disruption occurs below the fourth to sixth thoracic vertebrae, left sided or bilateral if the disruption occurs at this level or above. The pleural fluid has a characteristic milky appearance but may mimic that of empyema. Centrifugation of the fluid will result in layering and deposition of cellular debris at the bottom in empyema, whereas in chylothorax the appearance will remain the same. Pleural fluid analysis shows lymphocyte predominance, a relatively low LDH and high protein (protein discordance) level. Triglyceride levels are greater than 110 mg/dL (see Table 236-6). Chylomicrons should be measured if the triglyceride level falls between 50 and 110 mg/dL. Table 236-9 lists the causes of chylothorax encountered in the hospital.

A pulmonary consultation is recommended in all cases of chylothoraces to tailor the most appropriate therapy according to the etiology. A diet rich in medium-chain triglycerides may reduce the flow of chyle; absorbed directly into the blood, medium-chain triglycerides bypass the thoracic duct. Octreotide may reduce the rate of chyle formation as well. Thoracentesis may reduce dyspnea; a chest tube should be avoided because drainage of significant amount of protein and lymphocytes may cause malnutrition and immunodeficiency. A pleuroperitoneal shunt may be considered in cases of malignant obstruction unresponsive to chemo- or radiation therapy. Thoracic duct embolization, ligation, or talc pleurodesis are all aimed at controlling chyle leak.

Cholesterol effusion is the accumulation of lipid from cholesterol or lecithin-globulin due to a long-standing pleural effusion in the presence of a pleural cavity surrounded by fibrin. Cholesterol effusion develops in the presence of chronic pleural space inflammation, such as tuberculous pleuritis, rheumatoid pleuritis, parasitic infection, or trauma. Unlike chylothorax, triglyceride levels in pleural fluid are low. Cholesterol crystals may be seen on cytology and the cholesterol level is usually greater than 250 mg/dL (see Table 236-6). Treatment is aimed at the underlying cause.

TABLE 236-8 Causes of Hemothorax

Traumatic	Iatrogenic	Nontraumatic
Penetrating injury	Thoracic surgery (heart or lung)	Malignant effusion
Nonpenetrating injury	Central vein perforation after central line insertion	Anticoagulation therapy
	Thoracentesis	Ruptured aortic aneurysm
	Chest tube insertion	Arterio-venous malformation
	Lung biopsy	Hematological disorder (ie, hemophilia, thrombocytopenia)
	Transbronchial biopsy	Intrapleural fibrinolytics
		Catamenial

TABLE 236-9 Causes of Chylothorax

Traumatic	Nontraumatic
Iatrogenic	Tumors
Surgery	Lymphoma
Radiotherapy	Metastatic pleural tumors
Endoscopy	
Noniatrogenic	Lymphatic involvement
Chest wall trauma	Lymphangioleiomyomatosis
Childbirth	Tuberous sclerosis
	Amyloidosis
	Yellow-nail syndrome
	Sarcoidosis
	Filariasis
	Dasatinib and tyrosine kinase inhibitors
	Gorham syndrome
	Venous pressure
	Mediastinal fibrosis
	Superior vena cava thrombosis
	Chylous ascites

PNEUMOTHORAX

Pneumothorax is defined as presence of air in the pleural cavity. Primary spontaneous pneumothorax occurs as a result of a ruptured apical pleural bleb in the majority of cases. Chest tube insertion

TABLE 236-10 Classification of Pneumothorax

Spontaneous Primary (no underlying lung disease) Secondary (underlying lung disease)
Traumatic
Iatrogenic
Catamenial
Tension

or air evacuation is indicated if the patient is symptomatic or if the pneumothorax is greater than 20% in size. Nearly all patients with secondary spontaneous pneumothoraces require chest tube insertion given their low underlying lung reserve and symptomatic presentation.

The most common cause of pneumothorax in the hospitalized patient is iatrogenic.

Table 236-10 lists the general classification of pneumothoraces. Diagnosis is established by chest radiography or ultrasound imaging (see Figure 236-6). Ultrasound findings that indicate the presence of a pneumothorax include: (1) absence of lung-sliding; (2) absence of B-lines; and (3) presence of a lung-point. The identification of a lung-point confirms the presence of pneumothorax; while the absence of lung-sliding on M-mode or 2-D ultrasound suggests a pneumothorax. The nondependent parts of the thorax should be initially scanned with the ultrasound. The size of the pneumothorax is estimated by measuring the distance between the visceral pleural line and the chest wall at the level of the hilum or apex. About 1 cm is equivalent to 10%. The estimated size of the pneumothorax is approximately 20% if the distance is 2 cm.

Chest tube insertion is recommended in iatrogenic pneumothoraces that result in symptoms and are greater than 20% in size. If the patient is asymptomatic and the pneumothorax is less than or equal to 20%, conservative management may be pursued with high-flow 100% continuous oxygen and observation. Tension pneumothorax may easily develop in patients on mechanical ventilation; and therefore chest tube insertion is recommended in patients who develop iatrogenic pneumothorax. The chest tube should be left in place for at least 48 hours after the air leak stops while these patients remain on the ventilator.

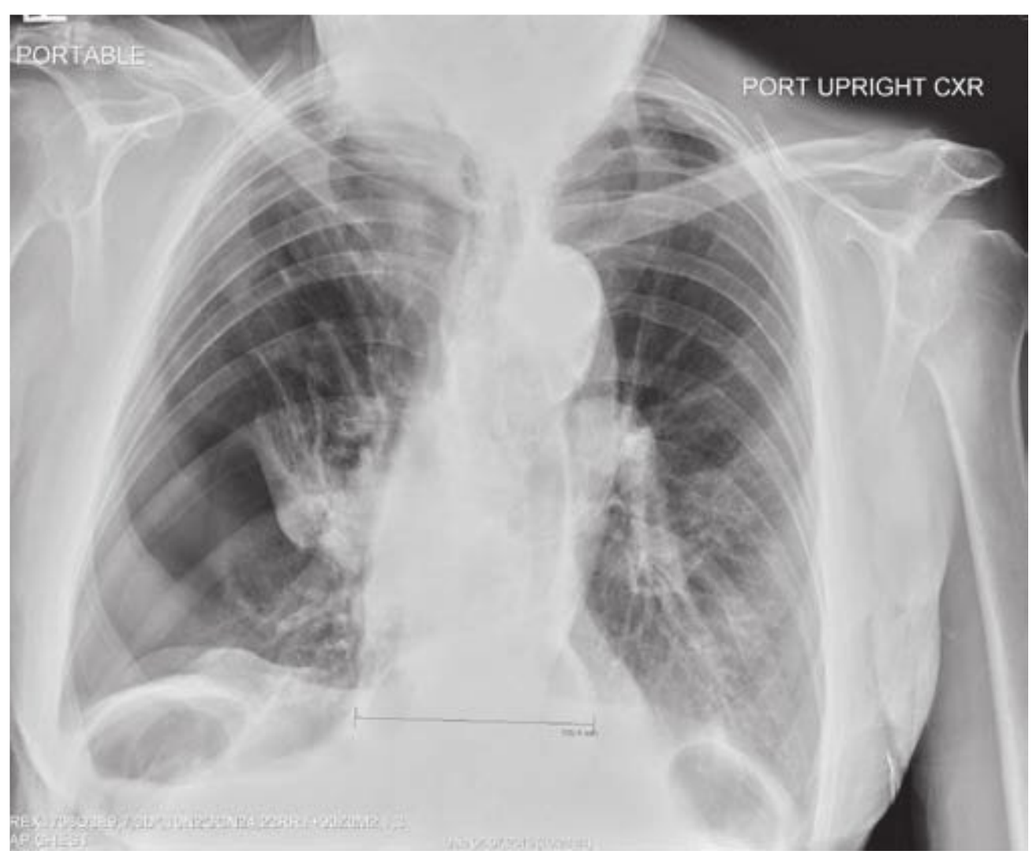

Figure 236-6 Chest radiography shows a large right side pneumothorax with a visceral pleural line noted and absence of blood vessels and lung markings towards the chest wall beyond the pleural line. Note that the pleural line is sharp and well demarcated.

■ TENSION PNEUMOTHORAX

The clinical signs of tension pneumothorax include sudden cardiovascular collapse, cyanosis, and respiratory distress. In mechanically ventilated patients, peak pressure suddenly increases if assist control volume cycled mechanical ventilation is used. In patients receiving cardiopulmonary resuscitation, dif culty in ventilating the patient may be the only sign. Emergent size 14 to 16 gauge needle catheter insertion at the level of the midclavicular line, anterior second intercostal space is performed. The catheter is left in place until air ceases to exit. Chest tube should then be inserted.

Indications for Chest Tube Insertion

Chest tube insertion should be performed by experienced operators and in the appropriate clinical setting. Smaller bore chest tubes are noninferior to larger bore chest tubes for most indications. Although they are easier to insert and reduce the amount of pain, smaller bore chest tubes tend to dislodge easier. Chest tube insertion is recommended for the following:

- Complicated parapneumonic effusion
- Empyema
- Talc pleurodesis administration
- Hemothorax
- Tension pneumothorax
- Secondary spontaneous pneumothorax and symptomatic
- Pneumothorax greater than 20%

Indwelling pleural catheters are recommended in malignant pleural effusions with an unexpandable lung.

Pulmonary Consultation

Pulmonary consultation is recommended in the following:

- Thoracentesis and chest tube insertion if provider is unfamiliar or uncomfortable with procedures
- Unilateral effusion, absence of cardiomegaly, bilateral asymmetric effusions, fever or pleurisy in a patient with congestive heart failure
- Recurrent hepatic hydrothorax or suspected spontaneous bacterial pleuritis
- Undiagnosed transudate or exudate
- Suspected trapped lung and need for pleural manometry
- Complicated parapneumonic effusions and empyemas
- Evaluation for intrapleural t-PA and DNase
- Malignant effusions with need for indwelling pleural catheter insertion and talc pleurodesis evaluation
- Suspected tuberculous pleuritis
- Hemothorax
- Chylothorax and pseudochylothorax
- Pneumothorax

SUGGESTED READINGS

Broaddus VC, Light RW. Pleural effusion. In: Broaddus VC, Mason RM, Ernst JD, et al, eds. Murray & Nadel's Textbook of Respiratory Medicine, 6th ed. Philadelphia, PA: Elsevier Saunders; 2015;1396-1424.

Colice GL, Curtis A, Deslauriers J, et al. Medical and surgical treatment of parapneumonic effusions: an evidence-based guideline. Chest. 2000;118(4):1158-1171.

Light RW. Textbook of Pleural Diseases. Baltimore, MD: Wolters Kluwer Lippincott Williams and Wilkins; 2013.

Light RW, Macgregor MI, Luchsinger PC, Ball WC Jr. Pleural effusions: the diagnostic separation of transudates and exudates. Ann Intern Med. 1972;77(4):507-513.

MacDuff A, Arnold A, Harvey J. Management of spontaneous pneumothorax: British Thoracic Society Pleural Disease Guideline 2010. Thorax. 2010;65(Suppl 2):18-31.

Rahman NM, Maskell NA, West A, et al. Intrapleural use of tissue plasminogen activator and DNase in pleural infection. N Engl J Med. 2011;356(6):518-526.

Romero-Candeira S, Hernandez L, Romero-Brufao S, Orts D, Fernandez C, Martin C. Is it meaningful to use biochemical parameters to discriminate between transudative and exudative pleural effusions? Chest. 2002;122(5):1524-1529.

Sahn SA. Getting the most of pleural fluid analysis. Respirology. 2012;17(2):270-277.