SECTION 2

Glomerular Diseases

Podocytopathies

Minimal Change Disease 48
Classification of Focal Segmental Glomerulosclerosis 56
Etiologies of Focal Segmental Glomerulosclerosis 60
Focal Segmental Glomerulosclerosis, Primary 62
Collapsing Glomerulopathy 70
Focal Segmental Glomerulosclerosis, Adaptive (Secondary) 80
Metabolic Syndrome/Obesity-Related Glomerular Disease 86

Membranous Glomerulonephritis

Etiologies of Membranous Glomerulonephritis 90
Membranous Glomerulonephritis, Primary 92
Membranous Glomerulonephritis, Secondary 98
Membranous Glomerulonephritis With Anti-TBM Antibodies 102

C3-Related Glomerulonephritis and Membranoproliferative Glomerulonephritis

Classification of MPGN and Complement-Related Diseases 104
Dense Deposit Disease 108
C3 Glomerulonephritis 114
Membranoproliferative Glomerulonephritis With Immune Complexes 120

Immunoglobulin A-Related Glomerulonephritis

Overview of IgA-Related Glomerular Diseases 128
IgA Nephropathy 132
IgA Vasculitis (Henoch-Schönlein Purpura) 146
IgA Acute Glomerulonephritis Associated With *Staphylococcus aureus* 152
Hepatic Disease With IgA Deposition 156

SLE and Related Autoantibody-Mediated Diseases

Systemic Lupus Erythematosus 158
Mixed Connective Tissue Disease 176
Rheumatoid Arthritis 178
Mixed Cryoglobulinemic Glomerulonephritis 184
Idiopathic Nonlupus Full-House Nephropathy 190

Anti-GBM Diseases

Anti-GBM Glomerulonephritis 192
Atypical Anti-GBM Disease 200

Monoclonal Immunoglobulin Diseases of Glomeruli

Introduction to Diseases With Monoclonal Immunoglobulin Deposits 204
Monoclonal Immunoglobulin Deposition Disease 208
Proliferative Glomerulonephritis With Monoclonal IgG Deposits 216
Membranous Glomerulonephritis With Masked IgG κ Deposits 220
Type I Cryoglobulinemic Glomerulonephritis 224
Waldenström Macroglobulinemia 228

Amyloidosis

Amyloidosis Classification 230
AL/AH Amyloidosis 236
AA Amyloidosis 242
AFib Amyloidosis 246
AGel Amyloidosis 248
ALECT2 Amyloidosis 250
AApoAI Amyloidosis 252
AApoAII Amyloidosis 253
AApoAIV Amyloidosis 254
AApoCII Amyloidosis 255
ATTR Amyloidosis 256

Idiopathic Fibrillary Glomerulopathies

Diseases With Organized Deposits 258
Fibrillary Glomerulopathy 262
Immunotactoid Glomerulopathy 266
Fibronectin Glomerulopathy 270

Diabetic Renal Disease

Diabetic Nephropathy 274
Idiopathic Nodular Glomerulopathy 284

Infection-Related Glomerular Disease

Overview of Infection-Related Glomerular Disease 288
Poststreptococcal Acute Glomerulonephritis 292
Postinfectious Acute Glomerulonephritis, Nonstreptococcal 300

Glomerulonephritis of Chronic Infection, Including Shunt Nephritis 306
Endocarditis 308
Syphilis 312
Lyme Disease 314
Hepatitis B Virus 316
Hepatitis C Virus 320
HIV-Associated Nephropathy 324
Miscellaneous HIV-Associated Renal Diseases 330
Schistosomiasis 336
Filariasis 338
Leishmaniasis 339

Drug-Induced Glomerular Diseases

Drug-Induced Minimal Change Disease 340
Bisphosphonate-Induced Collapsing Glomerulopathy 342
Chloroquine Toxicity 343
Anti-Hepatitis C Virus Drugs 344
Anti-EGFR Drugs 348

Genetic Diseases of Glomerulus

Overview and Classification of Genetic Diseases of Glomerulus 350

Genetic Diseases of GBM Collagen

Alport Syndrome 352
Thin Basement Membrane Disease 364

Genetic Diseases of Podocyte

APOL1-Related Glomerular Disease 366
Diffuse Mesangial Sclerosis 370
Congenital Nephrotic Syndrome of Finnish Type 374
Pierson Syndrome 378
Galloway-Mowat Syndrome 380
Denys-Drash Syndrome 382
Frasier Syndrome 386
Podocin Deficiency 390
Alpha-Actinin-4 Deficiency 392
Autosomal Dominant FSGS Due to *INF2* Mutations 394
Schimke Immunoosseous Dysplasia 396

Genetic Storage and Lipid Diseases

Fabry Disease 398
Lecithin-Cholesterol Acyltransferase Deficiency 406
APOE Lipoprotein Glomerulopathy 410
Type III Hyperlipoproteinemia 412
Gaucher Glomerulopathy 414
I-Cell Disease (Mucolipidosis II) 416
Alagille Syndrome 418

Other Genetic Diseases Affecting Glomerulus

Nail-Patella Syndrome 420
Type III Collagen Glomerulopathy 422
Glomerulopathy of Hereditary Multiple Exostoses 426

Miscellaneous Glomerular Diseases

C1q Nephropathy 428
IgM Nephropathy 434
Cryofibrinogenic Glomerulopathy 436
Hemophagocytic Glomerulopathy 440
Podocyte Infolding Glomerulopathy 444
Intravascular Large B-Cell Lymphoma 446

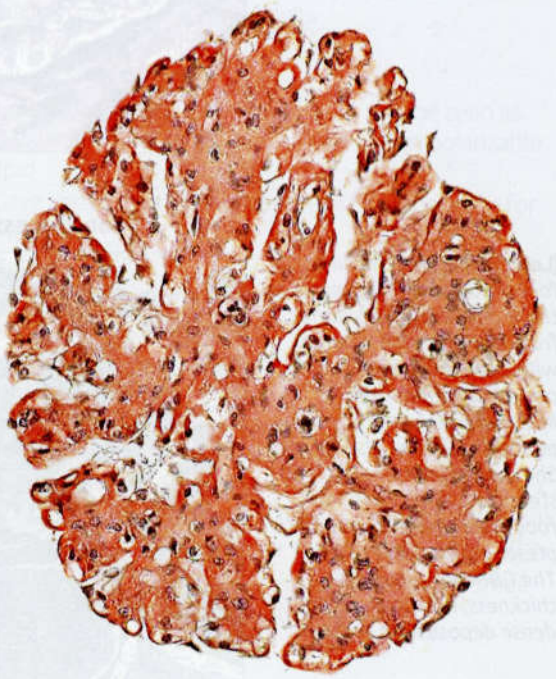

Minimal Change Disease

KEY FACTS

TERMINOLOGY

- Idiopathic glomerular disease that causes nephrotic syndrome with minimal or no light or immunofluorescent microscopic abnormalities and diffuse podocyte foot process effacement on electron microscopy

ETIOLOGY/PATHOGENESIS

- Usually idiopathic
- Involves loss of glomerular negative charge
- Circulating permeability factor, likely autoimmune etiology
- Secondary forms due to virus, drugs, lymphoma

CLINICAL ISSUES

- Nephrotic syndrome
- Most common in young children, boys > girls
- 90-95% respond to corticosteroids
- Can present as acute renal insufficiency in adults

MICROSCOPIC

- Glomeruli normal by light microscopy except for variable podocyte hypertrophy
- Protein reabsorption droplets in tubules

ANCILLARY TESTS

- Immunofluorescence negative except for variable focal IgM ± C3 and tubular protein reabsorption droplets
- Electron microscopy has characteristic findings
  - Podocyte foot process effacement, swelling, and microvillous transformation
  - Slit diaphragm loss
  - Normal GBM and no deposits

TOP DIFFERENTIAL DIAGNOSES

- FSGS
- Diffuse mesangial hypercellularity
- Rarely IgA, IgM, or C1q nephropathy

Normal Glomerulus

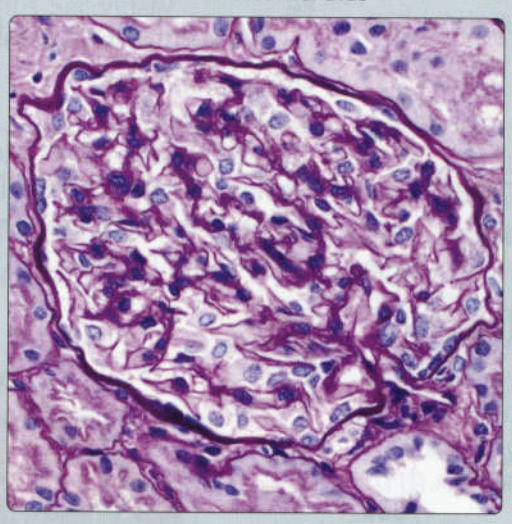

Fine Granular Podocyte IgG Staining in Minimal Change Disease

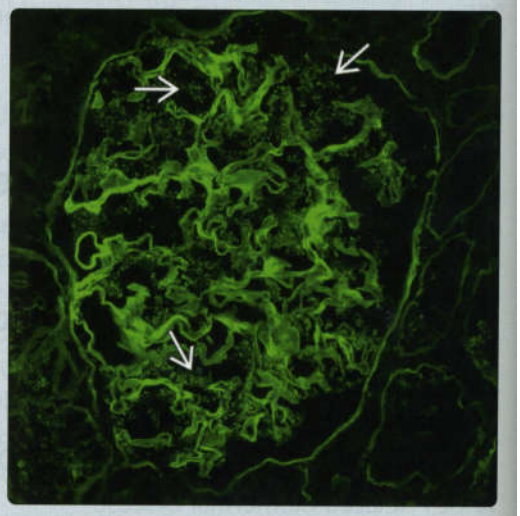

(Left) *Glomerulus appears normal by light microscopy PAS stain in a 5-year-old boy with nephrotic syndrome due to minimal change disease (MCD) with multiple relapses off steroids. Immunofluorescence (IF) studies were negative.* **(Right)** *Occasionally, diffuse and fine granular IgG staining can be detected over podocytes ➡ of uncertain significance.*

Foot Process Effacement

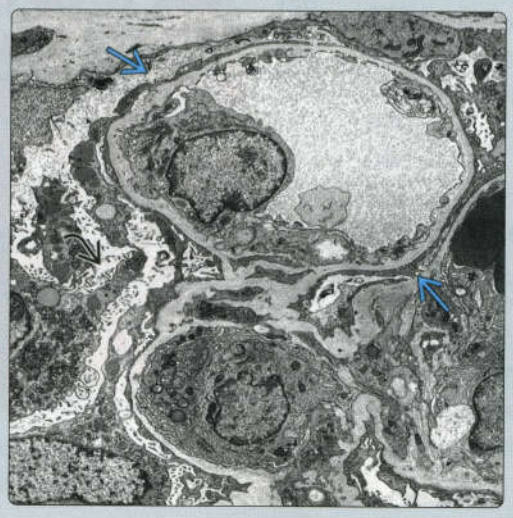

Foot Process Effacement

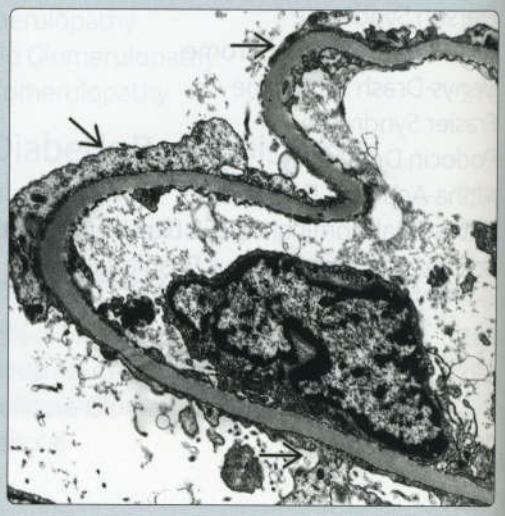

(Left) *Extensive effacement of foot processes ⇨ is present in these glomerular capillaries from a 37-year-old woman with sudden onset of edema and 15-lb weight gain. Microvillous change in podocytes ⇨ can also be seen. She responded completely to steroids.* **(Right)** *Prominent foot process effacement ⇨ is present in this case of MCD. The GBM has a normal thickness, and no electron-dense deposits are present.*

TERMINOLOGY

Abbreviations

- Minimal change disease (MCD)

Synonyms

- Lipoid nephrosis, nil disease, diffuse podocytopathy with minimal glomerular changes

Definitions

- Idiopathic and diffuse podocytopathy that causes acute-onset nephrotic syndrome with minimal or no light microscopic or immunofluorescence (IF) abnormalities and diffuse podocyte foot process effacement (FPE)
- Occurs as primary (idiopathic) disease frequently in children, and is secondary to drugs, allergic reactions, immunologic diseases, and neoplasia at all ages

ETIOLOGY/PATHOGENESIS

Primary MCD (Without Other Diseases)

- Classified as primary disease of podocytes, a form of "podocytopathy"
- Loss of podocyte negatively charged glycocalyx possibly contributing feature
  - Cause unknown; possibilities include
    - Enzymatic cleavage (e.g., neuraminidase)
    - Neutralizing positively charged molecule
    - ↓ synthesis
  - Loss of negative (anionic) charge leads to
    - Selective leakage of albumin (most negative charge of major plasma proteins)
    - FPE
- Circulating permeability factor or cytokine abnormality likely, but not identified
  - Various substances have been suggested, ranging in molecular weight from 12-160 kDa
  - T-cell IL-13 content ↑ during relapse
    - Antiinflammatory Th2 cytokine for B cells and monocytes
  - ↑ serum IgE, IgG4 in some patients
- Rarely familial, no strong genetic associations
- Likely immune-related phenomenon
  - Often seen in setting of infection, allergic reaction, or lymphoproliferative disorder
- Loss of filtration slit diaphragms

Secondary MCD (Associated With Other Diseases)

- Specific infection-related MCD
  - HIV
  - Mononucleosis
- Lymphoma (Hodgkin, mantle cell)
  - MCD may precede lymphoma by year or more
- Allergy
  - Drugs, especially NSAIDs
  - Bee venom; immunization
- Immune reactions to kidney
  - Graft-vs.-host disease
  - Acute renal allograft rejection (rare)
  - Checkpoint inhibitor drugs
- "Lupus podocytopathy" in SLE

Relationship to FSGS

- Both represent diffuse podocytopathies, but idiopathic FSGS differs in extent of podocyte loss, glomerular scarring, and shows evidence of parietal epithelial cells on tuft
- Some evidence exists that idiopathic FSGS may be related &/or represents progressive form of injury leading to focal podocyte loss

CLINICAL ISSUES

Epidemiology

- Age
  - Most common cause of nephrotic syndrome in children younger than 10 years (70-90% of cases)
    - Median age of onset is 2.5 years; peak incidence at 2-3 years
  - ~ 50% of nephrotic syndrome in adolescents
  - ~ 10-15% of nephrotic syndrome in adults, with late peak incidence
    - 46% are 80-91 years
- Sex
  - In children, M:F = 2:1
  - In adults, M = F
- Ethnicity
  - More common in Caucasians and Asians than in African Americans

Presentation

- Sudden (days) onset of nephrotic syndrome
- Nephrotic syndrome
  - Proteinuria defined as ≥ 3.5 g/d in adults and ≥ 40 mg/m² body surface area/hr in timed overnight collection in children
    - Selective proteinuria (mainly albumin)
  - Edema
  - Hypoalbuminemia defined as serum albumin < 2.5 g/dL in children and < 3.5 g/dL in adults
  - Hypercholesterolemia
  - Lipiduria
    - Lipid-laden enucleated tubular cells may be seen as "oval fat bodies" in urinary sediment, with polarizable lipid
    - Gave rise to term "lipoid nephrosis," original term for MCD
- Hematuria
  - Microscopic hematuria (10-30% of cases)
- Renal dysfunction
  - Acute renal failure occurs in 25% of adults with MCD, often with morphologic evidence of tubular injury
    - Associated with proteinuria > 10 g/d, serum albumin < 2 g/dL, hypertension, male sex, older age
    - Most recover in 4-8 weeks
      - Elevated serum Cr often persists (mean 2.11 ± 0.44)
  - Serum Cr > 98th percentile in < 1/3 of children with MCD
    - Reduced glomerular hydraulic conductivity for small molecules from loss of filtration slit pores

Laboratory Tests

- Usually negative serologic testing for PLA2R1

Treatment

- Drugs

- Corticosteroids primary treatment
  - 90-95% of children respond within 8 weeks, 85-90% of adults respond within 20 weeks
  - Steroids often used as empirical treatment in children
    - If no response, renal biopsy performed to identify cause of nephrotic syndrome
  - Relapse within 1st year in up to 50% of children and 60-75% of adults
    - Usually treated with another course of steroids
- Treatment of steroid nonresponders
  - Cyclophosphamide, levamisole, cyclosporine; rituximab (off label)
  - Abatacept (CTLA4-Ig) (off label)
  - Repeat biopsy to detect FSGS

Prognosis

- Primary (idiopathic)
  - Rarely, if ever, leads to ESRD without development of FSGS
  - Adults with MCD and acute renal failure also usually fully recover
  - Relapses common and often lead to steroid dependence
- Secondary: Remits if underlying condition can be cured
- MCD may be initial manifestation of FSGS (~ 5%), in which case prognosis is that of FSGS

MACROSCOPIC

General Features

- Enlarged, waxy, yellow cortex due to lipid accumulation in proximal tubules

MICROSCOPIC

Histologic Features

- Glomeruli
  - Normal by light microscopy (LM)
    - Slight ↑ in mesangial cellularity and matrix in minority
    - Normal GBM
    - Normal glomerular size
  - Podocytes may be swollen and prominent with basophilic cytoplasm
    - Albumin reabsorption droplets in podocytes
  - Loss of negative charge revealed by ↓ colloidal iron stain along GBM
  - Globally sclerotic glomeruli may be seen in MCD in adults
    - 10% of glomeruli may be sclerotic by age 40 and 30% by age 80
  - In children, involuted glomeruli are sometimes present
    - Lack of atrophic tubules indicates developmental rather than acquired glomerular sclerosis
- Tubules
  - Protein resorption droplets ("hyaline droplets")
    - PAS(+) and red on trichrome stain
  - Lipid droplets
    - Origin of term "lipoid nephrosis"
    - Clear vacuoles on H&E, PAS, and trichrome
    - Red droplets on oil red O-stained frozen sections
  - Usually little to no tubular atrophy
    - Older patients with concurrent arteriosclerosis may have underlying glomerular obsolescence and tubular atrophy
  - Tubular regenerative changes and injury in adults with acute renal failure
- Interstitial inflammation and fibrosis are usually absent
  - Interstitial foam cells may be seen but are rare

ANCILLARY TESTS

Immunofluorescence

- Can be negative, but faint granular "dusting" of IgG over podocytes is seen in some cases
- Minority have faint (≤ 1+) staining in glomeruli for IgM ± C3
  - < 5% of MCD cases have mesangial staining for IgG, IgM, IgA, C1q, &/or C3, particularly in children
    - May predict higher rate of steroid resistance
- Renal tubular resorption droplets stain for albumin ± Ig and C3

Electron Microscopy

- Podocyte FPE
  - Foot processes retract and cell body spreads on GBM (not "fusion")
  - Diffuse, usually involving > 75% of capillary surface
    - Extent (% of surface) correlates with severity of proteinuria in some but not all reports
  - Morphometry
    - Mean foot process width (1,566 ± 429 nm vs. 472 ± 52 nm normal); median 1,725 nm vs. 562 nm
    - Number of feet/10 μm of GBM (0.84 ± 0.24 vs. 3.84 ± 1.8 normal)
  - After remission, foot processes return toward normal, although some persistent change observed
  - FPE occurs in any renal disease with severe glomerular proteinuria
- Other usual podocyte abnormalities
  - Vacuolization and microvillous transformation
  - Resorption droplets and ↑ cellular organelles
  - ↓ numbers of filtration slit diaphragms
- Mild mesangial expansion in minority of cases
  - Vague mesangial and paramesangial electron densities, probably due to nonspecific protein insudation
- Tubules
  - Proximal tubules contain electron-dense resorption droplets (secondary lysosomes) and electron-lucent lipid droplets

Immunohistochemistry

- ↓ nephrin along GBM, corresponding with loss of slit diaphragms
  - Nephrin loss is seen in other diseases with FPE, particularly in advanced stages
- Markers that favor FSGS over MCD
  - CD44 in parietal epithelial cells (PEC), which is marker of activation
  - Ectopic PEC markers in glomerular tuft
    - Claudin-1, A-kinase anchor protein, annexin-A3
  - Preservation of α- and β-dystroglycan in some but not all studies
- Marker that favors MCD over FSGS
  - Decreased podocyte α-dystroglycan

DIFFERENTIAL DIAGNOSIS

FSGS, Idiopathic

- Segmental hyalinosis or synechiae to Bowman capsule
- Minority of cases with MCD on initial biopsy show FSGS later due to sampling or progression
- FSGS cases with unsampled glomerulosclerosis may be misdiagnosed as MCD
  - Serial sectioning required to detect segmental glomerulosclerosis, most common at corticomedullary junction
    - Sections of segmentally sclerotic glomeruli may appear normal if plane of section does not include segmental sclerosis
  - Probability of detecting focal glomerular lesion (P) is function of % of glomeruli affected in kidney (p) and number of glomeruli in biopsy (n)
    - P = (1-p)^n
    - e.g., to detect lesions with > 95% probability, if 5% affected in kidney, 60 glomeruli needed; if 10% affected, 30 glomeruli needed
  - Clues to underlying FSGS
    - Glomerular hypertrophy or tubular atrophy
      - Glomerular area of 1.75x age-matched controls
    - Expression of PEC proteins in glomerular tuft (PAX2, Claudin-1)
    - Endocapillary foam cells
- Recurrent FSGS in transplants begins as MCD-like lesions in 1st month after transplant, followed by FSGS lesions later

Diffuse Mesangial Hypercellularity

- Possibly variant of MCD
  - > 4 mesangial cells per mesangial region in ≥ 80% of glomeruli in 2-3 μm tissue sections
- ~ 3% of pediatric cases of idiopathic nephrotic syndrome
- IF may show IgM or C3; electron microscopy (EM) shows electron-dense deposits in 50%
- More likely to have hematuria and hypertension
- Higher rate of steroid resistance

IgM Nephropathy

- Possibly a variant of MCD/FSGS
- Diffuse, global mesangial IgM (≥ 2+); C3 in 30+%
- EM shows FPE and occasional scanty paramesangial deposits
- Hematuria and hypertension more common than in MCD
- 6x increased rate of progression to FSGS in children compared with MCD

IgA Nephropathy

- MCD superimposed on IgA nephropathy should be entertained if nephrotic syndrome is of rapid onset and complete FPE is present
- Most respond to steroids (80%)

C1q Nephropathy

- C1q in mesangium (≥ 2+) ± immunoglobulins on IF
- Occasional electron-dense deposits on EM
- Possibly (early?) expression of an autoimmune disease on lupus spectrum

Chyluria

- Normal podocytes (no FPE) with heavy proteinuria

Amyloidosis

- Has been missed in early cases without EM or Congo red

Congenital Nephrotic Syndrome (Finnish Type)

- Onset in in utero/infancy
- Absence of podocyte slit diaphragm by EM

DIAGNOSTIC CHECKLIST

Pathologic Interpretation Pearls

- Podocyte hypertrophy (cytoplasmic basophilia) and tubular reabsorption droplets are LM clues to diagnosis
- Multiple levels important to detect FSGS
  - Note whether biopsy includes corticomedullary junction (site initially affected by FSGS); prudent to always state "FSGS cannot be excluded"
- Acute tubular necrosis may be present and account for acute renal failure

SELECTED REFERENCES

1. Bertelli R et al: Molecular and cellular mechanisms for proteinuria in minimal change disease. Front Med (Lausanne). 5:170, 2018
2. Gao B et al: Minimal change disease associated with anti-PD1 immunotherapy: a case report. BMC Nephrol. 19(1):156, 2018
3. Meyrier A et al: Acute kidney injury complicating nephrotic syndrome of minimal change disease. Kidney Int. 94(5):861-9, 2018
4. van de Lest NA et al: Nephrin loss can be used to predict remission and long-term renal outcome in patients with minimal change disease. Kidney Int Rep. 3(1):168-77, 2018
5. Garin EH et al: Case series: CTLA4-IgG1 therapy in minimal change disease and focal segmental glomerulosclerosis. Pediatr Nephrol. 30(3):469-77, 2015
6. Ling C et al: Urinary CD80 levels as a diagnostic biomarker of minimal change disease. Pediatr Nephrol. 30(2):309-16, 2015
7. Iwabuchi Y et al: Long-term prognosis of adult patients with steroid-dependent minimal change nephrotic syndrome following rituximab treatment. Medicine (Baltimore). 93(29):e300, 2014
8. Kofman T et al: Minimal change nephrotic syndrome associated with non-Hodgkin lymphoid disorders: a retrospective study of 18 cases. Medicine (Baltimore). 93(24):350-8, 2014
9. Liu XJ et al: Ultrastructural changes of podocyte foot processes during the remission phase of minimal change disease of human kidney. Nephrology (Carlton). 19(7):392-7, 2014
10. Smeets B et al: Detection of activated parietal epithelial cells on the glomerular tuft distinguishes early focal segmental glomerulosclerosis from minimal change disease. Am J Pathol. 184(12):3239-48, 2014
11. Munyentwali H et al: Rituximab is an efficient and safe treatment in adults with steroid-dependent minimal change disease. Kidney Int. 83(3):511-6, 2013
12. Chugh SS et al: New insights into human minimal change disease: lessons from animal models. Am J Kidney Dis. 59(2):284-92, 2012
13. Wei C et al: Minimal change disease as a modifiable podocyte paracrine disorder. Nephrol Dial Transplant. 26(6):1776-7, 2011
14. Garin EH et al: Urinary CD80 excretion increases in idiopathic minimal-change disease. J Am Soc Nephrol. 20(2):260-6, 2009
15. Deegens JK et al: Podocyte foot process effacement as a diagnostic tool in focal segmental glomerulosclerosis. Kidney Int. 74(12):1568-76, 2008
16. Waldman M et al: Adult minimal-change disease: clinical characteristics, treatment, and outcomes. Clin J Am Soc Nephrol. 2(3):445-53, 2007
17. Stokes MB et al: Glomerular tip lesion: a distinct entity within the minimal change disease/focal segmental glomerulosclerosis spectrum. Kidney Int. 65(5):1690-702, 2004
18. Fogo A et al: Glomerular hypertrophy in minimal change disease predicts subsequent progression to focal glomerular sclerosis. Kidney Int. 38(1):115-23, 1990
19. Jennette JC et al: Adult minimal change glomerulopathy with acute renal failure. Am J Kidney Dis. 16(5):432-7, 1990
20. Childhood nephrotic syndrome associated with diffuse mesangial hypercellularity. A report of the Southwest Pediatric Nephrology Study Group. Kidney Int. 24(1):87-94, 1983

(Left) *Jones methenamine silver stain shows that the GBMs have a normal thickness ⇨ in MCD with no duplication or glomerular hypercellularity.* **(Right)** *Glomerulus from a patient with MCD appears normal by light microscopy. The only clue that there is proteinuria is the presence of hypertrophied podocytes ⇨, which have increased, basophilic cytoplasm ⇨.*

Normal GBM

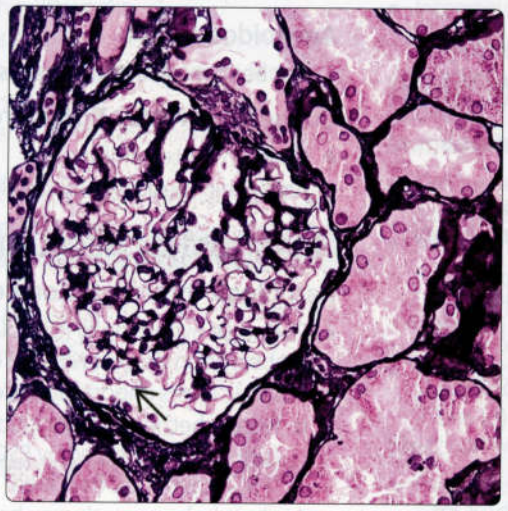

Hypertrophied Podocytes

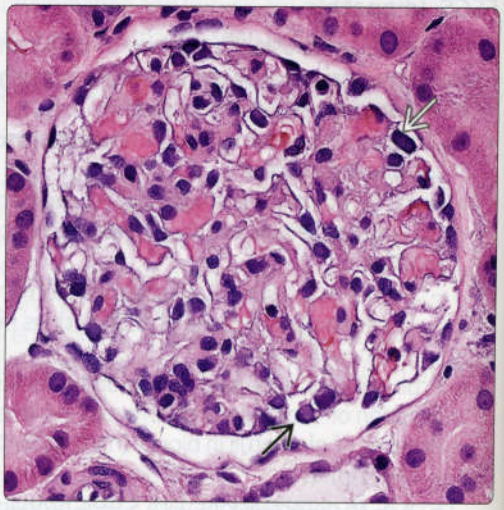

(Left) *This specimen is from a 5-year-old boy who presented with MCD. Glomeruli with an immature appearance are present, with crowded podocytes ⇨. This should not be confused with collapsing glomerulopathy.* **(Right)** *This "pseudoadhesion" ⇨ is due to a tangential section through the GBM in a patient with MCD. In presumed MCD, it is essential to search for evidence of FSGS in multiple levels, as adhesions and artifacts such as this can confound interpretation.*

Crowded Podocytes

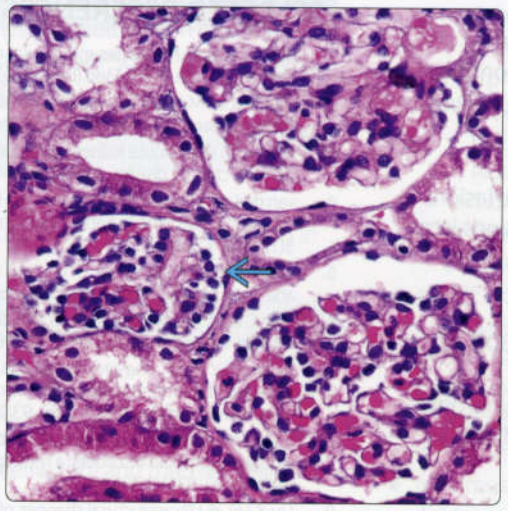

"Pseudoadhesion"

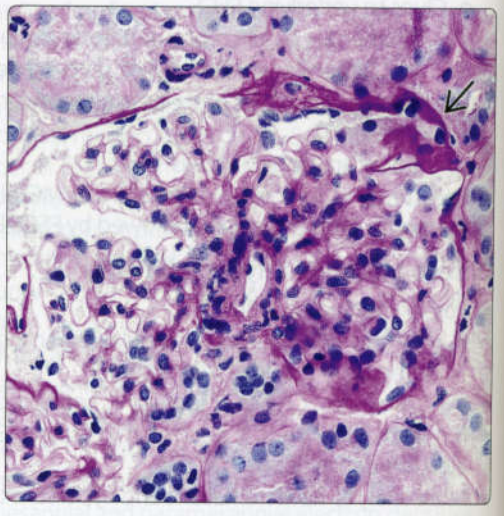

(Left) *PAS(+) tubular resorption droplets ⇨ in MCD are predominantly in the proximal renal tubules. These are found in any disease with glomerular proteinuria.* **(Right)** *Oil red O stain of a frozen section from a patient with MCD shows the characteristic lipid ⇨ in proximal tubules. These accumulate in tubules in all diseases with nephrotic-range proteinuria, but since the lipid was the only feature noted originally in MCD it lead to the term "lipoid nephrosis."*

Tubular Resorption Droplets

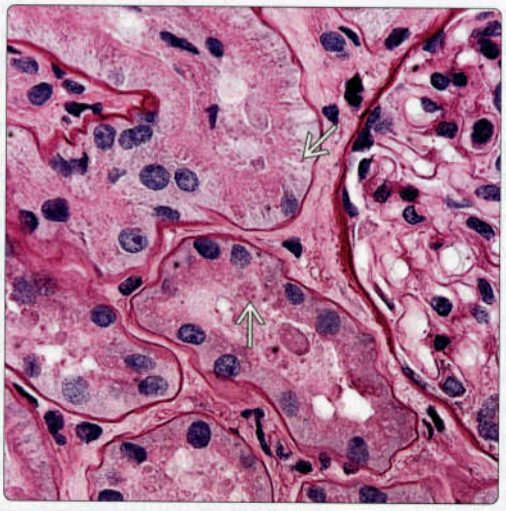

Lipid in Tubules

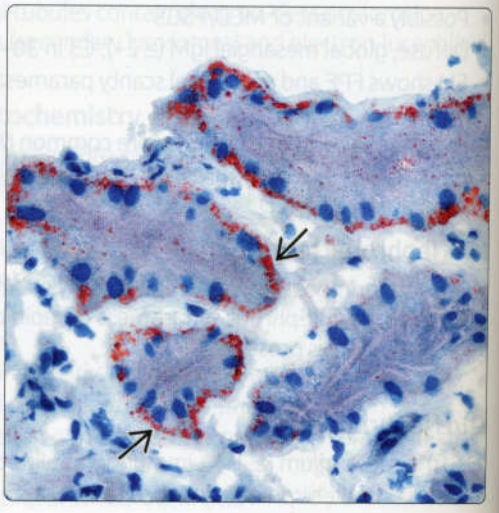

Minimal IgM Deposits

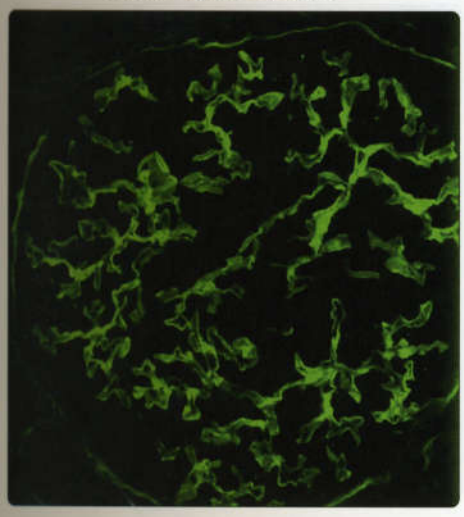

IgM Deposits

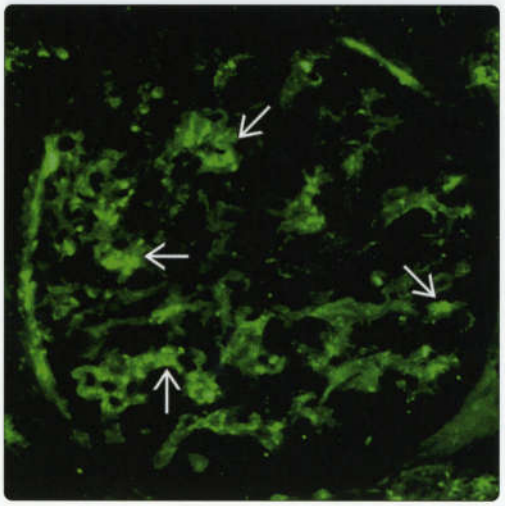

(Left) *Trace mesangial IgM can sometimes be seen in MCD. When 2+ IgM is present along with electron-dense deposits by electron microscopy (EM), some categorize the lesion as IgM nephropathy.* **(Right)** *In MCD, there can be mesangial staining for IgM, as in this case, which some might categorize as IgM nephropathy. This may be associated with decreased responsiveness to steroids.*

Negative IgA

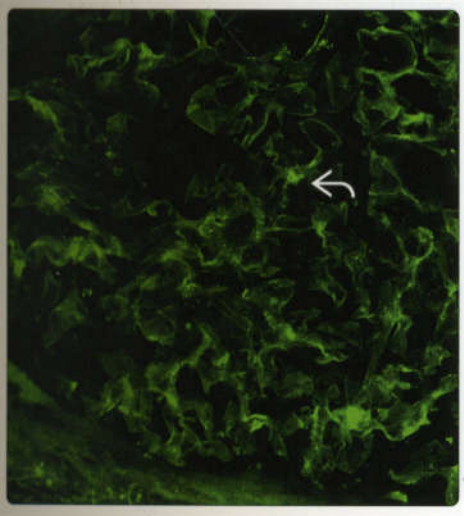

Glomerular C3

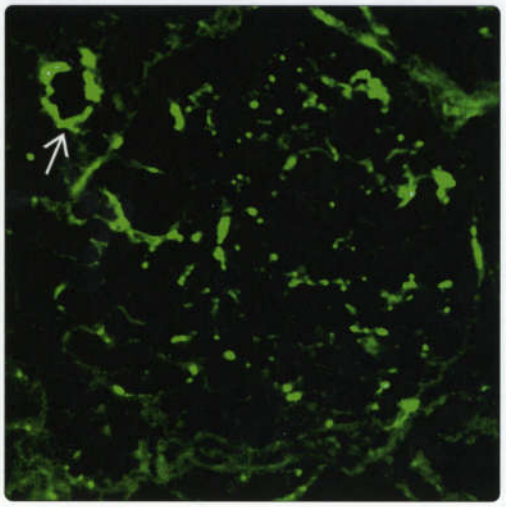

(Left) *In MCD, little or no immunoglobulin is typically present. In this case of MCD, no IgA is detected in the glomerulus aside from a few faint granules that are probably protein reabsorption droplets in the podocyte.* **(Right)** *This patient with MCD has more prominent C3 in the glomerulus. Most is probably in podocyte reabsorption droplets, and some is in the mesangium. The arterial wall also has C3, a common, nonspecific finding.*

Tubular Reabsorption Droplets

Reabsorption Droplets

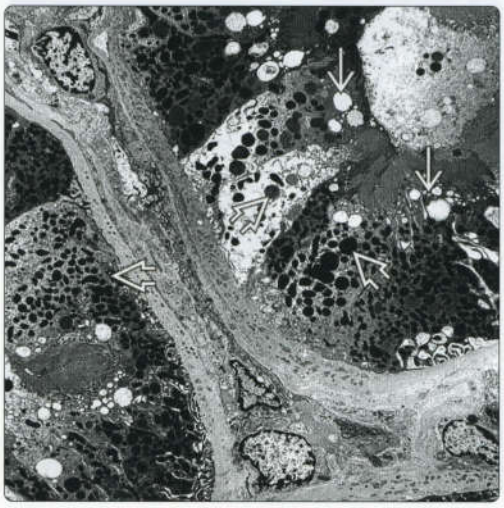

(Left) *Proximal tubules show abundant reabsorption droplets that stain for albumin in this patient with MCD. Other plasma proteins are commonly found as well. This may be the only abnormality by IF.* **(Right)** *The tubules in MCD may have frequent resorption droplets, some of which are clear on EM, representing lipid vacuoles, and some of which are electron-dense, representing proteinaceous droplets.*

(Left) *This patient with MCD shows expansion of the cell body surface area, a classic feature of the podocyte reaction to heavy proteinuria that produces villous hypertrophy ⇨. Foot processes are effaced, and the GBM is normal.* **(Right)** *Patient with MCD has swollen podocytes ⇨ but only patchy foot process effacement in this capillary.*

Podocyte Villous Hypertrophy

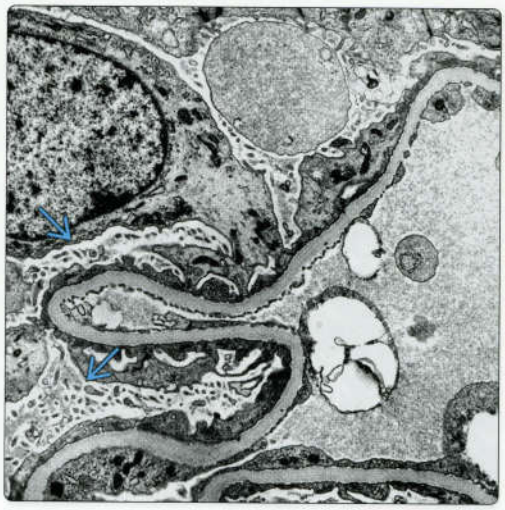

Swollen Podocytes

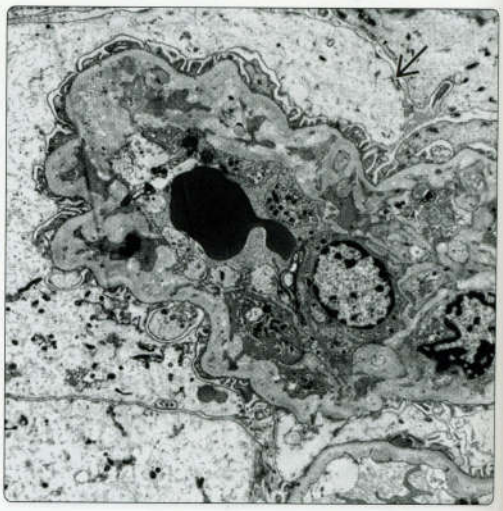

(Left) *In MCD, the mesangium can be mildly expanded with cellular debris ⇨. Vague densities ➡ may be present although these are not considered evidence of an immune complex-mediated disorder but rather of nonspecific entrapment.* **(Right)** *This specimen is from an 18-year-old man who presented with nephrotic syndrome due to MCD associated with retroperitoneal masses, later shown to be Hodgkin disease. Lymphoma is a cause of MCD but usually remits with remission of the lymphoma.*

Mildly Expanded Mesangium

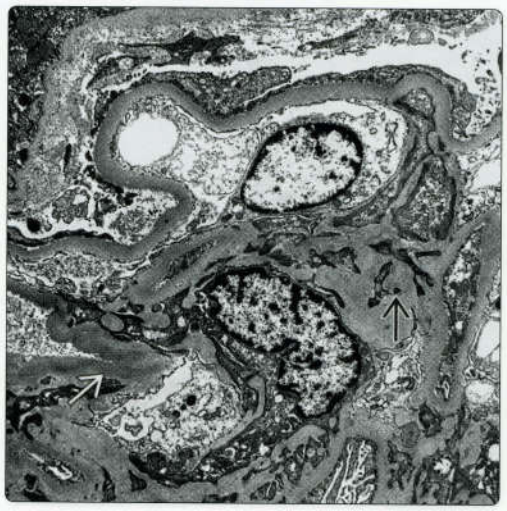

Minimal Change Disease Due to Lymphoma

(Left) *A 68-year-old woman presented with 3.4 g protein/day and edema associated with NSAIDs. Acute interstitial nephritis was also present. Drugs, especially NSAIDs, are associated with MCD.* **(Right)** *A 9-year-old girl with nephrotic syndrome was treated successfully with corticosteroids and biopsied when the proteinuria was in remission. EM shows complete recovery of foot processes ⇨.*

Minimal Change Disease Due to NSAIDs

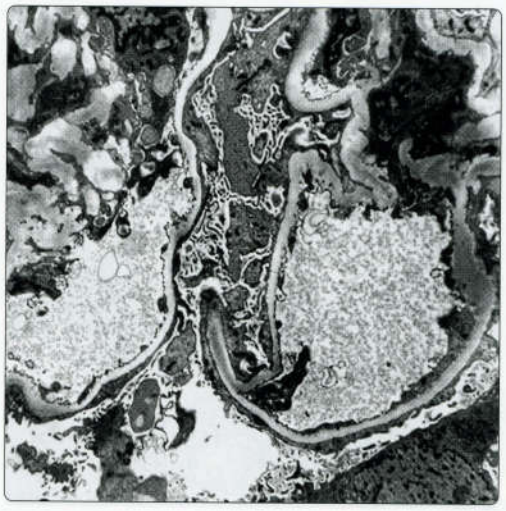

Recovery of Podocyte Foot Processes

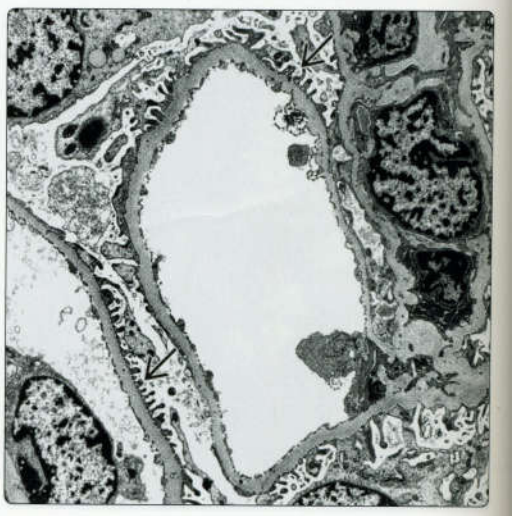

Minimal Change Disease and IgA Nephropathy

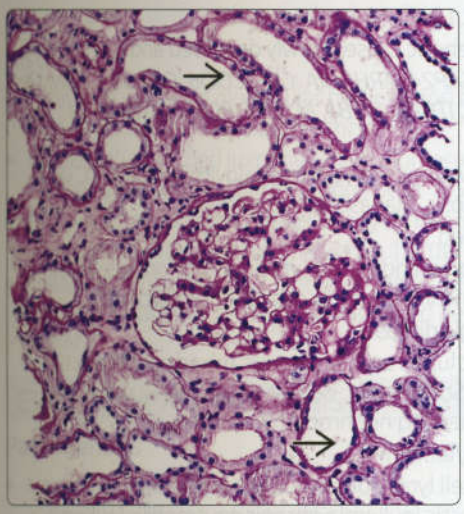

Minimal Change Disease and IgA Nephropathy

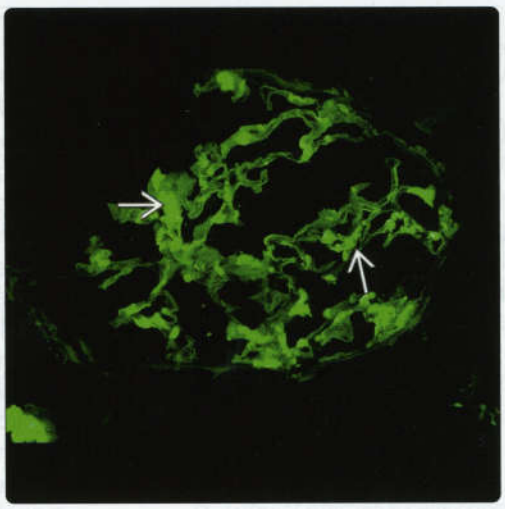

(Left) *Glomeruli in a 48-year-old man with acute onset of nephrotic syndrome and renal failure (albumin 1 g/dl, 15 g/d proteinuria, Cr 1.5 mg/dL) show mild mesangial hypercellularity. Dilated tubules show flattened epithelium. IgA was prominent by IF.* **(Right)** *IF in a patient with an acute nephrotic syndrome clinically suspicious for MCD reveals bright granular mesangial staining for IgA. Glomeruli showed similar staining for C3 and both light chains. There was widespread foot process effacement by EM.*

Minimal Change Disease and IgA Nephropathy

Minimal Change Disease With C1q Nephropathy

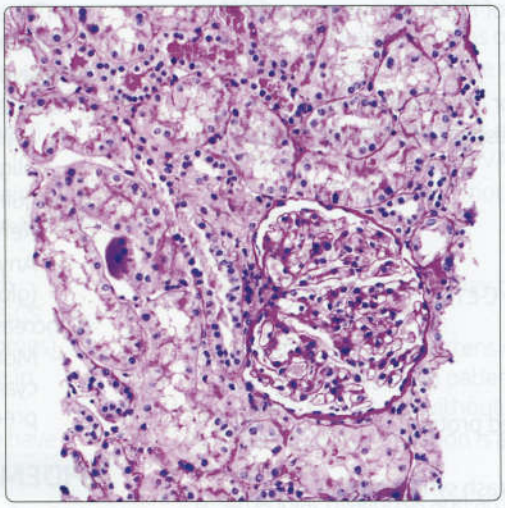

(Left) *Ultrastructural study reveals diffuse podocyte foot process effacement, typical of MCD. Mesangial and paramesangial electron-dense deposits are present as well, part of IgA nephropathy.* **(Right)** *Biopsy from a 20-year-old man with sudden onset of nephrotic syndrome with anasarca and 10 g/d proteinuria shows glomeruli appearing normal. C1q was 2+ in the mesangium associated with electron-dense deposits.*

Minimal Change Disease and C1q Nephropathy

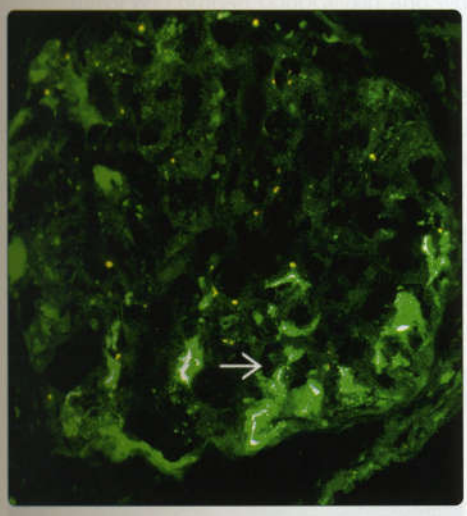

Minimal Change Disease and C1q Nephropathy

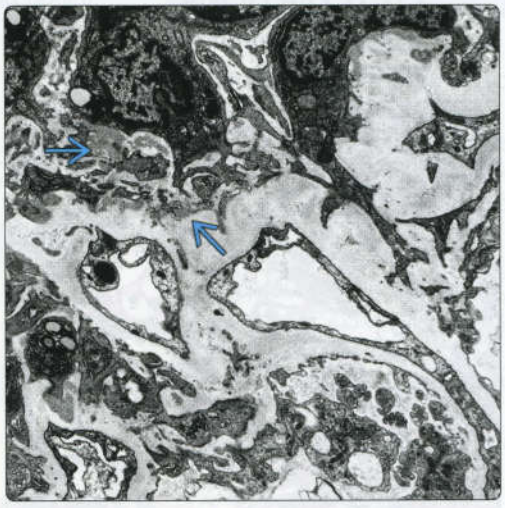

(Left) *Staining for C1q reveals 2+ granular mesangial staining. C1q was the dominant immunoreactant in this case; there was lesser staining of glomeruli for IgG κ and γ, and stains for IgA were negative. The patient did not have clinical or laboratory evidence of SLE and otherwise had MCD.* **(Right)** *There are scattered amorphous mesangial electron-dense deposits within the glomeruli in this patient with MCD and C1q nephropathy.*

TERMINOLOGY

Abbreviations

- Focal segmental glomerulosclerosis (FSGS)

Definitions

- Group of podocytopathies (of varied etiology) sharing feature of FSGS, typically with moderate to heavy proteinuria

CLASSIFICATION SYSTEMS

Morphologic Classification

- Based on glomerular morphology, categories defined by Columbia classification
  - Collapsing variant
  - Glomerular tip lesion
  - Cellular variant
  - Perihilar variant
  - FSGS not otherwise specified (NOS)

Etiologic Classification

- Based on identified causes of FSGS: Some correspondence with morphologic variants
- Idiopathic (primary)
  - Usual form, either NOS or collapsing variant
  - Circulating factor likely responsible, identity elusive
- Genetic
  - Nonsyndromic
    - *NPHS1* (nephrin)
    - *NPHS2* (podocin)
    - *PLCE1* (phospholipase C ε1)
    - *INF2* (familial FSGS)
    - *ACTN4* (α-actinin-4)
    - *TRPC6* (familial CG)
    - *CD2AP* (CD2-associated protein)
  - Syndromic
    - *WT1* (Frasier, Denys-Drash syndromes)
    - *COL4A3, COL4A4* (Alport syndrome)
    - *LAMB2* (Pierson syndrome)
    - *LMB1X* (nail-patella syndrome)
    - *WDR73* (Galloway-Mowat syndrome)
    - *COQ2* (CoQ10 deficiency)
    - *MT-TL1* (MELAS syndrome)
  - Other genetic causes, newly described and rare
    - *ARHGAP24, ARHGDIA, CFH, COQ6, COQ8B, CUBN, GLA, DGKE, ITGA3, ITGB4, MYO1E, PDSS2, SMARCAL1*
- Infections
  - HIV, parvovirus B19, cytomegalovirus, hepatitis C virus, tuberculosis, filariasis, schistosomiasis
- Drug-induced
  - Interferon-α and -β, lithium, bisphosphonates, heroin, calcineurin inhibitors, sirolimus, anthracyclines
- Immunologic diseases
  - Systemic lupus erythematosus, mixed connective tissue disease, Still disease, Behçet syndrome, Guillain-Barré syndrome, C1q nephropathy
- Lymphoma/leukemia
  - Mantle cell lymphoma, multiple myeloma, acute monoblastic leukemia, chronic neutrophilic leukemia, NK-cell leukemia, hemophagocytic syndrome
- Vascular
  - HTN, atheromatous emboli, sickle cell disease, thrombotic microangiopathy
- Adaptive, structural-functional responses
  - Congenital deficiency of nephrons
    - Unilateral renal agenesis, dysplasia/hypoplasia, oligomeganephronia, prematurity/low birth weight
  - Acquired loss of nephrons
    - Reflux nephropathy
    - Any scarring disease that severely reduces nephrons (glomerular, tubular, interstitial, vascular)
  - Increased metabolic demand
    - Morbid obesity, anabolic steroid abuse, acromegaly, cyanotic congenital heart disease, diabetes mellitus, preeclampsia, glycogen storage disease

EPIDEMIOLOGY

Incidence

- Most common cause of nephrotic syndrome in adults

FSGS Lesion in a Glomerulus

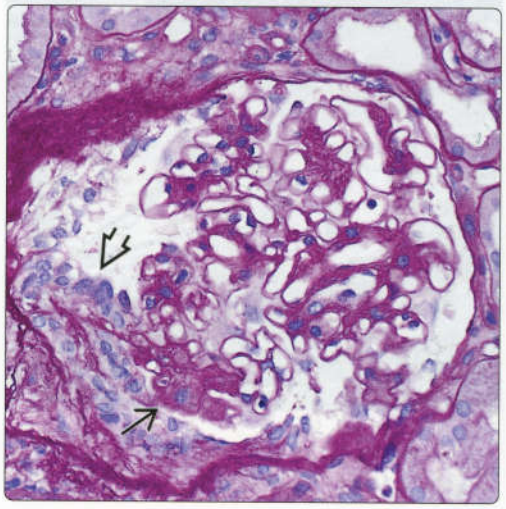

Segmental C3 Deposition

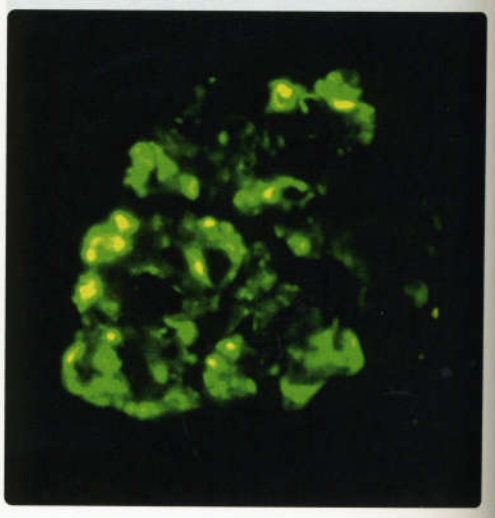

(Left) *An early segmental sclerosing lesion ⇨ with active bridging of activated parietal epithelial cells onto the tuft, forming a tuft adhesion to Bowman's capsule ⇨, is shown here.* **(Right)** *Immunofluorescence for C3 shows a predominantly segmental pattern of staining in the mesangium and in areas of glomerular capillary loop collapse in a case of focal FSGS.*

- Apparent increased incidence over past 2 decades
  - ~ 25% of adult nephropathies, compared with < 10% 20 years ago

History

- Focal and segmental glomerular hyalinization and capillary loop degradation described by Fahr in 1925
- Arnold Rich described juxtamedullary glomerulosclerosis in children dying with nephrotic syndrome in 1957
- FSGS was recognized as distinct entity by International Study of Kidney Diseases in Children in 1970s
- Collapsing variant was recognized by Mark Weiss in 1980s and later as usual pattern of HIV-associated nephropathy (HIVAN)

ETIOLOGY/PATHOGENESIS

Pathogenesis

- Now classified as podocytopathies
  - Familial podocyte protein defects
    - Mutations in *TRPC6*, calcium-permeable cation channel, lead to abnormal podocyte function and hereditary FSGS
    - FSGS with defects in α-actinin-4 (*ACTN4*), podocin (*NPHS2*, defective in corticosteroid-resistant nephrotic syndrome), and nephrin (*NPHS1*, defective in congenital nephrotic syndrome of Finnish type) are relatively rare familial forms of FSGS
    - Nephrin interacts with CD2-associated protein (CD2AP), and podocin interacts with nephrin-CD2AP complex
    - Mutations in WT1 transcription factor, which regulates several podocyte genes, lead to FSGS syndromes (Denys-Drash and Frasier syndromes)
  - Abnormal cytokines thought to play major role in idiopathic FSGS development
    - Circulating factor identified in patients who have recurrent FSGS after transplant, typically occurring within months after transplantation
  - Podocyte dysregulation/dysfunction
    - Differentiation markers of podocytes (e.g., Wilms tumor WT1 protein, podocalyxin, and synaptopodin) disappear in collapsing FSGS and HIVAN
  - Loss of podocytes leads to adhesions
  - Risk factor in African descent is *APOL1* gene
- Relationship with minimal change disease (MCD) unclear
  - Dystroglycan, integral component of GBM, is decreased in MCD but maintained in nonsclerotic segments in FSGS

MACROSCOPIC

General Features

- Pale yellow kidneys due to lipid in tubules

MICROSCOPIC

General Features

- Glomeruli
  - Sclerosis involves some glomeruli (focal) and only portion of glomerular tuft (segmental)
    - Diagnosed even when only 1 glomerulus involved
    - Global sclerosis may be incidental finding and is not particularly useful in making diagnosis of FSGS
  - Adhesions (synechiae) of glomerular tuft to Bowman space often accompany segmental sclerosis and are often seen early in sclerosis process
  - Hyalinosis
    - Portion of glomerular involvement has smooth, glassy (hyaline) appearance
    - Typically thought to occur from insudation of plasma proteins
  - Increased matrix with obliteration of glomerular capillary lumen
  - FSGS has zonal distribution, beginning in corticomedullary (juxtamedullary) junction (CMJ)
    - Important to note whether sampling of CMJ is included
  - Glomerular hypertrophy often accompanies FSGS
    - Potential surrogate marker in cases without sampled segmental sclerosis
- Tubules
  - Tubular epithelial cells contain PAS(+) reabsorption droplets due to glomerular proteinuria
  - Tubular atrophy is typically only focal early in course of FSGS
    - TBM thickened in areas of atrophy
    - Tubular atrophy may be more prominent late in course of disease
  - Tubulointerstitial changes pronounced in collapsing variants of FSGS and in HIVAN
    - Cystic dilatation and more prominent lymphoid infiltrate
- Interstitium
  - Interstitial fibrosis (IF) may be present and is typically focal
    - Some cases have extensive IF ± tubular atrophy (TA), and IF/TA in young patients may indicate unsampled FSGS in patients without identified glomerulosclerosis
  - Interstitial inflammation is absent or minimal
- Vessels
  - Arteriolar hyalinosis and arterial intimal fibrosis may be prominent late in course of FSGS

ANCILLARY TESTS

Immunofluorescence

- IgM and C3 often positive in sclerotic areas or areas of mesangial matrix increase
  - Thought to be nonspecific entrapment
  - IgM staining without EM deposits does not appear to have etiologic, prognostic, or diagnostic significance

Electron Microscopy

- Foot process effacement (FPE) typically not complete
- Secondary FSGS usually shows less FPE than idiopathic forms of FSGS
- In HIVAN, tubuloreticular inclusions can sometimes be identified
- Subepithelial multilamination of GBM in collapsing variant

FSGS Morphologic Classification Algorithm

Variant	Diagnostic Criteria	Exclude	Prognosis	% of 1° FSGS
Collapsing	≥ 1 glomerulus with collapse with segmental or global collapse and podocyte hyperplasia and hypertrophy	None	Poor	8-12%
Tip	≥ 1 segmental lesion in tip domain (outer 25% of tuft next to proximal tubule origin), adhesion is required at tubular lumen or neck	Collapsing variant, perihilar sclerosis	Possibly better prognosis	1-10%
Cellular	≥ 1 glomerulus with segmental or global endocapillary hypercellularity occluding lumina, ± karyorrhexis and foam cells	Collapsing and tip variants	Possibly early-stage lesion	1-3%
Perihilar	≥ 1 glomerulus with perihilar hyalinosis, ± sclerosis	Collapsing, tip, and cellular variants	Might often be a secondary type of FSGS	1-7%
FSGS (NOS)	≥ 1 glomerulus with segmental increase in matrix obliterating capillary lumina	Collapsing, tip, cellular, and perihilar variants	Usual course	68-90%

FSGS Morphologic Features

Variant	Location	Distribution	Hyaline	Adhesion	PCH	MHC	GM	AH
Collapsing	Anywhere	Segmental or global	-/+	-/+	+++/-	-/+	-/+	-/+
Tip	Tip domain	Segmental	+/-	+++/-	++/-	-/+	-/+	-/+
Cellular	Anywhere	Segmental	-/+	-/+	++/-	-/+	-/+	-/+
Perihilar	Perihilar	Segmental	++/-	+++/-	-/+	-/+	+++/-	++/-
FSGS (NOS)	Anywhere	Segmental	+/-	++/-	-/+	-/+	+/-	+/-

AH = arteriolar hyalinosis; GM = glomerulomegaly; MHC = mesangial hypercellularity; PCH = podocyte hyperplasia. Features are expressed as "most common/least common presentation." Each (+) denotes the approximate frequency at which the features occur; (-) denotes that this feature may be absent. Adapted from D'Agati et al: Pathologic classification of focal segmental glomerulosclerosis: a working proposal. Am J Kidney Dis. 43(2):368-82, 2004.

DIFFERENTIAL DIAGNOSIS

Focal Glomerulonephritis

- IgA nephropathy, lupus, and other inflammatory glomerulonephritis can result in segmental scars in glomeruli
- Breaks in GBM sometimes evident in PAS/silver stains (not seen in FSGS)

Minimal Change Disease

- No segmental sclerosis, unless segmental sclerosis is preexistent due to other etiology
- Numerous globally sclerotic glomeruli, IF, and vascular changes in patient with nephrotic syndrome are suggestive of FSGS even if no segmental lesions are seen

DIAGNOSTIC CHECKLIST

Pathologic Interpretation Pearls

- Multiple levels (step sections) may be needed to identify focal segmental lesions
- Note whether corticomedullary junction is sampled
- Adequate sample of glomeruli is crucial to make diagnosis of FSGS since focal lesions may be missed with small samples
  - For example, biopsy with 10 glomeruli has 35% probability of missing focal lesion present in 10% of glomeruli in kidney, whereas probability decreases to 12% if 20 glomeruli are sampled
- Repeat biopsies show transition to NOS category in ~ 50% of patients with non-NOS patterns on initial biopsy

SELECTED REFERENCES

1. De Vriese AS et al: Differentiating primary, genetic, and secondary FSGS in adults: a clinicopathologic approach. J Am Soc Nephrol. 29(3):759-74, 2018
2. Rosenberg AZ et al: Focal segmental glomerulosclerosis. Clin J Am Soc Nephrol. 12(3):502-17, 2017
3. Trautmann A et al: Long-term outcome of steroid-resistant nephrotic syndrome in children. J Am Soc Nephrol. 28(10):3055-65, 2017
4. Zhong Y et al: The evolution of morphological variants of focal segmental glomerulosclerosis: a repeat biopsy-based observation. Nephrol Dial Transplant. 31(1):87-95, 2016
5. Fogo AB: Causes and pathogenesis of focal segmental glomerulosclerosis. Nat Rev Nephrol. 11(2):76-87, 2015
6. Sadowski CE et al: A single-gene cause in 29.5% of cases of steroid-resistant nephrotic syndrome. J Am Soc Nephrol. 26(6):1279-89, 2015
7. Stokes MB et al: Morphologic variants of focal segmental glomerulosclerosis and their significance. Adv Chronic Kidney Dis. 21(5):400-7, 2014

Normal Glomerulus

Collapsing Variant

(Left) *Features that are important to consider in FSGS include the podocytes, the hilar region with the afferent and efferent arterioles, the endocapillary cells, sclerosis along glomerular basement membranes, and the "tip" of the glomerulus at the tubular pole.* **(Right)** *In FSGS collapsing variant, at least 1 glomerulus has collapse and an overlying podocyte hypertrophy/hyperplasia together with glomerulosclerosis.*

Tip Variant

Cellular Variant

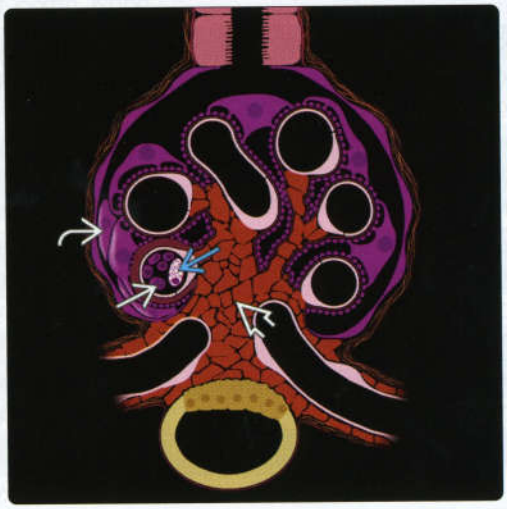

(Left) *In FSGS "tip" variant, there is at least 1 segmental lesion involving the tip domain, often coupled with an adhesion, podocyte hypertrophy, and intraluminal foam cells.* **(Right)** *In FSGS cellular variant (rarest type), there is at least 1 glomerulus with segmental endocapillary hypercellularity occluding lumina, often with inflammatory cells, foam cells, karyorrhexis, overlying podocyte hyperplasia, and mesangial hypercellularity. Some consider this within the collapsing group.*

Perihilar Variant

FSGS, Not Otherwise Specified Variant

(Left) *In FSGS perihilar variant, at least 1 glomerulus has perihilar hyalinosis/sclerosis, which must be present in over 50% of glomeruli with segmental lesions. This is typical of adaptive FSGS.* **(Right)** *In FSGS (NOS), at least 1 glomerulus must have segmental increase in the matrix that obliterates the capillary lumina. This is often in a peripheral, nonspecific pattern of sclerosis ± overlying podocyte hypertrophy. This random distribution of scarring is the most common pattern in idiopathic (primary) FSGS.*

Etiologies of FSGS

Disease	Distinctive Pathology Features	Comments	PMID
Primary			
Idiopathic FSGS	Histology: ~ 80% NOS, ~ 10% CG, ~ 5% TIP, ~ 5% PH, ~ 1% CV; FPE > 40%	Circulating factor, various candidates, none confirmed; recurs in transplants	28242845 25447132
Genetic: Primarily Kidney Involvement			
Congenital nephrotic syndrome (Finnish) *NPHS1*	May have only DMS	7% of familial SRNS; milder cases reported in adulthood (AR)	19812541 26195142
Podocin deficiency *NPHS2*	May have diffuse mesangial hypercellularity without FSGS	10% of familial SRNS; childhood or congenital; ~ 7% of sporadic FSGS in children; ± *NPHS1* mutations (AR)	24856380 29474669
Phospholipase Cε1 *PLCE1*	DMS 18-40%	2% of familial SRNS (AR); not found in sporadic FSGS	25349199
Familial collapsing FSGS *TRPC6*	CG	0.5% of familial SRNS (AR); ESRD >21 years (AD)	23689571
CD2AP deficiency *CD2AP*	CG; diffuse mesangial IgM	Heterozygote in ~ 3% sporadic SRNS (AR)	17713465
α-actinin-4 *ACTN4*	Podocyte cytoplasmic aggregates	Adult onset, may have hematuria (AD)	27977723
Apolipoprotein L1 *APOL1*	CG	2 G1 and G2 risk alleles in 10-15% of African Americans; affects other renal diseases, donor kidneys (AR)	29389775
Dent disease *CLCN5*	CaPhos; metachromatic casts	Hypercalciuria, tubular proteinuria (X)	24810952
Other genes (rare)	Scant pathology information	*ANLN, ARHGAP24, ARHGDIA, EMP2, LAMA5, MAGI2, MYO1E, PODXL, PTPRO, TTC21B*	29127259
Genetic: Often With Extrarenal Involvement			
Autosomal dominant FSGS *INF2*	NOS, CG, minimal change disease; jagged foot processes	0.5% of familial SRNS; 12% have Charcot-Marie-Tooth (AD); does not recur in transplants	20023659 29038887
Frasier and Denys-Drash syndromes *WT1*	PH, NOS; DMS common (23%) (especially Denys-Drash)	4.8% of familial SRNS; Wilms tumor (Denys-Drash); male pseudohermaphroditism (Frasier); (AD)	27596598
Pierson syndrome *LAMB2*	DMS 14%	1% of familial SRNS; microcoria (AR)	29673759
Alport syndrome *COL4A3, COL4A4*	NOS or PH; GBM irregularities not diagnostic of Alport	Familial FSGS with proteinuria, hematuria (AR, X); may be no eye or hearing signs; estimated ~ 10% of familial FSGS	25229338 21908087
Schimke immunoosseous dysplasia *SMARCAL1*	CG, TIP; TUNEL + podocytes, parietal and tubular epithelium	T-cell deficiency, spondyloepiphyseal dysplasia; 0.9% of familial SRNS (AR)	25319549
Nail-patella syndrome *LMX1B*	Banded collagen in GBM	FSGS can occur without extrarenal signs (AD)	23687361
Galloway-Mowat *WDR73*	CG, DMS	Microcephaly (AR)	25873735
Epidermolysis bullosa *ITGA3/B4*		Childhood onset (AR)	24902943
Epstein Fechtner *MYH9*		Deafness, leukocyte inclusions, macroplatelets (AR)	21210153
Fabry disease *GLA*	CG, NOS; EM lipid inclusions	Late change (X)	28980669
CoQ10 deficiency *COQ2, COQ8B, COQ6, PDSS2, ADCK4*	CG; dysmorphic mitochondria	0.2% of familial SRNS (AR); hearing loss; treated with oral CoQ10	17855635 29637272
MELAS syndrome (*MT-TL1,2,Y*)	NOS; dysmorphic mitochondria	Encephalomyopathy, lactic acidosis, stroke-like episodes	29190634
Nuclear pore *NUP93, NUP205, NUP107, XPO5*		Microcephaly (AR)	27190346
Other genes (rare)	Scant pathology information	*ALG1, CD151, CRB2, CUBN, EYA1, IKBKAP, KANK1,2,4, LMNA, NXF5, PAX2, PMM2, SCARB2, SPGL1, ZMPSTE24*	27987548
Infection			
HIV	CG, TRS, tubular dilation, infiltrate	Associated with *APOL1* risk alleles	29236630
Parvovirus B19	CG, TRS, tubular dilation, infiltrate	Associated with *APOL1* risk alleles	27600725
CMV	CG, TIP, abundant TRS	Associated with *APOL1* risk alleles	26849829
HCV	NOS, CG	Direct acting antiviral treatment	28211090
Tuberculosis	CG, NOS		23594801
Filariasis (*Loa loa*)	CG; microfilariae in vessels		22325313
Schistosomiasis	CG	Black race risk factor; persists after schistosomal therapy	22124564
Drugs			
Interferon (α, β, γ)	Abundant endothelial TRS	**100%** *APOL1* risk alleles; improved after drug withdrawal	20203164
Lithium	Microcysts	Progression even with drug withdrawal if Cr > 2.5	10906157

Etiologies of FSGS (Continued)

Disease	Distinctive Pathology Features	Comments	PMID
Bisphosphonates	CG	Occasionally with single dose	18685574
Calcineurin inhibitors	CG, severe hyaline arteriolopathy	Allograft and native kidneys	28571148
Sirolimus	NOS, ↓ VEGF expression	Improved after discontinuation of drug	21716195
Anthracyclines	CG, NOS	Improved after discontinuation of drug	23219112
Immunological Diseases			
SLE	TV, NOS, PH, CG, NOS; with class II	Also minimal change disease	26983707
MCTD	CG		21269591
Adult Still disease	CG		15112192
Behçet syndrome	CG	Remission on cyclosporine	21833522
Guillain-Barré syndrome		Remission of nephropathy with neuropathy	24726719
C1q nephropathy	CG, NOS	May have *APOL1* association	18650484
Membranous GN	NOS, PH; ↓ glomerular CD34(+) cells		25875837
Lymphoma/Leukemia			
Mantle cell lymphoma	NOS	Remission with chemotherapy	26354841
Multiple myeloma	CG	Partial remission with myeloma treatment	15022922
Acute monoblastic leukemia	CG	Related to GVHD	17879218
Chronic neutrophilic leukemia	Interstitial neutrophil infiltrate	Remission with hydroxyurea/interferon	25366011
Natural killer cell leukemia	CV, CG		21908087
Hemophagocytic syndrome	CG; MCD	Rare survival	16557222
Vascular Diseases			
Atheroembolism	CG; emboli		9041208
Thrombotic microangiopathy	CG, NOS, CV, PH, TV	Transplanted and native kidneys; various causes	27650730
Sickle cell disease	CG, NOS, sickled cells in capillaries		20075701
Adaptive (Maladaptive or Post Adaptive)			
All causes	PH, glomerular hypertrophy, thickened GBM, little FPE (< 40%)	Usually slow progression	25447132
Congenital Deficiency of Nephrons			
Dysplasia/hypoplasia	Cartilage, decreased lobes		2302871
Unilateral renal agenesis	NOS, PH	May be familial; genetic causes. e.g., mutation to *HNF1B*	8503422
Oligomeganephronia	Small kidneys, < 50% normal	Infancy, later ESRD (*PAX2, EYA1, SIX5, SIX1, TCF1*)	6490319
Prematurity/low birth weight	PH	Birth weight < 1,500 g; FSGS in adolescence or later	19019999
Acquired Loss of Nephrons			
Reflux nephropathy	Dilated ureter, hydronephrosis	Associated with hypertension	8008693
Any disease that severely reduces nephrons	Pathologic features of underlying disease (e.g., IgA, pyelonephritis)		21178978
Increased Metabolic Demand			
Anabolic steroid abuse	PH, CG	Stabilized off drugs; relapse when resumed	19917783
Morbid obesity	PH	BMI ≥ 30; remission after bariatric surgery	27263398
Acromegaly	Glomerulomegaly	Remission reported after pituitary surgery	11499662
Congenital heart disease	PH, NOS	With cyanosis; remission with ACE inhibitor	11773480
Diabetes mellitus	CG, GBM thickening	Obesity, vascular disease and *APOL1* also contribute	24081860
Preeclampsia	Endothelial swelling	FSGS, if present, may come first	23334478
Glycogen storage disease	NOS	Onset 13-47 years	21620087

Isolated case reports: HTLV-1, Prader-Willi, Turner syndrome, renal tubular acidosis. Abbreviations: AD = autosomal dominant; AR = autosomal recessive; CV = cellular variant; CG = collapsing glomerulopathy; DMS = diffuse mesangial sclerosis; FPE = foot process effacement; NOS = not otherwise specified variant; PH = perihilar variant; PMID = PubMed identifier; SRNS = steroid resistant nephrotic syndrome; TIP = tip variant; X = X-linked.

De Vriese et al. Differentiating primary, genetic and secondary FSGS in Adults, a clinicopathologic approach. J Am Soc Nephrol 29:759-74, 2018.

Focal Segmental Glomerulosclerosis, Primary

KEY FACTS

ETIOLOGY/PATHOGENESIS

- Idiopathic disease with podocytopenia and parietal cell activation
- Plasma factor and genetic predisposition

CLINICAL ISSUES

- Common cause of nephrotic syndrome in children and adults (15-20% of biopsies)
- More common in patients of African descent
- Therapy
  - Minority respond to steroids (~ 33%)
  - Cyclophosphamide, cyclosporine, plasmapheresis
  - Under study: Rituximab, abatacept
- Recurs in transplants

MICROSCOPIC

- 5 pathologic variants (Columbia classification)
  - Not otherwise specified (NOS): Random distribution of adhesions (commonest)
  - Tip: Adhesion at inlet of proximal tubule
  - Perihilar: Adhesion around hilum
  - Cellular: Endocapillary hypercellularity
  - Collapsing: Collapse and hypercellularity of podocytes
- Juxtamedullary glomeruli affected early
- Hyaline can accumulate at adhesion
- Foot process effacement and loss by electron microscopy
- IgM and C3 in segmental scars by immunofluorescence

TOP DIFFERENTIAL DIAGNOSES

- Secondary forms of FSGS with known cause
- Minimal change disease
- FSGS superimposed on other glomerular diseases

DIAGNOSTIC CHECKLIST

- Multiple levels may be needed to sample segmental scar
- FSGS NOS is diagnosis of exclusion; other diseases can cause segmental glomerular scars

(Left) *FSGS is a light microscopic pattern of segmental glomerular scarring affecting some glomeruli, typically with hyaline ➡ and adhesion ➡ to the Bowman capsule (BC). Most of the glomerulus appears normal, podocytes show reactive features ➡.* **(Right)** *Defining features of FSGS are sparing of some glomeruli (focal) and partial involvement of affected tufts (segmental). The affected glomerulus shows segmental tuft adhesion and hyalinosis ➡.*

FSGS in a Glomerulus

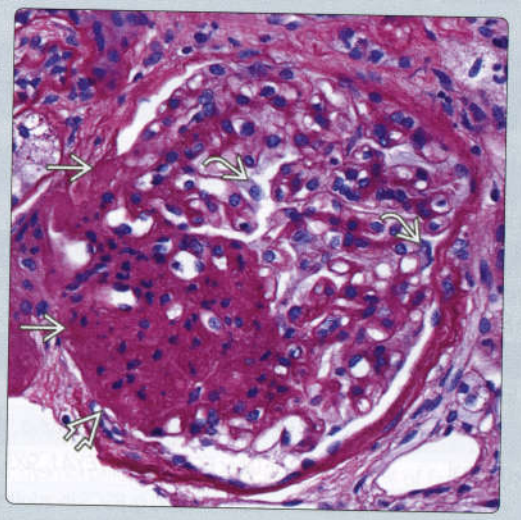

Adhesion and Hyalinosis

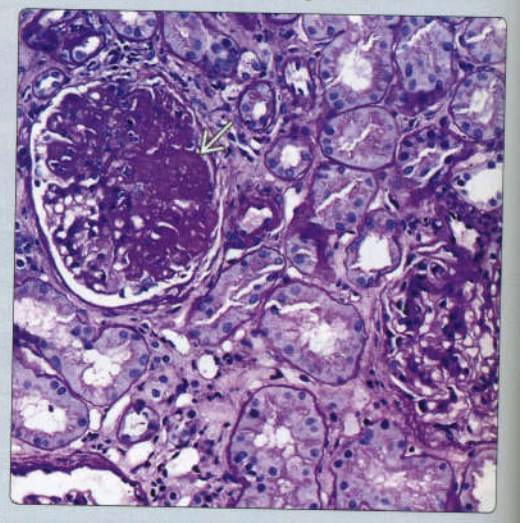

(Left) *IgM is segmentally present in the scarred segment of the glomerulus ➡, representing entrapped macromolecules. C3 is typically also present in scarred segments. Otherwise, little or no immunoreactants are present.* **(Right)** *Electron microscopy (EM) in primary FSGS reveals extensive foot process effacement ➡ and is often indistinguishable from minimal change disease. The GBM is usually of normal thickness. No electron-dense deposits are present. Areas of denuded GBM can be present.*

IgM in Segmental Scar

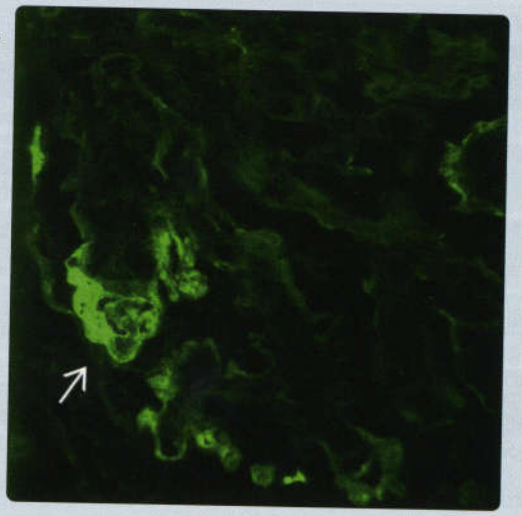

Extensive Foot Process Effacement in FSGS

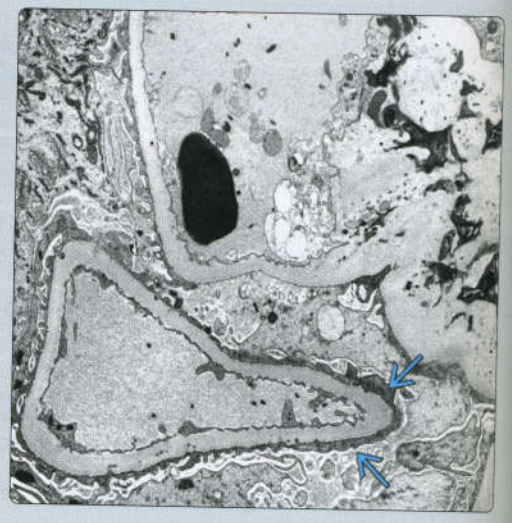

TERMINOLOGY

Abbreviations

- Focal segmental glomerulosclerosis (FSGS)

Synonyms

- Idiopathic FSGS

Definitions

- Idiopathic glomerular disease manifested by marked proteinuria, often nephrotic syndrome, with segmental scars in some glomeruli, adhesion of tuft to Bowman capsule (BC), and extensive foot process effacement (FPE)
  - Pattern of injury classified separately from FSGS secondary to known causes [genetic disorders, infection, drugs, glomerulonephritis (GN), and adaptive responses]
  - As more specific causes are identified, idiopathic FSGS category will diminish and will be replaced by known etiologies
- Pathologic classification (Columbia): Adhesions are randomly distributed [not otherwise specified (NOS)] at origin of proximal tubule (tip variant) or at hilum (perihilar variant); glomeruli may show endocapillary hypercellularity (cellular variant) or tuft collapse (collapsing variant)

ETIOLOGY/PATHOGENESIS

Podocyte Disease/Podocytopathy

- Podocyte depletion believed to be central mechanism (podocytopenia)
  - Podocytes are postmitotic cells with limited replicative ability
  - Multiple mechanisms of podocyte loss are likely
    - TGF-β is mediator in animal models
    - Podocyte detachment &/or cell death
- Podocyte loss leads to bare GBM, promoting adhesion and repopulation by parietal epithelial cells

Circulating Plasma Factor

- Proteinuria often vigorously recurs after renal transplant, sometimes within minutes of reperfusion (recurrent FSGS)
- Recurrent FSGS patient serum causes proteinuria in rats, and glomeruli isolated from these rats have ↑ glomerular permeability
- Identification of plasma factor remains elusive; no proposed candidates are definitively proven as causative in human disease
  - Cardiotrophin-like cytokine-1
  - Soluble urokinase plasminogen activator receptor (suPAR)

Genetic Factors

- Genetic factors may predispose to developing FSGS after diffuse podocyte insult
- Several forms of FSGS with similar morphology have genetic defect (e.g., *NPHS2, ACTN4*)
- ↑ FSGS risk in African Americans with *APOL1* gene variants

Tubulointerstitial Injury

- Proteinuria thought to cause tubulointerstitial injury by ↑ tubular chemokine expression and endoplasmic stress

CLINICAL ISSUES

Epidemiology

- Incidence
  - 2.2% of ESRD in USA (2004-2008)
    - 11.6% of ESRD in children (2008-2014)
  - Increasing incidence in children and adults
    - FSGS-related ESRD increased 49x from 1980 to 2000
  - ~ 20% of adult renal biopsies for nephrotic syndrome
  - 30-70% NOS, 20-40% tip, 3-5% cellular (more common in children)
- Age
  - Mean age at onset: ~ 37-50 years in adults, ~ 6-7 years in children
- Sex
  - Male preponderance (1.5-3x)
- Ethnicity
  - ESRD from FSGS 4-5x more common in individuals of recent African descent due to *APOL1* risk alleles
    - African descent: Lifetime risk 1:556
    - Caucasians: Lifetime risk 1:2,500

Presentation

- Sudden onset nephrotic-range proteinuria (> 3.5 g/d), often with full nephrotic syndrome
  - ~ 60% with NOS variant
  - ~ 97% with tip variant

Treatment

- Drugs
  - Steroids
    - Limited response rate (~ 33%) and frequent relapse
    - Tip variant often responds to steroids (80%) with complete remission in 60%, similar to minimal change disease (MCD)
  - 2nd-line therapies: Cyclosporine, cyclophosphamide, mycophenolate mofetil, rituximab, plasmapheresis
  - ACE inhibitors to ↓ proteinuria and tubular injury
  - Abatacept (under study): Targets B7-1 (CD80) and led to remission of proteinuria in small series

Prognosis

- Wide range due to diverse patient selection and therapies
- ESRD in 3-5 years according to pathologic classification
  - NOS variant: 20-37%
  - Tip variant: 6-24%
  - Cellular variant: 0-33%
  - Perihilar: 0-37%
  - Collapsing: 18-70%
- Risk factors for ESRD: Heavy proteinuria, elevated Cr, HTN at time of biopsy; failure to respond to therapy; other lesions in tip variant

MICROSCOPIC

Histologic Features

- Glomeruli (NOS variant)
  - Adhesion of glomerular capillaries to BC
    - Randomly distributed (by definition, not at tip or perihilar)
    - Sometimes epithelial cell bridging between BC and GBM

- Accumulation of hyaline at site of adhesion
- Segmental obsolescence of glomerular capillaries
- Zonal cortical distribution (worst at corticomedullary junction)
- By definition, no glomerular collapse with podocyte proliferation (feature of collapsing variant)

- Tubules: Tubular resorption droplets and focal atrophy, associated with sclerotic glomeruli
- Interstitium: Fibrosis, associated with atrophic nephrons
- Vessels: No or variable intimal fibrosis and arteriolar hyalinosis

Other Variants

- Tip variant
  - Adhesion in tip region: Outer 25% of glomerulus next to proximal tubule origin
    - Affected segment may "herniate" into tubular lumen
  - Segmental lesions can contain endocapillary hypercellularity or sclerosis (often intracapillary foam cells)
  - May have adhesions in other sites (except perihilar)
  - Tip lesion can be seen in glomerular diseases other than primary FSGS (e.g., thrombotic microangiopathy, GN)
- Cellular variant
  - Expansile endocapillary hypercellularity occluding lumina
    - Intracapillary endothelial cells and macrophage-type foam cells ± neutrophils and lymphocytes
    - ± apoptosis with pyknotic or karyorrhectic debris
    - ± fibrin within glomerular capillaries
    - No scar; possibly represents early stage
- Perihilar variant
  - Sclerosis restricted to vascular pole in > 50% of glomeruli
  - Rare in primary FSGS (< 10%), common in adaptive (secondary) FSGS
- Collapsing variant
  - ≥ 1 glomerulus with segmental collapse and hypercellularity of visceral epithelium (podocytes)

ANCILLARY TESTS

Immunohistochemistry

- Parietal epithelium on GBM expresses claudin-1 and pax-2 and may express CD44 (migration marker) and Ki-67(+)

Immunofluorescence

- Polyclonal IgM and C3 in scarred segments
- Other stains most often negative or with minimal scattered deposits (IgG, IgA, C1q, fibrin)
- Rarely delicate polyclonal IgG "dusting" over podocytes, mostly in tip variant

Electron Microscopy

- Extensive podocyte FPE, typically > 50% of capillary surface area, assessed in nonsclerosed glomerulus
- Normal GBM without rupture
- No or minor immune deposits
- Loss of podocytes with bridging of parietal epithelium to GBM in areas of adhesion
- Cellular variant: Intracapillary foam cells and segmental capillary occlusion
- Collapsing variant: Subepithelial laminations of new GBM

DIFFERENTIAL DIAGNOSIS

FSGS Secondary to Adaptive Response

- Glomerular hypertrophy
- Perihilar distribution of adhesions and hyaline
- Less extensive FPE (by measure of foot process width)
  - Average foot process width > 1,500 μm distinguishes primary FSGS from secondary FSGS due to adaptive response with ~ 100% sensitivity and ~ 70% specificity

Minimal Change Disease

- Cannot distinguish without presence of segmental glomerulosclerosis
- Sampling issue without corticomedullary junction or small number of glomeruli
- May be expressions of same disease process

FSGS Due to Genetic Causes

- Usually NOS variant; genetic testing required

FSGS Superimposed on Other Glomerular Diseases

- Segmental scars, collapse, and tip lesions may complicate other glomerular diseases
  - Immunofluorescence and electron microscopy needed to detect underlying glomerular disease

DIAGNOSTIC CHECKLIST

Pathologic Interpretation Pearls

- In setting of nephrotic syndrome and MCD, FSGS cannot be ruled out
  - Presence of tubular atrophy even without glomerular scar is suspicious
  - Multiple levels may be necessary to demonstrate segmental lesions
- FSGS NOS is diagnosis of exclusion; other diseases can result in segmental glomerular scars

SELECTED REFERENCES

1. Kienzl-Wagner K et al: Successful management of recurrent focal segmental glomerulosclerosis. Am J Transplant. 18(11):2818-22, 2018
2. Tao J et al: JAK-STAT signaling is activated in the kidney and peripheral blood cells of patients with focal segmental glomerulosclerosis. Kidney Int. 94(4):795-808, 2018
3. Rosenberg AZ et al: Focal segmental glomerulosclerosis. Clin J Am Soc Nephrol. 12(3):502-17, 2017
4. Maas RJ et al: Minimal change disease and idiopathic FSGS: manifestations of the same disease. Nat Rev Nephrol. 12(12):768-76, 2016
5. Fogo AB: Causes and pathogenesis of focal segmental glomerulosclerosis. Nat Rev Nephrol. 11(2):76-87, 2015
6. Hakroush S et al: Extensive podocyte loss triggers a rapid parietal epithelial cell response. J Am Soc Nephrol. 25(5):927-38, 2014
7. Smeets B et al: Detection of activated parietal epithelial cells on the glomerular tuft distinguishes early focal segmental glomerulosclerosis from minimal change disease. Am J Pathol. 184(12):3239-48, 2014
8. D'Agati VD et al: Association of histologic variants in FSGS clinical trial with presenting features and outcomes. Clin J Am Soc Nephrol. 8(3):399-406, 2013
9. Strassheim D et al: IgM contributes to glomerular injury in FSGS. J Am Soc Nephrol. 24(3):393-406, 2013
10. Deegens JK et al: Podocyte foot process effacement as a diagnostic tool in focal segmental glomerulosclerosis. Kidney Int. 74(12):1568-76, 2008
11. Thomas DB et al: Clinical and pathologic characteristics of focal segmental glomerulosclerosis pathologic variants. Kidney Int. 69(5):920-6, 2006
12. D'Agati VD et al: Pathologic classification of focal segmental glomerulosclerosis: a working proposal. Am J Kidney Dis. 43(2):368-82, 2004

Corticomedullary Junction Predisposition

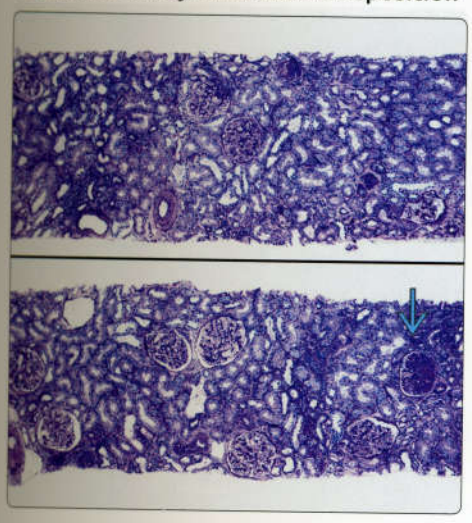

Adhesion

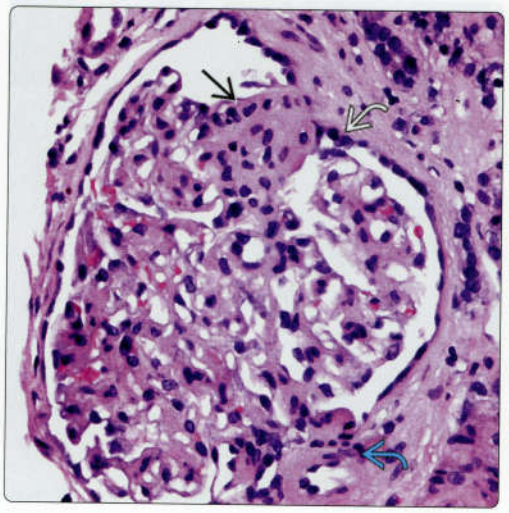

(Left) *Low-power view biopsy of FSGS reveals 1 glomerulus ⇨ with segmental GS in an African American man. These glomeruli are preferentially located at the corticomedullary junction, which should be included to consider the sample adequate.* **(Right)** *Glomerular tuft adhesion ⇨ to the BC is shown. Note BC tenting ➡, a useful feature indicating that the adhesion is not an artifact. Identification of the glomerular base ⇨ helps exclude that structure, which sometimes resembles an adhesion.*

Adhesion to Bowman Capsule

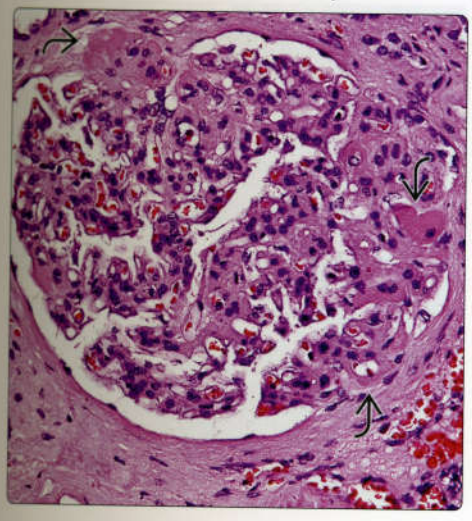

Adhesion in FSGS

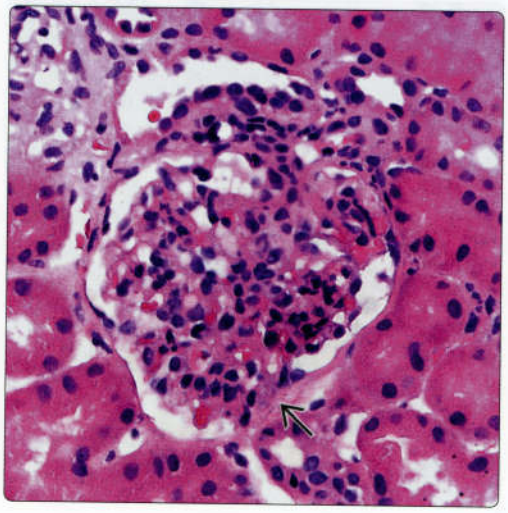

(Left) *This glomerulus has 3 sites of tuft adhesion to the BC with accompanying deposition of hyaline ⇨. The rest of the glomerulus has mild mesangial hypercellularity but is otherwise unremarkable.* **(Right)** *Subtle adhesion ⇨ in a 6 year old with nephrotic syndrome is shown. The tenting of the BC is useful to distinguish real from artifactual adhesions.*

Adhesion With Bridging by Parietal Epithelium

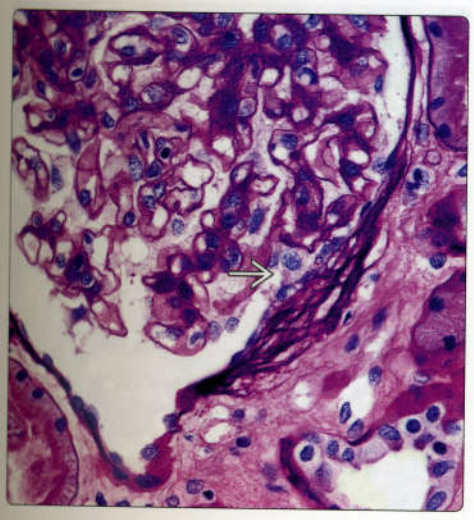

Perihilar Adhesion and Hyaline

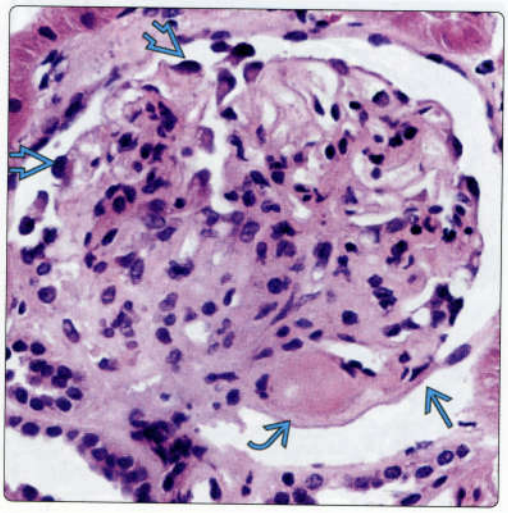

(Left) *An adhesion has a cell ➡ bridging between the laminated BC and the GBM. The presence of a BC reaction helps distinguish a real adhesion from one created as a biopsy artifact with compression of the tuft against the capsule.* **(Right)** *Perihilar adhesion ⇨ and hyaline ⇨ deposition are present in > 50% of glomeruli in the perihilar variant. This pattern is most common in secondary, maladaptive FSGS (nephron overload). Note the reactive podocytes ⇨.*

Segmental IgM Deposit in FSGS

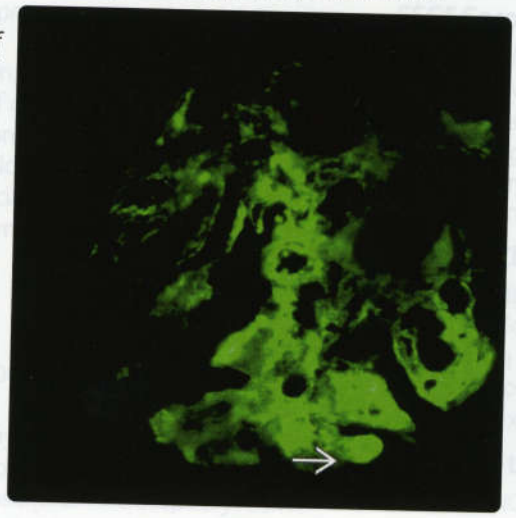

C3 Deposit in FSGS

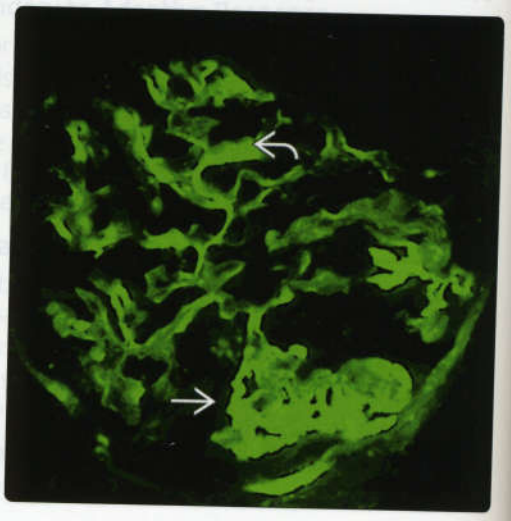

(Left) *Segmental IgM deposits in the sclerotic segments of the involved glomeruli in FSGS are shown. Mesangial IgM is also not uncommon. IgM in scarred areas is thought to be due to nonspecific trapping, although there is no proof of that interpretation.* **(Right)** *C3 deposits in sclerotic segments of glomeruli in FSGS are seen here. C3 is also present in the rest of the glomerulus in the mesangium. Glomeruli with segmental sclerosis, whatever the cause, may have IgM and C3 deposits in the area of scarring.*

Segmental IgM in FSGS

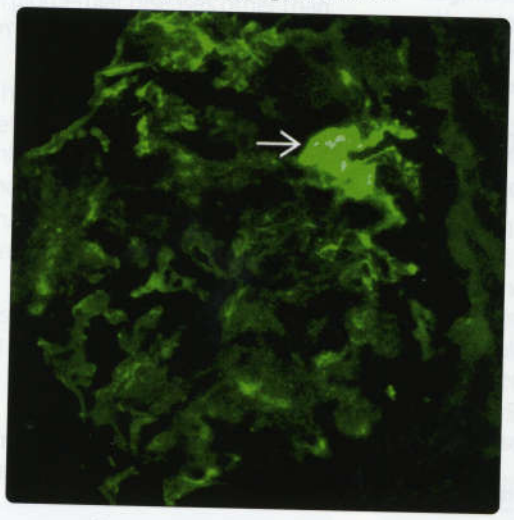

C3 at Capsular Adhesion in FSGS

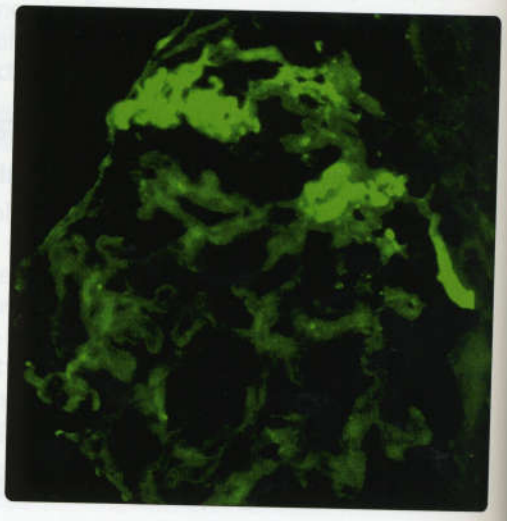

(Left) *Segmental IgM in a case of FSGS is shown. Typical of FSGS, this case also had C3 but no IgG or IgA staining.* **(Right)** *C3 is present in a capsular adhesion. Whether this has a role in the pathogenesis is unknown, but it is almost invariably present along with IgM.*

FSGS Superimposed on Membranous Glomerulonephritis

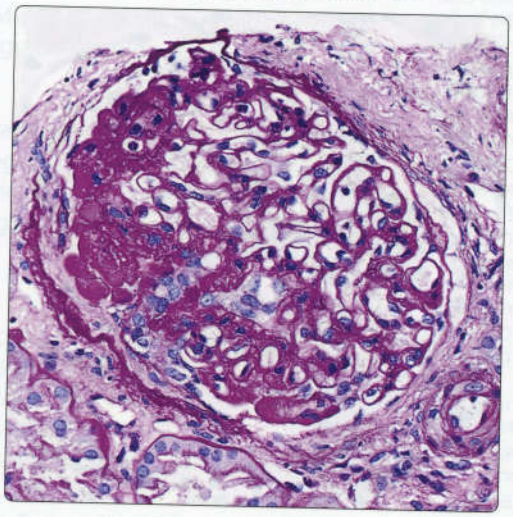

Broken GBM in Segmental Scar in IgA Nephropathy

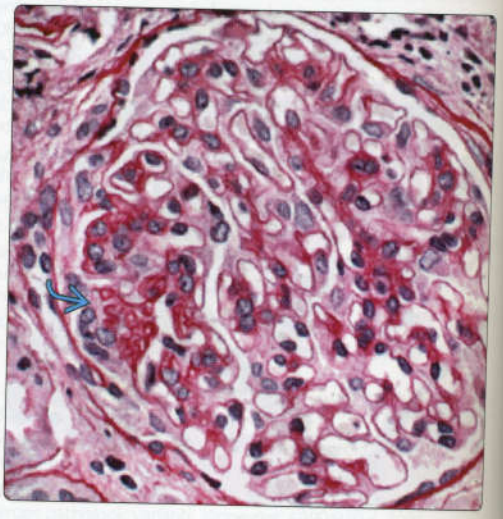

(Left) *FSGS can be superimposed on almost any glomerular disease, including membranous glomerulonephritis (shown) as well as IgA, diabetic glomerulopathy, and Alport syndrome. The presence of FSGS lesions can be an adverse prognostic feature, as in IgA nephropathy.* **(Right)** *Segmental scars can be the result of focal glomerular inflammation, as in this case of IgA nephropathy. One clue that the scar is due to inflammatory injury rather than podocyte loss is a fragmented GBM.*

Foot Process Effacement

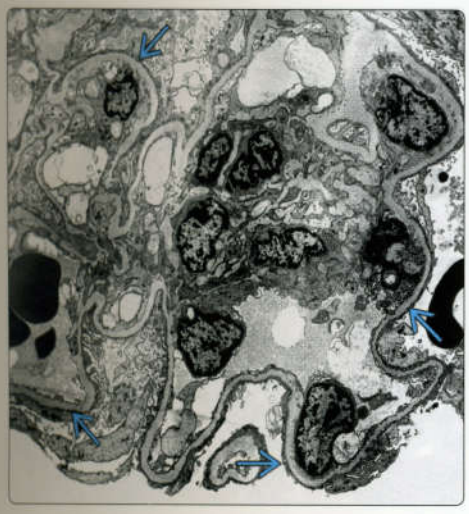

GBM Wrinkling and Foot Process Effacement

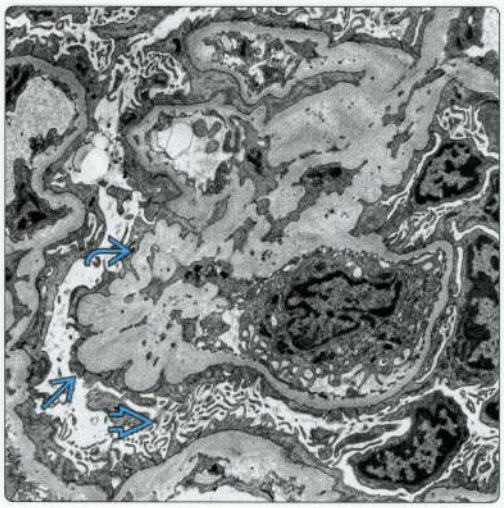

(Left) *Electron microscopy (EM) at low power in FSGS reveals extensive foot process effacement and a normal GBM in a 25 year old with nephrotic-range proteinuria and FSGS seen in the light microscopic portion of the biopsy.* **(Right)** *In FSGS, there is often extensive foot process effacement, which may be accompanied by podocyte microvillous transformation and GBM wrinkling.*

Podocyte Hypertrophy

Foot Process Effacement and Adhesion

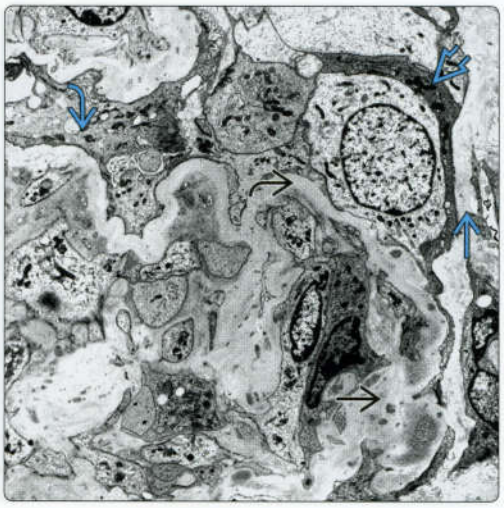

(Left) *In this 22-year-old African American patient with 1.8 g/d proteinuria and FSGS, patchy foot process effacement affects ~ 20% of glomerular capillaries. A podocyte is stretched and is in close contact with parietal epithelium but not the BC.* **(Right)** *Segmental GS with adhesion to the BC in a 25-year-old African American patient with nephrotic syndrome is shown. A cell bridges the GBM and BC. Podocyte foot process effacement is widespread.*

Segmental Scar and Podocyte Loss

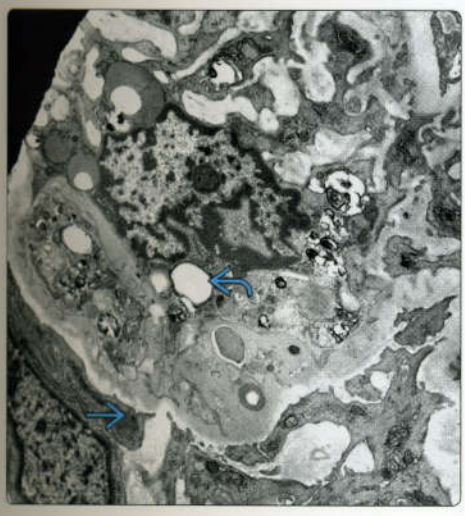

Cellular Bridging of Bowman Capsule in FSGS

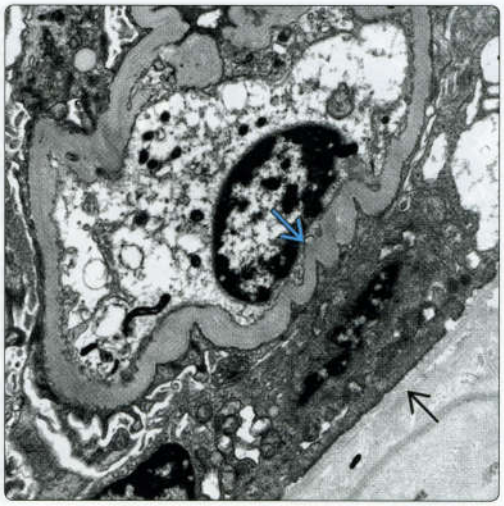

(Left) *Segmental scar shows lipid in mesangial cells and loss of the podocytes, leaving behind denuded GBM.* **(Right)** *A single cell bridges the BC and the GBM, probably the earliest phase of an adhesion in FSGS. Based on experimental evidence, it is likely a parietal epithelial cell that has attached to a bare GBM lacking podocyte coverage.*

(Left) *In this case of FSGS (tip variant), there is herniation of the glomerular tuft into the proximal tubule where it exits the Bowman space.* **(Right)** *In this case of FSGS (tip variant), a glomerular capillary contains foam cells and is adherent to the BC at the inlet of the proximal tubule. Enlarged, reactive podocytes are also at the site.*

Tip Variant

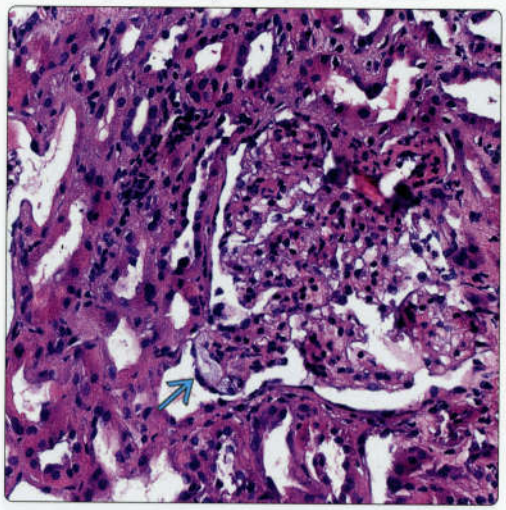

Tip Variant With Adhesion

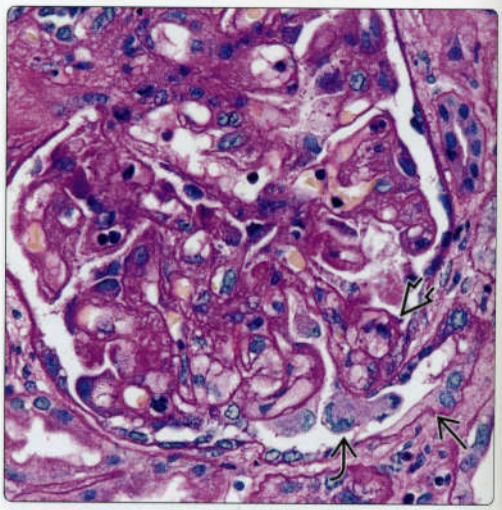

(Left) *Even though the proximal tubule is not seen in this section, the characteristic intracapillary foam cells are seen in the tip quadrant opposite the glomerular hilum at the bottom.* **(Right)** *In this tip variant, the glomerular capillary loops are adherent to the BC. Hypertrophic podocytes are "herniating" through the site at which the tubular pole exits, and adjacent foam cells are in capillaries.*

Tip Lesion With Foam Cells

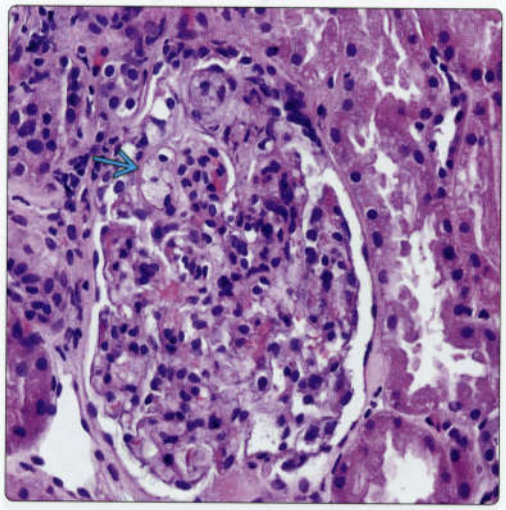

Podocyte Hypertrophy and Endocapillary Foam Cells

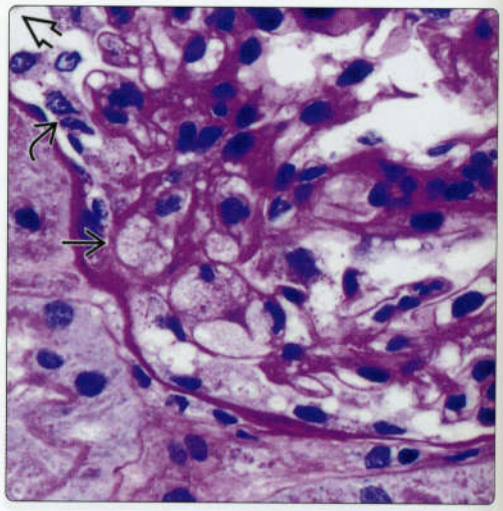

(Left) *In this case of FSGS (tip variant), EM shows wrinkled GBMs and endocapillary hypercellularity at the portion adjacent to the tubular pole.* **(Right)** *In this case of FSGS (tip variant), there is widespread podocyte foot process effacement by EM.*

GBM Wrinkling in Tip Variant

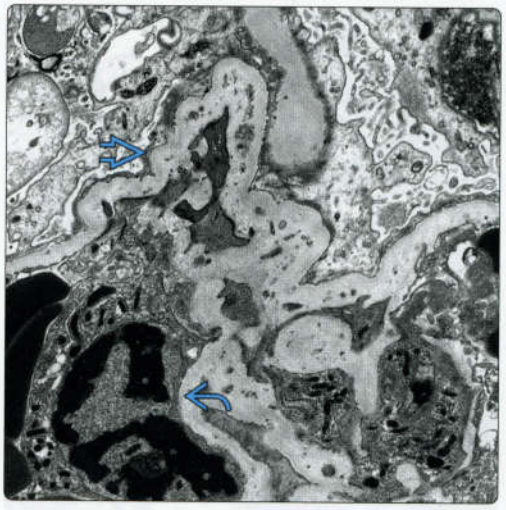

Foot Process Effacement in Tip Variant

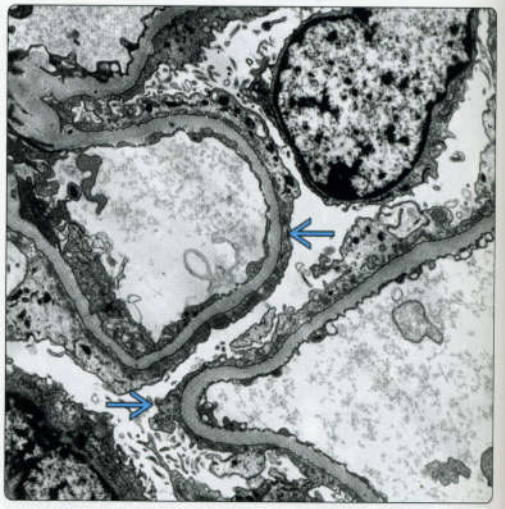

Cellular Variant With Mononuclear Cells Filling Capillaries

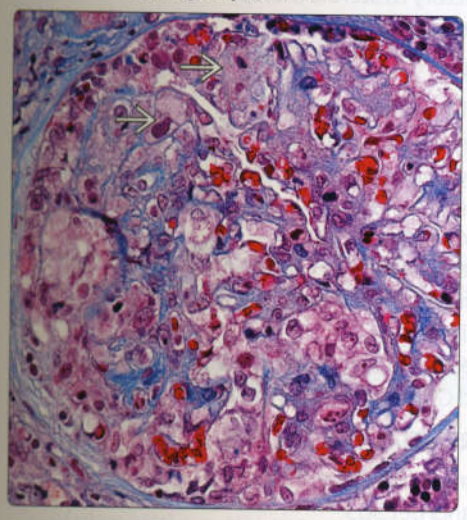

Cellular Variant With Intracapillary Cells

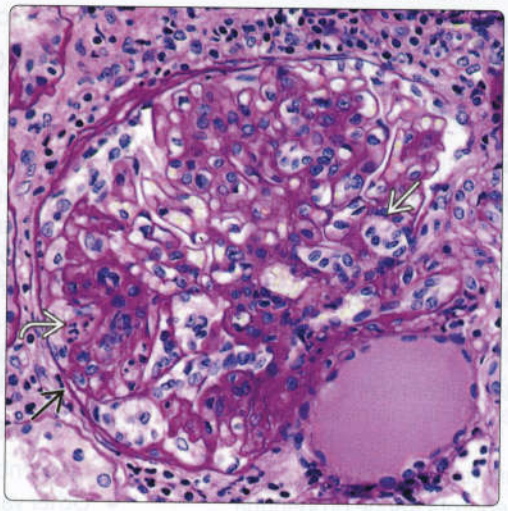

(Left) *Trichrome stain of a biopsy with the cellular variant of FSGS shows most glomerular capillaries filled with mononuclear cells with abundant, sometimes foamy cytoplasm* ➡. **(Right)** *In this case of FSGS (cellular variant), the glomerulus shows intracapillary cells* ➡ *and adhesions to the BC* ➡. *Karyorrhexis is also present* ➡, *which may indicate podocyte death.*

Segmental IgM in Cellular Variant

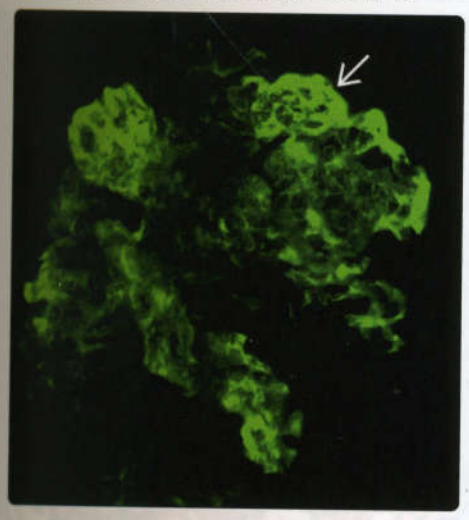

Segmental C3 in Cellular Variant

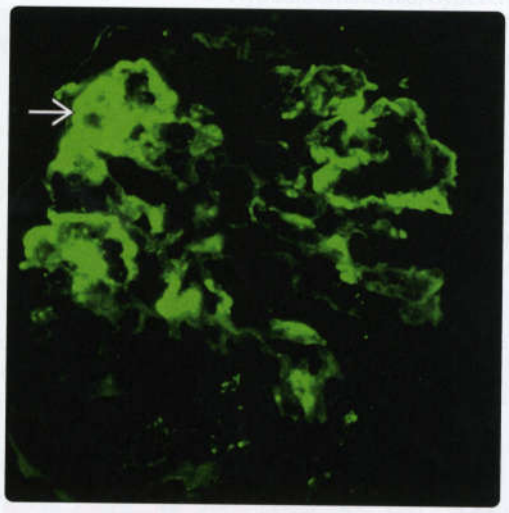

(Left) *IgM by immunofluorescence shows segmental positivity* ➡ *in the cellular variant of FSGS.* **(Right)** *In this case of FSGS (cellular variant), there is segmental deposition of C3* ➡ *by immunofluorescence.*

Cellular Variant With Intracapillary Cells

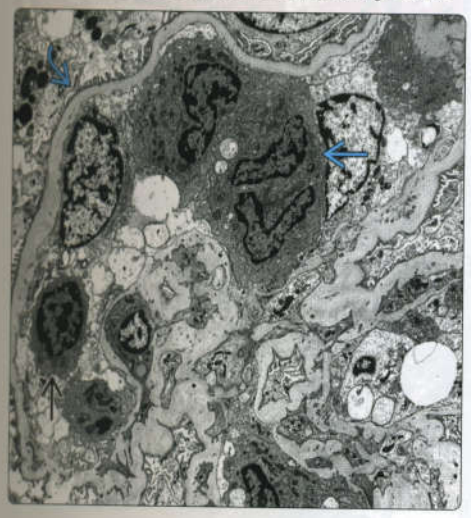

Podocyte Foot Process Effacement in Cellular Variant of FSGS

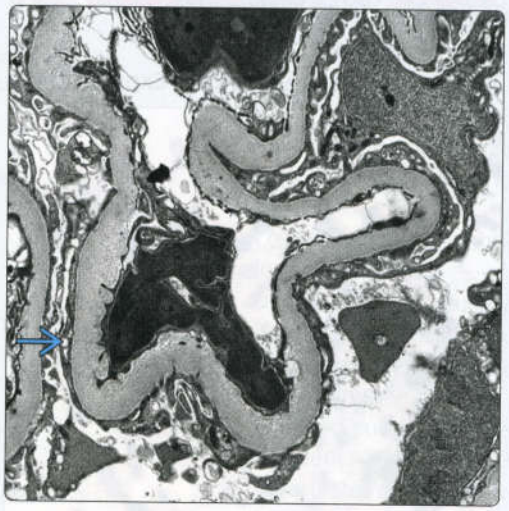

(Left) *The cellular variant of FSGS is defined by intracapillary cells, here shown to be monocytes* ➡ *and lymphocytes* ➡. *Foam cells, either macrophages or endothelial cells, can also be conspicuous. Foot process effacement is present but patchy* ➡. **(Right)** *In the cellular variant of FSGS, there is podocyte foot process effacement* ➡ *&/or blunting around many of the glomerular capillary loops.*

Collapsing Glomerulopathy

KEY FACTS

TERMINOLOGY

- Glomerular diseases defined by prominent capillary loop collapse, parietal epithelial cell activation, glomerular visceral epithelial cell hypercellularity, and proliferation, in absence of glomerular inflammation

ETIOLOGY/PATHOGENESIS

- Podocyte loss and replacement with parietal epithelial cells
- Causes
  - Idiopathic believed to be due to circulating factor
  - Infection: HIV, parvovirus B19, and many others
  - Drugs: Interferons, bisphosphonates, calcineurin inhibitors
  - *APOL1* risk alleles in individuals of recent African descent

CLINICAL ISSUES

- Black patients disproportionately affected
- Nephrotic syndrome and nephrotic-range proteinuria
- Renal dysfunction
- Often refractory to steroid therapy
- Rapid progression to renal failure

MICROSCOPIC

- At least 1 glomerulus with
  - Global or segmental collapse
  - Overlying epithelial cell hyperplasia and hypertrophy
- Tubulointerstitial fibrosis, tubular microcysts, and interstitial inflammation can be present
- Ki-67(+) visceral epithelial cells (proliferation)
- Immunofluorescence: Segmental IgM and C3
- Electron microscopy
  - Foot process effacement and separation from GBM
  - Wrinkled GBM with capillary loop collapse

TOP DIFFERENTIAL DIAGNOSES

- Crescents in glomerulonephritis
- Other variants of FSGS
- Superimposed on underlying glomerular disease

(Left) *Epithelial cell proliferation in acute collapsing glomerulopathy (CG) can resemble a cellular crescent. However, the cells are more rounded than the more spindle-shaped parietal epithelial cells typically seen in a crescent and are not associated with glomerular inflammation or necrosis.* **(Right)** *In later stages of CG, glomerular capillary loops are not well defined, and a palisading rim of crowded epithelial cells is present. These cells are often quiescent.*

Pseudocrescent in CG

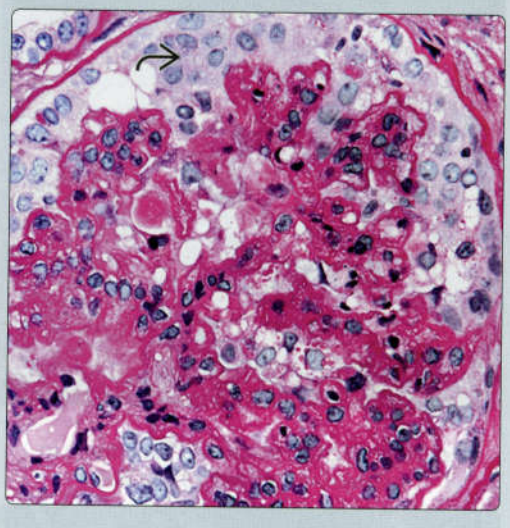

Palisading Epithelial Hypercellularity

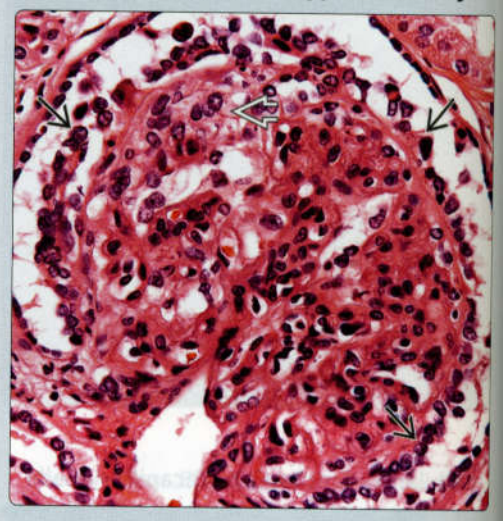

(Left) *Proliferating epithelial cell are highlighted by Ki-67 immunohistochemistry in this case of CG.* **(Right)** *EM shows prominent glomerular basement membrane (GBM) wrinkling with collapse of glomerular capillary lumina.*

Proliferating Epithelial Cells Express Ki-67

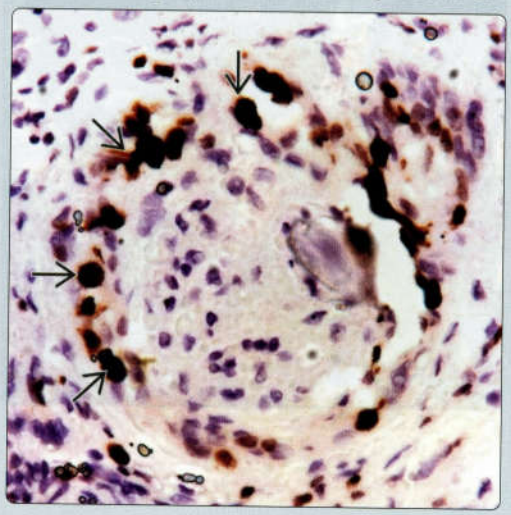

Glomerular Capillary Loop Collapse

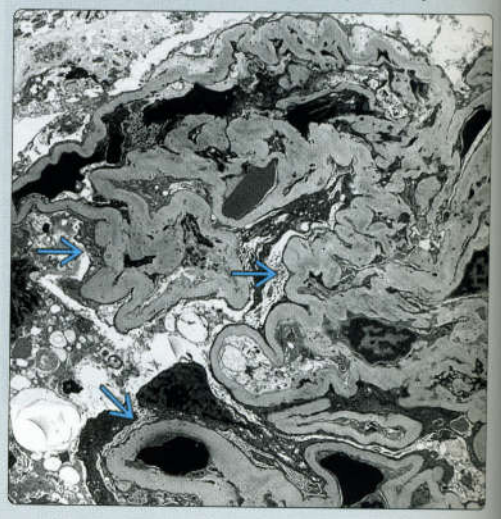

TERMINOLOGY

Abbreviations

- Collapsing glomerulopathy (CG)

Synonyms

- FSGS, collapsing variant
- Idiopathic collapsing FSGS

Definitions

- Podocytopathy defined by prominent capillary loop collapse, glomerular epithelial cell hypercellularity and proliferation

ETIOLOGY/PATHOGENESIS

Diverse Etiologies

- Primary (idiopathic)
- Secondary (many causes)
  - Infection (viral, e.g., HIV, parvovirus, CMV), drugs, vascular disease, malignancy, genetic disorders
  - Superimposed on other glomerular diseases (e.g., systemic lupus erythematosus, diabetes)
  - In renal transplants related to presence of *APOL1* risk alleles in donor (de novo CG)
  - ↑ interferon states thought to be causative

Common Features

- Extensive podocyte loss and subsequent repopulation by migrating/proliferating parietal epithelial cells
  - Proliferating or palisading epithelial cells on tuft characteristically lack expression of podocyte markers (e.g., synaptopodin, WT1) and express markers of proliferation (Ki-67), cell migration (CD44), and parietal epithelium (pax-2, cytokeratin 8/18 and 19, claudin-1)
    - Originally attributed to dedifferentiation or dysregulation of podocytes
    - Parietal epithelial cell activation and proliferation ("pseudocrescents") in acute phase followed by palisading quiescent epithelial cells lining collapsed and sometimes sclerotic tuft segment in late phase
  - Cellular bridging between Bowman capsule and tuft can be seen
  - CG differs from other types of FSGS in its greater degree of podocyte loss and proliferation and repopulation with parietal epithelial cells
  - Shed podocytes detectable in urine
- Proximal tubular cells often also affected and show increased cell turnover

Specific Mechanisms in Idiopathic (Primary) Collapsing Glomerulopathy

- Subset appear to represent progression of minimal change disease with possible autoimmune etiology, although genetic or other contributing factor (besides *APOL1* risk alleles) likely

Genetic Factors

- 2 *APOL1* risk alleles in patients of recent African descent
  - Affects risk of CG due to drugs and other glomerular diseases
  - *APOL1* risk alleles may promote interferon-induced podocyte injury
- Mitochondrial genes
  - Coenzyme Q2

CLINICAL ISSUES

Epidemiology

- Incidence
  - ~ 10% of FSGS in adult renal biopsies in USA
    - Rare in children < 10 years old except for genetic forms
- Ethnicity
  - Geographic/racial differences probably due to *APOL1* risk alleles
    - Black patients are disproportionately affected (20-50x rate of nonblack patients)
    - More common in FSGS series in Brazil (37%) than Korea (1%) or India (2%)

Presentation

- Nephrotic syndrome or nephrotic-range proteinuria, often in absence of edema
  - Hypoalbuminemia, hypercholesterolemia
- Renal dysfunction
  - Elevated serum Cr at presentation; > than other types of FSGS

Treatment

- Drugs
  - Typically refractory to steroids
  - Treatment of underlying condition, such as infection or tumor, can lead to remission

Prognosis

- Poor prognosis of idiopathic CG in all series
  - 47% progress to ESRD in 3 years
  - 50% ESRD in 6 months
  - More rapid progression than other types of FSGS
    - "Malignant" FSGS
- Improvement can occur in cases with recovery from or removal of etiologic agent

MICROSCOPIC

Histologic Features

- Glomeruli
  - At least 1 glomerulus with global or segmental glomerular collapse and overlying epithelial hyperplasia and hypertrophy, according to Columbia working proposal
    - Lowest possible threshold has led to marked increase in diagnosis of CG
      - Overlap with cellular variant of FSGS possible
  - Visceral epithelial cells with hypertrophy and hyperplasia
    - Urinary space may be filled with podocytes, forming pseudocrescents
    - Enlarged nuclei with open, vesicular chromatin and frequent nucleoli in acute phase
    - Binucleate forms may be seen
    - Mitotic figures and apoptosis occasionally sampled in pseudocrescents
    - Abundant and prominent protein reabsorption droplets

- GBMs wrinkled or thickened in areas of collapse
  - PAS and Jones methenamine silver stains useful in highlighting basement membrane collapse
- Mesangial and intracapillary matrix not appreciably increased, except in cases superimposed upon diabetes
- Tubules
  - Tubular microcysts in ~ 40% of cases
    - Proximal tubules dilated with proteinaceous casts, sometimes with "peripheral scalloping"
    - Enlarged hyperchromatic nuclei, mitotic figures, nucleoli, and focal apoptosis
  - Tubular atrophy/injury
    - Tubular epithelial simplification and flattening
  - Tubulitis can be present, often with neutrophils
- Interstitium
  - Inflammation
    - Interstitial mononuclear inflammation can be prominent
  - Edema
- Arteries/arterioles
  - Renal vessels may have changes of thrombotic microangiopathy (TMA) if etiology involves TMA

ANCILLARY TESTS

Immunofluorescence

- IgM and C3 with segmental or global deposits in collapsed segments, less common with deposits of C1q
- IgG, IgA, and albumin in visceral epithelial protein resorption droplets
- Tubules have epithelial protein resorption droplets containing plasma proteins (IgG, IgA, C3, albumin, and others)

Electron Microscopy

- Podocyte hypertrophy overlying areas of collapse
  - Foot processes are extensively effaced
  - Contain electron-dense protein resorption droplets, electron-lucent transport vesicles, and increased numbers of organelles, including prominent rough endoplasmic reticulum
  - Podocytes detached from GBM with interposition of newly formed extracellular matrix
  - Multiple layers of newly formed GBM between podocyte and original GBM
  - Actin cytoskeleton disrupted, making cytoplasm appear open and pale
  - Podocytes become cuboidal
- GBM
  - Wrinkled GBM in areas of collapse
  - GBM not appreciably thickened
  - Absent electron-dense deposits except for small, rare paramesangial deposits
- Glomerular endothelium
  - Tubuloreticular inclusions can be present in cases with high interferon-states, including HIV nephropathy, and in lupus-associated forms

Immunohistochemistry

- Ki-67 (MIB-1), proliferation marker, is positive in activated parietal and visceral epithelial cells
  - Podocytes rarely express Ki-67 (< 1/glomerulus)
  - Proximal tubular cells also have increased Ki-67 staining
- Loss of normal podocyte markers on glomerular tuft
  - WT1, synaptopodin, podocin, podocalyxin, GLEPP1, α-actinin, CD35, and CD10
- Gain of markers of parietal epithelial cells
  - Pax-2, claudin-1, CK8/18, CD44 (migration marker)
- Epithelial phenotype alterations do occur in other forms of FSGS with podocyte loss but to much lesser degree

DIFFERENTIAL DIAGNOSIS

FSGS, Not Otherwise Specified

- Podocyte proliferation and hypercellularity minimal
- More hyalinosis, sclerosis, and capsular adhesions
- One collapsing lesion forces classification to CG in Columbia classification

FSGS, Cellular Variant

- Endocapillary hypercellularity distinguishes cellular variant
- May be in CG spectrum because of overlapping features
- Cellular variant also has ↑ Ki-67 and cytokeratin expression in visceral epithelial cells and ↓ WT1, CD10, α-actinin

Glomerulonephritis With Crescents

- True crescents usually contain fibrin and spindle-shaped cells that lack reabsorption droplets
- Periglomerular inflammation, necrotizing lesions in capillary tuft and GBM breaks absent in CG

Superimposed on Other Glomerular Diseases

- Diagnostic features of underlying glomerular disease also present (e.g., IgA nephropathy, lupus nephritis, diabetes)
- Typically marked proteinuria and rapid progression to ESRD
- Associated with *APOL1* risk variants

Superimposed on Arterial Disease

- Characteristic vascular lesions: TMA, severe arteriolar hyalinosis, or atheroembolism

Collapsing Glomerulopathy Due to HIV-Associated Nephropathy

- Prominent tubuloreticular structures in endothelial cells
- ± mitochondrial abnormalities due to antiretroviral therapy

SELECTED REFERENCES

1. Kukull B et al: Collapsing glomerulopathy in older adults. Mod Pathol. ePub, 2018
2. Santoriello D et al: Donor APOL1 high-risk genotypes are associated with increased risk and inferior prognosis of de novo collapsing glomerulopathy in renal allografts. Kidney Int. 94(6):1189-1198, 2018
3. Nicholas Cossey L et al: Collapsing glomerulopathy: a 30-year perspective and single, large center experience. Clin Kidney J. 10(4):443-449, 2017
4. Hakroush S et al: Extensive podocyte loss triggers a rapid parietal epithelial cell response. J Am Soc Nephrol. 25(5):927-38, 2014
5. Larsen CP et al: Apolipoprotein L1 risk variants associate with systemic lupus erythematosus-associated collapsing glomerulopathy. J Am Soc Nephrol. 24(5):722-5, 2013
6. Testagrossa L et al: Immunohistochemical expression of podocyte markers in the variants of focal segmental glomerulosclerosis. Nephrol Dial Transplant. 28(1):91-8, 2013

Pathogenetic Classification of Collapsing Glomerulopathy

Category/Cause	APOL1 Risk Alleles*	Comments
Idiopathic		
Putative circulating factor		Most common form of CG, recurs in renal allografts
Infection		
HIV	+	Common form of HIV glomerular disease in persons of recent African descent; TRI prominent
CMV	+	Improved with steroids and ganciclovir; can persist after CMV resolved
Parvovirus B19	+	Post kidney transplant; in situ demonstration of virus in parietal epithelial cells
Tuberculosis		Recovery reported
Leishmaniasis		Visceral form; recovery reported
Malaria		*Plasmodium falciparum* or *vivax* with hemolytic uremic syndrome; recovery reported
Filariasis		Microfilariae in vessels
Schistosomiasis		Persists after therapy
Drugs		
Calcineurin inhibitors		Probably related to vascular disease (TMA, hyalinosis); poor prognosis
IV drug abuse (e.g., heroin)		Often associated with HIV
Bisphosphonates		High-dose pamidronate, especially IV; recovery reported
Interferons (IFN-α, -β, -γ)	+	IFN-α for HCV; IFN-β for multiple sclerosis; IFN-γ for pulmonary fibrosis; TRI prominent
Griseofulvin		Recovered on drug withdrawal
Vascular		
Atheroembolism		
Thrombotic microangiopathy		Transplant, also in hemolytic uremic syndrome
Periinfarct		Shows that acute glomerular ischemia can lead to CG pattern of injury
Autoimmune Disease		
Still disease		Remission reported with steroids
Behçet syndrome		Remission on cyclosporine
Malignancy		
Leukemia/lymphoma		Multiple myeloma, hemophagocytic syndrome; remission after chemotherapy reported
Superimposed on Other Glomerular Diseases		
SLE	+	With class IV; partial remission reported with steroids, cyclophosphamide
Diabetes	+	Associated with severe hyalinosis; 75% ESRD in 7 months
C1q nephropathy	+	
IgA nephropathy		Poor prognosis; 90% ESRD
Post transplant de novo CG	+	Poor prognosis; relevant *APOL1* risk alleles in donor
Genetic		
Apolipoprotein L1 *(APOL1)*	+	Individuals of recent African descent, *APOL1* expressed in podocytes, increased by interferons
Sickle cell disease (*HBB*)		Sickled cells in capillaries
CoQ10 deficiency *(COQ2, COQ6)*		Dysmorphic mitochondria in podocytes; onset < 2 years (*COQ2*) or 29 years (*COQ6*)
Familial collapsing FSGS (*SCARB2*)		Lysosomal protein; myoclonic epilepsy and renal failure
Familial collapsing FSGS (*TRPC6*)		Early onset CG in infants (6 months)
CD2AP deficiency (*CD2AP*)		3% of sporadic FSGS
Autosomal dominant FSGS (*INF2*)		Charcot-Marie-Tooth (12%)
Other genetic diseases		Schimke immunoosseous dysplasia (*SMARCAL1*), Mandibuloacral dysplasia (*ZMPSTE24*), Galloway-Mowat syndrome (*WDR73*)

*Rare case reports: Campylobacter, Epstein-Barr virus, HTLV-1, hepatitis C virus, post partum TMA, mixed connective tissue disorder, AL amyloidosis, Guillain-Barré syndrome, giant cell arteritis, anabolic steroids, valproic acid, and sirolimus. Abbreviations: IFN = interferon; SLE = systemic lupus erythematosus; TMA = thrombotic microangiopathy; TRI = tubuloreticular inclusions. *APOL1 not tested in most categories.*

(Left) *Minimal collapsing lesions are seen in 2 segments of this glomerulus, one with features of hypertrophy ⇨ and one with adhesion or bridging of epithelial cells to Bowman capsule ⇨. A segmental sclerosing lesion with tuft adhesion to Bowman capsule is also present ⇨.* **(Right)** *Jones methenamine silver (JMS) stain illustrates areas of glomerular capillary loop collapse ⇨. The epithelium filling in the Bowman space often resembles a crescent ⇨ ("pseudocrescent formation").*

Features of Segmental Collapsing Lesions

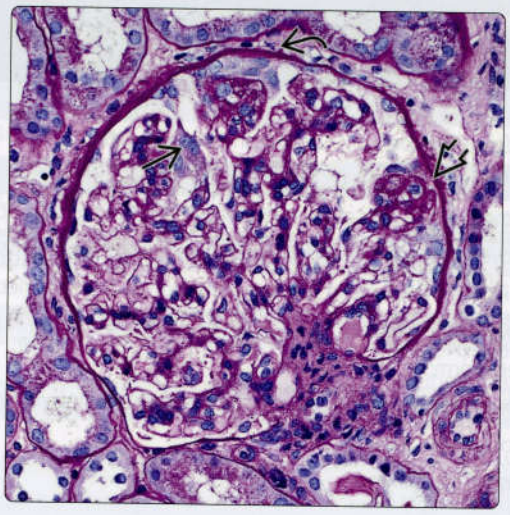

Pseudocrescent Formation in CG

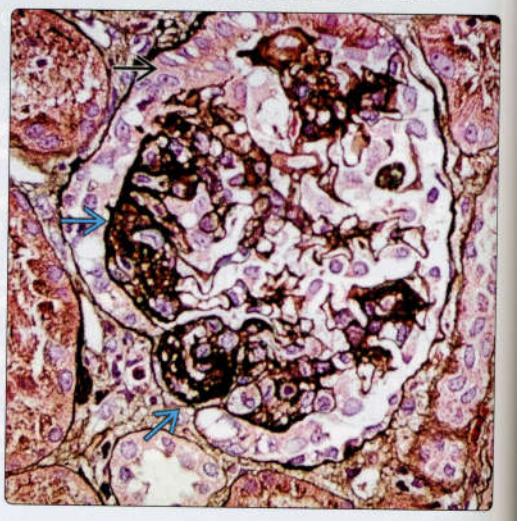

(Left) *Podocyte apoptosis ⇨ in a 29-year-old woman with new onset of nephrotic syndrome over 1 month due to idiopathic CG provides evidence of acute podocyte injury and loss in the pathogenesis of CG. (Courtesy I. Rosales, MD.)* **(Right)** *A glomerulus has undergone global collapse with overlying palisading epithelial cells ⇨ and marked dilatation of Bowman space ⇨.*

Podocyte Apoptosis in Early CG

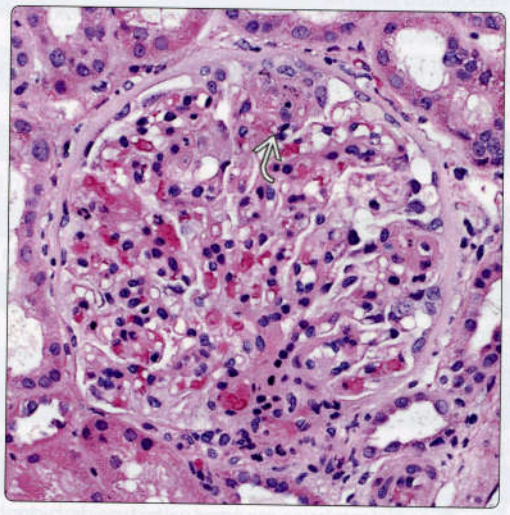

Bowman Space Dilatation and Global Glomerular Collapse

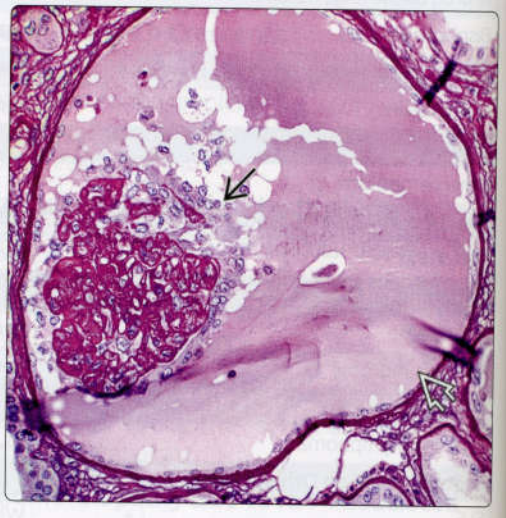

(Left) *This glomerulus with glomerular capillary loop collapse has prominent adhesions to the Bowman capsule ⇨ and no residual open capillary lumina. This likely represents a late stage preceding global sclerosis.* **(Right)** *A globally sclerotic glomerulus in a case of CG shows collapse and occlusion of glomerular capillary loops ⇨, illustrating the collapsing process that leads to global sclerosis. The lesion can be confused with a fibrous crescent.*

Adhesion to Bowman Capsule

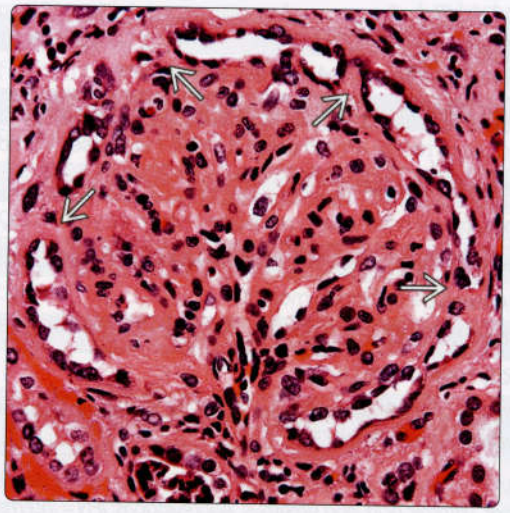

Global Glomerulosclerosis

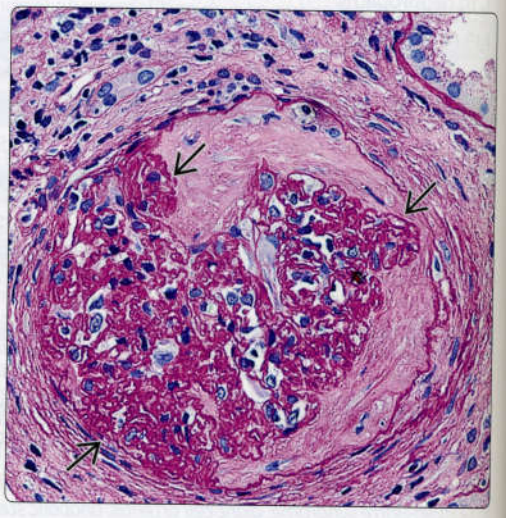

Bridging Epithelial Cells From Tuft to Capsule

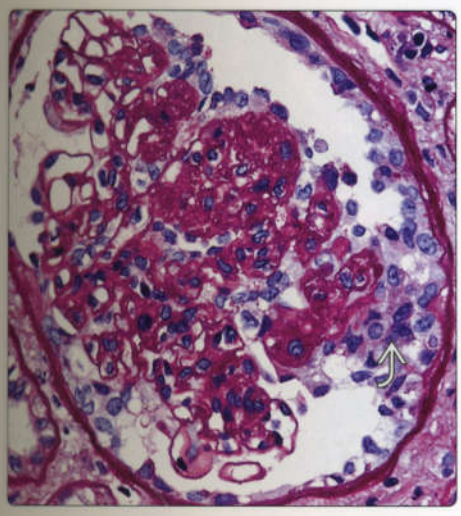

Mitosis

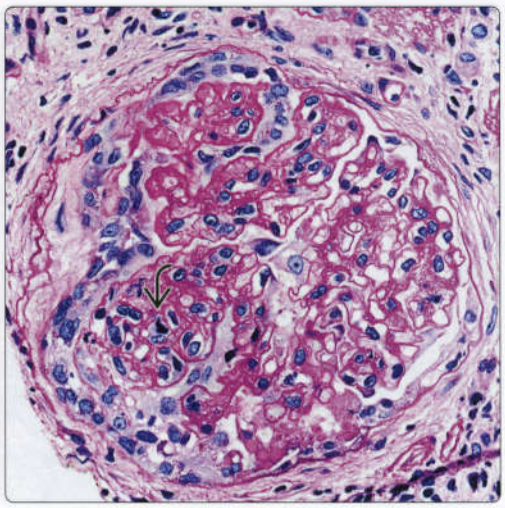

(Left) *CG with a pseudocrescentic tuft adhesion is shown. This glomerulus has prominent reactive epithelial cells bridging glomerular tuft and Bowman capsule.* **(Right)** *CG is present in a 74-year-old white man with nephrotic syndrome. Severe vascular disease was present and may have contributed. An unidentified cell is in mitosis.*

Segmental IgM

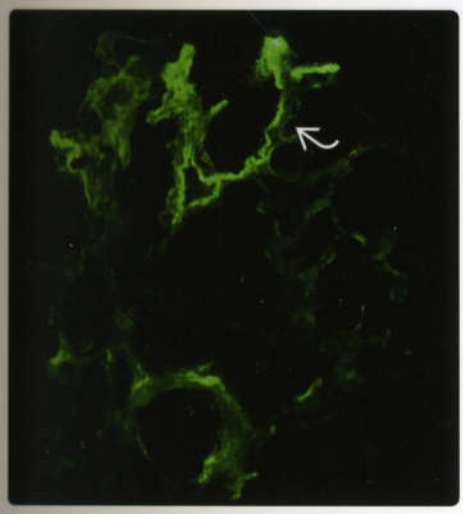

Segmental C3

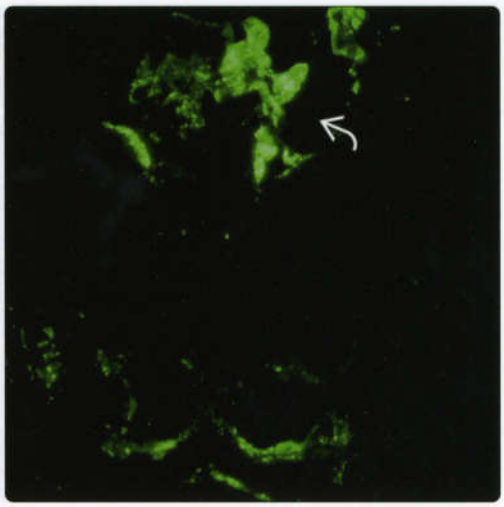

(Left) *Segmental IgM is commonly present in all forms of FSGS, including CG, as illustrated here. While this is generally regarded as "nonspecific" trapping, there is some recent experimental evidence that IgM is necessary for the development of FSGS.* **(Right)** *Segmental C3 is commonly present in all variants of FSGS, including the collapsing variant. Other immunoreactants are generally absent or minimally detected.*

Reabsorption Droplets in Visceral Epithelial Cells

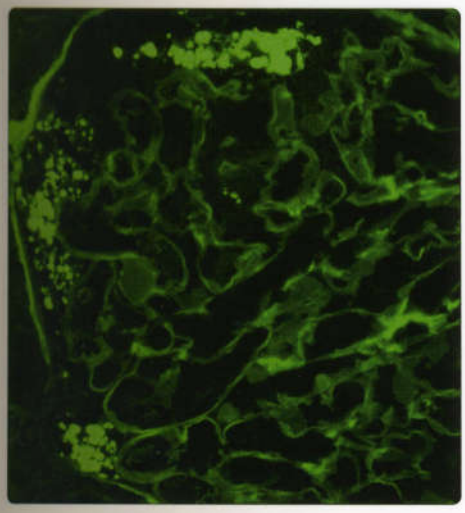

Large Reabsorption Droplets in Visceral Epithelium

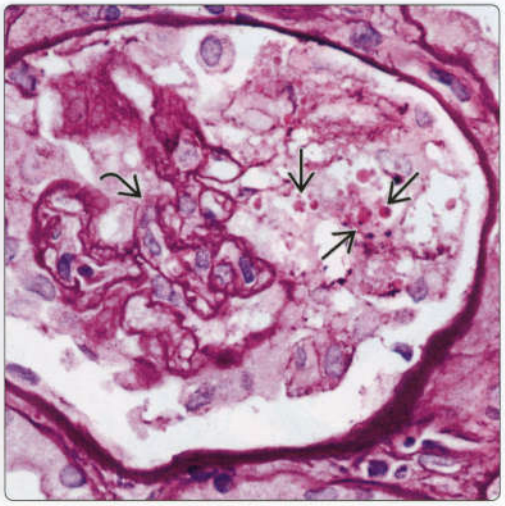

(Left) *Prominent large protein reabsorption droplets reactive for albumin are commonly present in CG. Immunoglobulin and complement components can also be present in these droplets and should not be mistaken for immune complexes.* **(Right)** *This collapsed glomerulus has prominent epithelial proliferation with protein reabsorption droplets.*

(Left) *Wrinkled GBM leads to collapse of glomerular capillary loops. Overlying epithelial cells are segmentally separated from the original GBM with multiple layers of newly formed GBM. Swollen reactive endothelial cells are also present.* **(Right)** *Podocytes are separated from the original GBM by multiple layers of newly formed matrix, indicating past podocyte injury and repair. The segmental process was first described in FSGS associated with heroin addiction.*

Subepithelial Neo-GBM

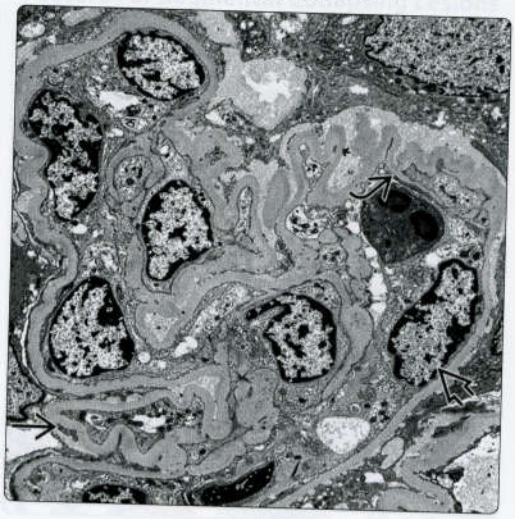

Newly Formed GBM Matrix

(Left) *Capillary loops are occluded in this CG, and visceral epithelial cells show absence of foot processes. Endocapillary cells are swollen and reactive; however, this case did not have enough endocapillary cellularity to suggest the "cellular lesion."* **(Right)** *Prominent laminations on the outer aspect of the collapsed GBM are evident in this case of CG. Intracapillary foam cells were present, a feature more commonly associated with the cellular variant of FSGS.*

Occluded Capillary Loops

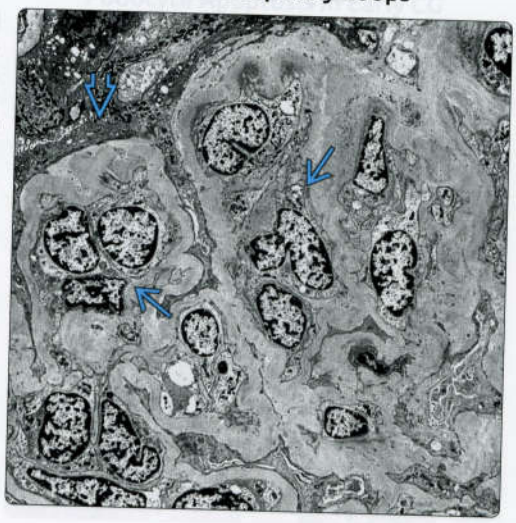

Intracapillary Foam Cells

(Left) *This biopsy was taken from a 7-year-old boy with recurrent CG 2 days post transplant and shows widespread effacement of foot processes but no collapse, resembling minimal change disease. APOL1 status of the donor is unknown.* **(Right)** *In a nephrectomy performed for intractable protein loss in a 9-year-old boy with recurrent CG 2 years after transplant, collapse of glomerular capillaries and prominent podocyte hypertrophy are shown with villous transformation. Recurrence began 2 days after transplant.*

Foot Process Effacement

Recurrent CG With Glomerular Capillary Loop Collapse

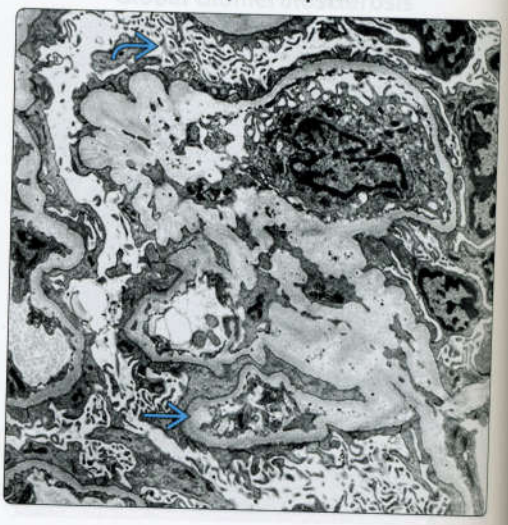

Tubular Dilatation

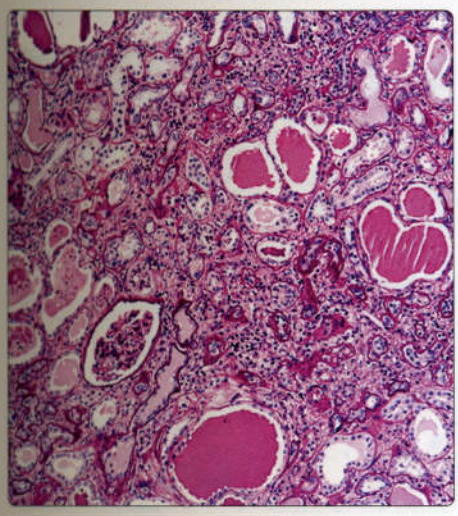

Ectatic Tubules With PAS(+) Casts

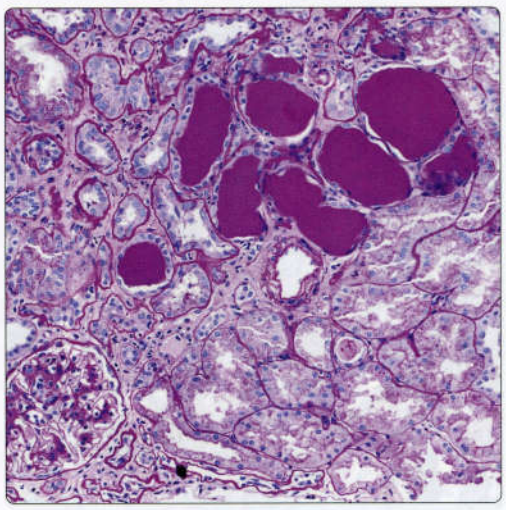

(Left) *CG can be accompanied by tubulointerstitial disease, here shown at low power. Microcystic dilation of proximal tubules filled with PAS(+) protein is evident as well as tubular atrophy and interstitial inflammation.* **(Right)** *Markedly dilated tubules distended with PAS(+) material are characteristic of CG of all causes. Tubular epithelial cells proliferate as well as glomerular epithelial cells.*

Interstitial Inflammation

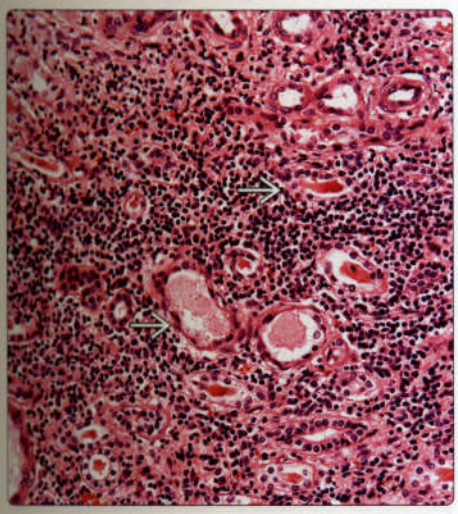

Interstitial Inflammation

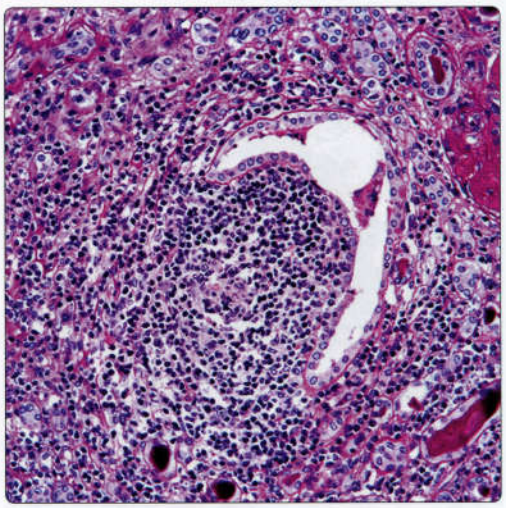

(Left) *There is prominent interstitial inflammation amidst these atrophic tubules, many of which have proteinaceous casts* ➡. **(Right)** *Lymphoid interstitial infiltrates are often prominent in CG and sometimes form lymphoepithelial structures with tubules, as shown here. The presence of tubulointerstitial disease indicates that CG is not exclusively a "podocytopathy."*

Sloughed Cells in Tubules

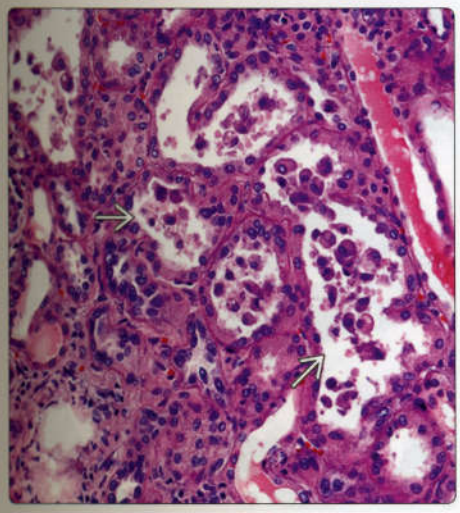

Lipid Accumulation

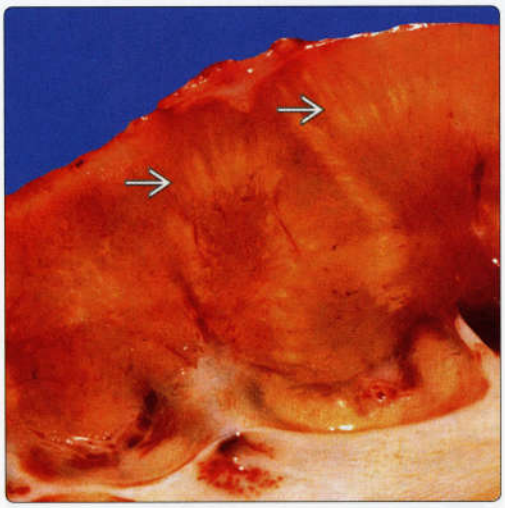

(Left) *The reactive tubular cells in CG are shed in the tubule, as shown here* ➡. *The sloughed cells may also include podocytes, which have been detected in the urine.* **(Right)** *This nephrectomy specimen from a 7-year-old boy with idiopathic CG was done in preparation for renal transplantation. Yellow areas at the corticomedullary junction* ➡ *are due to lipid in tubules.*

De Novo CG Due to Calcineurin Inhibitor Therapy

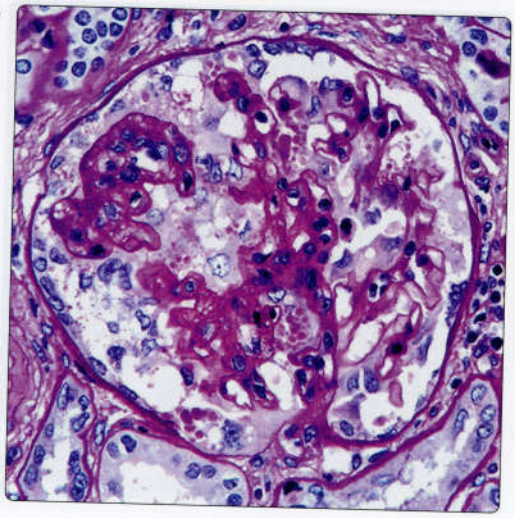

CG Complicating IgA Nephropathy

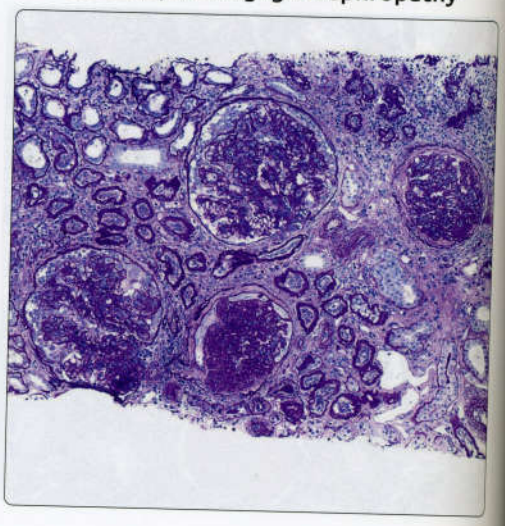

(Left) *De novo CG developed in the native kidneys of this patient 10 years post heart and lung transplant. Severe arteriolar hyalinosis was also present, related to cyclosporin therapy.* **(Right)** *IgA nephropathy can present with superimposed CG, as in this case, which had mesangial IgA (3+) and electron-dense deposits. The disease typically rapidly progresses with end-stage renal disease (ESRD) in 90%.*

CG Related to *Plasmodium falciparum* Malaria

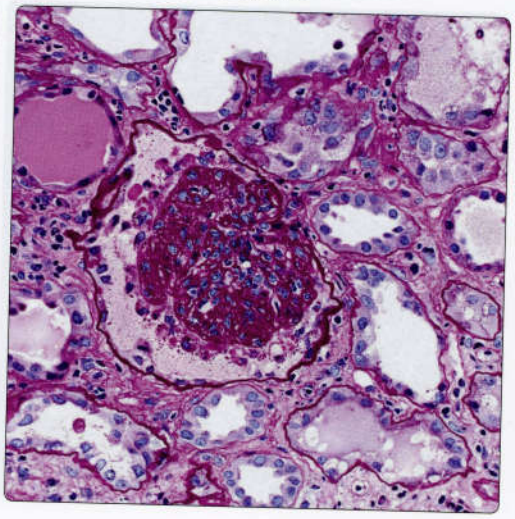

Tubuloreticular Inclusion in HIV

(Left) *A biopsy is depicted from a 28-year-old black woman who returned from South Africa with Plasmodium falciparum malaria and new onset of nephrotic syndrome. Black patients with certain APOL1 variants have a much greater risk of developing CG secondary to other forms of glomerular disease.* **(Right)** *Tubuloreticular inclusions ⇨ are present in endothelial cells in CG secondary to HIV infection; these are not often present in other causes of CG, except those related to high interferon states.*

CG Due to Interferon Therapy

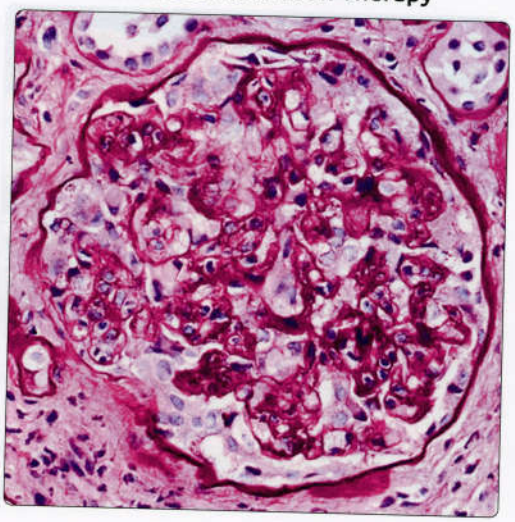

Tubuloreticular Structures Due to Interferon Therapy

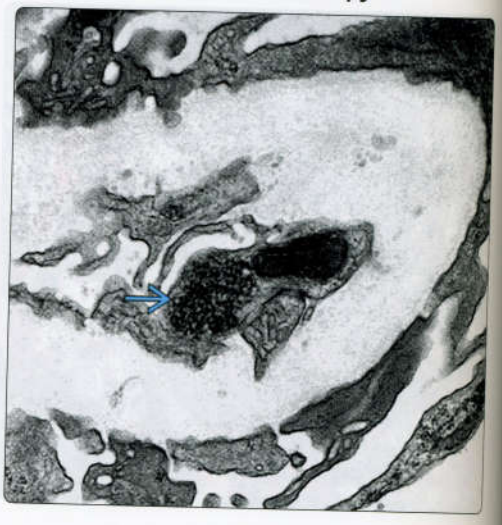

(Left) *CG is shown in a woman who developed nephrotic syndrome while on interferon-β for treatment of multiple sclerosis. Collapse and prominent epithelial cell hyperplasia are present. Intracapillary leukocytes are also present, a feature of the cellular variant of FSGS.* **(Right)** *In CG present in a woman on interferon-β for treatment of multiple sclerosis, numerous tubuloreticular structures ⇨ were present in the glomerular endothelium, an effect of interferon-α, -β, or -γ.*

Ki-67 Highlights Proliferating Visceral and Parietal Epithelium

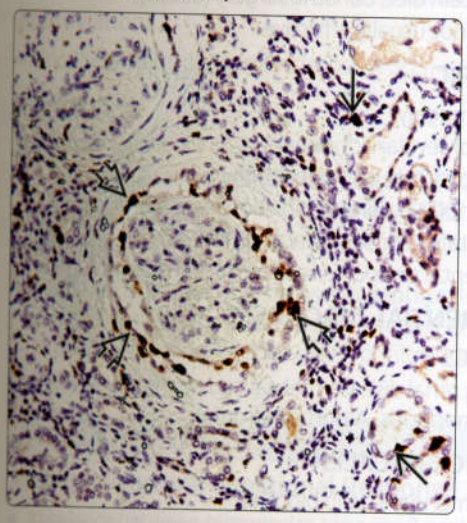

Ki-67(+) Tubular Epithelium

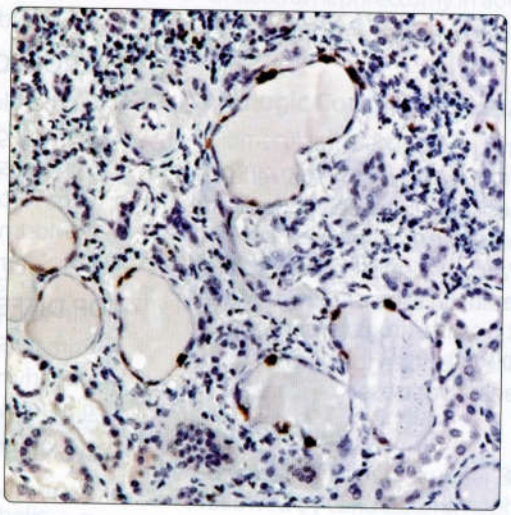

(Left) *Ki-67 immunohistochemistry highlights proliferating glomerular epithelium ⇨. Occasional Ki-67(+) proliferating tubular epithelial cells ⇨ are also present, compatible with the tubular injury that can be seen in CG.* **(Right)** *Just as proliferation of glomerular epithelial cells occurs in CG, proliferation of proximal tubular cells also occurs, as shown here with a Ki-67 stain. This indicates that proliferation is a more generalized phenomenon in CG.*

Colloidal Iron Lost Due to Loss of Podocyte (-) Charge

No WT1 Expression in Visceral Epithelial Cells of Collapsing Segments

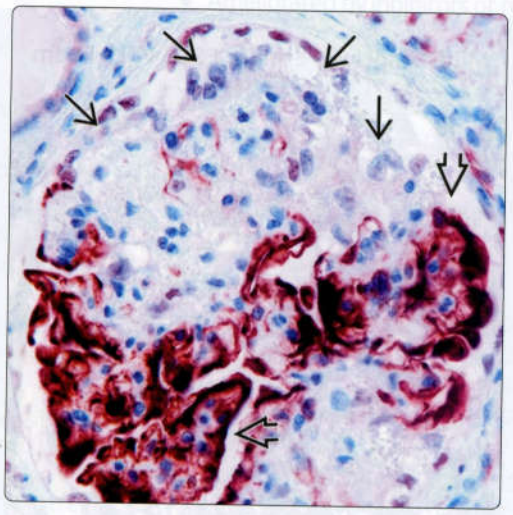

(Left) *Loss of the negative charge of the podocytes can be detected by loss of colloidal iron staining ⇨, as shown segmentally in this glomerulus. Normal staining is seen in 1/2 of the glomerulus ⇨. Alternatively, this may indicate segmental loss of podocytes.* **(Right)** *WT1 stain of glomerulus in CG shows segmental loss of expression in the visceral epithelium ⇨, possibly indicating podocyte loss and replacement with parietal epithelial cells. The other 1/2 of the glomerulus stains normally for WT1 ⇨.*

Ectopic Expression of CK8/18 in Visceral Epithelial Cells

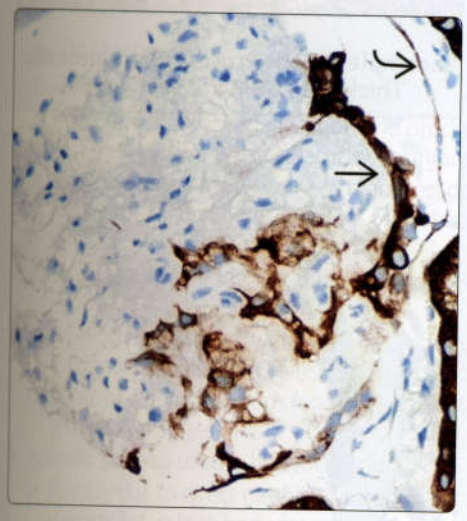

Ectopic Expression of CK19 in Visceral Epithelial Cells

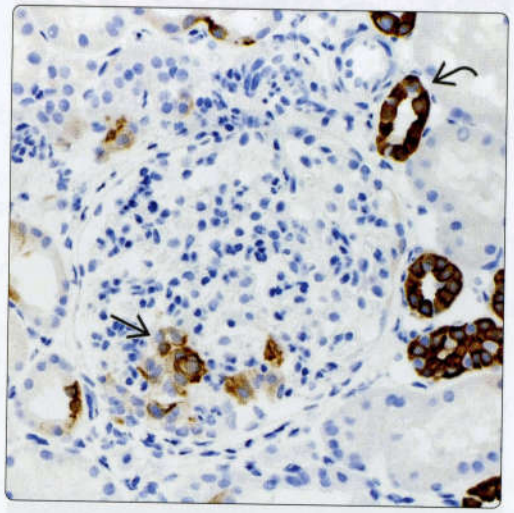

(Left) *CK8/18 shows expression in visceral epithelial cells ⇨ in a patient with CG. This cytokeratin is normally expressed by parietal epithelial cells ⇨ but not podocytes. This likely represents replacement of podocytes by the parietal epithelium.* **(Right)** *Ectopic expression of CK19 in visceral epithelial cells ⇨ is characteristic of CG. Podocytes do not normally express CK19, although distal tubules do ⇨.*

Focal Segmental Glomerulosclerosis, Adaptive (Secondary)

KEY FACTS

TERMINOLOGY

- FSGS due to adaptive response to excess demand on glomerular function

ETIOLOGY/PATHOGENESIS

- Adaptive structural-functional response
  - Reduced nephron mass: Oligomeganephronia, reflux nephropathy, renal agenesis/dysplasia, ablation, cortical necrosis, advanced renal disease of any cause
  - Normal nephron mass: Vascular disease, obesity-related glomerulopathy, atheroemboli/vasoocclusion, sickle cell anemia, congenital heart disease, drugs (anabolic steroids, calcineurin inhibitors)
- Podocytopenia due to maladaptive stress

CLINICAL ISSUES

- Proteinuria & systemic HTN
- Treatment
  - Angiotensin II receptor antagonists &/or ACE inhibitors
  - Low-protein diet, bariatric surgery (obesity)
  - Steroids not usually effective

MICROSCOPIC

- Glomerulomegaly
- Perihilar glomerular adhesion & hyaline
- Compensatory tubular hypertrophy
- Often arteriolar hyalinosis, arteriosclerosis
- IF: Most notable for segmental IgM & C3
- EM: Segmental podocyte foot process effacement

TOP DIFFERENTIAL DIAGNOSES

- Primary FSGS
- Underlying renal disease that caused nephron loss (e.g., glomerulonephritis, Alport syndrome)

DIAGNOSTIC CHECKLIST

- Assess glomerular size in biopsies
- Rough guide: Normal glomeruli are < 50% of diameter of 40x field of 440 μm

Mild Adaptive Perihilar FSGS With Foam Cells

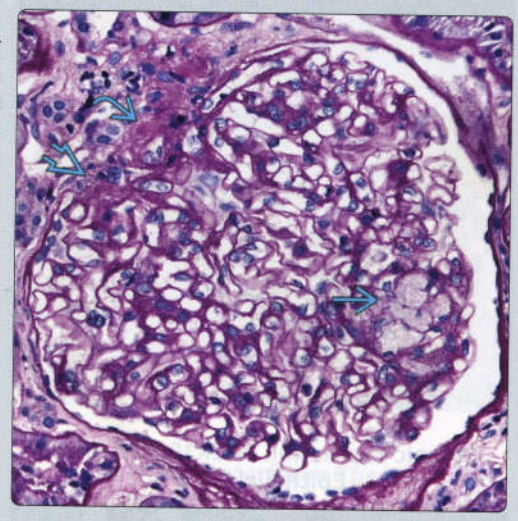

Adaptive FSGS in Metabolic Syndrome

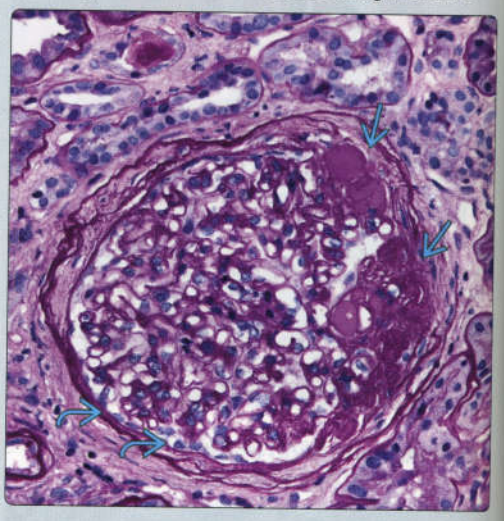

(Left) *This case from a patient with obesity shows glomerular hypertrophy with mild perihilar FSGS, vascular hyalinosis, and intraglomerular foam cells. (Courtesy H. Rennke, MD.)* **(Right)** *This glomerulus from a patient with obesity and metabolic syndrome shows perihilar segmental hyalinosis and sclerosis and activated parietal epithelial cells. Perihilar glomerulosclerosis is typical of adaptive FSGS but not specific.*

Segmental C3 Deposition

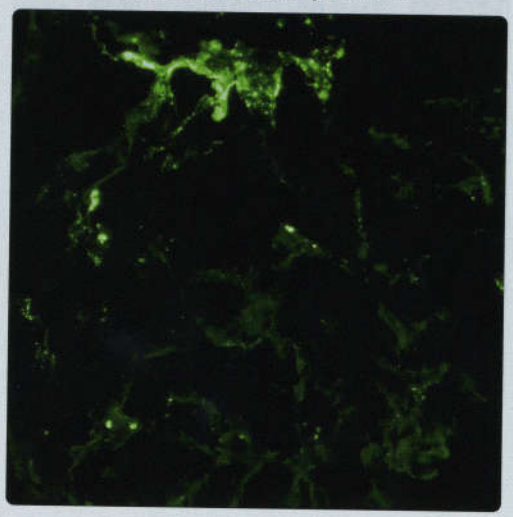

Incomplete Foot Process Effacement and Thickened GBM in Adaptive FSGS

(Left) *Segmental C3 deposition occurs in areas of glomerular scarring and adhesion in FSGS due to any cause, including, as illustrated in this case, with adaptive FSGS. IgM shows a similar pattern. This is a common pattern in other types of FSGS.* **(Right)** *Adaptive FSGS most often shows incomplete or segmental foot process effacement. This is best assessed in a nonsclerotic glomerulus. The GBM is thickened, similar to that in diabetes. (Courtesy H. Rennke, MD.)*

TERMINOLOGY

Abbreviations

- Focal segmental glomerulosclerosis (FSGS)

Synonyms

- Perihilar variant of FSGS
  - Common histologic pattern of adaptive FSGS but also occurs in minority (< 10%) of primary FSGS

Definitions

- Adaptive FSGS arises as response to nephron loss or ↑ demand, likely due to ↑ filtration/perfusion of glomeruli, insufficient numbers of podocytes for filtration area, & podocyte stress

ETIOLOGY/PATHOGENESIS

Adaptive Structural-Functional Response

- Imbalance between glomerular capacity & metabolic demands
  - Thought to act through glomerular HTN, ↑ filtration, relative podocytopenia, & podocyte stress
  - ↑ glomerular capillary pressures & flow rates
- Arises from several pathways
  - Failure to develop normal number of glomeruli
    - Unilateral renal agenesis, dysplasia, oligomeganephronia, low birth weight, & other congenital renal developmental diseases
  - Acquired disease that causes loss of functional nephrons
    - Sequelae of chronic renal disease of any etiology with nephron loss as final common pathway
    - Reflux nephropathy, Alport syndrome, HTN, cortical necrosis, & virtually any other chronic renal disease
  - Normal number of glomeruli but ↑ "demand"
    - Obesity, body builders, anabolic steroids, possibly HTN

Common Mechanism

- Adaptive podocyte injury & loss, due to ↑ podocyte stress
  - Unable to keep up with ↑ glomerular size (capillary surface area)
  - Ischemia due to hypoperfusion

Specific Mechanisms

- Obesity-related glomerulopathy (ORG)
  - Receptor for advanced glycation end products (RAGE) may mediate obesity-associated renal injury
  - RAGE may also be important to diabetes, doxorubicin-induced nephropathy, HTN, lupus nephritis, ischemic renal injury, & renal amyloidosis
- Chronic vasoconstriction, leading to sustained or episodic ischemia
  - Arteriolar constriction with variable glomerular perfusion (calcineurin inhibitors in transplant recipients)
  - Abuse of vasoactive drugs (cocaine, amphetamines, systemic decongestants)
- Anabolic steroids used in bodybuilding
  - Possibly due to direct nephrotoxic effect of anabolic steroids & ↑ in lean body mass
- Sleep apnea
  - Hypoxia leads to sympathetic nervous system activation & stimulates renin-angiotensin system
- Unilateral renal agenesis
  - Higher risk of FSGS than general population
- Unilateral nephrectomy in adults no ↑ risk for FSGS
- Arteriosclerosis, with hypoperfusion of kidney & secondary HTN

Pathologic Consequences

- Glomerular hypertrophy
  - ↑ in diameter & number of mesangial cells
  - Thickened GBM
  - Relative deficiency of podocytes, which have limited replicative ability
- Segmental glomerular capillary scars and adhesions to Bowman capsule
  - Classically, adhesion & hyaline in perihilar region (perihilar variant)

Murine Model

- Removal/infarction of upper & lower pole of kidney followed by contralateral nephrectomy (5/6 nephrectomy)
- Results in HTN, glomerulomegaly, & later, FSGS over 8-12 weeks with proteinuria & loss of renal function
- Ameliorated by inhibitors of renin-angiotensin system (angiotensin II receptor inhibitors)

CLINICAL ISSUES

Epidemiology

- Incidence
  - Apparent ↑ incidence of ORG coincident with obesity epidemic

Presentation

- Proteinuria is often > 3.5 g/d but usually without hypoalbuminemia, hypercholesterolemia, & edema
  - Specifically, ORG shows a greater ↓ in incidence of nephrotic syndrome than idiopathic FSGS
- Renal dysfunction
  - Most have ↑ serum Cr & ↓ glomerular filtration rate (GFR) preceding development of nephrotic proteinuria
    - ORG is notable exception since it may have ↑ GFR (supernormal, > 120 mL/min) 2° to hyperfiltration caused by ↑ ratio of body mass to renal mass
- HTN
- ORG patients typically have BMI > 30
  - BMI 30.0-34.9, grade 1 obesity; BMI 35.0-39.9, grade 2 obesity; & BMI ≥ 40.0, grade 3 obesity (morbid obesity)

Treatment

- Drugs
  - Steroids are not typically effective and may be contraindicated
  - Angiotensin II receptor antagonists &/or ACE inhibitors
- Stop anabolic steroid, cocaine, or decongestant use
- Low-protein diet
- Bariatric surgery may normalize proteinuria in ORG

Prognosis

- Adaptive FSGS more indolent than primary FSGS
- Prognosis of perihilar variant of FSGS variable
  - Probably relates to underlying cause

MICROSCOPIC

Histologic Features

- Glomeruli
  - Glomerulomegaly
    - Glomeruli enlarged with expanded hypercellular mesangium
    - Universal definition of glomerulomegaly not established, even by "gold standard" morphometric methods due to significant population variability
    - Rule of thumb: Glomerular diameter > 220 µm (~ 1/2 diameter of typical 40x objective field)
    - Variable degrees, heterogeneity
  - Segmental glomerulosclerosis (GS)
    - Loss of intrinsic cells & structure of glomerulus
    - Global GS may also be present
  - Adhesion to Bowman capsule
    - Often in perihilar region
    - Contains hyaline deposits in capillary loops
    - Hyalinosis composed of protein insudation between GBM & endothelial cells
    - To qualify for hilar variant, > 50% of glomeruli with segmental lesions must have perihilar GS &/or hyalinosis
    - Foam cells may be seen in glomeruli &/or interstitium
  - Podocyte hypertrophy & hyperplasia may be present
- Vessels
  - Arteriolar hyalinosis may be in continuity with perihilar segment of arteriole
- Tubules & interstitium
  - Tubular hypertrophy (↑ tubular diameter & cell size)
  - Atrophy & interstitial fibrosis related to ↓ nephron number

Specific Features by Cause

- Obesity
  - Mesangial expansion, GBM thickening, & glomerulomegaly
  - Segmental lesions often perihilar with hyalinosis
  - Tubulointerstitial disease often mild in comparison with glomerular changes
- Reflux nephropathy
  - Reflux nephropathy shows prominent periglomerular fibrosis & thickening of Bowman capsule
  - Interstitial fibrosis in geographic pattern
- Sickle cell disease
  - Glomerular hypertrophy & capillary loop congestion by sickled erythrocytes
  - Glomerular capillaries may have double contours due to thrombotic microangiopathy
- Vascular disease
  - Endothelial injury, sometimes with capillary wall remodeling (double contours)
  - Vasoconstriction &/or arteriosclerosis
  - HTN
  - Glomerulosclerosis occurs in outer cortex, forming subcapsular scars
  - Often perihilar lesions

ANCILLARY TESTS

Immunofluorescence

- Segmental IgM & C3 in glomerulosclerotic lesions
- Little or no immunoglobulin otherwise

Electron Microscopy

- Podocyte foot process effacement (FPE) is cardinal feature
  - Typically mild or segmental FPE (often < 50%)
    - Average foot process width of < 1,500 µm distinguishes adaptive FSGS from primary FSGS (100% sensitive & 70% specific)
  - Podocyte hypertrophy & hyperplasia typically < in primary FSGS
  - Podocytes may contain protein resorption droplets
  - Podocytes may detach from GBM, leaving bare GBM
- Thickened GBM > 350 nm in 70% in one series of ORG
- Features of particular etiologies
  - Obesity-associated FSGS: Subtotal FPE & marked glomerulomegaly
  - HTN: Ischemic wrinkling & thickening of GBM

DIFFERENTIAL DIAGNOSIS

Primary FSGS

- Less glomerulomegaly, more diffuse FPE
- Majority NOS variant rather than perihilar

Identification of Underlying Renal Disease

- Look for features of underlying immune complex, proliferative, or nonimmune diseases
- Immune complexes may be difficult to find in end-stage kidneys, making diligent search necessary

Focal Glomerulonephritis

- Segmental scars may be residue of past inflammatory glomerulonephritis

DIAGNOSTIC CHECKLIST

Pathologic Interpretation Pearls

- Perihilar glomerulosclerosis & hypertrophy are clues to diagnosis
- Routinely assess glomerular size in biopsies
  - Normal is < 50% of diameter of 40x field (440 µm)

SELECTED REFERENCES

1. D'Agati VD: Podocyte growing pains in adaptive FSGS. J Am Soc Nephrol. 28(10):2825-7, 2017
2. Nishizono R et al: FSGS as an adaptive response to growth-induced podocyte stress. J Am Soc Nephrol. 28(10):2931-45, 2017
3. Ikezumi Y et al: Low birthweight and premature birth are risk factors for podocytopenia and focal segmental glomerulosclerosis. Am J Nephrol. 38(2):149-57, 2013
4. D'Agati VD et al: Focal segmental glomerulosclerosis. N Engl J Med. 365(25):2398-411, 2011
5. D'Agati V et al: RAGE and the pathogenesis of chronic kidney disease. Nat Rev Nephrol. 6(6):352-60, 2010
6. Herlitz LC et al: Development of focal segmental glomerulosclerosis after anabolic steroid abuse. J Am Soc Nephrol. 21(1):163-72, 2010
7. Goumenos DS et al: Early histological changes in the kidney of people with morbid obesity. Nephrol Dial Transplant. 24(12):3732-8, 2009
8. D'Agati VD et al: Pathologic classification of focal segmental glomerulosclerosis: a working proposal. Am J Kidney Dis. 43(2):368-82, 2004
9. Rennke HG et al: Pathogenesis and significance of nonprimary focal and segmental glomerulosclerosis. Am J Kidney Dis. 13(6):443-56, 1989

Global and Segmental Glomerulosclerosis

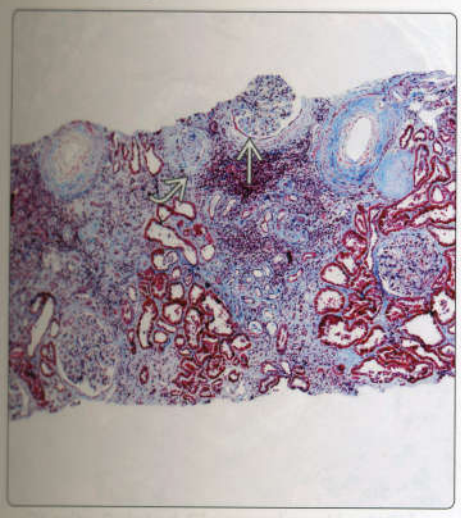

Perihilar Adhesion and Scar in Hypertensive Renal Disease

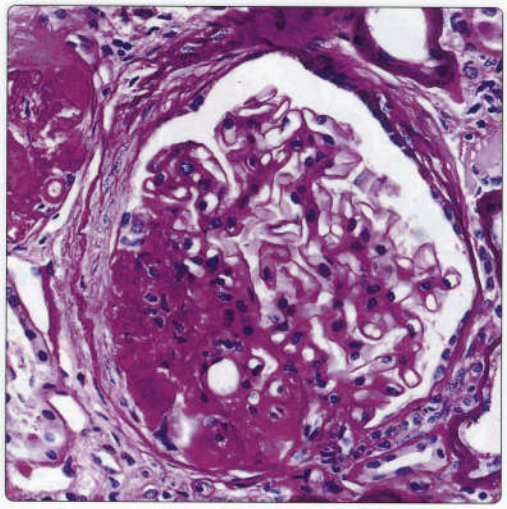

(Left) *One of the more common causes of adaptive FSGS is HTN, which causes progressive loss of functional nephrons and produces global ➡ and segmental ➡ glomerulosclerosis, as shown here in a 63-year-old woman with poorly controlled HTN for 30 years.* **(Right)** *Adaptive FSGS can arise from many causes; in this case, hilar sclerosis and adhesions were due to chronic renal disease presumed to be hypertensive nephropathy. Cr was 2.2, and the urine protein/Cr ratio was 2.8.*

Sclerosis at Glomerular Hilum With Lipid Droplets

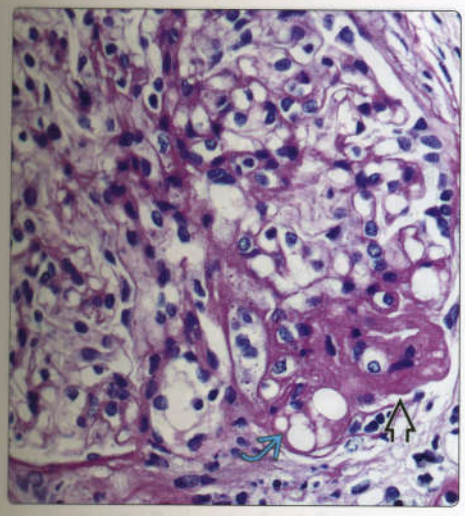

Perihilar Segmental Glomerulosclerosis

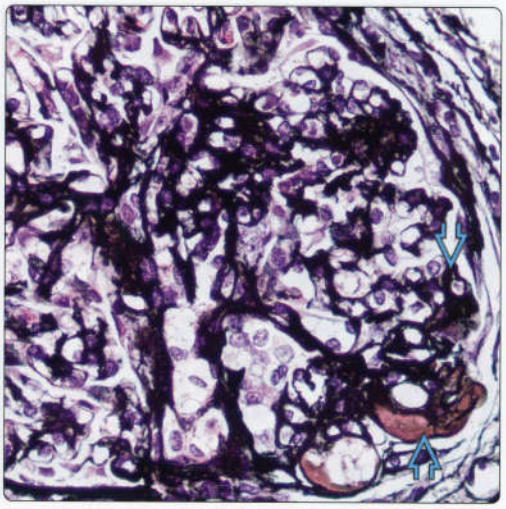

(Left) *High power of a PAS stain shows sclerosis at the glomerular hilum ➡ containing lipid droplets ➡.* **(Right)** *High-power view of a silver stain in a 21-year-old man with nephrotic syndrome and perihilar segmental glomerulosclerosis shows that intracapillary hyaline ➡ is present in the segmental sclerosis lesion.*

Adaptive FSGS in Reflux Nephropathy

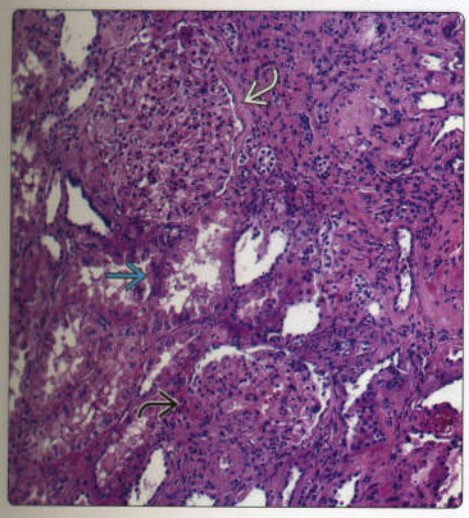

IgM Deposits Segmentally in FSGS

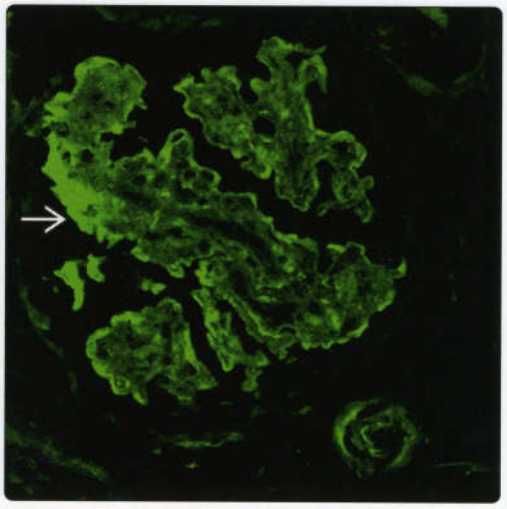

(Left) *Late-stage bilateral reflux nephropathy is one of the classic causes of adaptive FSGS. The remaining glomeruli are hypertrophied ➡; the spared tubules are also hypertrophied ➡. Perihilar adhesions are present ➡.* **(Right)** *The main value of immunofluorescence (IF) in patients with FSGS is to rule out underlying glomerular disease. In FSGS of all types, segmental deposits of IgM ➡ and C3 are in the segmental lesions, sometimes with segmental granular deposits along the GBM.*

Obesity-Related Glomerulopathy With Hypertrophic Glomerulus and Periglomerular Fibrosis

Obesity-Related Glomerulopathy With Glomerular Capillary Loop Condensation

(Left) *H&E from a 37-year-old African American woman with morbid obesity (> 350 lb), HTN, and proteinuria shows a hypertrophic glomerulus* ⇨ *and a relatively normal-sized glomerulus with periglomerular fibrosis* ⇨. *Overall, this is clinicopathologically compatible with obesity-related glomerulopathy (ORG).* **(Right)** *In an ORG case, there is peripheral condensation of the glomerular capillary loops* ⇨, *suggestive of evolving FSGS.*

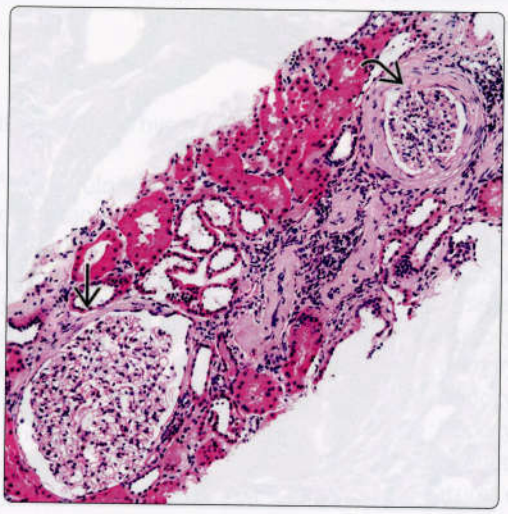

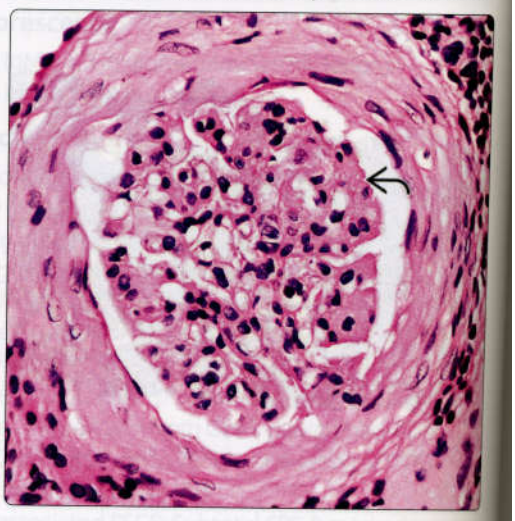

Obesity-Related Glomerulopathy With Peripheral Irregularities

Obesity-Related Glomerulopathy With Peripheral Irregularities

(Left) *A PAS stain shows the peripheral irregularities in glomerular capillary loops* ⇨ *in a case most compatible with ORG in a 37 year old with morbid obesity.* **(Right)** *A periodic acid methenamine silver stain shows peripheral irregularities* ⇨ *in the glomerular capillary loops in a patient with ORG.*

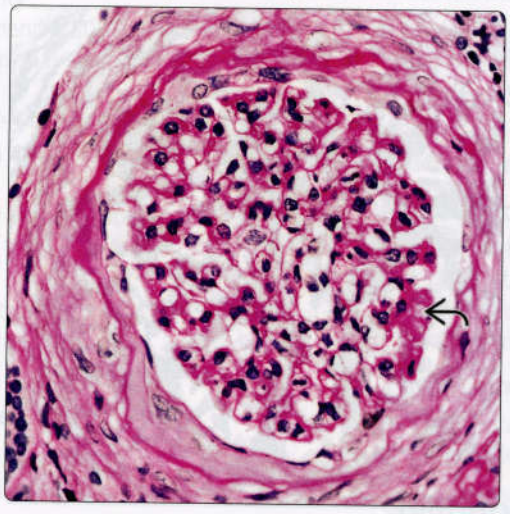

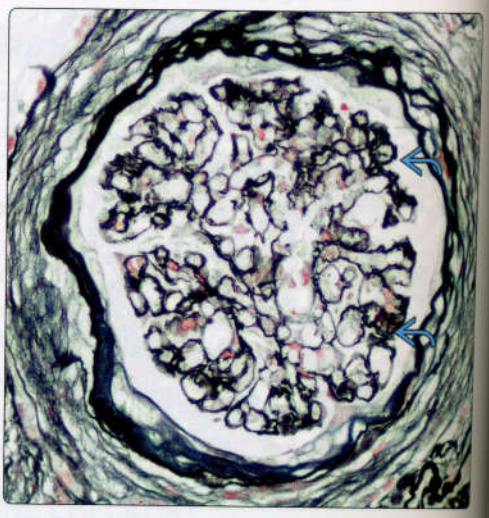

Obesity-Related Glomerulopathy With Glomerular Hypertrophy

Obesity-Related Glomerulopathy With Glomerular Hypertrophy

(Left) *This glomerulus shows marked hypertrophy in a patient with ORG. A rule of thumb is whether the glomerular diameter exceeds 1/2 of the diameter of a standard 40x field (440 µm).* **(Right)** *Hypertrophied glomeruli have an increased number of capillaries and a marked increase in the surface area of the GBM, which stretches the nondividing podocyte to cover a greater area causing stress. Few podocyte nuclei are identified* ⇨, *and some appear stretched* ⇨.

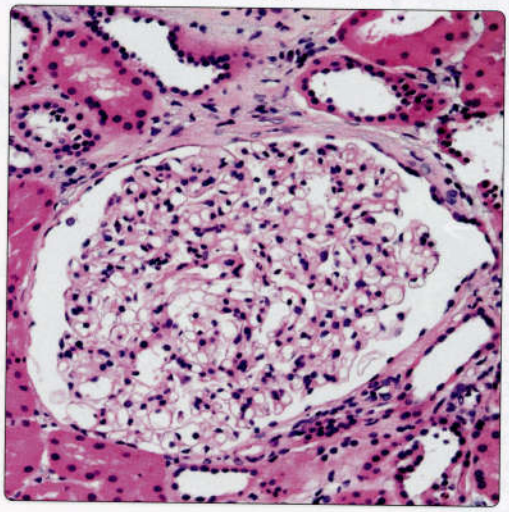

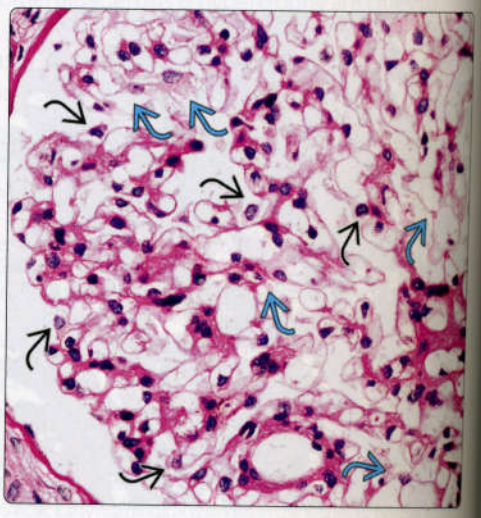

Obesity-Related Glomerulopathy With Minimal Foot Process Effacement

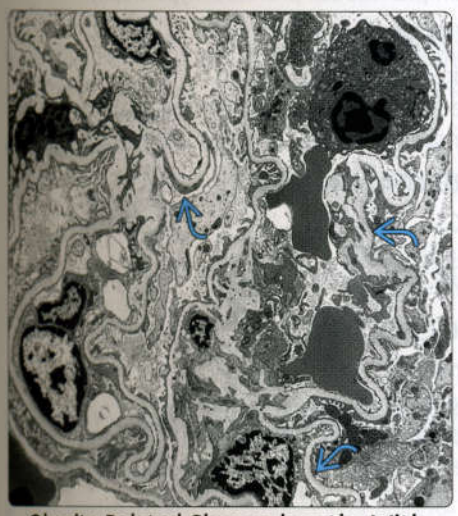

Obesity-Related Glomerulopathy With Segmental Podocyte Foot Process Effacement

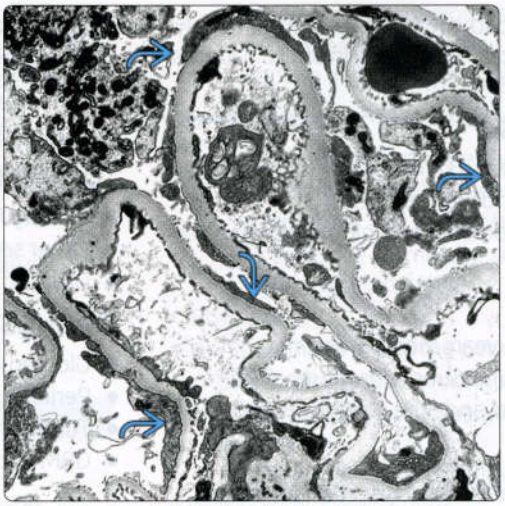

(Left) *In a 53-year-old man with morbid obesity (BMI 41.9), Cr 10 mg/dL, and a urine protein/Cr ratio of 12.96, there is only patchy foot process effacement (FPE).* **(Right)** *Segmental FPE is present here, typical of adaptive FSGS, in contrast to the widespread effacement usually found in primary FSGS.*

Obesity-Related Glomerulopathy With Segmental Podocyte Foot Process Effacement

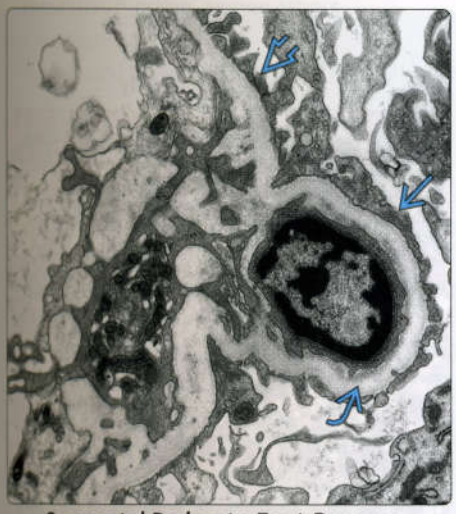

Segmental Podocyte Foot Process Effacement in FSGS From Anabolic Steroids

(Left) *Prominent segmental podocyte FPE is shown here together with more preserved foot processes, compatible with obesity-related FSGS. A few amorphous mesangial deposits of uncertain significance are present.* **(Right)** *In a 40-year-old male bodybuilder with years of anabolic steroid use, there is segmental podocyte FPE. This adaptive FSGS is attributed to increased glomerular filtration demand due to anabolic steroid use.*

Segmental Podocyte Foot Process Effacement in FSGS From Anabolic Steroids

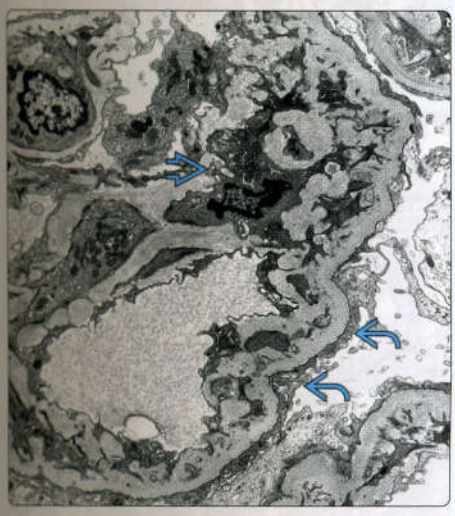

Vague Densities in FSGS from Anabolic Steroids

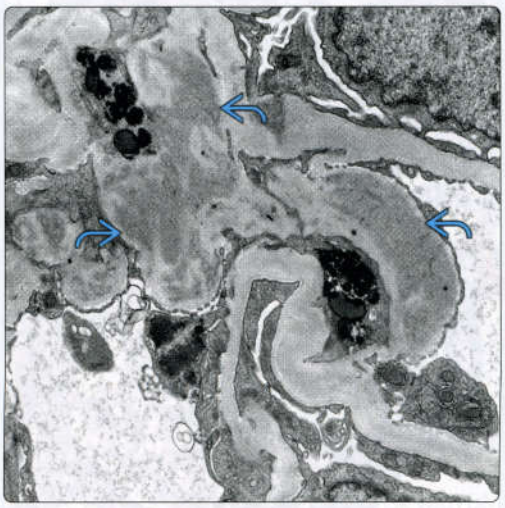

(Left) *This patient with a history of years of anabolic steroid use for bodybuilding has segmental podocyte FPE and mesangial expansion.* **(Right)** *In FSGS attributed to anabolic steroids, there were occasional vague densities, some having a hyaline quality. IF did not impart specificity to the densities, suggesting that their presence is secondary to entrapment.*

KEY FACTS

TERMINOLOGY

- Obesity-related glomerulopathy (ORG) is glomerulomegaly and secondary adaptive focal FSGS arising in obese patients with body mass index of ≥ 30 kg/m²

ETIOLOGY/PATHOGENESIS

- Increased body mass relative to kidney size
- Glomerular hypertension and hyperfiltration
- Segmental sclerosis is predominantly in glomerular perihilar zones

CLINICAL ISSUES

- Middle-aged adults ~ 35-45 years most commonly
- Slowly progressive proteinuria: Subnephrotic in > 90%
- Renal survival 75% at 5 years and 50% at 10 years in ORG

MICROSCOPIC

- Glomerulomegaly with increased cross-sectional area and volume of glomeruli
- Segmental glomerular sclerosis
- Enlarged complex tubular profiles in hypertrophy

ANCILLARY TESTS

- Electron microscopy
  - Thickened GBMs and mesangial sclerosis
  - Partial or segmental foot process effacement

TOP DIFFERENTIAL DIAGNOSES

- Primary FSGS
- Other secondary FSGS
- Diabetic nephropathy

DIAGNOSTIC CHECKLIST

- Glomerulomegaly
- Perihilar segmental sclerosis
- Tubular hypertrophy
- GBM thickening and segmental foot process effacement

Glomerulomegaly in Obesity-Related Glomerulopathy

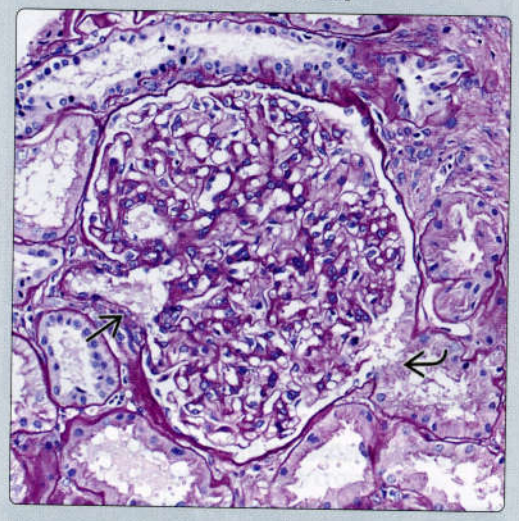

Glomerulomegaly

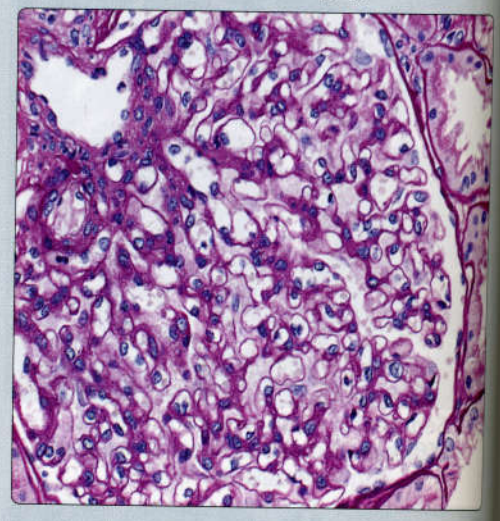

(Left) *This glomerulus from a 26-year-old woman with a body mass index (BMI) of 49.5 is enlarged with mild mesangial expansion but no hypercellularity, a characteristic feature of obesity-related glomerulopathy (ORG). The hilus ⇨ and exit pole ⇨ are present.* **(Right)** *This glomerulus fills more than 1/2 of a 40x high-power field, indicative of hypertrophy or glomerulomegaly. The GBM is generally thickened and there is mild mesangial expansion. Capillaries are open, and cellularity is normal.*

Perihilar Segmental Sclerosis

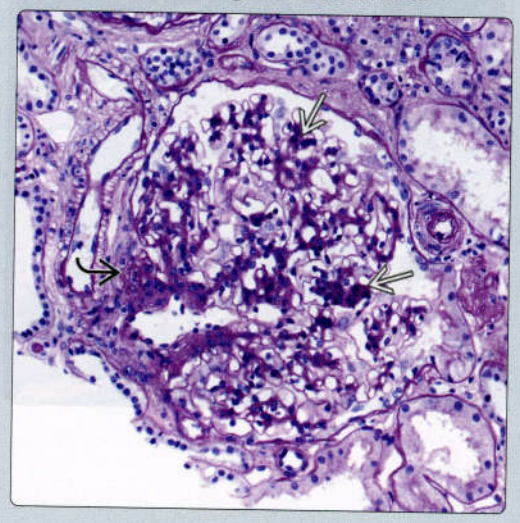

Extended Perihilar Segmental Sclerosis

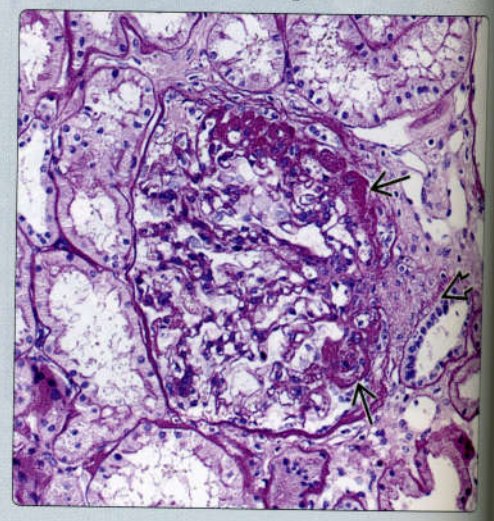

(Left) *This glomerulus from a 33-year-old obese man with 2 g proteinuria has segmental sclerosis ⇨ adjacent to the hilus or vascular pole. There appears to be mild mesangial hypercellularity ⇨, although this could be the effects of a near transhilar section.* **(Right)** *This glomerulus from a 60-year-old man with a BMI of 35.4 and proteinuria is enlarged and has hyalinization on each side of the hilus ⇨. The upper hyalinized segment has broad adhesion to Bowman capsule. Macula densa and juxtaglomerular apparatus ⇨ are also shown.*

TERMINOLOGY

Definitions

- Obesity-related glomerulopathy (ORG) is glomerulomegaly and secondary adaptive FSGS arising in obese patients with body mass index (BMI) of ≥ 30 kg/m²
- Metabolic syndrome is concurrence of obesity and metabolic risk factors for type 2 diabetes mellitus (T2DM) and cardiovascular disease
  - Metabolic risk factors include
    - Abdominal obesity (increased waist-to-hip ratio)
    - Hyperglycemia
    - Dyslipidemia
    - Hypertension

ETIOLOGY/PATHOGENESIS

Metabolic Disorder

- Increased BMI due to accumulation of adipose tissue
  - BMI = mass in kg/(height in m)²; normal = 18.5-25.0 kg/m²
- Obesity has effects on circulatory, endocrine, and respiratory function, among others
- Circulatory
  - Increased body mass is associated with increased blood volume
  - Leads to increased renal blood and plasma flow, and increased glomerular filtration rate (GFR)
    - May begin to develop when BMI is < 30 kg/m²
  - Glomerular hypertension due to increased capillary flow and hydraulic pressure
  - Leads to hyperfiltration (increased filtration fraction = GFR/renal plasma flow)
  - Adaptive increase in glomerular volume and matrix synthesis, and tubular volume
  - Reduced podocyte density
    - Prolonged podocyte shear stress results in loss of adhesion and detachment
  - Adhesion formation and nidus for development of segmental sclerosis
  - Segmental sclerosis is predominantly in glomerular perihilar zones
    - Highest glomerular hydraulic pressure near entry of afferent arteriole
  - Progression to global sclerosis
- Endocrine
  - Adipose tissue has endocrine function and secretes adipokines
    - These include leptin, visfatin, and apelin
  - Leptin receptors on endothelial and mesangial cells in mouse kidney
    - May have effects on GBM and mesangial matrix synthesis
    - Some evidence of profibrotic effects also
  - Other endocrine effects of obesity include
    - Hyperglycemia and hyperinsulinemia
      - > 90% of T2DM have obesity
      - ~ 1/3 of obese have T2DM
    - Elevated growth hormone and insulin-like growth factor levels
- Respiratory
  - Obstructive sleep apnea
    - Activates renal sympathetic nervous system by intermittent hypoxia
    - Activates renin-angiotensin aldosterone system
    - Promotes hyperfiltration, glomerular hypertension, sodium and water retention

Consequences of Glomerular Hyperfiltration

- Structural changes precede changes in function
  - Nephron hypertrophy or nephromegaly
    - Glomerular and tubular hypertrophy
    - Progressive glomerular sclerosis, interstitial fibrosis, and tubular atrophy
- Physiologic
  - Albuminuria (> 500 mg per day)
  - Slowly progressive proteinuria
  - Proteinuria may eventually reach nephrotic range (> 3.5 g/24 hours)
  - Possible contributions of renal lipid accumulation unclear

CLINICAL ISSUES

Presentation

- Middle-aged adults ~ 35-45 years most common
- May also arise in children and older adults
- ORG may be present without overt clinical disease
- Slowly progressive proteinuria: Subnephrotic in > 90%
- Nephrotic range proteinuria in ~ 10%, but nephrotic syndrome is rare (< 5%)
- Contribution of diabetic nephropathy to proteinuria in metabolic syndrome

Treatment

- Weight loss induces significant reduction of proteinuria
  - Proteinuria reduction is directly proportional to weight lost
  - Reduction of proteinuria occurs within days on low calorie diet
    - May arise without change in GFR
- Blockade of renin angiotensin system
  - Angiotensin receptor blockers and angiotensin converting enzyme inhibitors
    - Reduction of glomerular hyperfiltration and proteinuria
- Bariatric surgery
  - Roux-en-Y gastric bypass, gastric banding, and partial gastrectomy
  - Associated with weight loss, decreased GFR, and reduction of proteinuria

Prognosis

- Slowly progressive proteinuria often with hypertension and T2DM
  - Slower progression compared with primary FSGS
- Renal survival 75% at 5 years and 50% at 10 years in ORG
- BMI associated with increased relative risk of ESRD
  - Risk of ESRD is directly proportional to BMI in 1 large study
  - ~ 2x increased risk with BMI of 25-29.9
  - ~ 4x increased risk with BMI of 30-34.9
  - ~ 6x increased risk with BMI of 35-39.9
  - ~ 7x increased risk with BMI of ≥ 40

MACROSCOPIC

Size

- Kidneys may be enlarged in massive obesity (BMI of ≥ 40)

MICROSCOPIC

Histologic Features

- Glomeruli
  - Glomerulomegaly with increased cross-sectional area and volume of glomeruli
    - Glomerular diameter averaged 226 μm in 1 study (controls 168 μm)
    - Rule of thumb: Diameter > 1/2 of 40x high-power field most likely glomerulomegaly
    - Thickened GBMs
    - Increased mesangial matrix ± hypercellularity
  - Segmental glomerular sclerosis
    - Tuft consolidation by matrix and hyaline with capillary obliteration
    - Consolidated areas have foam cells in early stages
    - Characteristically located in the perihilar zone
    - ~ 20% pure perihilar and 80% perihilar and peripheral in 1 study
    - Extent of segmental sclerosis averages 6-12% of glomeruli
      - ~ 40-50% in primary FSGS
  - Global glomerular sclerosis with hyalinosis
  - May be complicated by diabetic glomerulopathy
  - Decreased glomerular density on low-power microscopy
    - Possibly attributable to
      - Tubular hypertrophy
      - Low initial nephron endowment
- Tubules and interstitium
  - Enlarged complex tubular profiles in hypertrophy
    - Larger diameter; may be nuclear crowding
  - Interstitial fibrosis, nonspecific mononuclear inflammation, focal tubular atrophy
    - May be progressive
- Vessels
  - Arteriosclerosis and arteriolosclerosis are common

ANCILLARY TESTS

Immunofluorescence

- IgM, C3, and C1q accumulate in hyalinized glomerular segments
- Podocyte protein droplets contain IgG, IgA and albumin
- No immune complex deposits in the glomeruli

Electron Microscopy

- Lipid droplets in mesangial cells and in podocytes
- Thickened GBMs
- Mesangial matrix expansion ± hypercellularity
- Partial or segmental foot process effacement
  - 25-40% in ORG compared to > 75% in primary FSGS
  - Segmental effacement even with nephrotic range proteinuria
  - Segmental detachment with basket-weave new basement membrane
- Hyalinization typically intramembranous; no immune-type electron-dense deposits

DIFFERENTIAL DIAGNOSIS

Primary FSGS

- Proteinuria more severe and with sudden onset
- Glomeruli not enlarged
- Segmental sclerosis involves higher proportion of glomeruli
  - 40-50% in primary FSGS compared with 6-12% in ORG associated FSGS
- Perihilar FSGS relatively uncommon at ~ 16% of adult biopsies with primary FSGS
  - Other variants collectively more frequent
- GBMs of normal thickness
- More extensive foot process effacement in primary FSGS (> 75%)

Diabetic Nephropathy

- Early features characterized by increased GFR and microalbuminuria
- Persistent hyperglycemia and elevated hemoglobin A1C
- Glomeruli are enlarged with thickened basement membranes in early disease
  - Difficult or impossible to distinguish from ORG on morphologic grounds
  - Perihilar segmental sclerosis likely due to ORG
- Hyalinization of afferent and efferent arterioles

Other Secondary FSGS

- Arterionephrosclerosis: Vascular sclerosis, ischemic glomerulopathy
- Anabolic steroids: Clinical history
- Developmental disorders like hypoplasia and oligomeganephronia
  - Small kidneys with fewer lobes; marked glomerulomegaly

SELECTED REFERENCES

1. De Vriese AS et al: Differentiating primary, genetic, and secondary FSGS in adults: a clinicopathologic approach. J Am Soc Nephrol. 29(3):759-774, 2018
2. Nishizono R et al: FSGS as an adaptive response to growth-induced podocyte stress. J Am Soc Nephrol. 28(10):2931-2945, 2017
3. D'Agati VD et al: Obesity-related glomerulopathy: clinical and pathologic characteristics and pathogenesis. Nat Rev Nephrol. 12(8):453-71, 2016
4. Goumenos DS et al: Early histological changes in the kidney of people with morbid obesity. Nephrol Dial Transplant. 24(12):3732-8, 2009
5. Serra A et al: Renal injury in the extremely obese patients with normal renal function. Kidney Int. 73(8):947-55, 2008
6. Hsu CY et al: Body mass index and risk for end-stage renal disease. Ann Intern Med. 144(1):21-8, 2006