CMC GI Surgical Oncology Handbook

Jonathan Salo MD

Table of contents

Introduction **1**

I Inpatient Care **3**

1 CMC Inpatient **5**
1.1 Admissions 5
1.2 Rounds 5
1.3 Resident Epic teams: 5
1.4 Consults 6
1.5 Postop Clinic Appt 6
1.6 Conferences 7
1.7 Medicine Consults 7

2 Pineville Inpatient **9**
2.1 Rounds 9
2.2 Resident Epic teams: 9
2.3 Consults 9
2.4 Postop Clinic Appts 9
2.5 Conferences 10

3 Rounds **11**

4 Progress Notes **13**

5 Consults **15**

6 Ward Phone list **17**

7 Department Phone list **19**

8 Signout **21**

9 Discharges **23**

10 Education **25**
10.1 Medical Student Duty Hours 25
10.2 Procedures/Diseases 26
10.3 Ask a Resident (5min discussion) 26
10.4 Medical Student Resources 26
10.5 Recommended Resources: 26
10.6 SHELF exam 27
10.7 Entrustable Professional Activities 27

II Preoperative Care **29**

11 Preop Esophageal Ca **31**
11.1 Medical Evaluation 32
11.2 Restaging 32

12 Salo Clinic **33**
12.1 Clinic Notes 33
12.1.1 Update Problem list 34
12.1.2 Cardiac 34
12.1.3 Pulmonary 34
12.1.4 GI 35
12.1.5 Endocrine 35
12.1.6 Renal 35
12.1.7 Neurologic 35
12.1.8 Physical Exam 35
12.1.9 Assessment/Plan 35
12.2 Return Visit Notes 35
12.2.1 Summarize Recent Surgery 35
12.3 36

13 Hill Clinic **37**
13.1 Preop Colorectal Patients 37

III Operating Room **39**

14 Colorectal Cases **41**
14.1 Preop 41
14.2 Intraop 41
14.3 Postop 42

15 CV Port (IJ) **45**

16 Lap Jejunostomy **49**

17 Lap Gastrostomy **53**

18 Subtotal Gastrectomy **57**

19 Esophagectomy 1 Stage **61**
19.1 Indications 61
19.2 Preop Orders 61
19.3 Room Prep 61
19.4 Position 63
19.4.1 Time Out 64
19.5 Gastric Mobilization 64
19.5.1 Distal mobilization 65
19.5.2 Left gastric artery 65
19.5.3 Mediastinal dissection 65
19.5.4 Division of Esophagus (Four-Phase) 66
19.5.5 Entry into right chest 66

20 Esophagectomy Robot Ivor Lewis **71**
20.1 Preoperative evaluation 71
20.2 Preop Area 71
20.3 Room Prep 71
20.4 Abdominal Position 73
20.4.1 Time Out 73
20.5 Laparoscopy 74
20.6 Robotic ports 74
20.7 Abdominal Phase 75
20.7.1 Lesser Sac Dissection 75
20.8 Distal Greater Curve 75
20.9 Proximal Greater Curve 75
20.10Mediastinal dissection 76
20.11Pyloric Drainage - Pyloromyotimy (optional) 76
20.12Pyloric Drainage - Pyloroplasty (optional) 76
20.13Creation of Conduit 76
20.14Preparation of Conduit 76
20.15Prep for Thoracic Phase 76
20.16Preparation for ICG 77
20.17Jejunostomy 77
20.18Closure 77
20.19ICG injection into groin. 77

21 Thoracic Phase **79**
21.1 Transition to Lateral position 79
21.2 Prep and drape 79
21.3 Thoracic Ports 79
21.4 Thoracic Dissection 80
21.5 Delivery of Conduit into chest 80
21.6 Preparation of conduit 81
21.7 Circular stapled anastomosis - Orvil 81

21.8 Circular stapled anastomosis - Luketich 82
21.9 Linear Stapled Anastomosis 82
21.9.1 Omental Flap 82
21.9.2 NG tube 83
21.10 Drains 83
21.11 Closure 83
21.12 Postoperative care 83
21.13 References 84

22 Esophagectomy Robot/VATS 85
22.1 Preoperative evaluation 85
22.2 Preop Area 85
22.3 Room Prep 85
22.4 Abdominal Position 87
22.4.1 Time Out 87
22.5 Laparoscopy 88
22.6 Robotic ports 89
22.7 Abdominal Phase 89
22.7.1 Distal Greater Curve 89
22.8 Posterior Stomach 90
22.8.1 Lesser Sac Dissection 90
22.9 Proximal Greater Curve 90
22.10 Mediastinal dissection 90
22.11 Pyloric Drainage - Pyloromyotomy 91
22.12 Pyloric Drainage - Pyloroplasty (optional) 91
22.13 Creation of Conduit 91
22.14 Preparation for ICG 91
22.15 Final dissection of mediastinum 91
22.16 Preparation of Conduit 91
22.17 Jejunostomy 92
22.18 Drains 92
22.19 Closure 93
22.20 ICG injection into groin. 93
22.21 Thoracic Phase 93
22.22 Transition to Corkscrew Position 93
22.23 Prep and drape 93
22.23.1 Thoracoscopy 93
22.24 Thoracic Dissection 94
22.25 Delivery of Conduit into chest 94
22.26 Abdominal Exposure (optional) 94
22.27 Preparation of conduit 95
22.28 Circular stapled anastomosis - Orvil 95
22.29 NG Tube 95
22.30 Chest Tube 96
22.31 Closure 96
22.32 Postoperative care 96

IV Postop Care **99**

23 Colectomy Postop **101**

24 LAR + Ileostomy **105**

25 Abdominoperineal Resection Postop **109**

26 Gastrectomy Postop **113**
26.1 Postoperative PPI 113
26.2 Nasogastric tubes 113
26.3 Drains 113

27 Gastrostomy Feeds **115**
27.1 Free Water Flushes 115
27.2 Med Administration via G-Tubes 115

28 Jejunostomy Feedings **117**
28.1 Med Administration via J-Tubes 118
28.2 Occluded Jejunostomy Tubes 119
28.3 Jejunostomy feedings on preop Patients 119

29 Jejunostomy + Diabetes **121**

30 Esophagectomy ICU **123**

31 Esophagectomy Ward **127**
31.1 Anti-Hypertensives 127
31.2 Epidural Catheter 127
31.3 Chest tubes 128
31.3.1 Chest tube removal 128
31.4 GI Medicines 128
31.5 Evaluation for leak 128
31.5.1 Drain Amylase 129
31.5.2 CT esophagram 129
31.6 Anastomotic Leak Treatment 129
31.7 Labs 131
31.8 Discharge Medicines 131
31.9 Diet at discharge 132

V Outpatient **133**

32 Outpatient Jejunostomy Care **135**
32.1 Jejunostomy Tubes 135

33 Outpatient Esophagectomy **137**

33.1 Postop Evaluation 137
33.2 Medication Management 139
33.3 Special Cases 140
33.3.1 Weaning Tube Feeds in Diabetics 140

VI Esophageal Cancer 141

34 Esophageal Overview 143

35 EsoCa SCORE - JR 145

36 EsoCa Objectives - Chief 147

37 Staging 149

38 Barrett's Esophagus 151
38.1 Anti-reflux surgery for Barrett's esophagus 151

39 Superficial EsoCa (T1) 153
39.1 Endscopic Mucosal Resection (EMR) 153
39.2 Endoscopic submucosal dissection (ESD). 154

40 Localized EsoCa 155
40.1 T1b Tumors 155
40.2 T2N0 Tumors 155
40.3 Staging of T2N0 Tumors 156
40.3.1 PET for staging of early-stage esophageal cancer 156
40.4 Primary Surgery 156

41 Locally Advanced EsoCa 157
41.1 Trimodality Therapy 157
41.2 Neoadjuvant Chemo (adenocarcinoma) 158
41.2.1 Neoadjuvant Chemotherapy → ChemoRT 159
41.3 Postoperative chemoradiation 159
41.4 Restaging 159
41.5 Active Surveillance 159
41.6 GE Junction 160

42 Metastatic EsoCa 161
42.1 Palliative radiation 161
42.2 Chemoradiation vs chemotherapy in Stage IV 161
42.3 Stents for malignant disease 161
42.4 Perc Esophagostomy 161

43 Chemoradiation 163
43.1 Phase II Studies 163

43.2 ChemoRT vs Trimodality therapy 163
43.3 Active Surveillance 164

44 Salvage esophagectomy 165

45 Nutrition 167
45.1 Jejunostomy tubes 167
45.2 Gastrostomy tubes 167

46 Esophageal Surgery 169
46.0.1 Trans-thoracic vs Transhiatal Esophagectomy 170
46.0.2 GE Junction Adenocarcinoma 170
46.0.3 Preoperative Evaluation 170
46.1 Minimally-invasive Esophagectomy 170
46.2 Early Recovery Pathways 170
46.3 Colon Interposition 171

47 Survivorship 173
47.1 Nutritional consequences of esophagectomy 173
47.1.1 Vitamin D deficiency 173
47.2 Cardiac toxicity of radiation 173

48 Surveillance 175
48.0.1 Recurrence Profile 175

VII Gastric Cancer 177

(PART*) Gastric Cancer 179

Gastric Ca SCORE 181

49 Gastrectomy 183
49.1 Proximal gastrectomy 183

50 Hereditary Diffuse Gastric Cancer 185
50.0.1 Penetrance estimates for lifetime risk of DGC 185
50.1 Surveillance for CDH1 carriers 185

51 Gastric GIST 189
51.1 Genetics 189
51.2 Surgery 189
51.3 Positive margins after resection 190

52 Locally-Advanced Gastric 191
52.1 Preoperative Chemotherapy 191
52.2 Postoperative chemotherapy 192

52.3 Postoperative chemoradiation 192
52.4 Preoperative chemoradiation 192
52.5 Preop Immunotherapy 193

53 M1 Gastric CA **195**
53.1 Surgery for M1 disease 195
53.2 Conversion Surgery 195

VIII Colon Cancer **197**

54 Colectomy **199**
54.1 SCORE 199
54.2 Early Recovery Protocols 199
54.3 Anesthetic Management 199
54.4 Extended Node dissection 200

IX Rectal Cancer **201**

55 Rectal Cancer Staging **203**
55.1 MRI staging 203
55.2 EUS 203

56 Rectal Ca Surgery **205**
56.1 Trans-abdominal Rectal Surgery 205
56.2 Low Anterior Resection 205
56.2.1 Total Mesorectal Excision 205

57 Rectal Adjuvant Therapy **207**
57.1 Surgery ⇒ CRT 207
57.2 CRT ⇒ Surgery 207
57.3 TME 208
57.4 TME + ChemoRT 208
57.5 Short-course RT 208
57.6 Total Neoadjuvant 208
57.7 Selective Adjuvant 209
57.8 Neoadjuvant ImmunoTx 210
57.9 Neoadjuvant Chemotherapy 210

X Anal Cancer **211**

58 Anal Squamous Cell Carcinoma **213**
58.1 Chemoradiation 213
58.1.1 Restaging after chemoRT 213
58.2 Anal Intraepithelial Neoplasia 213

XI Sarcoma **215**

59 Soft Tissue Neoplasms **217**
59.1 Desmoid Tumors 217
59.2 Lipomatous Tumors 217
59.3 Retroperitoneal 217
59.3.1 Preop Radiation 217
59.4 Peritoneal mesothelioma 217

References **219**

Introduction

This handbook is designed for education and guidance of surgical trainees at Carolinas Medical Center.

Please forward corrections or suggestions to Jonathan.Salo@atriumhealth.org

Part I

Inpatient Care

Chapter 1

CMC Inpatient

Colorectal Surgery (Davis/Kasten) and GI Surgical Oncology (Hill/Salo/Squires) will cover Pineville and CMC. For efficiency, the services at each hospital will merge for patient care. Each patient will continue to have an attending surgeon, but rounding and inpatient care will be provided by the service.

1.1 Admissions

Provider group: "GI Surg Onc Attending LCI CMC"

List Attending Surgeon in addition

Patient List is CMC GI Surgical Oncology

1.2 Rounds

Attending rounds 4-5pm on Tuesday and 4-5pm on Thursday

1.3 Resident Epic teams:

- GI Surgical Oncology Colorectal LCI CMC
- Colorectal Surgery Pineville

It is critical that you notify service attendings before the start of the month to adjust the resident call schedule. Each "shift" is 5:50am to 6pm. At 6pm the resident Epic Teams will be forwarded to the night team.

Please append a text block to the bottom of each progress note specifying the Epic Team *GI Surgical Oncology Colorectal LCI CMC* for that patient to facilitate communication from nursing.

1.4 Consults

Established patients and directed should be discussed with the attending surgeon.

All new inpatient, PCL, and ER consults will be evaluated by the Red Team instead of the surgical oncology team. Established patients will be directed to either the Red Team or surgical oncology team depending on the time since surgery. Those within the three-month global period after surgery will continue to be evaluated by the surgical oncology team, while patients outside of the 90-day global period will be managed by the Red Team. This change aims to streamline patient care. All established patients will be listed on the surgical oncology list, though residents will not be responsible for management if the Red Team is primary.

1.5 Postop Clinic Appt

Postoperative patients are generally seen for a Transition of Care visit within the first week

Discharge appointments are made by sending a message in Canopy the evening prior (preferred) OR the morning of discharge before 8am to:

- LCI CMC GI, Clerical
- Kit Sluder (Salo and Squires)
- Rebecca Wicks (Hill)
- Brandon Galloway

Please include the following information in the Epic Message:

- Name of attending
- Ward from which the patient is being discharged
- Desired date for appt @ same time
- Need for bloodwork at first visit
- Other studies to be done after discharge
  - Upper GI
  - Chest X-ray
  - Modified Barium Swallow

Clinic RNs can be reached at: (Hill) 980-442-6146 or (Salo and Squires) 980-442-6143.

For patients likely to go home over the weekend or holidays, please plan to send a canopy message before 3pm on Friday or the day prior.

The scheduler will respond with a message to the discharging resident AND to the ward CNL with the appointment time, which can be included within the discharge summary. Copies of the message will also be sent to clinical nurse leaders:

- 11Tower: Sharon Hood

1.6 Conferences

- GI Tumor Planning Conf Mon 7-8am (via Teams and LCI I 3rd floor Conf Rm)
- Resident Teaching Conf Tues 7-8am 5th floor LCI II. Please review the upcoming clinic schedule and choose a case to present.
- Bone and Soft Tissue Conf Fri 7-8am (via Teams)

1.7 Medicine Consults

For medicine consults, please use "CHG Service Hospitalists CMC" for all *new* consult requests as of 11/2023 due to merging of CHG and Staff Medicine services.

Chapter 2

Pineville Inpatient

2.1 Rounds

Starting time for rounds is variable from day to day. Maddie Georgino will help organize work and timing of rounds, etc.

2.2 Resident Epic teams:

- Colorectal Surgery Pineville

Residents will be assigned to Epic teams by schedule. It is critical that you notify service attendings before the start of the month to adjust the resident Epic schedule. Each "shift" is 5:50am to 6pm. At 6pm the resident Epic Teams will be forwarded to the night team.

Please append a text block to the bottom of each progress note specifying the Epic Team for that patient to facilitate communication from nursing.

2.3 Consults

Established patients and directed should be discussed with the attending surgeon.

2.4 Postop Clinic Appts

Postoperative patients are generally seen for a Transition of Care visit at about two weeks.

Discharge appointments are made by sending a message in Canopy the evening prior (preferred) OR the morning of discharge before 8am to:

- Hale Mock
- Kamisha Wilson
- Madeline Georgino

Please include the following information in the Canopy Message:

- Name of attending
- Ward from which the patient is being discharged
- Desired date for appointment
- Need for Wound Ostomy RN appointment at same time (essential for new stomas)
- Need for bloodwork at first visit
- Other studies to be done after discharge
  - Upper GI
  - Chest X-ray

For patients likely to go home over the weekend or holidays, please plan to send a canopy message before 3pm on Friday or the day prior.

2.5 Conferences

- GI Tumor Planning Conf Monday 7-8am (Teams)
- Resident Teaching Conf 7-8am in Conference Room. Please review the upcoming clinic schedule and choose a case to present.
- Bone and Soft Tissue Conference Friday 7-8am (Teams)

Chapter 3

Rounds

The following format will help speed communication of data on rounds.

ID: One line description: "Mr Glenn: PostOp day 3 after low anterior resection"

24 hour events: Summary of important events in prior 24 hrs

Data Communication (organized by system)

Neuro: Pain control, level of alertness, psychotropic meds, sedatives, and pain meds.

CardioVascular: Vital signs (normal OR cite the range of systolic blood pressures and range of heart rate). Heart rhythm. Cardiac meds. Most recent recommendations of cardiology consult.

Respiratory: Pulmonary exam, oxygen saturation, supplied oxygen, ventilator setting. Results of CXR.

GI: Diet, bowel function, NG output. Drain outputs can often be summarized unless they are unusually high or low (and ready to be removed. New finding of bile in any abdominal drain needs special emphasis. GI meds (eg protonix, Entereg). Tube feed formula, rate and duration (continuous or nocturnal). Status of C Diff tests. Results of JP drain amylase levels (gastroesophageal patients). Results of JP triglycerides or creatinine, if sent,

Renal: Urine output in 24 hours AND in most recent 8 hour shift. Presence (or absence) of Foley catheter and plans for removal, if present. Most recent creatinine. If diuretics administered, dosage and amount of urine output during the shift when it was administered. Most recent potassium in any patient receiving (or about to receive) furosemide (Lasix). Results of Mg and Phos if abnormal.

Heme: Hemoglobin, platelets, DVT prophylaxis. PLEASE CHECK THE MAR SUMMARY DAILY to be certain that the ordered DVT prophylaxis has been

given.

ID: WBC, Tmax in past 24 hours, culture results.

Endo: Diabetic regimen, blood sugar range, and amount of sliding scale insulin administered in the prior 24 hours.

Assessment/Plan (organized by Problem List):

Each of the patients problems are addressed with an assessment and plan. Pre-existing medical problems and postoperative complications need to be addressed in the plan. An assessment and plan for each organ system is usually not necessary, except for the most complex patients. Patients active medical problems should be documented on the Patient List for rounds. This helps to remind the team about medical problems which the team is managing:

- Chronic anticoagulation
- Diabetes
- Malnutrition

This problem list-oriented approach will also be helpful to writing problem-oriented notes.

Chapter 4

Progress Notes

Progress notes need to reflect the problems which are being managed by the team. The current medical problems being managed by the team should be added to the problem list for that hospitalization. This will make it easier to generate notes which are oriented to the patient's problem list.

In addition, the progress notes provide a narrative which can later be used to generate the discharge summary (particularly for complex patients). Each day, the event of the hospitalization is carried from note to note. Each day, an additional line is added to the progress note which summarizes events for that day. This makes it possible to see within each Progress Note the pertinent events for the hospitalization. These events would include extubation, re-intubation, positive cultures, dates lines are inserted or removed, dates of removal of NG tubes and drains, and transfer to ward or re-admission to ICU. This chronology assists in treatment decisions ("how old is the IJ line" or "when did we start antibiotics?" or "when is the planned antibiotic stop date"?) but also makes the discharge summary much easier to prepare.

Notes should be forwarded to the patient's attending (unless out of town)

Esophagectomy Events to be Documented:

- Extubation date/time
- NG Removal date
- Chest tube removal date
- MBS date(s) and results (aspiration | penetration)
- ICU DC orders written
- ICU discharge (transfer to ward)

Esophagectomy Complications to be Documented:

N	Delirium
	Stroke
CV	New arrhythmia req Rx
	MI
R	Pneumonia (3 of fever | WBC | infiltrate | abx | sputum cx)
	Effusion req drainage
	Reintubation
	Atelectasis req bronchoscopy
	ARDS
	PE
	Ventilation >48 hours after leaving OR
GI	Anastomotic leak (medical rx | stent | surgery)
	Delayed gastric emptying req botox or NG >7d
	C Diff
GU	Urinary Retention
	Discharge with foley catheter
H	DVT req treatment
	Return to OR
	Return to ICU

Communication

Please add an addendum at the BOTTOM of each progress note which includes a means for contacting the team:

Please message "GI Surgical Oncology Colorectal LCI CMC via Haiku 24/7. Messages are automatically forwarded to the General Surgery Resident on Call evenings and weekends."

Chapter 5

Consults

Common Haiku Groups for Consults

Service	Haiku Group
Advanced GI (Dries/Doshi/Lewis/Chauhan)	CMC Advanced GI ERCP Consult
Advanced GI (Narang)	CDHA Advanced GI ERCP
Hospitalist	CGH Service Hospitalist CMC - Consults Only
Interventional Radiology	Eric Dodson - Haiku or 5-3599
Body Radiology	5-2270
Ultrasound	5-3600
Endocrine	CMC Endocrinology Consult Team (Kelli Dunn)
Nephrology	Metroline Neph Consult CMC
Cardiology	CMC SHVI General Cardiology
ID	CMC Infectious Disease Consults
General Surgery Red	General Surgery Red CMC floor/consults
Pulmonary	CMC Pulmonary Consult PCCC
STICU	STICU Charge for TRANSFERS
Hospital at Home	GCM HAH Nurse Navigators (referrals) CLT

Chapter 6

Ward Phone list

3B Obs	704-355-0142
3K Obs	704-446-6690
3L	704-355-8644
3T Onc	704-355-6312
4B BMT	704-446-9350
5A Overflow	704-446-5511
6A	704-355-2033
6B	705-355-6275
6T Thoracic	704-355-6260
7B	704-355-6262
7T	704-355-6210
7 Dixon Heart	704-355-2xxx
9A	704-355-6291
9B	704-355-6261
9T	704-355-6290
9 NICU	
10A	704-355-6211
10DE PROG	704-355-2022
10T	704-355-6230
10 MICU	
11A	704-446-6311
11B	704-355-6310
11T	704-446-XXXX
11 STICU	704-355-2023
KDU Dialysis	704-355-2078

Chapter 7

Department Phone list

Admitting	704-355-3071
Bed Management	704-512-6360
Code Blue	704-355-2345
ER Triage	
ER Diag	704-355-3271
ER Major	704-355-2157
ER AEC	704-355-8683
ER Holding	704-355-3276
Endoscopy	704-355-2792
Lab	704-355-9350
Language Line	704-381-8255
Preop	704-355-8922
PACU	704-355-2431
Radiology	704-355-3404
Rad CT	704-355-2270
Rad MRI	704-355-4196
Rad Ultrasound	704-355-3600
Rad IR	704-355-3430
Wound Ostomy	704-355-7605

Chapter 8

Signout

Evening Signout

The Handoff Tool should be completed for all inpatients, and the responsible attending designated. This tool is critical for the safe care of patients by the nigh team. If there are studies which are pending at the time of signout (CT scan, follow-up Hb), it is critical that a plan be in place for whom to notify with an abnormal or critical study. In general, Drs Hill, Squires, and Salo are always available until 10pm. Attending notification plans (service attending vs covering attending) for unstable patients should be negotiated before nightfall.

Weekend Signout

The senior resident is responsible for making certain that the weekend rounding resident is familiar with the patients, their problems, and the plan of care. A signout email should be prepared Friday afternoon and forwarded to the service attendings by 6pm for their review. This signout can then be edited with the attendings' notes and forwarded to the weekend rounding attending.

Chapter 9

Discharges

Discharge Prescriptions

Prescriptions should be ideally be prepared the day prior to anticipated discharge and sent to the patient's pharmacy. According to North Carolina STOP guidelines, opioid prescriptions for postoperative patients should be for no more than a 7 day supply. At the same time, patients taking narcotics in the hospital should have the same dosages for their outpatient prescription, to avoid patients running out of narcotics between the time of discharge and their first clinic visit.

Note that metoprolol is available in liquid form in the hospital, but is not available for outpatient prescription

Note that in many cases narcotics for patients living in South Carolina a prescription from an attending.

Additional Appointments

If followup appointments in additional to surgical followup are needed, these should be designated on the discharge orders. Particularly:

- Primary Care Physician
- Cardiologist (if new cardiac medicines)
- Co-surgeons (Urology, Thoracic Surgery, GYN)

Discharge Summary

The discharge summary documents important events and complications in the postoperative course and serves to inform the referring physician and primary physician about these events, but also serves as a blueprint for post-discharge treatment planning. Please recognize that the first post-operative visit may be with a resident who may be meeting the patient for the first time. Key items to include:

N	Followup plan for chronic pain management Stroke
CV	Postop Arrhythmia? | MI? | CHF? If new cardiac meds: Who is managing medications If afib: CHADS score and anticoagulation plan
R	Pneumonia? | ARDS? | TRACH? Need for home oxygen? CXR needed at first postop visit?
GI	Delayed gastric emptying? | leak? | ileus? Tube feed regimen Diet at discharge (Low residue | Full liquds | Meds with thickened water |NPO) New stoma (ileostomy | colostomy) Wound care needs (VAc | Prevena)
GU	Urinary Retention Discharge with foley catheter
H	Complications: DVT | PE Anticoagulation Plan
Endo	Insulin regimen at DC (dose will be in med rec)
ID	Antibiotics at DC Return to ICU

Communication

It is essential that discharge summaries be sent to the patient's primary MD and referring physician. Please review the initial consultation note for the names of providers involved in a patient's care.

Chapter 10

Education

The service will host Third- and Fourth-year medical students from Wake Forest University as well as externs.

Student notes should be forwarded to the patient's attending for attestation and signature.

Third year students will have a 'green card' of diagnoses and procedures which need to be checked off (and signed) during the rotation. Students: Please remind the chief resident and attendings about items which remain to be completed..

10.1 Medical Student Duty Hours

Hours:

- Students will not work longer hours than residents on the same service
- Students will not work more than 80 hours/week averaged over 4 weeks.

Breaks: Students will

- have 4 24-hour periods free from assigned activities over a 4 week period
- not work longer than 16 continuous hoours
- have a 8 hour break from clinical/academic hours following a 16-hour shift
- can only work a maximum of 5 sequential overnight shifts

Exams:

- Must be excused no later than midnight prior to the day of the shift or final exam

Holidays:

- Must be excused from responsibilities from 5pm on the day prior to the holiday on the academic calendar through the holiday[1]

10.2 Procedures/Diseases

- Wound Care (VAC/dressing change, identify infection)
- Suture/Staple removal
- Suture Skin
- Foley catheter insertion (adult)
- Insert nasogastric tube (or OG in OR)
- Make an incision, any site
- Participate in intubation, bag mask ventilation in OR
- Xray 3-way of abdomen (interpret)
- Xray chest (interpret)
- Assist with insertion of chest tube or pigtail

10.3 Ask a Resident (5min discussion)

- Abdominal Pain (RUQ)
- Acute Limb Ischemia (vascular disease)
- Diverticulitis
- Neoplastic process (Breast Mass, GI Mass, soft tissue)
- Abdominal wall mass or hernia
- ABC's of trauma, Primary/Secondary survey
- Ileus, small and large bowel obstruction
- Evaluate acute surgical abdomen (participate)
- Post-op fever in surgical inpatient (discuss and participate)
- Post-op pain management (discuss and participate)

10.4 Medical Student Resources

Subcuticular suturing video

10.5 Recommended Resources:[2]

- Essentials of general surgery, 6th edition, [edited by] Peter F. Lawrence
- Surgery: A Case Based Clinical Review (Christian de Virgilio)
- Kaplan Surgery Notes
- NMS Surgery CaseBook
- Surgical Recall (Lorne H. Blackbourne)
- UWorld QBank

[1] From Faculty as Teacher 2023
[2] from Spring 2023 Surgery Syllabus

- Aquifer / Wise-MD
- OnlineMedEd

10.6 SHELF exam

SHELF exam topic areas

10.7 Entrustable Professional Activities

1. Gather a history and perform a physical examination
2. Prioritize a differential diagnosis following a clinical encounter
3. Recommend and interpret common diagnostic and screening tests
4. Enter and discuss orders and prescriptions
5. Document a clinical encounter in the patient record
6. Provide an oral presentation of a clinical encounter
7. Form clinical questions and retrieve evidence to advance patient care
8. Give or receive a patient handover to transition care responsibility
9. Collaborate as a member of an interprofessional team
10. Recognize a patient requiring urgent or emergent care and initiate evaluation and management
11. Obtain informed consent for tests and/or procedures
12. Perform general procedures of a physician
13. Identify system failures and contribute to a culture of safety and improvement

Part II

Preoperative Care

Chapter 11

Preop Esophageal Ca

Patient who present with esophageal and GE junction diagnoses present in several manners, which determine their evaluation.

- Superficial tumors

These patients typically have Barrett's esophagus and are found to have small tumors on surveillence endoscopy. These are considered [superficial].

Workup typically involved endosopic ultrasound to determine T stage and endoscopic mucosal resection [EMR] which can be both diagnostic and therapeutic for T1 tumors.

- Tumors without dysphagia

Patients with minimal symptoms who may present with upper GI bleeding or vague symptoms but have no difficulty swallowing. Thesea are considered [early stage]. Workup typically involves PET and endoscopic ultrasound (EUS). Some patients will undergo primary surgery.

- Tumors with dysphagia

Patients with esophageal or GE junction tumors who present with dysphagia are considered [locally-advanced]. Workup involves PET scan. Most patients will undergo neoadjuvant therapy. Many will need a central venous port and some will need a feeding tube. Most need a referral for medical oncology.

- Tumors with metastatic disease

Patients who have signs of metastatic disease on CT or PET are considered [metastatic]. These patient typically need a central venous port of chemotherapy.

11.1 Medical Evaluation

11.2 Restaging

Chapter 12

Salo Clinic

12.1 Clinic Notes

In most cases, a note will already have been started, so first check under the Notes tab.

If note exists, start a new note and use the template ".lcir"

At the "HPI»" prompt, enter history of present illness:

12.1.0.1 Identifier:

- 67M presentation with iron-deficiency anemia. Usual weight 145#
- 73F presentation with 3 months of dysphagia to solids. Usual weight 181#. Weight at presentation 151#
- 44M presentation with 6 weeks of reflux symptoms. Usual weight 165#

Baseline (usual) weight is important for gastroesophageal cancer patients.

No narrative (this is not a creative writing workshop)

Avoid descriptors such as "pleasant" or "unfortunate"

12.1.0.2 Workup

> EGD April 14, 2024 by Dr Larry Pennington: Malignant appearing stricture at 40cm. Pathology (S24-345229) shows poorly-differentiated adenocarcinoma. EUS May 1, 2024 by Dr Andrew Dries. Staged as uT3 N1 PET May 15, 2024: Hypermetabolic lesion in the distal esophagus. No regional lymphadenopathy. No metastatic disease

Each paragraph contains one study: study -> date -> operator -> findings

Pathology accession number is helpful for staff to track down outside path

12.1.0.3 Consult Visit

> GI Surgical Oncology consultation June 1, 2024. Taking only liquids. No odynophagia. Hand grip strength R: 31/30/29. ECOG 0. Weight 165#. Still smoking.

12.1.0.4 ECOG performance scale

- 0 Fully active, able to carry on all activities
- 1 Ambulatory can do light house work, office work
- 2 Ambulatory but can't work up and about more than 50% of waking hours
- 3 Capable of only limited selfcare; confined to bed or chair more than 50% of waking hours
- 4 Completely disabled; cannot carry on any selfcare; totally confined to bed or chair

12.1.1 Update Problem list

Critical to update problem list for co-morbidities which would affect anesthetic/operative management.

Add details to problem list under "Overview"

12.1.2 Cardiac

- History of heart attack?
- Coronary artery stent? When? Within the last 6mo?
- Is patient on antiplatelet therapy? Which agents?
- Date and location of most recent echocardiogram
  - If aortic stenosis: Is valve area <1cm^2?
  - If pulmonary hypertension: Peak pressures?
- Date and location of stress test. Is there ischemia? Who is cardiologist?

12.1.3 Pulmonary

- Prior diagnosis of COPD? Dyspnea at rest? Dyspnea walking up one flight of stairs?
  Has patient had recent pulmonary function tests? Is patient on steroids? History of prior lung surgery?

12.1.4 GI

Prior abdominal surgery? Hernia repair: Prosthetic mesh? Laparoscopic vs open inguinal hernia repair Prior history of bariatric surgery?

12.1.5 Endocrine

If diabetes: Is insulin required? How much? Steroid use?

12.1.6 Renal

If kidney disease, what is baseline creatinine? Dialysis?

12.1.7 Neurologic

History of Stroke? History of TIA? Carotid bruit on exam? History of dementia? Who manages finances? Who makes medical decisions?

12.1.8 Physical Exam

Cardiopulmonary exam

- Carotid Bruit?
- Cervical Incision?
- Cardiac murmur
- Abdominal incisions - reconcile with past surgical history

12.1.9 Assessment/Plan

Enter assessment/plan after "A/P" prompt Do not erase blue-shaded "Assessment Plan: No problem-specific assessment/plan found for this encounter *Briefly* summarize assessment/plan Dr Salo will add A/P and rationale/evidence base

12.2 Return Visit Notes

Use notes template ".lcir" Select HPI text from prior note and use Copy Forward button

12.2.1 Summarize Recent Surgery

- Minimally-invasive esophagectomy July 2, 2024. Benign postoperative course. Discharged on 5 cartons of tube feeds and protein shakes. Pathology (CMCS24-004553): T3 N1 M0 1/26 nodes margins negative
- Postop visit July 14, 2024: Doing well. Staples out. Advance diet. Metoprolol decreased to 25mg daily x 7days-> stop.

Sign notes and forward to Dr Salo

12.3

Chapter 13

Hill Clinic

13.1 Preop Colorectal Patients

- Opiod Cessation
- Smoking Cessation
- EtOH/Drugs of Abuse – Social Work
- Nutritonal Evaluation
  - All Patients – Ensure for 3d preop
  - Poor nutrition – ?Delay surgery
- Preop Anesthesia/ERAS Class
- Expectations of Surgery:
  - Length of Stay 1-3 days
  - Diet (self-limiting)
  - Pain control (low-opoid)
  - Activity (OOB at 6am, OOB 3x/day)
- Bowel Prep – Abx and mechanical

Part III

Operating Room

Chapter 14

Colorectal Cases

14.1 Preop

ADULT SURG Colorectal ERAS MPP Hill This is what has all of the main ERAS components. Tylenol, gabapentin, Decadron, Alvimopan and heparin are all given in pre-op holding

ADULT STANDING Antimicrobial colorectal In general, I will give Ancef to patients with almost all patients with allergies to PCN. They have to remember the "severe" reaction. If it is a severe reaction, please use the second line antibiotics listed in the power plan.

Type and Screen are not typically needed for colectomy. They will have an antibody screen from office. If antibodies present, then d/w attending

Entereg for all colorectal patients (if they are not taking preoperative opoids)

VTE prophylaxix

Carbohydrate load (2 hours preop)

14.2 Intraop

Positioning: Attending will typically position patients personally

Right sided=supine; Left sided=lithotomy; All laparoscopic colon cases will have their arms tucked with a chest tape strap.

NG/OG tubes: usually not needed, unless there is gastric distension. Patients receive multiple oral medicatinos in preop.

Review anesthesia fluid management during time out. 2L max volume, urine output not an accurate indicator.

Open procedures: No Epidural

14.3 Postop

Fluids: Goal of 3 liters total in first 24 hours

Postop Day 0

- Goal-directed fluid administration
- OOB (Dangling not compliant)
- Diet
- Low Residue diet
- Ensure Supplements
- Teaching
  - Gum, Mag & Entereg
- Pain Management
  - PCA
  - Tylenol 1gm q6 ATC
  - Gabapentin 300mg TID
  - Tramadol PRN

Resume all baseline pain meds

Resume all home medications

No therapeutic anti-coagulation

Diabetes medicines - Prefer to resume all oral diabetes meds - Sliding-scale insulin ordered for all diabetics

Postop Day 1

Labs: K+ and CBC only

Heparin lock IV

Remove Foley

d/c PCA (unless open incision)

Out of bed > 6 hrs

Diet: low residue

Pain management

d/c PCA

Tylenol

Gabapentin 300 tid

Tramadol

Home meds

Oxy if lots of pain

Afternoon rounds

Check patient 2-4PM

Ambulation 2x's by PM

Patient education

Postop Day 2

- No IV fluids unless indicated
- No labs unless indicated
- OOB >6 hrs
- No PT unless going to rehab or SNF (ask Hill first)
- Pain management: same as POD#1

Discharge planning

Consider early D/C (median LOS=2d)

Otherwise plan

Patient

Nursing

Afternoon rounds

Possible home today!

Check patient 2-3PM

Ambulation 2x's by PM

Check for dehydration

Patient education

Give estimated date of discharge

Postop Day 3-5

- IVF
  - Consider bolus of IV fluids
  - Consider maintenance IV if we feel won't resolve soon
- Labs
  - No labs unless indicated
  - Consider ordering QOD Chem7 if prolonged ileus
- OOB >6 hrs
  - No PT unless likely to go to rehab or SNIF (ask Hill first)
- Pain management: Same as POD#1
- Afternoon rounds

  - Possible home today!
  - Check patient 2-3PM

Ambulation 2x's by PM

Check for dehydration

Patient education

Give estimated date of discharge

Chapter 15

CV Port (IJ)

Room Prep

- Slider bed (Skytron 3600B) with head section
- C-Arm
  - Radiology technician alerted to need for C-Arm
  - Will need lead and thyroid shields for everyone in room
- Ultrasound with hockey-stick probe near patient's RIGHT SHOULDER

Instruments - Minor instrument pan

Disposables/Meds

- Confirm choice of port with surgeon. Usual options
  - Bard PowerPort VUE with 8Fr attachable catheter (1708062)
  - Bard PowerPort slim Implanted port (for patients with low BMI)
- Heparin 5mL of 1000U/ml labeled as "1000 U/ml"
- Heparin 5mL of 1000U/ml + 45mL saline labeled as "100 U/ml"
- Local
- If general anesthesia: Marcaine 0.5% with epinephrine
- If MAC: Xylocains 1% with epinephrine
- 1000 drape x3 AND blue paper drapes 4 packs of 2 each = 8 total
- Suture
  - 3-0 Prolene RB-1 double-arm
  - 3-0 Vicryl SH
  - 4-0 Monocryl PS2

Position

- Supine with left arm tucked, right arm on armboard at side.
  - Right arm on armboard in case needed by anesthetist
  - NO shoulder roll
- Foley catheter: usually NOT required – *check with surgeon*

- Lower body Bair Hugger from abdomen to feet with ONE layer of blankets on top of Bair Hugger. Velcro strap on thighs.

Prep

Chloroprep: RIGHT chest, neck to chin and earlobe, shoulder to include deltopectoral groove.

Drape

1000 plastic drapes outline the sterile field for the port. The skin is stretched to avoid a gap between drape and skin. Allow access to the right sternocleidomastoid, right deltopectoral groove, and sternal notch. Blue paper drapes on top of 1000 drapes Transverse drape reversed head-to-foot. Ioban around edges of port field. Skin over SCM is left without Ioban to facilitate ultrasound

Preop evaluation

- Allergies
- Blood thinners or anti-platelet agents
- Hx of prior central lines or ports
- History of neck surgery

Operation

Reverse Trendelenburg

Port pocket is constructed 1cm below and parallel to clavicle 3cm long. It is essential that there is no bleeding in the pocket (to avoid a port pocket hematoma).

Trendelenburg

Ultrasound set up so that the lateral neck appears on the right side of the screen (as if looking towards the feet)

Right internal jugular vein is identified and its course cephalad-caudad marked on the skin.

Finder needle (22Ga) *OR* micropuncture kit passed into IJ. The needle should enter the vein directly beneath the ultrasound probe.

Skin anesthetized and transverse 6mm counter-incision made at needle entry site

Respiration held by anesthesia

16Ga needle passed into IJ under ultrasound. It is essential that the vein is scanned up and down by rolling the the probe to visualize the tip of the needle as it passes inferior.

J Wire passed through 16Ga needle and needle withdrawn

Anesthesia resumes respirations

Ultrasound used to confirm presence of wire within the vein by scanning up and down.

Level bed

Fluoroscopy used to confirm position of wire. Dilator and sheath inserted under fluoroscopic visualization ('live'). C-arm backed away off field.

Tunneler connected to tubing on the end with small numbers. Port collected to tubing on the opposite end. Tubing must come to rest 1mm from the body of the port. Clear plastic collar is pushed over the tubing and the edge must be flush with the body of the port. Tunneler bent into a curve to avoid injury to the carotid artery.

Catheter tunneled from port pocket to counter-incision over SCM. The tunneler path describes a gentle arc to avoid kinking the catheter. The port is moved to the top of the port pocket by traction on the catheter. Tonsil clamp placed at 25cm and fluoroscopy used to evaluate the length of the catheter, which is trimmed with a heavy scissors.

Catheter placed through dilator into central circulation. Peel-away sheath split and removed. Port accessed with straight Huber needle with 100U/ml heparinized saline. Blood is withdrawn into port. Needle is left in the port and the syringe detached.

C-arm is returned to the field to confirm catheter placement. It may be necessary to 'orbit' the C-arm if the catheter overlies the spine.

Syringe with concentrated flush (1000U/ml) is attached to the needle and the port flushed (without aspiration of blood). Syringe and needle are removed.

Port sutured to the underlying pectoralis fascia with 2 sutures of 3-0 Prolene, one forehand and one backhand. Sutures are tied and cut.

The port pocket irrigated and the incision closed with two layers of subcutaneous 3-0 Vicryl followed by subcuticular 4-0 Monocryl. The skin is dressed with Dermabond.

Postop Orders

CXR in recovery to confirm central line placement

Chapter 16

Lap Jejunostomy

Room Prep

- EGD cart near patient's LEFT SHOULDER (with ADULT EGD scope)
- If central venous port is placed at the same time:
- Slider bed (Skytron 3600B) with head section
- Radiology technician alerted to need for C-Arm
- BK Ultrasound with hockey-stick probe near patient's RIGHT SHOULDER

Instruments

- 5mm 30 degree scope AND 5mm 0 degree scope
- SRI laparoscopic Pan
- Salo laparoscopic instruments (or pan with laparoscopic needle drivers)

Disposables/Meds

- Veress needle (with 10mL syringe and saline)
- 5mm Z-thread optical port (3 on table, 2 more in room)
- Transverse drape (for port) AND laparoscopy drape
- Confirm choice of port with surgeon. Usual options
  - Bard PowerPort 8Fr xx8062
  - Bard PowerPort 8Fr xx8000 (low profile)
- Heparinized saline: 100U/ml (dilute) and 1000U/ml (concentrated)
- 1000 drape x3 AND blue paper drapes 4 packs of 2 each = 8 total
- Micropuncture kit available/not open (from Anesthesia)
- Jejunostomy tube: MIC 0201-14
- Silk 2-0 on RB-1 needle (on Surgical Oncology suture cart)

Position

- Supine with left arm tucked, right arm on armboard at side.
- Foley catheter: Usually required – *check with surgeon*

- Lower body Bair Hugger on thighs. ONE layer of blankets on top of Bair Hugger. Velcro strap on thighs. NO PILLOW UNDERNEATH LEGS.

Prep

Chloroprep (two sticks) of abdomen (need to keep pubis in field, as well as right anterior superior iliac spine), both costal margins.

If port: RIGHT chest, neck to chin and earlobe, shoulder to include deltopectoral groove

Drape

If central venous port: Perimeter of field draped with 1000 (clear adhesive) drapes. Four 1000 drapes around port site:

- Medial border: From Angle of Louis superiorly along midline to chin.
- Superior border: Inferior to jaw (to allow access to right internal jugular vein and SCM)
- Laterally: From inferior to ear down to right shoulder
- Inferior: From lateral shoulder medially to Angle of Louis

Abdomen: Two 1000 drapes used inferiorly keeping pubis and right anterior inferior iliac spine in field. This is critical as the far inferior/lateral RLQ needs to be in the field for optimal port placement.

Six Blue Paper Drapes around perimeter of field (on top of 1000 drapes)

If central venous port: Transverse sheet TURNED HEAD-TO-FOOT turned at an angle to keep deltopectoral groove and SCM within the field

Laparoscopy drape skewed to inferior and right to keep pubis and right ASIS in the field.

Turn on Bair Hugger only AFTER drapes in place

Indications

Laparoscopic jejunostomy is used for enteral nutrition in patients prior to planned (or possible) esophagectomy or gastrectomy or those for whom the stomach is otherwise not available (ie after esophagectomy or gastrectomy). Patients with metastatic esophageal cancer who need enteral access are generally treated with a gastrostomy, which does not require feeding with a pump

Preop (Resident) Preop orderset: search for "Jejunostomy"

Review Clinical Information (Resident) Review staging scans (especially PET scan) to identify suspicious areas on imaging which need to be investigated at the time of laparoscopy Outpatient anticoagulation use (warfarin, Xaralto, aspirin, Plavix) Review dietitian's recommendations (how many cans of feeding per day?) If patient is scheduled for central venous port Confirm that a port has not already been placed Prior history of central venous lines? Confirm location of port placement with surgeon (left vs right)

Operation

If a central venous port is placed, the port is performed first. See IJ Port

Abdominal access is obtained in one of two ways:

Infraumbilical approach using modified Hasson technique. If the peritoneum is not easily entered, a Veress needle is used to insufflate, followed by incision of the fascia with a 15 blade, and a 5mm optical port (Applied Medical Kii Fios First Entry Z-Thread Trocar) Veress needle inserted in LEFT upper quadrant just inferior to costal margin. Abdominal entry with 5mm optical Z-Thread port. 5mm port in right upper quadrant, 5mm port in RLQ just lateral to rectus, 5mm camera port between RUQ and RLQ ports

The transverse colon is now elevated (using the umbilical port, if used) and the ligament of Treitz is identified. The proximal bowel is arranged in a "C" configuration to confirm the proximal and distal ends of bowel.

A site for placement of the jejunostomy is selected on the skin, left lateral and just superior to the umbilicus. A site is selected on the bowel in the most proximal site on the jejunostomy selected which would allow for placement of the jejunostomy without tension, but at least 20cm from ligament of Treitz.

The proximal jejunum is sutured to the anterior abdominal wall with 2-0 silk. This is usually done with a 9 suture which is introduced into the abdomen with a needle driver "Korean Style" or "Paraguayan Style." Two cm distal to this suture, a diamond of sutures is placed around the proposed tube site, and one suture placed distal to avoid torsion. The final arrangement of sutures is one proximal and one distal and 4-6 sutures around the tube. All sutures were marked with hemostatic clips to facilitate replacement of the tube via fluoroscopy should the tube become dislodged.

Using Seldinger technique, a 14Fr Cook catheter introducer kit is placed within the jejunum, followed by a 18Fr dilator and sheath

A MIC 14Fr jejunustomy tube (0200-14) is inserted and the balloon inflated with 5mL of sterile WATER. The ballon valve is labeled for 7-10mL of water, but this risks obstruction of the jejunum.

The tube is dressed with a BioPatch and a Tagederm dressing.

The abdomen is desufflated and the port sites closed with 4-0 Monocryl, followed by Dermabond.

Endoscopy

The scope is set up:

- Suction and aspiration valves inserted and working
- Suction tubing attached Biopsy valve attached and not leaking
- Cart set up for recording by powering on the Stryker SDC digital capture box

A bite block is used and the scope lubricated. A neonatal scope may be necessary in patients with a tight stricture. Important findings to record:

- Level in cm from the incisors, of the most proximal area of Barrett's esophagus.
- Level in cm from the incisors of the GE junction Appearance of the GE junction on retroflexed view.
- Extent of invasion of the tumor into the cardia or fundus.

The scope is withdrawn and the hypopharynx suctioned. The liquid from the 'First Step' disinfectant is suctioned through the scope, followed by water.

Chapter 17

Lap Gastrostomy

Room Prep

- EGD cart near patient's LEFT SHOULDER (with NEONATAL EGD scope)
- If central venous port is placed at the same time:
  - Slider bed (Skytron 3600B) with head section
  - Radiology technician alerted to need for C-Arm
  - BK Ultrasound with hockey-stick probe near patient's RIGHT SHOULDER

Instruments

- 5mm 30 degree scope AND 5mm 0 degree scope
- SRI laparoscopic Pan (available)

Disposables/Meds

- Veress needle (with 10mL syringe and saline)
- 5mm Z-thread optical port (3 more in room)
- Transverse drape AND laparoscopy drape
- Confirm choice of port with surgeon. Usual options
  - Bard PowerPort 8Fr xx8062
  - Bard PowerPort 8Fr xx8000 (low profile)
- Heparinized saline: 100U/ml (dilute) and 1000U/ml (concentrated)
- 1000 drape x4 AND blue plastic adhesive drapes 4 packs of 2 each = 8 total
- Micropuncture kit available/not open (from Anesthesia)
- 20Fr Laparoscopic gastrostomy kit in room/not open
- 16Fr MIC gastrostomy tube in room/not open
- Gastrostomy 20Fr Pull PEG (in vending machine)
- GI Anchors ("T-fasteners") in room/not open

Endoscope Setup – Neonatal EGD scope

- Valves attached and working (suction/aspiration/biopsy cap)
- Suction tubing attached
- Connect water bottle to left-hand port
- Gauze sponges, lubricant, plastic "tray" from gauze filled with water
- **Yellow** (small) bite block
- "First step" sanitizer

Anesthesia

- ET Tube taped to left. Head turned to the left on donut
- No EKG electrodes on anterior right chest

Position

- Supine with left arm tucked, right arm on armboard at side.
- Foley catheter: usually NOT required – *check with surgeon*
- Lower body Bair Hugger on thighs. ONE layer of blankets on top of Bair Hugger. Velcro strap on thighs. NO PILLOW UNDERNEATH LEGS.

Prep

Chloroprep (two sticks) of abdomen (need to keep pubis in field, as well as right anterior superior iliac spine), both costal margins.

If port: RIGHT chest, neck to chin and earlobe, shoulder to include deltopectoral groove

Indications

Laparoscopic gastrostomy is used in patients with esophageal obstruction . Gastrostomy feedings are much easier than jejunostomy, as they can be administered via syringe or gravity bag. By contrast, jejunostomy feedings require administration via pump. Gastrostomy is usually done as an outpatient unless there are concerns for refeeding.

Review Clinical Information (Resident)

Review staging scans (especially PET scan) to identify suspicious areas on imaging which need to be investigated at the time of laparoscopy Outpatient anticoagulation use (warfarin, Xaralto, aspirin, Plavix) Review dietitian's recommendations (how many cartons per day?)

Drape

If central venous port: Perimeter of field draped with 1000 (clear adhesive) drapes. Four 1000 drapes around port site:

- Medial border: From Angle of Louis superiorly along midline to chin.
- Superior border: Inferior to jaw (to allow access to right internal jugular vein and SCM)
- Laterally: From inferior to ear down to right shoulder

- Inferior: From lateral shoulder medially to Angle of Louis

Abdomen: Blue adhesive drapes used inferiorly keeping pubis and right anterior inferior iliac spine in field. This is critical as the far inferior/lateral RLQ needs to be in the field for optimal port placement if the patient needs a jejunostomy.

Six Blue Adhesive Drapes around perimeter of field (on top of 1000 drapes)

If central venous port: Transverse sheet TURNED HEAD-TO-FOOT turned at an angle to keep deltopectoral groove and SCM within the field

Laparoscopy drape skewed to inferior and right to keep pubis and right ASIS in the field.

Turn on Bair Hugger only AFTER drapes in place

Operation

If a central venous port is placed, the port is performed first. See IJ Port

Abdominal access is obtained in one of two ways:

- Veress needle inserted in left upper quadrant just inferior to costal margin. Abdominal entry with 5mm optical port at lateral border of rectus just superior to umbilicus
- Infraumbilical approach using modified Hasson technique. If the peritoneum is not easily entered, a Veress needle is used to insufflate, followed by incision of the fascia with a 15 blade, and a 5mm optical port

The insufflation pressure is decreased to 4mmHg and the abdomen vented to drop the pressure. A 30 degree scope is passed inferior to the falciform ligament into the left upper quadrant over the lateral segment of liver. The post of the scope is positioned to the left, allowing visualization of the lesser curvature of the stomach with the end of the scope near the left aspect of the falciform.

A site for placement of the gastrostomy is selected on the skin, using a 22Ga needle as a finder. The site is marked, then infiltrated with local anesthetic and a 5mm transverse incision made.

Endoscopy is performed and the following noted:

Level in cm from the incisors, of the most proximal area of Barrett's esophagus. Level in cm from the incisors of the GE junction Appearance of the GE junction on retroflexed view. Extent of invasion of the tumor into the cardia or fundus.

A bite block is positioned (unless the patient is edentulous). The endoscope (usually a neonatal scope) is introduced into the esophagus and the video capture started. If the tumor will not allow passage of the scope, do not force the scope.

Once the scope is passed into the stomach, the fundus and duodenal bulb are suctioned.

Insufflation is then reduced to 4mm and the stomach insufflated to find the optimal location for tube placement which will minimize tension and will avoid

injury to the right gastroepiploic artery. The reduced laparoscopic insufflation pressure allows endoscopic insufflation of the stomach.

Gastrostomy tube placement is done either by Pull or Seldinger technique.

Seldinger Gastrostomy

Four T-fasteners are then used to affix the stomach to the anterior abdominal wall. These are arranged at 8:00, 10:00, 2:00, 4:00 relative to the proposed tube site. T-fasteners are not placed inferior to the tube site to avoid injury to right gastroepiploic vessels.

The J wire is then passed into the stomach, followed by the dilators, up to 20Fr. A 16Fr MIC gastrostomy tube is introduced and the balloon inflated with 7mL of *water*.

Pull Gastrostomy

A 20Fr PULL PEG tube kit is opened. The snare and tube are passed to the upper operator. The snare is passed through the scope and opened in anticipation of the passage of the wire.

The angiocath from the kit is placed into the stomach through the abdominal wall. Once the snare has grasped the angiocath, the needle is withdrawn and the split wire passed through the Angiocath into the stomach. The snare is adjusted to grasp the split wire, which is pulled out through the mouth.

The laparoscopic port site is considered clean. The PEG tube, once it is pulled through the mouth, is considered dirty. The right abdomen is covered with a towel to protect the laparoscopic site.

The recording is now stopped. The split wire is joined to the PEG tube, which is pulled into place by the abdominal operator. The tapered portion of the tube will be the first source of resistance, which may require firm traction. The split wire (and PEG tube) is dropped of the table to the patient's left.

Once the tapered portion of the tube is through the abdominal wall skin, the next point of resistance will be the bumper of the PEG tube passing through the tumor. In general, if a 5mm neonatal scope can pass the tumor, a 20Fr PEG tube can pass as well.

The tube is pulled into position and the measurement at the skin noted. The stomach is aspirated by the upper operator and insufflation is resumed at 8mmHg. Tension on the PEG tube is adjusted to allow apposition of the gastric serosa to the abdominal wall. If the tube is not easily apposed to the abdominal wall, T fasteners ("GI Anchors") must be employed.

The scope is withdrawn and the hypopharynx suctioned. The liquid from the 'First Step' disinfectant is suctioned through the scope, followed by water.

The abdomen is desufflated and the port sites closed with 4-0 Monocryl.

Chapter 18

Subtotal Gastrectomy

Room Prep

- EGD cart near patient's LEFT SHOULDER (with ADULT EGD scope)

Instruments

- 5mm 30 degree scope AND 5mm 0 degree scope
- SRI laparoscopic Pan (available)

Disposables/Meds

- Veress needle (with 10mL syringe and saline)
- 5mm Z-thread optical port
- Robot prostatectomy drape
- 1000 drape x4 AND blue plastic adhesive drapes 2 packs of 2 each = 8 total

Endoscope Setup –Adult EGD scope

- Valves attached and working (suction/aspiration/biopsy cap)
- Suction tubing attached
- Connect water bottle to left-hand port
- Gauze sponges, lubricant, plastic "tray" from gauze filled with water
- **Yellow** (small) bite block
- "First step" sanitizer
- ICG bottle reconstituted with 10ml Water (ask first)
- 25% albumin (to mix with ICG)
  - Will mix 2mL of ICG solution with 5mL of 25% albumin
  - Save remainder of ICG and keep it sterile

Position

- Supine arms abducted on arm boards
- Foley catheter

- Bovie pad
- Lower body Bair Hugger on thighs. ONE layer of blankets on top of Bair Hugger. Velcro strap on thighs. NO PILLOW UNDERNEATH LEGS.

Prep

Chloroprep of abdomen from midline at the level of the nipples to the pubis, and table to table

Review Clinical Information (Resident)

Review staging scans (especially PET scan) to identify suspicious areas on imaging which need to be investigated at the time of laparoscopy Outpatient anticoagulation use (warfarin, Xaralto, aspirin, Plavix)

Drape

Abdomen: Four Blue Adhesive Drapes around perimeter of field (on top of 1000 drapes)

3/4 sheet over thighs

Prostate Drape

Operation

Abdominal access is obtained in one of two ways:

- Veress needle inserted in left upper quadrant just inferior to costal margin. Abdominal entry with 5mm optical port at lateral border of rectus just superior to umbilicus
- Infraumbilical approach using modified Hasson technique. If the peritoneum is not easily entered, a Veress needle is used to insufflate, followed by incision of the fascia with a 15 blade, and a 5mm optical port

Ports

Location of ports (cephalad-caudad) depends upon proximal extent of tumor.

Abdominal entry in RUQ 8-9cm from midline with OptiView port. This will be upsized to 8mm robot port (#1)

Port #4 as far lateral as possible in LUQ.

Port #3 in LUQ midway between midline and Port #4

Port #2 in midline

Assisting port in LLQ: - 5mm or 12m port inferior to the midway point between Port #3 and Port #4.

Laparoscopy is performed, and biopsies taken as needed. Once it is determined that there is no peritoneal disease, port #3A is changed to a 12mm robotic stapler port.

Retraction port right mid-quadrant for flexible liver retractor held by Endosopic Bookwalter

Flexible liver retractor can be omitted in very distal lesions. Other options include suspending the lateral sector of liver with a 10cm Penrose drain or using a 0 silk on Keith needle to suspend falciform ligament and distract it to patient's right

Porta Hepatis

- Mark pylorus with cautery by making 2-3 dots 1cm proximal to the pylorus
- Dissect pylorus off porta hepatis
- Mobilize duodenum if needed

Mobilize Greater Curvature

Can be done with bipolar + monopolar scissors or Extend vessel sealer. Enter lesser sac and check for peritoneal disease posterior to stomach on the anterior surface of pancreas

Divide Duodenum

Dissection is carried out to the right of the right gastroepiploic nodal basin to divide between duodenum/pancreas and transverse mesocolon. Dissection is brought superiorly to the edge of the duodenum at the proposed site of transection. Duodenum is divided with a Blue load stapler

**EGD with ICG injection*

Once the duodenum is dissected, an injection of ICG mixed in albumin is made in the submucosal around the tumor.

Division of greater curvature

The gastrocolic omentum is dissected at this point (to allow ICG to transit to lymph nodes). This can be taken up to the inferior edge of the spleen.

Right gastroepiploic pedicle dissection

Right gastroepiploic artery dissected free and triple-clipped. Right gastroepiploic vein can be taken with vessel sealer or double-clips.

Right gastric artery

Nodes to the left of the porta hepatis (12a) are dissected and kept with the specimen. The right gastric artery is divided.

Central node dissection

The antrum is reflected to the patient's left. Nodes are dissected from the common hepatic artery (Station 8), proximal splen artery (Station 11), and celiac axis (Station 9). The coronary vein is divided with the vessel sealer. The left gastric artery is triple-clipped. Dissection is now carried out posteriorly.

The lesser curvature is cleared of lymph nodes (Stations 3) and right paracardial nodes (Station 1) taken depending upon tumor location.

Proximal division

The greater curvature is dissected proximally, typically taking several inferior short gastric vessels. The stomach is divided with several Blue loads.

Extraction and frozen section

An extraction incision is made and the specimen placed in a 12/15mm bag and removed and sent for frozen section. The extraction site can be closed or used to create with roux limb. The extraction incision is closed with two sutures of #1 Stratafix

Roux-en-Y reconstruction

The division site for jejunum is selected 25cm distal to Treitz. ICG can be injected intravenously to define the arcades. Up to two arcade vessels can be divided to yield more length of vascularlized bowel. It is important that this division of the mesentery be made central to the vasa recta. The stapler is positioned in port #3A, if it is not already. After initial division of the mesentery, the bowel is divided with a white load stapler.

A roux limb 40cm in length is measured and a jejunojejunostomy constructed with a white stapler load. Enterotomies made with a hook cautery. The bowel defect is closed with two running 3-0 Stratafix sutures on RB-1 needle.

The bare area is fenestrated to the left of the middle colic artery. The Roux limb is transposed through the mesentery to superior to the transverse mesocolon.

Gastrojejunostomy

Once the frozen section confirms a clear margin, the Roux limb is positioned posterior to the proximal gastric pouch. A gastrostomy is made on the posterior stomach at least 1cm from the staple line. An enterotomy is made on the antimesenteric border of bowel 7cm from the end of the limb. The anastomosis is made with a Blue load. The defect is closed with two sutures of 3-0 Stratafix.

NG tube

After the anastomosis, an NG tube is placed by Anesthesia and bridled.

Drains

Solitary 19Fr drain placed posterior to the anastomosis

Closure

12mm stapler site closed with 0 Vicryl in figure-of-eight fashion. Transversus abdominus place blocks placed.

Chapter 19

Esophagectomy 1 Stage

19.1 Indications

MI Ivor Lewis ("One Stage") esophagectomy is the most common approach to esophagectomy. The patient is positioned in 'corkscrew' position to allow simultaneous access to the abdomen and chest by prepping both abdomen and chest.

19.2 Preop Orders

- Type/Screen
- No subcutaneous heparin if an epidural catheter is planned

19.3 Room Prep

Double-decker Back Table

EGD Cart (check w/ Salo regarding adult vs neonatal scope)

Doppler box with foot pedal

BK Ultrasound (with laparoscopic probe)

Walter 'Long Arm' retractor

Salo Positioning Cart:

- Four black side-rail clamps
- Four rectangular lateral positioners
- Yassargil socket
- Well-leg holder (used as an arm holder)

Harmonic Scalpel generator box

Critical supplies (chek prior to pt in room)

- Stapler 25mm DSTXL
- Orvil 25mm
- Stapler 21mm DSTXL
- Orvil 21mm
- Echelon 60mm stapler with 10 gold loads and 2 gray loads
- Gel Port

Anesthesia

- Dual-lumen ETT tube (**taped to left**)
- Arterial line (left arm will be on arm board)
- Anesthesia will usually place epidural catheter either in preop or in OR

19.4 Position

Supine on blue foam pad. No pillow under knees. Keep siderails clear by tucking drawsheet into gap between rails.

Mark upper midline with skin marker

Foley catheter (with Criticor temp sensor)

Bovie pad

Lower-body Bair Hugger at level of thighs

Hair clipped from abdomen, right chest, and right axilla.

Pre-existing jejunostomy

- Prep into field
- Remove any eschar at site
- Secure to skin inferiorly with 0 silk

Shoulders are shifted to the right in preparation for 'corkscrew' positioning

Lateral positioners positioned with pad extending from greater trochanter inferiorly.

Velcro strap over thighs and over lateral positioners

Yassargil socket attached to headpiece of bed on left side.

Well-leg holder attached to Yassargil socket and used to support right forearm (which will cross body). Right arm crosses body and is supported on well-leg holder.

Lateral positioner placed posterior to spine and scapula to support right chest, allowing access for thoracoscopy.

Arm holder is dropped towards the floor enough that right arm is brought forward.

Prep

Chloroprep (two sticks) of abdomen, right chest, right axilla. Particular attention to prepping as far as possible to the left lateral side and the right lateral side. Nipple prepped into field.

Drape

Proximal right arm draped with 1000 (clear adhesive) drape.

Two blue plastic "U" drapes with center of the "U" on either lateral side with tails forming the perimeter of the field Trauma drape. All of right chest and axilla is kept within the field, as is the lateral aspect of the left upper quadrant. The field does not need to extend inferior to the umbilicus. In general, it is usually possible to keep all of these area in the field without cutting the drape, except in very large patients. Ioban strips (4") aound the periphery of the surgical field after the trauma drape. Laparoscopic cords (gas, light cord, camera) to tower at left shoulder. Suction irrigator brought off field. Laparoscopic LigaSure (2 bars) and Bovie (30/30).

19.4.1 Time Out

Operation header on consent

Tumor location and likelihood of division of esophagus from abdomen (two-phase operation) vs division of esophagus from chest (four-phage operation).

Blood:

- Surgeon's expectation of blood loss
- Availability of blood (type/screen vs type/cross).

Comorbidities:

Cardiopulmonary disease. If echo, ejection fraction and aortic valve area (if abnormal)

Beta blockage: Note whether patient on home beta blockade and if so, whether home medication was taken the morning of surgery.

Anticipated Intraop Problems:

- Possibility of tension left pneumothorax due to carbon dioxide entry into left chest during mediastinal dissection
- Expectation of ventilatory difficulties due to carbon dioxide entry into the right chest Gastric mobilization – Greater Curvature

19.5 Gastric Mobilization

7cm upper midline incision for handport. Incision is centered over pylorus. GelPort inserted, and abdomen insufflated to 15mmHg. Two 5mm ports placed LUQ. Medial LUQ 5mm port placed in angle between left costal margin and superior edge of GelPort ring. Lateral LUQ 5mm port placed as far lateral as possible. Depending upon visualization, a third port may be required between these two and somewhat more inferior.

If feasible, division of gastrocolic omentum starts by delivering transverse colon into GelPort and dividing ligament with cautery and LigaSure in the avascular

plane just cephalad to transverse colon. Dissection proceeds as far proximal and distal and feasible. It is important to avoid damage to the right gastroepiploic artery.

Colon is returned to abdomen and gastricolic ligament divided going using LigaSure, taking care to avoid the colon and the right gastroepiploic artery. For patients with a bulky omentum, it may be helpful to place an additional port in the left mid-quadrant for the camera to facilitate dissection of omentum off the transverse colon. Stomach is retracted to the patient's right with the back of the left hand, placing the gastrocolic ligament (and short gastric arteries) on stretch. Left gastroepippoic artery divided with LigaSure near its origin. Short gastric arteries divided with Ligasure close to spleen. As superior aspect of short gastrics is reached, the dissection plane shifts medially to create a tunnel towards the base of the left crus. This places the most superior short gastric vessels on stretch and facilitates their division. Once all short gastric vessels divided, peritoneum tethering fundus to diaphragm is incised, and fundus brushed medially.

19.5.1 Distal mobilization

Attention is directed to mobilizing the lateral aspect of the duodenum. This can either be accomplished with the camera through a LUQ port and a 45 degree camera or by placing an additional 5mm port in the RLQ. Hook cautery is used to incise the connective tissue lateral and posterior to the duodenum. The gastrocolic ligament is now dissected distally, taking care to preserve the integrity of the right gastroepiploic vessels. An areolar plane generally exists between the fat pad containing the right gastroepiploic vessels and that containing the transverse mesocolon vessels.

19.5.2 Left gastric artery

Lymph nodes around the celiac axis and left gastric artery are now dissected. The extend of dissection depends upon the tumor location and the presence of nodes her either based upon imaging or palpation. Dissection begins on the superior edge of the pancreas, and proceeds superiorly to the right crus. The left gastric (coronary) vein is usually located to the left of the arery and is divided with the LigaSure. In a two-phase approach, the left gastric artery is now divided with a 30mm gray load (2.0mm) Echelon linear stapler. For patients with mid-esophageal tumors, (for whom a four-phase approach is used), if there is any question about the resectability of the tumor, division of the left gastric gastric artery is generally deferred until the second abdominal phase.

19.5.3 Mediastinal dissection

The esophagus is now dissected circumferentially at the gastroesophageal junction. The peritoneum overlying the diaphragm is incised, and circumferential dissection of esopahgus performed. On the left side, it is helpful to distract the left crus laterally with a Prestige clamp placed on the left crus The right pleura is widely

entered in otder to both facilitate the thoracic dissection of the esophagus and placing the conduit into the right chest in preparation for the final thoracic phase. Division of Esophagus (Two-Phase only) In a four-phase approach, the esophagus is divided from the right chest during the first (of two) thoracic phases. In a two-phase approach, the esophagus is divided from the abdomen by reaching up into the mediastinum to divide the esophagus above the tumor. This is only feasible for tumors of the gastroesophageal junction. In a two-phase approach, the esophagus is divided with a 60mm Medium-Thich (Gold) Echelon TriStaple stapler.

19.5.4 Division of Esophagus (Four-Phase)

Penrose Drain (Four-Phase only) In a four-phase approach, the esophagus is divided from the chest. In order to facilitate the thoracic dissection, a 1/4 penrose drain is tied around the distal esophagus and the drain is slid cephalad into the mediastinum. The 'tails' of the drain are directed into the right chest so that they can be grasped from the right chest during the thoracic phase and can be used to provide traction on the esophagus

19.5.5 Entry into right chest

The pneumoperitoneum in the abdomen is vented and the gas pressure turned down to 8mmHg in preparation for the thoracic phase. The bed is rotated to the left 20 degrees. A site for entry in to the left chest is selected just posterior to the tip of the scapula. An incision is made here and a 5mm optical port with a 5mm 0 degree scope used to enter the chest. The chest is insufflated at 8mmHg of carbon dioxide, which helps to both copllapase the lung and depress the diaphragm. Two 12mm ports are placed. The more superior is placed lateral and superior to the nipple. The inferior port is placed just lateral to the diaphragmatic reflection. It is ciritcal to avoid injury to the diaphragm (and liver) with the inferior port placement. A mini-thoracotomy incision is placed along the mid-axillary line, frequently in the same interspace as the inferior/anterior 12mm port. The chest is entered just superior to the rib and the intercostal muscles divided with the LigaSure device to allow the ribs to separate. A narrow Deaver retractor is used to guage the space between the ribs, as the width of the retractor approximates the diameter of the 25mm stapler. A 5mm 'U' port is generally placed as high as possible midway between the scapular tip port and the anterior/superior 12mm port t0o the 4 right 5

Division of Esophagus (Two-Phase) In patients with low-lying tumors, it is possible to divide the esophagus above the tumor from the abdominal approach. This evaluation is facilitated by review of the properative endoscopy (and EUS), and the PET scan, particularly the PET obtained prior to neoadjuvant chemoradiation.

After dissection of the mediastinum, a Echelon stapler with a 60mm Medium-Thick (Gold) load is inserted through a 12mm port either placed either through

the GelPort or by upsizing the most lateral LUQ

Construction of Conduit The distal esophagus and stomach is exteriorized through the GelPort. The lesser curvature vessels are divided with the LigaSure 7-9cm cephalad from the pylorus. The stomach is now placed on stretch along the greater curvature. An Echelon Medium-Thick (Gold) stapler is used to construct a 5-6cm wide gastric tube. In constructing the conduit in a patient with a tumor of the GE jnction invading into the cardia, it is important to be certain that the staple line to construct the conduit stays clear of the tumor. Patients with tumors invading the cardia are at risk of a positive distal margin, meaning that microscopic tumor may be left in the wall of the gastric conduit. To make things more complicated, in patients with low-lying esophageal or GE junction tumors, not all of the length of the conduit are needed in order to reach to the level of the esophageal transection. After construction of the anastomosis, the 'extra' cephalad portion of the conduit (near the angle of His) are excised as the 'additional gastric margin.' In order to distinguish which portions of the conduit staple line which will be used to replace the esophagus and those which will be included in the 'additional gastric margin', both sides of the gastric conduit staple line are marked with sutures designated 'A', 'B', 'C', etc proceeding from the Angle of His to the antrum.

The distal esophagus and GE junction are now sent for frozen section.

Feeding jejunostomy The ligament of Trietz is identified and the jejunum is identified 20cm distal and marked with a directional suture. A site is selected to the left of the handport incision. A 16Fr Cook Introducer Kit is used to pass a 16Ga needle, followed by a J wire, through the left rectus muscle. A skin incision 4mm in length is made adjacent to the J wire. The 16Fr dilator and sheath are now passed through the rectus muscle and the dilator and wire removed. A 14Fr Jejunostomy Tube 0301-14 is selected and the 'wings' trimmed off with a scalpel. The jejunostomy tube is passed through the peelaway sheath, which is removed.

A pursestring suture 1.5cm in diameter is placed on the antimesenteric border of the jejunum. The pursestring is started and ends on the lateral aspect. A second 16Fr Cook Introduced Kit is used to introduce the J wire through the center of the pursestring.

Placement of Drains Two (or three) 19Fr full-fluted Blake drains (72230) are placed:

JP1: placed into the left pleura through the hiatus. Drain is brought out through the most lateral 5mm port site on the LUQ JP2: placed into the right pleura through the hiatus. Drain is brought out through the next most medial 5mm LUQ port site JP3: (optional) placed in the abdomen posterior to the left lateral segment of the liver and brought out through the most medial 5mm LUQ port site Transposition of Conduit The gastric conduit is now placed into the right pleura through the mediastinum, with the assistance of a laparoscopic Babcock and gentle pressure on the greater curvature with the fingers.

Entrance into the R chest (Two Phase) For two-phase operations, ports are now placed into the right chest, as stated above . In similar fashion, the inferior pulmonary ligament in dissected and the lung reflected anterior.

Anastomosis The right chest is entered and the right lung reflected anterior with the paddle placed in the superior/anterior port. The gastric conduit is placed into the mediastinum by tucking it medially from the right pleura into the posterior mediastinum, in order to allow the conduit to take the most direct path from the hiatus to the proximal esophagus. Gentle superior tension is now applied to the conduit in order to eliminate redundancy. The paddle retractor is now moved from the anterior/inferior port to the anterior/superior 12mm port and the lung reflected anterior and inferior.

OrVil The OrVil device is now used to place a EEA anvil into the distal esophagus. In general, a 25mm size is selected, unless the patient has particularly small frame, in which case a 21mm size is used. Two stay sutures of 2-0 silk on RB-1 needles are placed in the center of the esophageal staple line 3mm apart. A Harmonic scalpel is used to divide the staple line. The OrVil device is passed through the mouth and is passed through the fenestration in the staple line. The anvil portion of the OrVil is oriented so that the rounded portion is placed against the roof of the mouth. The OrVil is guided into the hypopharynx by pulling on the the tube end of the device. As the anvil approaches the hypopharynx, the jaw is pulled forward to allow passage of the anvil.

The shaft of the anvil is brought through the esophageal staple line, and the tube disconnected from the anvil by cutting the blue sutures.

The superior end of the conduit is opened along the staple line and the DST XL stapler (matching the diameter of the OrVil) introduced through the Alexis device. The stapler shaft is placed into the open end of the gastric conduit and the conduit pulled over it ('sock over shoe'). The stapler spike is brought out through the greater curvature. The anvil is grasped with a Maryland grasper placed through a superior 5mm port and the two components of the stapler are mated and the stapler tightened and fired. The knob of the stapler is rotated two turns counter-clockwise until a click is felt, at which time the anvil will flip. The stapler is withdrawn and the donuts examined and sent for pathologic exam.

The anastomosis is completed by firing a Echelon Medium-Thick (Gold) linear) across the conduit cephalad to the anastomosis. The excess conduit is sent for pathologic exam as 'additional gastric margin.'

NG Tube A Covidien Salem Sump 18Fr nasogastric tube is passed by the anesthetist. A laparoscopic BK ultrasound is used to monitor the passage of the NG tube through the esophagus and into the gastric conduit. The NG tube is passed to the level that all for dots are outside the nose, with the 4th dot at the nares. The NG tube is secured with an AMT bridle.

Chest Tube A 28Fr Blake chest tube is placed through the anterior/inferior 12mm port and is positioned into the posterior mediastinum. JP2 is placed near

the gastric conduit. The right lung is re-inflated.

Closure The stapler access port incision is closed with 0 Vicryl to approximate the serratus muscle. The incisions are closed with 4-0 Monocryl followed by Dermabond.

Chapter 20

Esophagectomy Robot Ivor Lewis

20.1 Preoperative evaluation

PET scan evaluted for extent of tumor, focusing on proximity to the carina.

CT scan evaluated for presence of replaced left hepatic artery.

20.2 Preop Area

Heparin is held if epidural catheter is planned

Clip hair from abdomen and right chest, including right axilla. Hair is clipped to base of pubis.

20.3 Room Prep

Double-decker Back Table

EGD Cart (check w/ Salo regarding adult vs neonatal scope)

BK Ultrasound (with robotic probe AND either hockey stick or small T probe). Will need sterile ultrasound jelly.

Walter 'Long Arm' retractor

Bean Bag

Salo Positioning Cart:

- Four black side-rail clamps

- Four rectangular lateral positioners
- Yassargil socket
- Well-leg holder (used as an arm holder)

Critical supplies (check prior to pt in room)

- Stapler 25mm DSTXL
- Orvil 25mm
- Stapler 21mm DSTXL
- Orvil 21mm

Anesthesia

- Dual-lumen ETT tube (taped to left)
- Arterial line (left arm will be on arm board)
- Anesthesia may place epidural in preop

20.4 Abdominal Position

Supine on blue foam pad.

Foley catheter (with Criticor temp sensor)

Bovie pad

Lower-body Bair Hugger at level of thighs, followed by single blanket and Velcro strap

Hair clipped from abdomen, right chest, and right axilla.

Pre-existing jejunostomy

- Prep into field
- Remove any eschar at site
- Secure to skin inferiorly with 0 silk

Velcro strap over thighs and over lateral positioners

Prep

Patient is positioned frog-leg for prep (and is returned to supine during draping). Chloroprep (2 sticks) of abdomen and lower chest up to the level of nipples (in case urgent chest tube needed). Particular attention to prepping as far as possible to the left lateral side and the right lateral side. Prep continues inferior to base of pubis. At the end of prep, bilateral groins are prepped.

Drape

Transverse 1000 drape is placed at the base of the pubis. On either side, the drape proceeds inferior and lateral to include both groins. Top gloves are changed.

Blue utility (paper) drape is placed transversely just above level of pubis. While the abdominal skin incisions are being closed,

1000 Drapes x4 in rectangular fashion with top of field 10cm above xiphoid and bottom at base of penis. Ioban strips (4") aound the periphery of the surgical field after the trauma drape. Laparoscopic cords (gas, light cord, camera) passed off. Suction irrigator brought off field.

20.4.1 Time Out

Operation header on consent

Time Out

Review:

- Consent
- Comorbidities, including cardiopulmonary disease
- Anticoagulation plan. If preoperative heparin was held for epidural, plans for timing of its administration. Circulator and anesthetist set alarms.
- Prior abdominal or thoracic operations
- Allergies
- Blood
  - Surgeon's expectation of blood loss
  - Availability of blood (type/screen vs type/cross).
  - Blood product administration limitations, if any
- Introduction by name and role
- Co-surgeons: Confirm availability prior to incision
- Operative plan
- Request ICU bed in STICU

Comorbidities:

Cardiopulmonary disease. If echo, ejection fraction and aortic valve area (if abnormal)

Beta blockage: Note whether patient on home beta blockade and if so, whether home medication was taken the morning of surgery.

Anticipated Intraop Problems:

- Possibility of tension left pneumothorax due to carbon dioxide entry into left chest during mediastinal dissection
- Expectation of ventilatory difficulties due to carbon dioxide entry into the right chest Gastric mobilization – Greater Curvature

20.5 Laparoscopy

Pneumoperitoneum established with Veress needle at left subcostal or inferior to umbilicus *or* modified Hasson approach. Abdominal entry with 5mm optical port at future location of Port #2 in mid-axillary line at level of umbilicus. Laparoscopy to look for peritoneal implants.

20.6 Robotic ports

Port #3 8mm left mid-axillary line 3cm above level of umbilicus → camera.

hook | monopolar scissors | Extend vessel sealer.

Port #4 left anterior axillary line. 8mm port →

Port #2 right mid-clavicular line. Switch from 5mm to 12mm robotic stapler port. Place 'sleeper' 0 Vicryl figure-of-eight suture and secure with a hemostat.

Port #1 left anterior axillary line 8mm port → fenestrated bipolar

Assistant port 8mm port inferior to umbilicus. Port #3 will be switched to this position for jejunostomy later in the case.

Nathanson liver retractor placed in midline using the 5mm optical port to create a tract. Nathanson held in place with Salo Endoscopic Bookwalter secured to bedrail just inferior to right armboard.

20.7 Abdominal Phase

20.7.1 Lesser Sac Dissection

Gastrohpeatic ligament divided. Celiac axis evaluated for resectability. Right crus dissected to ensure resectability. Dissection carried anteriorly and left crural dissection begun. Dissection posterior to esophagus.

Central node dissection begun, including common hepatic, left gastric, celiac, and proximal splenic aftery nodes. If replaced left hepatic artery present, may require preservation of left gastric artery. Left gastric artery divided with clips.

Posterior gastric dissection. Dissection is carried posterior towards most superior short gastric arteries (as these can be difficult to approach from the greater curvature side).

20.8 Distal Greater Curve

The right gastroepiploic artery is identified and the lesser sac entere to the left of midline. Dissection proceeds to the patient's right. This may require shifting ports:

- Camera to Port 2
- Vessel sealer to Port 3
- Tip Up to Port 4

Right gastroepiploic artery carefully preserved and gatrocolic omentum incised. Dissection proceeds to right to mobilize colon off duodenum. Kocher maneuver performed and omental adhesions to gallbladder taken down.

20.9 Proximal Greater Curve

Instruments are returned to original positions and dissection proceeds proximally, preserving the left gastroepiploic artery near its orgin. Posterior dissection from the pancreas and splenic artery is performed, followed by division of short gastric vessels

20.10 Mediastinal dissection

Penrose drain is placed around esophagus and secured with stapler or Weck clips. Dissection proceeds to level of inferior pulmonary veins. Penrose is tucked into the mediastinum.

When Penrose is placed, confirm that heparin has been given.

20.11 Pyloric Drainage - Pyloromyotimy (optional)

Pyloromyotomy is performed with camera in Port #2 and hook in Port #3 and Tip up in Port #4 (may need to move camera to midline)

20.12 Pyloric Drainage - Pyloroplasty (optional)

Stay sutures of 2-0 silk are placed cephalad and caudad to pyorus. Pyloric incision is made with hook cautery. Defect is closed with 2-0 silk cut to 6" (have 2 sutures ready)

20.13 Creation of Conduit

"Ruler" is created by making 1cm marks with black marker on Tip up. Tip up grasper place into Port #4. Robotic stapler is introduced into Port 2. Staple line starts ~5cm from pylorus. First firing with Green (4.8mm) stapler load followed by Blue loads. Conduit is created with goal of 3-4cm. Assistant retracts fundus towards left upper quadrant. Vicryl suture is placed 2cm above the start of the staple line (approximately 7cm from pylorus).

20.14 Preparation of Conduit

Camera is moved to Port #2. Suture cut needle driver is introduced into Port 3 and Tip Up into Port 4. Conduit is sutured to specimen with multiple sutures of 2-0 silk (cut to 6"). Arm 4 is undocked and 19 Fr Blake drain is introduced through the port. The drain is sutured to specimen with 2-0 silk cut to 4". JP2 is brought out through the LLQ 5mm assistant port or through the port for Arm #4.

20.15 Prep for Thoracic Phase

Once conduit has been constructed, confirm presence in room of bean bag, two pillows, and an extra OR bed for transition to lateral decubitus position.

20.16 Preparation for ICG

One vial of ICG is resuspended with 10mL of water. 5mL of the solution is brought onto the sterile field in a 5mL syringe, which is fitted with a 25Ga needle. The remainder of the ICG is given to Anesthesia for later (intravenous) use.

20.17 Jejunostomy

Camera is moved to midline (or Port 2) and Tip up into Port 3. Camera re-oriented to 30 degrees up. Ligament of Treitz is identified and site for jejunostomy marked at 30cm with marking pen on a Prestige with 1 dot for selected site and 2 transverse marks distally. 3-0 Stratafix on RB-1 is introduced with a non-cutting needle driver into Port 3. Insufflation pressre reduced to Jejunum is sutured to abdominal wall starting at 10:00. Pursestring is run to 2:00 position and 16Ga needle from a 14Fr Cook Introducer kit passed through the abdominal wall into the bowel. Insufflation of air confirms proper position. J wire and 14FR dilator introduced and left in place. Pursestring continues around proposed site and then proceeds cephalad to provide a broader area of fixation between bowel and abdominal wall. Tract is dilated with 18Fr dilator. 14Fr MIC jejunostomy (trimmed to 10cm) is introduced through 18Fr sheath and positioned within the bowel. 5mL of water in a slip-tip (non-Luer) 10ml syringe (from the Cook introducer kit) are instilled into the jejunostomy balloon.

20.18 Closure

Robot is disengaged and kept sterile. Laparoscopic cords are placed in a basin on a ring stand to be reused for the thoracic portion.

Abdomen is desufflated and ports removed. Port #2 site is closed by tying 0 Vicryl suture. Port sites are closed with 4-0 Monocryl followed by Dermabond.

20.19 ICG injection into groin.

While port sites are being closed, “loincloth” is removed and hockey stick or small T ultrasound transducer is brought onto the field. Under ultrasound guidance with sterile ultrasound jelly, ICG is injected into groin nodes.

Chapter 21

Thoracic Phase

21.1 Transition to Lateral position

Patient is transferred to a spare OR table and a bean bag placed. Patient is positioned lateral with tip of scapula at break in the table. Pillows are used under and between the knees. Arm is supported on a Well Leg Holder affixed to the left headrail with a Yassargil clamp. Lateral positioners used on patient's left side to stabilize bean bag and allow tilt to the left (into modified prone position).

Lower and upper body bair hugger used. Right arm is elevated for prep and lowered once drapes in place.

21.2 Prep and drape

Chloroprep including axilla and proximal right arm. Drape axilla/upper arm with 1000 drape.

Two blue "U" drapes used, folowed by trauma drape (or Universal). Ioban strips around edges. Once Ioban in place, arm is lowered

Laparoscopic instruments are kept sterile and may be returned to the field if pleural adhesions are encountered.

21.3 Thoracic Ports

- Arm #4 4th ICS 1cm medial to scapula
- Arm #3 6th IS more medial than 4th arm and close to posterior axillary line. Camera Port.
- Arm #2 8th ICS 12mm port for Vessel sealer or stapler

- Arm #1 10th ICS on the scapular line or posterior on 10th ICS A1 Assitant 9th ICS triangulated beween 1 and 2. Alexis port used for extraction incision A2 Assistant 5th ICS.

DaVinci docking with "Anatomy: Renal" "Patient Right" Target on azygous vein

21.4 Thoracic Dissection

1. Dissect plane between lung and anterior aspect of esophagus. Start dissection at the pericardium and proceed cephalad. Once the area of the right mainstem bronchus is approached, keep plane more superficial.
2. Dissect onto pericardium. Confirm that tumor will comes off pericardium. Leave pulmonary vein dissection to later. Counter traction with suction.
3. Dissection over parietal pleura up to azygous arch superficially. Dissect lower aspect of the azygous vein.
4. Superficial dissection superior to azygous vein to reach superior extent of dissection at inferior border of sygous svein, then proceed inferiorly along the posterior aspect of the esophagus. Dissection proceeds to hiatus.
5. Divide azygous vein with either vascular load stapler or Gray load
6. Dissection proceeds to hiatus
7. Divide thoracic duct with Hem-O-Lock clips at least 5cm superior to hiatus.
8. Return to dissection plane anterior to the esophagus and deepen plane. Leave dissection of Station 7 nodes until esophagus is completely freed up. Can switch instruments in Arm 1 and Arm 2.
9. Dissection of Station 4R nodes.
10. Dissection of subcarinal (Station 7) nodes. Start by dissecting esophagus from trachea, then outline inferior border of right and left mainstem bronchi. Keep Station 7 lymph nodes on the specimen.

21.5 Delivery of Conduit into chest

The conduit is delivered into the thorax. This is done using a laparoscopic graster. Ensure staple line faces you (right side). The specimen is removed through the assistant port incision. An Alexis port is used to seal the extraction site. Stomach is pulled into the chest until the **Vicryl marker suture** is seen.

Division of esophagus just above level of azygous vein. ICG can be used to check perfusion. If there is any question about the length of the conduit, confirm the length of the conduit prior to division of the esophagus.

Penrose drain is recovered. Specimen is sent for frozen section with instructions to freeze proximal margin.

Once conduit is delivered into chest, set up BK ultrasound to display on robotic screen.

21.6 Preparation of conduit

The gastric conduit is placed into the mediastinum by tucking it medially from the right pleura into the posterior mediastinum, in order to allow the conduit to take the most direct path from the hiatus to the proximal esophagus. Gentle superior tension is now applied to the conduit in order to eliminate redundancy.

21.7 Circular stapled anastomosis - Orvil

OrVil The OrVil device is now used to place a EEA anvil into the distal esophagus. In general, a 25mm size is selected, unless the patient has particularly small frame, in which case a 21mm size is used. Two stay sutures of 2-0 silk on RB-1 needles are placed in the center of the esophageal staple line 3mm apart. A Harmonic scalpel is used to divide the staple line. The OrVil device is passed through the mouth and is passed through the fenestration in the staple line. The anvil portion of the OrVil is oriented so that the rounded portion is placed against the roof of the mouth. The OrVil is guided into the hypopharynx by pulling on the the tube end of the device. As the anvil approaches the hypopharynx, the jaw is pulled forward to allow passage of the anvil.

The shaft of the anvil is brought through the esophageal staple line, and the tube disconnected from the anvil by cutting the blue sutures.

The superior end of the conduit is opened along the staple line and the DST XL stapler (matching the diameter of the OrVil) introduced through the Alexis device (Port #2). The stapler shaft is placed into the open end of the gastric conduit and the conduit pulled over it ('sock over shoe'). The stapler spike is brought out through the greater curvature. The anvil is grasped with a Maryland grasper placed through a superior 5mm port and the two components of the stapler are mated and the stapler tightened and fired. The knob of the stapler is rotated two turns counter-clockwise until a click is felt, at which time the anvil will flip. The stapler is withdrawn and the donuts examined and sent for pathologic exam.

The anastomosis is completed by firing a 60mm Blue load across the conduit cephalad to the anastomosis. The excess conduit is retrieved through the Alexis port and sent for pathologic exam as 'additional gastric margin.'

21.8 Circular stapled anastomosis - Luketich

May be helpful to move camera back to Port #3 to see anastomosis better. May need to remove Port #1 for better visibility cephalad.

Esophagus divided with robotic shears.

Pursestring suture of 0 Prolene SH to depth of 3-5mm. Two robotic arms used to stretch esophagus laterally → anvil introduced into esophagus with large needle driver → pushed superiorly → oriented cephalad-caudad. Pursestring tied. Second pursestring of 0 Prolene placed inside of first.

DST XL 28mm EEA stapler introduced through port #2 (???) into open end of conduit → mated and fired. Anastomosis completed with linear stapler. Distance between anatomosis and final linear staple line should be 2cm.

21.9 Linear Stapled Anastomosis

The esophageal stump is opened on the (right side) within the middle with cold scissors or monopolar cautery hook just proximal to the transecting stapler line

The site for linear stapler insertion is measured to be at least 6 cm distal to the transecting staple line on the gastric conduit. The incision is made using monopolar cautery close to the gastroepiploic arcade

Four retraction sutures are placed (dorsal, ventral, medial and lateral) around the opened esophageal lumen, making sure to fixate the mucosa to the rest of the esophageal wall. These retraction sutures will serve for applying optimal retraction on the stump for anastomotic suturing as well as help guide the esophageal stump over the stapler anvil.

The robotic stapler anvil and cartridge jaw (45mm? 60mm? length) are inserted into the appropriate lumens while the console surgeon guides the tissue onto the stapler. Once sufficient tissue overlap is achieved (approximately 60 mm) the stapler is fired (blue reload) and the gastric conduit and esophageal stump are connected dorsally side-to-side

34Fr gastric tube (?or Bougie) inserted. Anterior wall closed with two 4-0 Stratafix sutures run from each side toward the middle. Second later with 4-0 PDS

21.9.1 Omental Flap

Omental flap is positioned between the conduit and airway and the anastomosis is loosely wrapped.

21.9.2 NG tube

NG (Salem Sump silicone 18Fr tube) is passed by anesthetist. Robotic ultrasound used to confirm location. NG tube is advanced to 4th dot just about to enter the nose.

21.10 Drains

38Fr Chest tube (Blake or Hollow-bore) placed. 19Fr Blake (JP2) postioned posterior to anastomosis.

21.11 Closure

Extraction site closed with 0 Vicryl. Chest tube secured with 0 silk on SH needle. Skin incisions closed with 4-0 Monocyrl and Dermabond

Grimminger PP, Hadzijusufovic E, Lang H: Robotic-Assisted Ivor Lewis Esophagectomy (RAMIE) with a Standardized Intrathoracic Circular End-to-side Stapled Anastomosis and a Team of Two (Surgeon and Assistant Only). Thorac Cardiovasc Surg 66:404406, 2018

van der Sluis Ann Surg Oncol22 Supp3:S1350-6 - ICG for RGEA

21.12 Postoperative care

Admission to ICU. Epidural dosed.

Medications:

- Protonix 40mg IV
- Metoprolol 2.5mg IV q6h (may increase to 5mg)
- Home antihypertensives held unless bp is still elevated after adequate beta blockade
- No bowel regimen
- Reglan 10mg IV q6 hours

Labs:

- Daily drain amylase from JP2 starting POD#2
- CBC every other day or daily if elevated above 12
- BMP every other day
- CMP on admission and POD #4

Tube feeds at 30mL/hour start with Osmolite 1.5. Tube feeds advanced 10mL q12 hours once flatus returns.

Intravenous fluid stopped once tube feeds advanced and free water started 240mL qid via jejunostomy.

POD #1 Out of bed to chair

Chest tube to water seal on POD2 if no air leak. Chest tube removed once output below 200mL/day

JP2 removed by POD#7 if patient is otherwise doing well.

Upper GI POD#2 *AND* able to stand for 10min *AND* output less than 400mL/day. If good emptying on upper GI → NG removed.

Modified Barium Swallow once NG tube removed. Initiation of liquids dependent upon MBS.

POD #5 Epidural catheter removed if not done prior. Foley catheter removed once epidural out. No Flomax to be administered vai jejunostomy

21.13 References

Chapter 22

Esophagectomy Robot/VATS

22.1 Preoperative evaluation

PET scan evaluated for extent of tumor, focusing on proximity to the carina.

CT scan evaluated for presence of replaced left hepatic artery.

22.2 Preop Area

- Heparin is held if epidural catheter is planned
- Type/Screen
- Clip hair from abdomen and right chest, including right axilla. Hair is clipped from bilateral groins

22.3 Room Prep

- Double-decker Back Table
- EGD Cart (check w/ Salo regarding adult vs neonatal scope)
- BK Ultrasound with sterile ultrasound jelly
  - Laparoscopic probe AND
  - hockey stick probe AND
  - robotic probe

Walter 'Long Arm' retractor

Salo Positioning Cart:

- Three black side-rail clamps

- Two rectangular lateral positioners
- One round lateral positioner
- Yassargil socket
- Well-leg holder (used as an arm holder)

Robotic Instruments:

- Tip Up Grasper
- Fenestrated bipolar Forceps (420205)
- Hot Shears (Monopolar scissors) 470179
- Extend vessel sealer (480322)
- SutureCut Large Needle Driver (470296)
- Medium-Large Clip Applier (420327)
- Large Needle Driver (470006)
- Permanent Cautery Hook (470183) (hold)
- Cadiere Forceps (470049) hold

Critical supplies (check prior to pt in room)

- Stapler 25mm DSTXL
- Orvil 25mm
- Stapler 21mm DSTXL
- Orvil 21mm

Suture

- Stratafix Spiral PDS 3-0 RB-1 needle 15cm

Supplies:

- Micropuncture kit (from Anesthesia Workroom)
- Gel Port available
- 14Fr Balloon Jejunostomy tube (8200-14)
- 14Fr Cook introducer kit
- 18Fr Dilator and peelaway sheath

Anesthesia

- Epidural placed in preop area
- Dual-lumen ETT tube (taped to left)
- Arterial line (left arm will be on arm board)
- Heparin 5000U SQ 1-2 hours after epidural placed

22.4 Abdominal Position

Supine on blue foam pad

Foley catheter

Bovie pad

Lower-body Bair Hugger at level of thighs, followed by single blanket and Velcro strap

Hair clipped from abdomen, bilateral groins, right chest, and right axilla.

Pre-existing jejunostomy

- Prep into field
- Remove any eschar at exit site
- Secure to skin inferiorly with 0 silk

Prep

Chloroprep (2 sticks) of abdomen and lower chest up to the level of nipples (in case urgent chest tube needed). Particular attention to prepping as far as possible to the left lateral side and the right lateral side. Prep continues inferior to base of pubis. At the end of prep, bilateral groins are prepped.

Drape

Transverse 1000 drape is placed at the base of the pubis. On either side, the drape proceeds inferior and lateral to include both groins. Legs are returned to supine position and Velcro strap placed at thighs. Top gloves are changed.

Blue utility (paper) drape is placed transversely just above level of pubis. While the abdominal skin incisions are being closed, ICG will be injected into bilateral groins.

1000 Drapes x4 in rectangular fashion with top of field 10cm above xiphoid and bottom at base of penis. Ioban strips (4") aound the periphery of the surgical field after the trauma drape. Laparoscopic cords (CO2, light cord, camera) passed off. Suction irrigator brought off field.

22.4.1 Time Out

Review:

- Consent
- Comorbidities, including cardiopulmonary disease
- Anticoagulation plan. If preoperative heparin was held for epidural, plans for timing of its administration. Circulator and anesthetist set alarms.
- Prior abdominal or thoracic operations
- Allergies
- Blood
  - Surgeon's expectation of blood loss
  - Availability of blood (type/screen vs type/cross).
  - Blood product administration limitations, if any
- Introduction by name and role
- Co-surgeons: Confirm availability prior to incision
- Operative plan
- Request ICU bed in STICU

Comorbidities:

Cardiopulmonary disease. If echo, ejection fraction and aortic valve area (if abnormal)

Beta blockade: Note whether patient on home beta blockade and if so, whether home medication was taken the morning of surgery.

Anticipated Intraop Problems:

- Possibility of tension left pneumothorax due to carbon dioxide entry into left chest during mediastinal dissection
- Expectation of ventilatory difficulties due to carbon dioxide entry into the right chest

22.5 Laparoscopy

Pneumoperitoneum established with Veress needle at left subcostal or inferior to umbilicus *or* modified Hasson approach. Abdominal entry with 5mm optical port at future location of Port #2 in mid-clavicular line superior to umbilicus. Laparoscopy to look for peritoneal implants.

Ports:

1) Z-thread optical port at site for Port #1 in R mid-axillary line 5cm superior to umbilicus
2) RLQ assisting port (5mm)
3) Lower midline assisting port (later will become Port 2A)
4) LLQ assisting port (5mm)

Site for jejunostomy is selected 25cm from Treitz. 9" 2-0 silk suture is placed on anti-mesenteric aspect of jejunum and tied to itself. Abdominal wall site for jejunostomy is selected to be superior to ports 3 and 4. Site is marked with skin marker

Falciform suspended with 0 silk suture on Keith needle

Once site for jejunostomy marked, will placed ports 2,3,4. Port 4 is lateral at level of umbilicus. Port #3 is somewhat more inferior, to allow sewing jejunostomy. Port #2 in midline, inferior enough to allow

22.6 Robotic ports

Port #1 left anterior axillary line 8mm port 2cm above umbilicus. → fenestrated bipolar

5mm asstant ports RLQ and LLQ

Assistant port 8mm port inferior to umbilicus. Port #3 will be switched to this position for jejunostomy later in the case.

(locate future site for jejunostomy)

Port #3 8mm left mid-axillary line at level of umbilicus → camera.

Port #4 left anterior axillary line. 8mm port → Tip Up

Port #2 right mid-clavicular line 2cm above umbilicus. Switch from 5mm to 12mm robotic stapler port. Place 'sleeper' 0 Vicryl figure-of-eight suture and secure with a hemostat.

(suspend falciform with 0 silk on Keith needle)

Nathanson liver retractor placed in midline using the 5mm optical port to create a tract. Nathanson held in place with Endoscopic Bookwalter secured to bedrail just inferior to right armboard.

Place loop of 0 silk to suspend superior side of pylorus

Bed positioned to 12 degrees reverse Trendelenberg and tipped to right 10 degrees

22.7 Abdominal Phase

Robot docked: Anatomy: UPPER ABDOMINAL. Position: PATIENT RIGHT

Arm 1	Arm 2	Arm 3	Arm 4
Fenestrated Bipolar	Camera	Synchroseal OR Vessel Sealer	Tip Up

22.7.1 Distal Greater Curve

The course of the right gastroepiploic artery is identified and the lesser sac entered to the left of midline. Dissection proceeds to the patient's right. Right

gastroepiploic artery carefully preserved and gatrocolic omentum incised. Dissection proceeds to right to mobilize colon off duodenum. Kocher maneuver performed and omental adhesions to gallbladder taken down.

22.8 Posterior Stomach

Posterior dissection elevating stomach. Divide posterior gastric arteries. Dissection plane up to fundus and to short gastrics.

22.8.1 Lesser Sac Dissection

Gastrohpeatic ligament divided. Right gastric artery divided at 3rd arcade (approx 5cm from pylorus). Celiac axis evaluated for resectability. Right crus dissected to ensure resectability. Dissection carried anteriorly and left crural dissection begun. Dissection posterior to esophagus.

Penrose can be looped around body of stomach and used to retract stomach off central lymph nodes by traction to LLQ port site.

Central node dissection begun, including common hepatic, left gastric, celiac, and proximal splenic artery nodes. If replaced left hepatic artery present, may require preservation of left gastric artery. Left gastric artery divided with clips.

Posterior gastric dissection. Dissection is carried posterior towards most superior short gastric arteries (as these can be difficult to approach from the greater curvature side). (Penrose drain can be placed at this part of the operation)

22.9 Proximal Greater Curve

Arm 1	Arm 2	Arm 3	Arm 4
Tip Up	Fenestrated Bipolar	Camera	Synchroseal Vessel Sealer

Dissection proceeds proximally, dividing the left gastroepiploic artery near its orgin. Posterior dissection from the pancreas and splenic artery is performed, followed by division of short gastric vessels

22.10 Mediastinal dissection

Penrose drain is placed around esophagus and secured with Weck clips. Dissection proceeds to level of inferior pulmonary veins. Penrose is tucked into the mediastinum. When Penrose is placed, confirm that heparin has been given.

22.11 Pyloric Drainage - Pyloromyotomy

Stay sutures are placed superior and inferior with 2-0 Silk. The cephalad suture is looped with the prior loop of 0 silk placed at the Nathanson site

Arm 1	Arm 2	Arm 3	Arm 4
Fenestrated Bipolar	Camera	Scissors OR Cadiere	Tip Up

Pyloromyotomy is performed with camera in Port #2 and scissors in Port #3 and Tip up in Port #4 (may need to move camera to midline)

22.12 Pyloric Drainage - Pyloroplasty (optional)

Pyloric incision is made with scossors or hook cauterh. Defect is closed with 2-0 silk cut to 6" (have 2 sutures ready)

22.13 Creation of Conduit

Tip up grasper placed into Port #4. Robotic stapler is introduced into Port 1. Staple line starts ~5cm from pylorus. First firing with Green (4.8mm) stapler load followed by Blue loads. Conduit is created with goal of 4cm. Assistant retracts cut edge of specimen towards right upper quadrant. Vicryl suture is placed 2cm above the start of the staple line (approximately 7cm from pylorus).

22.14 Preparation for ICG

One vial of ICG is resuspended with 10mL of water. 5mL of the solution is brought onto the sterile field in a 5mL syringe, which is fitted with a 25Ga needle. The remainder of the ICG is given to Anesthesia for later (intravenous) use.

22.15 Final dissection of mediastinum

Once conduit has been disconnected from specimen, additional dissection of mediastinum cam be performed. A penrose drain is tied around the esopahgus. Once this is finished the penrose drain is pushed up into the mediastinum with the tails to the patient's right.

22.16 Preparation of Conduit

Arm 1	Arm 2A	Arm 3	Arm 4
Fenestrated Bipolar	Camera	**SutureCut Large Needle Driver**	Tip Up

If there is entry into the left pleaura, JP1 (19Fr) is brought in through LLQ 5mm port. This is frequently not necessary. Tip Up retracts left crus laterally and drain is placed in left pleura. All of the fluted portion is placed into the chest. The dot is left at the hiatus.

Conduit is sutured to specimen with multiple sutures of 2-0 silk (cut to 6”). After conduit is sutured, arm 4 is removed and JP2 brought in through that port. JP2 is now sutured to the specimen.

Conduit is now evaluated with ICG and with robotic ultrasound

22.17 Jejunostomy

Arm 1	Arm 2	Arm 2A	Arm 3
Fenestrated Bipolar	Camera (30 up)	**SutureCut Large Needle Driver**	Tip Up

Prior suture on jejunum is identified and grasped with suture passer at the pre-marked site. Two passes are made with the suture passer similar to transfascial sutures on a Stoppa hernia repair. The 22Ga needle from a **micropuncture kit** is introduced through the pre-marked site to extend 1cm into the abdominal cavity. 3-0 Stratafix on RB-1 is introduced with a non-cutting needle driver into Port 3. Insufflation pressure reduced to 8m Hg. Jejunum is sutured to abdominal wall starting at 10:00. Pursestring is run to 2:00 position and the J wire from the micropuncture kit threaded into the small bowel. Correct placement within the bowel lumen is confirmed by rapid insufflation of air through the needle. The micropuncture dilator is next used, followed by the J wire from a 14Fr Cook introducer kit. The tract is dilate with a 14FR dilator followed by 18Fr dilator introduced and left in place. Pursestring continues around proposed site and then proceeds cephalad to provide a broader area of fixation between bowel and abdominal wall. Tract is dilated with 18Fr dilator. 14Fr MIC jejunostomy 8200-14 (trimmed to 10cm) is introduced through 18Fr sheath and positioned within the bowel. 5mL of water in a slip-tip (non-Luer) 10ml syringe (from the Cook introducer kit) are instilled into the jejunostomy balloon.

22.18 Drains

Once jejunostomy in place, JP1 and JP2 are routed lateral to jejunostomy and brought out through Port #4 and the LLQ assisting port. Enough slack is left

on JP2 so that its outside length approximates that of JP1.

22.19 Closure

Robot is disengaged. Laparoscopic cords are placed in a basin on a ring stand to be reused for the thoracic portion.

Abdomen is desufflated and ports removed. Port #2 site is closed by tying 0 Vicryl suture. Port sites are closed with staples. A Red Rubber Robinson catheter (or 8Fr feeding tube) is placed through the Nathanson subxiphoid access site and covered with a Tegaderm. The RRR is used in case it is necessary to observe the transposition of the conduit from the abdomen.

22.20 ICG injection into groin.

While port sites are being closed, "loincloth" is removed and hockey stick or small T ultrasound transducer is brought onto the field. Under ultrasound guidance with sterile ultrasound jelly, ICG is injected into groin nodes.

22.21 Thoracic Phase

22.22 Transition to Corkscrew Position

Patient's chest is rotated to the left. Rectangular positioner supports scapula. Circular positioner on Left side supports chest. Rectangular positioner along left greater trochanter. Right arm rests on pink foam pad on Well Leg Holder. Lower and upper body bair hugger used. Right arm is elevated for prep and lowered once drapes in place.

22.23 Prep and drape

Chloroprep including axilla and proximal right arm. Prep should include all of abdomen. Drape axilla/upper arm with 1000 drape.

Two blue "U" drapes used, folowed by trauma drape (or Universal). JP drains are draped out of the abdominal field but ports 1,2,2A, AND 3 are prepped into teh field. Ioban strips around edges. Once Ioban in place, right arm is lowered

Laparoscopic instruments are kept sterile and may be returned to the field if pleural adhesions are encountered.

22.23.1 Thoracoscopy

Table is tipped 10-15 degrees to the left. Gas pressure turned down to 8mmHg in preparation for the thoracic phase. A site for entry in to the left chest is

selected just posterior to the tip of the scapula OR lateral to nipple. An incision is made here and a 5mm optical port with a 5mm 0 degree scope used to enter the chest. The chest is insufflated at 8mmHg of carbon dioxide, which helps to both copllapase the lung and depress the diaphragm. One 12mm port is placed just lateral to the diaphragmatic reflection. It is ciritcal to avoid injury to the diaphragm (and liver) with the inferior port placement. A mini-thoracotomy incision is placed along the mid-axillary line, frequently in the same interspace as the inferior/anterior 12mm port. The chest is entered just superior to the rib and the intercostal muscles divided with the LigaSure device to allow the ribs to separate. A narrow Deaver retractor is used to guage the space between the ribs, as the width of the retractor approximates the diameter of the 25mm stapler. A 5mm 'U' port is generally placed as high as possible midway between the scapular tip port and the anterior/superior 12mm port t0o the 4 right 5

22.24 Thoracic Dissection

The 1688 "Green" scope is used to identify the course of the thoracic duct. If a disruption is found, the duct is mass ligated as low as possible with 3-0 Stratafix on RB-1 needle.

22.25 Delivery of Conduit into chest

The conduit is delivered into the thorax. This is done using a laparoscopic grasper. Ensure staple line faces you (right side). The specimen is removed through the assistant port incision. Stomach is pulled into the chest until the **Vicryl marker suture** is seen.

Division of esophagus just above level of azygous vein. ICG can be administered intravenously to check perfusion. If there is any question about the length of the conduit, confirm the length of the conduit prior to division of the esophagus.

Penrose drain is recovered. Specimen is sent for frozen section with instructions to freeze proximal margin.

22.26 Abdominal Exposure (optional)

If needed to monitor passage of conduit into chest, the abdomen is insufflated using the RRR placed in the sub-xiphoid port. Ports #1, #2, #3 are re-opened and Nathanson retractor replaced. Robotic camera used to monitor passage of conduit into chest.

22.27 Preparation of conduit

The gastric conduit is placed into the mediastinum by tucking it medially from the right pleura into the posterior mediastinum, in order to allow the conduit to take the most direct path from the hiatus to the proximal esophagus. Gentle superior tension is now applied to the conduit in order to eliminate redundancy.

22.28 Circular stapled anastomosis - Orvil

OrVil The OrVil device is now used to place a EEA anvil into the distal esophagus. In general, a 25mm size is selected, unless the patient has particularly small frame, in which case a 21mm size is used. Two stay sutures of 2-0 silk on RB-1 needles are placed in the center of the esophageal staple line 3mm apart. A Harmonic scalpel is used to divide the staple line. The OrVil device is passed through the mouth and is passed through the fenestration in the staple line. The anvil portion of the OrVil is oriented so that the rounded portion is placed against the roof of the mouth. The OrVil is guided into the hypopharynx by pulling on the the tube end of the device. As the anvil approaches the hypopharynx, the jaw is pulled forward to allow passage of the anvil.

The shaft of the anvil is brought through the esophageal staple line, and the tube disconnected from the anvil by cutting the blue sutures.

The superior end of the conduit is opened along the staple line and the DST XL stapler (matching the diameter of the OrVil) introduced through the Alexis device (Port #2). The stapler shaft is placed into the open end of the gastric conduit and the conduit pulled over it ('sock over shoe'). The stapler spike is brought out through the greater curvature. The anvil is grasped with a Maryland grasper placed through a superior 5mm port and the two components of the stapler are mated and the stapler tightened and fired. The knob of the stapler is rotated two turns counter-clockwise until a click is felt, at which time the anvil will flip. The stapler is withdrawn and the donuts examined and sent for pathologic exam.

The anastomosis is completed by firing a 60mm Gold load across the conduit cephalad to the anastomosis. The excess conduit is retrieved through the Alexis port and sent for pathologic exam as 'additional gastric margin.'

22.29 NG Tube

A Covidien Salem Sump 18Fr nasogastric tube is passed by the anesthetist. A laparoscopic BK ultrasound is used to monitor the passage of the NG tube through the esophagus and into the gastric conduit. The NG tube is passed to the level that all for dots are outside the nose, with the 4th dot at the nares. The NG tube is secured with an AMT bridle.

22.30 Chest Tube

A 28Fr Blake chest tube is placed through the anterior/inferior 12mm port and is positioned into the posterior mediastinum. JP2 is placed near the gastric conduit. The right lung is re-inflated.

22.31 Closure

The stapler access port incision is closed with 0 Vicryl to approximate the serratus muscle. The incisions are closed with 4-0 Monocryl followed by Dermabond.

22.32 Postoperative care

Admission to ICU. Epidural dosed.

Medications:

- Protonix 40mg IV daily
- Metoprolol 2.5mg IV q6h (may increase to 5mg)
- Home antihypertensives held unless bp is still elevated after adequate beta blockade
- No bowel regimen
- Reglan 10mg IV q6 hours

Labs:

- Daily drain amylase from JP2 starting POD#2
- CBC every other day or daily if elevated above 12
- BMP every other day
- CMP on admission and POD #4

Tube feeds at 30mL/hour start with Osmolite 1.5. Tube feeds advanced 10mL q12 hours once flatus returns.

Intravenous fluid stopped once tube feeds advanced and free water started 240mL qid via jejunostomy.

POD #1 Out of bed to chair

Chest tube to water seal on POD2 if no air leak. Chest tube removed once output below 200mL/day

JP2 removed by POD#7 if patient is otherwise doing well.

Upper GI POD#2 *AND* able to stand for 10min *AND* output less than 400mL/day. If good emptying on upper GI → NG removed.

Modified Barium Swallow once NG tube removed. Initiation of liquids dependent upon MBS.

POD #5 Epidural catheter removed if not done prior. Foley catheter removed once epidural out. No Flomax to be administered via jejunostomy

Part IV

Postop Care

Chapter 23

Colectomy Postop

Clinic

- Opiod Cessation
- Smoking Cessation
- EtOH/Drugs of Abuse – Social Work
- Nutritonal Evaluation
  - All Patients – Ensure for 3d preop
  - Poor nutrition – ?Delay surgery
- Preop Anesthesia/ERAS Class
- Expectations of Surgery:
  - Length of Stay 1-3 days
  - Diet (self-limiting)
  - Pain control (low-opoid)
  - Activity (OOB at 6am, OOB 3x/day)
- Bowel Prep – Abx and mechanical

Preop Holding

- Colon PowerPlan (Hill)
- Antibiotic PowerPlan
- No PCN only for severe allergy
- Entereg (if no preop opiods)
- VTE prophylaxis
- Carbohydrate load (2hr preop)

OR

- Goal-directed fluid administration
- 2L total in OR
- 3L total/first 24hrs
- Open procedures: No epidural

Postop Day 0

- Goal-directed fluid administration
- OOB (Dangling not compliant)
- Diet
  - Low Residue diet
  - Ensure Supplements
- Teaching
- Gum, Mag & Entereg
- Pain Management
  - PCA
  - Tylenol 1gm q6 ATC
  - Gabapentin 300mg TID
  - Tramadol PRN
  - Resume all baseline pain meds
- Home Medications
  - Resume all home medications (write on postop 0 so it can be administered morning of POD1)
  - No therapeutic anti-coagiation
  - Diabetes medicines
    - Prefer to resume all oral diabetes meds
    - Sliding-scale insulin ordered for all diabetics

Postop Day 1

- Labs: K+ and CBC only
- Heparin lock IV
- Remove Foley
- d/c PCA (unless open incision)
- Out of bed > 6 hrs
- Diet: low residue
- Pain management
  1) d/c PCA
  2) Tylenol
  3) Gabapentin 300 tid
  4) Tramadol
  5) Home meds
  6) Oxy if lots of pain
- Afternoon rounds

1) Check patient 2-4PM
2) Ambulation 2x's by PM
3) Patient education

Postop Day 2

- No IV fluids unless indicated
- No labs unless indicated
- OOB >6 hrs

- No PT unless going to rehab or SNF (ask Hill first)
- Pain management
  - Same as POD#1
- Discharge planning
  - Consider early D/C (median LOS=2d)
- Otherwise plan
  - Patient
  - Nursing
- Afternoon rounds

1) Possible home today!
2) Check patient 2-3PM
3) Ambulation 2x's by PM
4) Check for dehydration
5) Patient education
6) Give estimated date of discharge

Postop Day 3-5

- IVF
  - Consider bolus of IV fluids
  - Consider maintenance IV if we feel won't resolve soon
- Labs
  - No labs unless indicated
  - Consider ordering QOD Chem7 if prolonged ileus
  - OOB >6 hrs
  - No PT unless likely to go to rehab or SNIF (ask Hill first)
- Pain management
  - Same as POD#1
- Afternoon rounds
  1) Possible home today!
  2) Check patient 2-3PM
  3) Ambulation 2x's by PM
  4) Check for dehydration
  5) Patient education
  6) Give estimated date of discharge

Chapter 24

LAR + Ileostomy

Clinic

- Opiod Cessation
- Smoking Cessation
- EtOH/Drugs of Abuse – Social Work
- Nutritional Evaluation
  - All Patients – Ensure for 3d preop
  - Poor nutrition – ?Delay surgery
- *Arrange Wound Ostomy Nursing*
- *Pre-approval for Home Health*
- Preop Anesthesia/ERAS Class
- Expectations of Surgery:
  - Length of Stay 1-3 days
  - Diet (self-limiting)
  - Pain control (low-opoid)
  - Activity (OOB at 6am, OOB 3x/day)
- Bowel Prep – Abx and mechanical

Preop Holding

- Colon PowerPlan (Hill)
- *CCM order*
- *WOCN order*
- Antibiotic PowerPlan
- No PCN only for severe allergy
- Entereg (if no preop opiods)
- VTE prophylaxis
- Carbohydrate load (2hr preop)
- Confirm stoma marking
- Confirm CCM aware of ostomy

OR

- Goal-directed fluid administration
  - 2L total in OR
  - 3L total/first 24hrs
- Open procedures: No epidural

Postop Day 0

- Goal-directed fluid administration
- OOB (Dangling not compliant)
- Diet
  - Low Residue diet
  - Ensure Supplements
- Teaching
- Gum, Mag & Entereg
- Pain Management
  - PCA
  - Tylenol 1gm q6 ATC
  - Gabapentin 300mg TID
  - Oxycodone once at night
  - Tramadol PRN
  - Resume all baseline pain meds
- Home Medications
  - Resume all home medications
  - No therapeutic anti-coagiation
  - Diabetes medicines
    - Prefer to resume all
    - Sliding-scale insulin if needed
- *Wound Ostomy teaching*
- *CCM for Home Health for stoma care*

Postop Day 1

- Labs: K+ and CBC only
- d/c "pre" plan & colon visit
- Heparin lock IV
- Remove Foley
- d/c PCA (unless laparotomy)
- Out of bed > 6 hrs
- Diet: low residue
- Pain management
  1) d/c PCA
  2) Tylenol
  3) Gabapentin 300 tid
  4) Tramadol
  5) Home meds
  6) Oxy if lots of pain

- Discharge planning

1) Possible home today!(25% will go home POD1)
2) Check patient 2-3PM

- Afternoon rounds

1) Possible home today!
2) Check patient 2-4PM
3) Ambulation 2x's by PM
4) Patient education

Postop Day 2

- No IV fluids unless indicated
- No labs unless indicated
- OOB >6 hrs
- No PT unless going to rehab or SNF (ask Hill first)
- Pain management
  - Same as POD#1
- *Wound Ostomy Teaching*
- Discharge planning
  - Consider early D/C (median LOS=2d)
- Otherwise plan
  - Patient
  - Nursing
  - *CCM for home health for stoma care*
- Afternoon rounds

1) Possible home today!
2) Check patient 2-3PM
3) Ambulation 2x's by PM
4) Check for dehydration
5) Patient education
6) Give estimated date of discharge

Postop Day 3-5 - IVF - Consider bolus of IV fluids - Consider maintenance IV if we feel won't resolve soon - Labs - No labs unless indicated - Consider ordering QOD Chem7 if prolonged ileus - OOB >6 hrs - No PT unless likely to go to rehab or SNIF (ask Hill first) - Pain management - Same as POD#1 - Afternoon rounds 1) Possible home today! 2) Check patient 2-3PM 3) Ambulation 2x's by PM 4) Check for dehydration 5) Patient education 6) Give estimated date of discharge

Chapter 25

Abdominoperineal Resection Postop

Clinic

- Opiod Cessation
- Smoking Cessation
- EtOH/Drugs of Abuse – Social Work
- Nutritional Evaluation
  - All Patients – Ensure for 3d preop
  - Poor nutrition – ?Delay surgery
- *Arrange Wound Ostomy Nursing*
- *Pre-approval for Home Health*
- Preop Anesthesia/ERAS Class
- Expectations of Surgery:
  - Length of Stay 1-3 days
  - Diet (self-limiting)
  - Pain control (low-opoid)
  - Activity (OOB at 6am, OOB 3x/day)
- Bowel Prep – Abx and mechanical

Preop Holding

- Colon PowerPlan (Hill)
- *CCM order*
- *WOCN order*
- Antibiotic PowerPlan
- No PCN only for severe allergy
- Entereg (if no preop opiods)
- VTE prophylaxis
- Carbohydrate load (2hr preop)

- Confirm stoma marking
- Confirm CCM aware of ostomy

OR

- Goal-directed fluid administration
  - 2L total in OR
  - 3L total/first 24hrs
- Open procedures: No epidural

Postop Day 0

- No sitting
  - Order Sign over bed "No sitting"
- Goal-directed fluid administration
- OOB (Dangling not compliant)
- Diet
  - Low Residue diet
  - Ensure Supplements
- Teaching
- Gum, Mag & Entereg
- Pain Management
  - PCA
  - Tylenol 1gm q6 ATC
  - Gabapentin 300mg TID
  - Oxycodone once at night
  - Tramadol PRN
  - Resume all baseline pain meds
- Home Medications
  - Resume all home medications
  - No therapeutic anti-coagiation
  - Diabetes medicines
    - Prefer to resume all
    - Sliding-scale insulin if needed
- *Wound Ostomy teaching*
- *CCM for Home Health for stoma care*

Postop Day 1

- Labs: K+ and CBC only
- d/c "pre" plan & colon visit
- Heparin lock IV
- Out of bed > 6 hrs
- Diet: low residue
- Pain management
  1) d/c PCA
  2) Tylenol
  3) Gabapentin 300 tid
  4) Tramadol

5) Home meds
6) Oxy if lots of pain

Postop Day 2

- No IV fluids unless indicated
- No labs unless indicated
- OOB >6 hrs
- No PT unless going to rehab or SNF (ask Hill first)
- Pain management
  - d/c PCA (unless laparotomy)
- *Wound Ostomy Teaching*
- Foley voiding challenge
  - 250mL saline into foley -> pull
  - Must void within 2 hours
- Discharge planning
  - Consider early D/C
- Otherwise plan
  - Patient
  - Nursing
  - *CCM for home health for stoma care*
- Afternoon rounds

1) Possible home today!
2) Check patient 2-3PM
3) Ambulation 2x's by PM
4) Check for dehydration
5) Patient education
6) Give estimated date of discharge

Postop Day 3-5 - IVF - Consider bolus of IV fluids - Consider maintenance IV if we feel won't resolve soon - Labs - No labs unless indicated - Consider ordering QOD Chem7 if prolonged ileus - OOB >6 hrs - No PT unless likely to go to rehab or SNIF (ask Hill first) - Pain management - Same as POD#1 - Afternoon rounds 1) Possible home today! 2) Check patient 2-3PM 3) Ambulation 2x's by PM 4) Check for dehydration 5) Patient education 6) Give estimated date of discharge

Chapter 26

Gastrectomy Postop

26.1 Postoperative PPI

Proton-pump inhibitors have been shown to reduce risk of marginal ulceration but also are associated with increased risk of delayed gastric emptying after pancreaticoduodenectomy and gastric bypass.

There is a limited evidence base for duration of PPIs after gastrectomy. The American Society for Metabolic and Bariatric surgery (Edwards et al. 2025) recommends at least 90 days of PPIs. A retrospective study found lower rate of marginal ulcer with 90 days of PPI after gastric bypass compared with 30 days.

26.2 Nasogastric tubes

The duration of nasogastric tubes will be determined by the attending surgeon, operation performed, and NG output. Experience with advanced recovery protocols would suggest that prolonged nasogastric tube drainage is not only unnecessary but may slow recovery.

For Dr Salo's patients, an upper GI is generally performed on postoperative day 2 using Isovue through the nasogastric tube. The patient stands upright and gastric emptying is evaluated

26.3 Drains

Drain amylase is monitored daily starting on the second day after surgery.

Chapter 27

Gastrostomy Feeds

Gastrostomy feeds are generally given via bolus feeds 3-4 times per day. Tube feed goal is usually 1 to 1.5 cartons at a time (4-6 cartons total). For patients at risk of refeeding, tube feeds are started at one half carton qid. The amount per feed can be increased over the next few days to goal.

Patients with severe reflux may require gastrostomy feeds via infusion pump, but this is much less common. Patients with gastrostomy feeds DO NOT routinely need an infusion pump initially.

Osmolite 1.5 is generally used as an initial formula. Glucerna is formulated with carbohydrates with low glycemic index, which is particularly helpful for bolus feeding (via gastrostomy). However, the high fiber context of Glucerna may make this formula more prone to causing clogging of gastrostomy tubes.

27.1 Free Water Flushes

Most patients require free water in addition to tube feeds. Most patients require 240mL 4 times per day via gastrostomy

27.2 Med Administration via G-Tubes

Patients who have difficulty with dysphagia or complete esophageal obstruction will need to have their medicines administered via jejunostomy tube. The process of designing a medicine regimen which can safely be administered via enteral tube can be a challenge and may require a consultation with the hospital pharmacist. One the other hand, the financial consequences of a clogged feeding tube are substantial. **Flomax is never given via enteral feeding tubes due to risk of clogging**.

Several common medicines are available in liquid form:

- Acetaminophen (pediatric formulation)
- Gabapentin
- Oxycodone
- Hydrocodone + acetaminophen
- Reglan

Apart from delayed-release medicines and Flomax (tamsulosin), *most medicines can be crushed and resuspended and administered via gastrostomy tube if needed.*

Nexium can be administered by opening the capsule and resuspending the beads in 50mL of water. The beads are resuspended and administered. In this case, the beads don't dissolve in the syringe, but can be administered without risk of clogging.

Chapter 28

Jejunostomy Feedings

Due to the osmotic load, jejunostomy feedings are given via enteral (Kangaroo) pump rather than bolus feeding. Feedings are generally begun as continuous (around-the-clock) and are then transitioned to nocturnal (generally 6pm to 10am) prior to discharge.

Jejunostomy feedings carry a small but significant risk (~1%) of small bowel necrosis, as evidenced by the findings of pneumatosis on CT scan and in some cases small bowel necrosis and perforation. The existing literature would suggest that the early symptoms associated with small bowel necrosis are abdominal distension. As a result, patients on jejunostomy tube feeding need to be carefully monitored for distension, and tube feeds held if distension develops.(Taylor et al. 2014) Tube feeds are generally started at 30mL/hour in the immediate postoperative patients. In patients who are awake and in whom it is possible to determine whether or not there are issues of tube feed intolerance, the rate of tube feedings is increased 10mL/hour every 12 hours to a goal of 60mL/hour for women and 75mL/hour for men. In patients who are intubated/sedated, the advancement of tube feeds is individualized, and decisions are made on a daily basis on rounds.

For patients who receive tube feedings preoperatively, the same formula is generally used after surgery.

For patients with BMI less than 35, Osmolite 1.5 is used as a starting formula. If Osmolite is not tolerated due to diarrhea, Vital 1.5 can be used. For patients with BMI greater than 35, Promote is used as a starting formula, as it contains a lower amount of carbohydrates then Osmolite 1.5. Patients who are intolerant to Promote can be switched to Vital High Protein.

Patients less than 150 pounds receive 4 cans of tube feedings, administered at 60mL/hour x 16 hours (6pm to 10am). Patients greater than 150 pounds receive 5 cans of tube feedings, administered at 75mL/hour x 16 hours (6pm to 10am).

Patients with BMI >35 receive 5 cans of Promote (or Vital High Protein).

Glucerna is formulated with carbohydrates with low glycemic index, which is particularly helpful for bolus feeding (via gastrostomy) or patients who are eating. Glycemic index is less important in patients on continuous tube feeds (eg via jejunostomy). In addition, the high fiber context of Glucerna may make this formula more prone to causing clogging of jejunostomy tubes. Free Water Flushes

Once patients are transferred to the ward, free water via jejunostomy should be ordered as 240mL via jejunostomy qid. This is entered under Flush Enteral Tube for Free Water Requirements. Diarrhea with Jejunostomy Feedings

Patients who experience diarrhea during jejunostomy administration (especially diarrhea at night) will need this addressed. Several steps

- Send stool for C Diff
- Consider changing tube feedings to a more easily digestible formula. Patients on Osmolite 1.5 can be changed to Vital 1.5. Patients on Vital 1.5 can be changed to Vivonex. Patients on Promote can be changed to Vital High Protein
- Stop tube feedings for 2-4 hours to allow diarrhea to resolve
- restart tube feeds at a lower rate (eg 20mL/hour lower than the prior rate).
- Bannatrol can be given to patients taking an oral diet. Bannatrol is NOT given via jejunostomy tube to avoid clogging.
- Lomotil is generally used as a last resort.

28.1 Med Administration via J-Tubes

Patients who have difficulty with dysphagia or complete esophageal obstruction will need to have their medicines administered via jejunostomy tube. The process of designing a medicine regimen which can safely be administered via enteral tube can be a challenge and may require a consultation with the hospital pharmacist. One the other hand, the financial consequences of a clogged feeding tube are substantial. **Flomax is never given via jejunostomy tubes due to risk of clogging**.

Several common medicines are available in liquid form:

- Acetaminophen (pediatric formulation)
- Gabapentin
- Oxycodone
- Hydrocodone + acetaminophen
- Reglan

Apart from delayed-release medicines and Flomax (tamsulosin), most medicines can be crushed and resuspended and administered via gastrostomy tube if needed.

Nexium can be administered by opening the capsule and resuspending the beads

in 50mL of water. The beads are resuspended and administered. In this case, the beads don't dissolve in the syringe, but can be administered without risk of clogging.

28.2 Occluded Jejunostomy Tubes

Jejunostomy tubes which are refractory to the usual non-invasive means (warm water, Coca-Cola) will need to be changed over a wire in Interventional Radiology.

28.3 Jejunostomy feedings on preop Patients

Scope Anesthesia policy states the jejunostomy feeds are considered equivalent to oral solid food in terms of NPO interval. In general, jejunostomy tube feeds should be held at midnight the night before surgery.

Chapter 29

Jejunostomy + Diabetes

Inpt – Jejunostomy ~ Diabetes

Patients on tube feeds are typically started on continuous (around-the-clock) tube feedings, and subsequently changed to a nocturnal regimen (typically 6pm to 10am). The diabetic management for these patients differs depending upon their tube feeding regimen:

Diabetics on Continuous Tube Feeds.

Non-insulin diabetic patients are generally initially given Osmolite 1.5 as it provides higher caloric density and does not contain fiber, which tends to clog the feeding tubes. Diabetic patients requiring insulin can be initially trialed on Osmolite 1.5 but are changed to Promote or Glucerna 1.5 if their blood sugars prove difficult to control (as evidence by either the need for EndoTool or requiring a q6 hour regimen of insulin N + insulin R).

Diabetic patients who need insulin while receiving tube feedings are typically treated initially with continuous tube feedings and around-the-clock insulin. Patients with large insulin requirements may need hourly intravenous insulin (with dosages calculated via EndoTool). Once their insulin requirements are stabilized, they are transitioned to a q6 hour regimen consisting of N and R insulin, typically twice as many units of N insulin as R (for instance, 6Units of N + 3 Units of R insulin every six hours). Patients who require EndoTool or a q6hr regimen need an endocrinology consultation with Dr Kelli Dunn to assist in diabetic management.

Diabetics on Nocturnal Tube Feeds

Most patients are transitioned from continuous tube feeds to nocturnal prior to discharge. Diabetic patients on nocturnal tube feedings typically receive tube feeding from 6pm to 10am and receive insulin at initiation of tube feeds (6pm) and again at 6 hours later (midnight). A typical regimen might be 18U of 70/30

at 1800 and 18U of 70/30 at MN. An alternative might be 12U NPH + 6U Regular at 1800 and 16U NPH and 8U Regular insulin at MN. Because it can take several days to determine the correct insulin regimen, diabetic patients receiving jejunostomy feedings are cycled as early in their hospital course as possible to avoid delaying discharge for blood sugar management.

Diabetic patients receiving insulin will need careful coordination of tube feeding and insulin administration when they are being transitioned from continuous to nocturnal tube feeds. Patients on continuous tube feeds may receive insulin on a q6 hour schedule, while those receiving nocturnal tube feeds receive insulin at 1800 and MN. When patients on continuous tube feeds are transitioned, the tube feeds are stopped at 10am, to be restarted at 6pm that evening. It is critical that as soon as the tube feeds are stopped at 10am, that the q6 hour insulin as stopped as well.

In either case it is critical that if tube feedings are stopped, standing insulin administration (either q6 hour OR 1800 and MN) be stopped as well. In these cases, sliding scale insulin is generally continued.

Day	Time	Tube Feeds	Insulin
SUN	MN	60mL/hr	8N+4R
Mon	6am	60mL/hr	8N+R
Mon	Noon	Stop	None
Mon	6pm	75mL/hr	16N + 8R
Mon	MN	75mL/hr	16N+ 8R
Tues	10am	Stop	None
Tues	6pm	75mL/hr	16N+ 8R
Tues	MN	75mL/hr	16N+ 8R
Weds	10am	Stop	None

In this example, the patient was receiving 8N + 4R every 6 hours, so total insulin units per day is (8+4) x 4 = 48units. Because the carbohydrate load of 60mL/hour x 24 is roughly equivalent to 75mL/hour x 16 hours, the total insulin administered is roughly the same. When converted to nocturnal dosing, the patient now received 16+8 = 24 units twice (6pm and MN) = 48U. In practice, it may be wiser to begin by adjusting the dose down a little, to perhaps 14U N and 7U R for the first night.

Chapter 30

Esophagectomy ICU

See Esophagectomy Postop Care

ICU Care

All patients admitted to STICU with Surgical Critical Care Consultation. Contact STICU High Team or STICU Low Team (depending upon bed assignment)

Ward Care

Once stable, patients are transferred to 6T. If a 6T bed is not available, please notify Dr Salo. Historically, over 95% of patients are transferred to 6T after leaving the ICU.

Neuro

Multimodal pain control:

- gabapentin (300mg tid liquid via Jejunostomy)
- Tylenol (1000mg q6hrs as pediatric liquid via Jejunostomy).
- Epidural in most patients. Epidurals will usually be removed by the fifth postoperative day.
- [ASRA Guidelines for anticoagulation] (https://rapm.bmj.com/content/rapm/43/3/263.full.pdf)
- Once epidural removed: PCA with subsequent conversion to oxycodone elixir via Jejunostomy.
- No ketorolac (Toradol) given risk of anastomotic failure1
- Home anxiolytics are generally administered at half the home dose

Cardiovascular

Postoperative atrial fibrillation is a common occurrence (20%) after esophagectomy, with the risk increasing in older patients. For patients over age 70, half of patients will develop atrial fibrillation in the postoperative period.

For prevention of atrial fibrillation, beta blockade is used. For patients receiving beta blockers prior to surgery, continuation of beta blockade is recommended. For others, patients are given metoprolol 2.5 mg IV q6hrs which can be titrated up to 10mg IV q6hrs as needed. See STS Guidelines.2

Home anti-hypertensives are usually held in order to allow beta-blockade. Patients who have elevated blood pressures once they are adequately beta-blocked (eg HR 60-70) are usually restarted on their home anti-hypertensives. *Home anti-hypertensives are not routinely restarted postoperatively*

Respiratory

Chest X-ray on admission to ICU. Chest tubes generally consist of a 28Fr Blake drain placed into the right chest. This is placed to water seal when output is less than 200mL/day and there is no leak visible in the Pleurevac container. Chest tubes are usually removed once output is less than 150mL/day and drainage is clear without evidence of chyle (milky appearance).

Gastrointestinal All patients receive pantoprazole 40mg IV daily and metoclopramide 5-10mg IV q 6hrs

Nutrition

All esophagectomy patients receive a feeding jejunostomy at the time of operation. In the immediate post-operative period, patients receive Osmolite 1.5 starting the day of surgery once they are off pressors. Tube feeds are started at 20mL/hour until flatus and then advanced at 10mL per hour every 8 hours, up to a goal of 60mL per hour (x24 hours). Patients who are on tube feeds prior to surgery are generally restarted on their home tube feed formula.

Patients who do not tolerate Osmolite are switched to Vital 1.5, which is prehydrolyzed. In order to allow enough time for switching of tube feedings, patients are generally switched from Vital to their home tube feeding formula 3-4 days prior to discharge. This is typically done when they are transferred out of the ICU.

Obese patients (BMI>30) are started on Promote at 20mL/hour and increased to a goal of 60mL/hour. Promote contains a more protein relative to carbohydrdates. An alternative is Vital High Protein, which is similar to Promote but using hydrolyzed proteins.

Diarrhea in patients on tube feeds (especially nocturnal diarrhea) needs to be addressed. Despite STICU guidelines for nutrition in trauma patients, diarrhea (especially night-time diarrhea) is justification for alteration in tube feeds. See Diarrhea and Jejunstomy Feeding

Diabetic Patients

Patients who require EndoTool in the ICU will need an endocrinology consult. See also Jejunostomy Feedings with Diabetes

'Free Water'

In addition to tube feeds, most patients will receive 'free' water flushes through the jejunostomy. This is typically done as 240mL four times per day (for a total of 32oz)

Nasogastric Tubes

A silicone nasogastric tube (Covidien Salem Sump) is placed in all patients during surgery and the position confirmed by ultrasound intraoperatively. Tubes are positioned so that all 4 dots are outside. Gastric emptying is evaluated with upper GI prior to NG tube removal. Once extubated, upper GI is typically performed on the 2nd through 4th postoperative day. Conversely, patients who are intubated will keep their nasogastric tube until extubated. Radiology ordered as "upper GI Series". In the comments section please add "IsoVue through NG tube. Contact Dr Salo for study". See Evaluation of GI Function

Drains

- JP1: 19Fr Blake drain in left pleura. The exit site the most lateral drain and is secured with a blue suture
- JP2: 19Fr Blake drain in right pleura. The exit site is medial to JP1 and is secured with a black suture
- JP3: 19 Fr Blake drain in abdomen. If used, the exit site is most medial and is secured with a blue suture
- JP4: 15Fr Blake drain in neck (for cervial incision)
- JP5: 15Fr Blake drain in subcutaneous tissue of incision

Evaluation for Anastomotic leak

Drain amylase is an inexpensive, specific, and relatively sensitive test for anastomotic leak. Fluid from JP2 (right chest) is sent for "Body Fluid Amylase" starting on postoperative day #4 and continued until postoperative day 9. Drain amylase over 400IU/ml is considered positive and prompts a CT esophagram for confirmation. See also Evaluation for Anastomotic Leak

Renal Total fluids (IV + tube feeds) are generally run at 75mL/hour. Foley catheter is removed on the first or second day after surgery. Some patients will need diuresis on the 3rd or 4th postoperative day

Heme All patients require VTE prophylaxis with Lovenox or heparin SQ.

Preoperative anti-platelet agents are started on the first (aspirin) or second (Plavix) postoperative day if there is no excessive bleeding from the chest tube or JP drains. Patients on preoperative anticoagulation are transitioned to therapeutic Lovenox on the second postoperative day if no signs of bleeding.

ID Prophylactic Cefazolin and Flagyl are administered for 24 hours and stopped

Chapter 31

Esophagectomy Ward

See Esophagectomy Postop Care

Ward Care

Once stable, patients are transferred to 6T. If a 6T bed is not available, please notify Dr Salo. Historically, >98% of patients are transferred to 6T after leaving the ICU.

31.1 Anti-Hypertensives

Patients are transitioned to enteral metoprolol once they are transferred to the ward. Patients on IV metoprolol at 2.5mg IV q6 hours are started on 25mg enteral bid, while patients receiving 5mg IV q6 hours are started on 50mg bid. For patients who are not taking medicines by mouth, liquid metoprolol can be ordered while an inpatient. (Liquid metoprolol is ***not*** available as a home medicine.)

Home anti-hypertensives are usually held in order to allow beta-blockade. Patients who have elevated blood pressures once they are adequately beta-blocked (eg HR 60-70) are usually restarted on their home anti-hypertensives. *Home anti-hypertensives are not routinely restarted postoperatively.* Home antihypertensives are restarted on a selective basis.

31.2 Epidural Catheter

Epidural catheters are routinely placed. Foley catheters are usually left in place until the epidural is removed. Preoperative heparin is ***not*** administered if an epidural is to be placed, but is administered by anesthesia at least one hour after epidural placements. Postoperatively, prophylactic Lovenox 40mg sq daily

is used. Therapeutic Lovenox and anti-platelet agents are not used until the epidural catheter is removed.

31.3 Chest tubes

Chest tubes generally consist of a 28Fr Blake drain placed into the right chest. This is placed to water seal when output is less than 200mL/day and there is no leak visible in the Pleurevac container. Chest tubes are usually removed once output is less than 150mL/day and drainage is clear without evidence of chyle (milky appearance).

31.3.1 Chest tube removal

- Supplies needed: Suture removal kit, 4x4 gauze, xeroform or Vaseline gauze, 2" silk tape, red biohazard bag
- Notify the bedside RN
- Explain procedure to patient including the need for prolonged expiration during removal
- Prepare a bandage with 4x4 gauze and Xeroform
- Cut and remove suture
- Cover the exit site with the Xeroform bandage
- Rehearse process with patient: prolonged expiration
- Pull tube and apply bandage
- Place tube and Atrium/Pleurevac in red biohazard bag and dispose of in soiled utility room
- Return patient room to prior condition (including lowering bed)

Chest x-ray 4 hours after removal to look for a pneumothorax.

31.4 GI Medicines

All patients receive pantoprazole 40mg IV daily and metoclopramide 5-10mg IV q 6hrs. This is later switched to enteric PPI and reglan. For patients <age 75, remeron is added as 15mg enteral qhs.

31.5 Evaluation for leak

Experience suggests that the median time to the diagnosis of leak is 7 day after surgery. Currently the risk of anastomotic leak at CMC after transthoracic esophagectomy is 2%. The most sensitive test for the diagnosis of leak is CT esophagram (see below). Based upon institutional experience, patients are divided into low risk of leak vs high risk for leak based upon drain amylase level and white blood cell count. Patients with a normal drain amylase (400IU/ml) between postoperative day 4 and day 7 AND white blood cell count less than 12 are considered low risk. Patients with either an elevated drain amylase or WBC

greater than 12 are evaluated with CT esophagram. In a group of 100 patients, several were found to have elevated drain amylase in the first four days (up to 2000Iu/ml) which subsequently declined, and no evidence of leak was found

31.5.1 Drain Amylase

JP2 is placed into the right pleura, passes through the hiatus, and is brought out through a trocar site in the medial left upper quadrant. Drain amylase from JP2 is tested beginning on postoperative day #4 until discharge or postoperative day #9. JP2 is generally removed prior to patient discharge. JP1 is placed in the left pleura and is generally not tested for amylase.

31.5.2 CT esophagram

This is the most sensitive study for the detection of anastomotic leak. In order to obtain sufficient sensitivity, it requires a pre-contrast scan and the administration of contrast into the esophagus. The need for a pre-contrast scan means that the presence of remnant barium in the esophagus (from a Modified Barium Swallow) makes it more difficult to interpret the scan and should be avoided. Awake patients can drink the contrast. Patients with an NG tube present at the time of the study generally will have contrast administered through their NG tube. Almost all esophagectomy patients will have a Covidien silicone Salem Sump 18Fr tube in place. This has four marks on the tube at 45, 55, 65, and 75cm. The tube is typically positioned with the 4th mark at the nares, which means that the tip is 45cm from the nares and is usually within the gastric conduit AND below the anastomosis. The NG tube also contains side holes which extend 8.5cm above the tip of the tube. The optimal study is done with the NG tube withdrawn so that there are two side-holes above the anastomosis, which means that the tip is approximately 5cm below the anastomosis. A scout CT will be performed, and the radiologist will determine how far back the NG tube needs to be withdrawn. This is communicated to the CT technician, who asks the nurse (or physician) to withdraw the tube the calculated amount (making a note of the starting position of the tube relative to the four marks). This should keep the tip below the level of the anastomosis, so that after the CT scan, the NG tube can be (blindly) advanced back to its original position (at approximately 45cm from the nares).

Patients who clinically deteriorate prior to post-operative day 7 in whom there is high suspicion for a leak (fevers, pleural effusion on chest X-ray, elevated JP amylase, respiratory failure) will undergo a CT esophagram earlier than post-operative day 7.

31.6 Anastomotic Leak Treatment

If a patient is demonstrated to have a leak, they are made NPO AND will have any pleural effusion treated with a pigtail catheter. Conservative management

will generally be successful for most patients with leaks provided 1) there is no evidence of conduit necrosis 2) nutrition is optimized and 3) empyema is treated. Patients with leaks may even need a decortication, which emphasizes the importance of CT scan in the sick post-operative esophagectomy patient, so that an empyema can be diagnosed and treated. Patients with leaks who show signs of systemic illness may need to be considered for an intraluminal stent. Patients who are profoundly ill need to be evaluated for gastric necrosis with upper endoscopy.

Nutrition

All esophagectomy patients receive a feeding jejunostomy at the time of operation. In the immediate post-operative period, patients receive Osmolite 1.5 starting the day of surgery once they are off pressors. Tube feeds are started at 20mL/hour until flatus and then advanced at 10mL per hour every 8 hours, up to a goal of 60mL per hour (x24 hours). Patients who are on tube feeds prior to surgery are generally restarted on their home tube feed formula.

Patients who do not tolerate Osmolite are switched to Vital 1.5, which is pre-hydrolyzed. In order to allow enough time for switching of tube feedings, patients are generally switched from Vital to their home tube feeding formula 3-4 days prior to discharge. This is typically done when they are transferred out of the ICU.

Obese patients (BMI>30) are started on Vital High Protein at 20mL/hour and increased to a goal of 60mL/hour. Promote contains a more protein relative to carbohydrdates.

Diarrhea in patients on tube feeds (especially nocturnal diarrhea) needs to be addressed. Despite STICU guidelines for nutrition in trauma patients, diarrhea (especially night-time diarrhea) is justification for alteration in tube feeds. See Diarrhea and Jejunostomy Feeding

Diabetic Patients

Patients on tube feeds are typically started on continuous (around-the-clock) tube feedings, and subsequently changed to a nocturnal regimen (typically 6pm to 10am). See Jejunostomy Feeds in Diabetic Patients

'Free Water'

In addition to tube feeds, most patients will receive 'free' water flushes through the jejunostomy. This is typically done as 240mL four times per day (for a total of 32oz)

Nasogastric Tubes

A silicone nasogastric tube (Covidien Salem Sump) is placed in all patients during surgery and the position confirmed by ultrasound intraoperatively. Tubes are positioned so that all 4 dots are outside. Gastric emptying is evaluated with upper GI prior to NG tube removal. Once extubated, upper GI is typically

performed on the 2nd through 4th postoperative day. Conversely, patients who are intubated will keep their nasogastric tube until extubated.

Upper GI is ordered as *FL Upper GI Track Single Contrast*

Drains

- JP1: 19Fr Blake drain in left pleura. The end of the tube is cut at an angle. The exit site the *usually* the most lateral/inferior drain.
- JP2: 19Fr Blake drain in right pleura. The exit site is *usually* medial/superior to JP1
- JP3: 19 Fr Blake drain in abdomen. If used, the exit site is *usually* most medial
- JP4: 15Fr Blake drain in neck (for cervical incision)
- JP5: 15Fr Blake drain in subcutaneous tissue of incision

Evaluation for Anastomotic leak

Drain amylase is an inexpensive, specific, and relatively sensitive test for anastomotic leak. Fluid from JP2 (right chest) is sent for "Body Fluid Amylase" starting on postoperative day #4 and continued until postoperative day 9. Drain amylase over 400IU/ml is considered positive and prompts a CT esophagram for confirmation. See also Evaluation for Anastomotic Leak

Renal Total fluids (IV + tube feeds) are generally run at 75mL/hour. Foley catheter is removed on the first or second day after surgery. Some patients will need diuresis on the 3rd or 4th postoperative day

Heme All patients require VTE prophylaxis with Lovenox.

Preoperative anti-platelet agents are started on the first (aspirin) or second (Plavix) postoperative day if there is no excessive bleeding from the chest tube or JP drains. Patients on preoperative anticoagulation are transitioned to therapeutic Lovenox on the second postoperative day if no signs of bleeding.

ID Prophylactic Cefazolin and Flagyl are administered for 24 hours and stopped

31.7 Labs

Once on the ward, BMP and CBC are checked every other day. Patients with leukocytosis (>12,000) are monitored with daily CBC until resolved.

31.8 Discharge Medicines

Patients after esophagectomy typically go home with the following medicines:

Proton pump inhibitors (will continue for 2 years) Oxycodone elixir via feeding tube. Current STOP guidelines dictate that patients receive no more than a 7 day supply of opiods at discharge Reglan 10mg po qid (will stop at 6 weeks

post-op) Remeron 15mg qhs (will continue for 3 months post-op) Tylenol 1000mg q6 hours as elixir (pediatric form) Gabapentin 300mg as liquid tid x 14 days Metoprolol if started postoperatively (most patients). If not on beta blockers preoperatively, this will be cut in half at the first visit and stopped at the second postoperative visit. It is important to limit the use of medicines via jejunostomy in order to lower the risk of clogging the feeding tube. While liquid metoprolol is available for inpatients, it is not available from outpatient pharmacies.

31.9 Diet at discharge

- 70% will pass their MBS for thin liquids are and discharged on protein shakes
- 15% will pass for nectar thick but fail for this liquids. They are discharged taking medicines with a sip of thickened water but otherwise NPO
- 15% will fail for nectar thick and are discharged NPO with medicines via jejunostomy

Part V

Outpatient

Chapter 32

Outpatient Jejunostomy Care

32.1 Jejunostomy Tubes

Two types of tubes are used

Dacron cuffed MIC tube 0301-14. These tubes are usually only placed after esophagectomy. The dacron cuff is designed to sit in the subcutaneous tissue. If the cuff becomes incorporated, the tube can stay in placed for extended periods of time. Unfortunately, the cuff is prone to infection. Patients with infection of a cuffed jejunostomy will need antibiotics (eg Augmentin) and orders for stat *IR J tube Manip Exchange*

Removal of cuffed tubes requires a small surgical procedure. Supplies required:

- ER Laceration tray
- 30mL 1% xylocaine (prefer with epinephrine)
- 15 blade scalpel
- Non-sterile gloves

Patient will need a surgical consent and a procedure note.

Balloon Tube MIC 8200-14

These tubes are held in place by a balloon simlar to a foley catheter. The balloon is typically inflated with 5mL of water. Saline is not used in the balloon as the salt may crystallize in the balloon valve. Balloon tubes can be removed by deflating the balloon and traction. A gauze is placed over the site. Patients are instructed that the site can drain for a few days. A jejunal-cutaneous fistula develops in approximately 1% of patients, who will will placement of an ostomy bag over the site and total parenteral nutrition (TPN) in order for the fistulous

tract to heal.

Chapter 33

Outpatient Esophagectomy

Patient are usually seen 7-10 days after hospital discharge.

33.1 Postop Evaluation

By system:

Neurologic - Pain control

Patient are typically discharged on:

- acetaminophen 1000mg qid
- gabapentin 300mg tid (liquid)
- oxycodone elixir 5mg q6 hrs prn

If patients need additional oxycodone, this is renewed 2 weeks at a time, typically to correspond to a clinic day. Their current daily usage at the time of their first postop visit is estimated, and the first prescription plans for the same daily amount for a two week period. If they are taking 5mg of oxycodone 5 times per day, a prescription is prepared for 5 x 14 = 70 doses. The prescription is annotated "Two week supply at 5 doses per day". Patients are told the prescription will be renewed 2 weeks later at a reduced dose (typically one fewer dose per day). If the oxycodone bottle is lost, patients are prescribed tramadol (50mg q6 hours). Patient are told that if they need long-term pain management, they will need the assistance of their primary care provider.

Patients are instructed that they are not "cleared" for driving as long as they are taking oxycodone

Cardiovascular

Beta blockers are used around the time of surgery to prevent atrial fibrillation. Management depends upon patients's preoperative medications:

Patients not on beta-blockers or antihypertensives prior to surgery are started on metoprolol 25 to 50mg enteral bid in the hospital. At their first postoperative visit, metoprolol is cut to once per day for one week, then stopped.

Patients taking antihypertensives but not on beta-blockers prior to surgery are started on metoprolol 25 to 50mg enteral bid in the hospital. In some cases, their anti-hypertensives are held to prevent hypotension. At their first postoperative visit, metoprolol is discontinued and their home antihypertensives resumed.

Patients taking beta-blockers are kept on their beta blockers in the hospital and after surgery

If patients have been experienced atrial fibrillation in the hospital or have new cardiac medicines, they will need cardiology follow up for management. Typically this is amiodarone.

Respiratory

Pleural effusion (typically on the right) is a risk after esophagectomy. If the lung exam suggests a pleural effusion, a chest x-ray PA/Lateral can be obtained same-day in LCI I.

Chest incisions should be inspected for signs of wound infection and retained silk (black) suture at the chest tube site

Patients who are hypoxemic should be further investigated with chest x-ray. Delayed pulmonary embolism would be unusual, but would need to be considered and evaluated with a CT angiogram.

GI

Patients who pass their modified barium swallow are discharged on protein shakes and water by mouth. They are advanced to a Phase I diet at their first post-operative visit.

Patients who do not pass their modified barium swallow will need an outpatient MBS ordered at the first postop visit. They will continue with either 1) meds via J tube or 2) meds with thickened water, depending upon their MBS results in the hospital.

Skin staples are removed, and the jejunostomy site inspected for infection. Infections are treated with Augmentin for 7-10 days. In some cases, infected cuffed jejunostomy tubes will need to be replaced in interventional radiology. See J tubes

Tube feeds are typically run for 16 hours nocturnal - 5 cartons for men (75mL/hour) and 4 cartons for women (60mL/hour). Free water is usually 240mL 4x/day.

Diabetics on Tube Feeds receiving insulin require special management.

70% of patient are taking oral liquids when discharged, including protein shakes. For patients that can get one Premier protein, this represents 30gm of protein,

which is the equivalent of 2 cartons of tube feeds. These patients can often have their tube feeds decreased to 3 cartons/night, which allows them to run for only 12 hours.

Diarrhea Loose stools during the day are to be expected, but diarrhea at night is problematic both for sleep and quality of life. This may require a change in formula from intact protein (Osmolite 1.5) to a peptide formula (Vital 1.5). If patients are taking enough protein orally through protein shakes, it may be possible to decrease the rate of tube feeds.

Constipation can be easily treated by increasing free water to 240mL 6x/day (48oz) or even 240mL 8x/day (64oz). Miralax is generally not required with a jejunostomy.

Reglan is used for 6 weeks after surgery, then stopped. If patients have reflux symptoms, this is renewed for another 6 weeks.

Remeron (if used) is given for 12 weeks after surgery, then stopped.

Proton pump inhibitors are used for 12 months after surgery, to prevent anastomotic stricture.

Renal

Patient with renal dysfunciton in the hospital should have BMP checked at their first postoperative visit.

Hematologic

Patients on Plavix or anticoagulation should have had theses medicines restarted before discharge.

ID

New fevers at home require investigation with CXR and CBC or CT chest/abdomen/pelvis as indicated

33.2 Medication Management

Beta blockade and anti-hypertensives

Atrial fibrillation occurs in the postoperative period in 20% of patients. For this reason, beta blockers are used to atrial fibrillation prevention. In the ICU, metoprolol is administered intravenously and is subsequently changed to enteral administration. Because metoprolol also lowers blood pressure, patients on home anti-hypertensives frequently have them held during their hospital stay (and after discharge). At the first postoperative visit, patients who were not treated with beta blockade preoperatively are generally switched from metoprolol back to their home anti-hypertensives.

33.3 Special Cases

33.3.1 Weaning Tube Feeds in Diabetics

As outpatients begin eating more orally, their tube feeds are reduced.

Weaning from 5 cans to 4 cans: Easiest method is to maintain the same schedule (16 hours) and reduce insulin dosage by 20%. For instance, the above patient who is on 5 cans at 75mL/hour x 16 hours is receiving 16N + 8R at start of tube feeds and 6 hours later. This patient could be weaned by reducing rate form 75mL/hour x 16 hours to 60mL/hour x 16 hours and reducing insulin to 12N + 6R at the start of tube feeds AND another dose of 12N + 6R after 6 hours.

Weaning from 4 cans to 3 cans: One option is to decrease the duration of tube feeds from 16 hours to 12 hours, while maintaining rate of 60mL/hour. In this case, the insulin dosage could be kept the same at the start of tube feeds, BUT the dose 6 hours after the start of tube feeds could be omitted.

Once patients are on 3 cans per night, further weaning can be accomplished by skipping tube feeds (and insulin) every other night in a "tube feed holiday". This allows an evening of interrupted sleep and can tend to increase the appetite the morning after tube feeds are held.

Part VI

Esophageal Cancer

Chapter 34

Esophageal Overview

Esophageal cancers can be grouped into 4 treatment categories:

- Superficial → Endoscopic therapy
- Localized → Primary surgery
- Locally Advanced → Trimodality therapy
- Metastatic → Systemic therapy

Patients with minimal dysphagia, no weight loss, and small (<3cm length) tumors are evaluated with endoscopic ultrasound:

- If uT1 on EUS and <2cm in size, endoscopic mucosal resection yields more information and may be therapeutic for tumors with negative margins and without high-risk features.
- If uT2N0 on EUS, and PET scan shows a small tumor (MTV <10cm^3), primary surgery is preferred in patients who are good surgical risks
- If T3 or N+ on EUS, if PET shows no metastatic disease, neoadjuvant therapy is optimal)

Patients with dysphagia to solids or weight loss or tumor length >3cm are unlikely to have T1-2 tumors and can be evaluated with PET scan.

- If PET shows disease confined to the esophagus and regional nodes, trimodality therapy (chemoradiation followed by surgery) is optimal.
- If PET shows metastatic disease, patients are eligible for palliative chemotherapy with radiation for treatment of symptoms of dysphagia.
- If PET shows extra-regional lymph node disease, patient is at high risk for distant disease and can be treated with induction chemotherapy followed by chemoradiation and surgical evaluation.

Chapter 35

EsoCa SCORE - JR

Junior Resident SCORE - Esophageal Neoplasms

Junior Resident SCORE - Esophagectomy

Anatomy

Epidemiology and Prevention

- Worldwide distribution
- Risk factors

Presentation

- Symptoms
- Nutritional consequences

Diagnosis and Staging

- Physical findings
- Role of PET scan
- Role of EUS
- TNM staging system
- Treatment Categories
  - Superficial
  - Localized
  - Locally-advanced
  - Metastatic

Operative Treatment

- Indications for surgery
- Operative anatomy
- Gastric tube construction
- Ivor Lewis

- Transhiatal
- McKeown

Complications

- Postoperative hypovolemia
- Chylothorax
- Anastomotic leak - chest
- Anastomotic leak - neck
- Atrial fibrillation
- Aspiration
- Vocal cord paralysis
- Stomach ischemia

Intraop Decision-making

- Liver metastasis
- Peritoneal lesion

Nonoperative management

- Palliative Radiation
- Esophageal stents

Resources

Esophageal Cancer Talk

Esophageal Cancer Cases

Chapter 36

EsoCa Objectives - Chief

Chief Resident SCORE

Epidemiology and Prevention

- Worldwide distribution
- Risk factors for squamous cell carcinoma
- Risk factors for adenocarcinoma

Presentation

- Symptoms
- Nutritional consequences

Diagnosis and Staging

- Physical findings
- Role of PET scan
- Role of EUS
- TNM staging system
- Treatment Categories
  - Superficial
  - Localized
  - Locally-advanced
  - Metastatic

Multidisciplinary Management

- High-grade dysplasia
- Endoscopic therapy
- Primary surgical therapy
- Trimodality therapy

Operative Mangement

- Ivor Lewis
- Transhiatal
- Left thoracoabdominal
- McKeown
- Alternative conduits
- Complications and their management

References

- CROSS Trial Behind the Knife Podcast
- MAGIC Trial
- FREGAT
- Dutch TIME trial

Chapter 37

Staging

The staging workup begins once a diagnosis is made on endoscopy.

The first step is to make a preliminary determination whether the tumor is early stage (and can be treated with endoscopy or primary surgery) or later stage (and treated with chemoradiation followed by surgery or with)

Patients with minimal dysphagia, no weight loss, and tumors with less than 3cm cranio-caudal extent have a reasonable change of being T1 or T2 tumors. Tumors <3cm in length are much more likely to represent T1-2 lesions than those $\geq$ 3cm(Hollis et al. 2017). For these patients, determining the precise T stage is important in their workup, so **endoscopic ultrasound** is the most frequent staging study after diagnosis.

Patients who present with dysphagia are likely to have T3 or T4 disease, which is generally treated with neoadjuvant chemoradiation followed by surgery. Data from Memorial Sloan Kettering (Ripley et al. 2016) among 61 patients with esophageal cancer who presented with dysphagia, 54 (89%) were found on EUS to have uT3-4 tumors. On the other hand, among 53 patients without dysphagia, 25 (47%) were uT1-2, and were potentially candidates for primary surgery. Their conclusion was that EUS could be omitted from the workup of patients with dysphagia, but is useful in patients without dysphagia.

PET can be helpful in evaluating patients who may have T1-2 disease, and might be candidates for primary surgical therapy. A comparison of PET and EUS (Malik et al. 2017) showed that uT1-2 tumors had median metabolic tumor volume (MTV) of 6.7cm^3, compared with uT3-4 tumors, with a median MTV of 35.7cm^3.

Chapter 38

Barrett's Esophagus

AGA recommendations for endoscopic ablation of Barretts:

Strong recommendation for ablation of high grade dysplasia. Recommends surveillance at 3,6,12 months, then annually.

Shaheen randomized trial of radiofrequency ablation (RFA) for dysplasia (Shaheen et al. 2009). Mean age 66 years. Mean length of Barrett's esophagus 5.3cm. RFA resulted in 77% rate of eradication of Barrett's at one year.

Meta-abalysis suggests ablation can reduce rate of development of cancer from 6.6 per 100 person years to 1.9 (Rastogi et al. 2008)

RFA for Barrett's national registry (Ganz et al. 2008)

RFA for low-grade dysplasia (Phoa et al. 2014) resulted in 25% risk reduction in progression to HGD.

38.1 Anti-reflux surgery for Barrett's esophagus

Chapter 39

Superficial EsoCa (T1)

Superficial esophageal cancer is usually asymptomatic, which means that the diagnosis is generally made in the context of surveillance for Barrett's esophagus.

Nodular Barrett's esophagus can be best evaluated with endoscopic mucosal resection, which can provide further staging information if an adenocarcinoma is found, such as depth of invasion, differentiation, and lymphovascular invasion.

Larger lesions arising within Barrett's esophagus should first be evaluated with endoscopic ultrasound (EUS)

EUS is less sensitive for T1 lesions (Bergeron et al. 2014) -> use EMR for diagnosis (Maish and DeMeester 2004)

T1a tumors have a low risk of nodal metastasis (Dunbar and Spechler 2012)

39.1 Endscopic Mucosal Resection (EMR)

For patients with nodular Barrett's esophagus or small tumors judged to be T1 by endoscopic ultrasound, endoscopic mucosal resection (EMR) can be diagnostic and potentially curative.

EMR is likely sufficient for small tumors with favorable pathologic factors(Nurkin et al. 2014):

- Size less than 2cm
- Lateral and deep margins clear
- Absence of lymphovascular invasion
- Well- or moderately- differentiated

Need for RFA of Barrett's after EMR: (Haidry et al. 2013)

Combination therapy with EMR and RFA results in lower rate of recurrence than EMR alone.(O. Pech et al. 2008) 1000 patients with T1a adenocarcinoma

werer treated with EMR followed by RFA with only 2 (0.2%) of patient dying of esophageal cancer with median followup of almost 5 years.(Oliver Pech et al. 2014)

Review of EMR: (Soetikno et al. 2005)

39.2 Endoscopic submucosal dissection (ESD).

For T1a tumors, EMR and ESD appear to have similar outcomes (Terheggen et al. 2017) Terheggen, G. et al. A randomised trial of endoscopic submucosal dissection versus endoscopic mucosal resection for early Barrett's neoplasia. Gut 66, 783–793 (2017).

Endoscopic submucosal dissection is a technique for deeper endoscopic removal of esophageal lesions using endoscopic cautery, which dissects through the submucosa. ESD has a higher rate of curative resection (Cao et al. 2009) albeit at the cost of prolonged operative times and increased risk of complications such a bleeding. (Repici et al. 2010)

ESD takes more time and has higher R0 resection rate but similar recurrence rate at 2 years (Terheggen et al. 2017)

Chapter 40

Localized EsoCa

40.1 T1b Tumors

40.2 T2N0 Tumors

Multiple studies have failed to show the additional benefit of chemotherapy or chemoradiation for pT2N0M0 esophageal cancer patients treated with radiation.

Neoadjuvant chemo not likey to be helpful for early stage disease - FFCD 9901 (C. Mariette et al. 2014) enrolled patients with T1-2 or T3N0 tumors to chemoradiation followed by surgery versus surgery alone. The majority of the tumors (72%) were squamous cell carcinoma.Postoperative mortality was significaly increased in the chemoradiation arm (11.1% vs 3.4%).

Meta-analysis of 5265 patients in 10 studies showed that while neoadjuvant therapy was associated with a reduction in positive margin rate, there was no difference in terms of recurrence or survival.(**mota176?**)

French trial FREGAT(Markar et al. 2016)

Retrospective review of the National Cancer DataBase failed to demonstrate a difference in survival of cT2N0M0 esophageal cancer with or without preoperative chemoradiation.(Speicher et al. 2014)

A retrospective report from Johns Hopkins examined outcomes of T2N0 squamous cell carcinoma patients and showed equivalent outcomes for primary surgery vs neoadjuvant chemoradiation followed by surgery (Zhang et al. 2012)

Retrospective reveiw from Utrecht found longer survival for cT2N0 patients treated with trimodality therapy compared with primary surgery (**wirsik799?**)

Indiana University: 731 patient undergoing esophagectomy, of whom 68 were cT2N0. Among 35 patients who had surgery alone, 17 (49%) were clinically

understaged. Understaging was more common among poorly-differentiated tumors (Hardacker et al. 2014)

40.3 Staging of T2N0 Tumors

The challenge for treatment decision-making is the limited sensitivity of endoscopic ultrasound in ruling out pT3 or pN+ disease. In other words, if a patient who is thought to have cT2N0 disease undergoes resection, and is found on pathology to have pT3 or pN^+ disease, this would dictate the need for postoperative chemoradiation. In general, chemoradiation after esophagectomy is difficult for patients to tolerate, with a 40 % chance of failure to complete therapy.

Data from the Cleveland Clinic looked at 53 patients judged to be T2N0 by endoscopic ultrasound (uT2N0) were treated with primary surgery. Pathologic examination showed that 17 (37%) were understaged by endoscopic ultrasound, and were pathologic (pT3) in 4 or node positive (pN^+) in 13 cases. These patients were treated with postoperative adjuvant chemoradiation.(Rice et al. 2007)

It is critical, therefore, in patients for whom primary surgery is contemplated, to attempt to identify those with occult T3 or N+ disease.

40.3.1 PET for staging of early-stage esophageal cancer

86 patients with esophageal adenocarcinoma and squamous cell carcinoma (Mantziari et al. 2020) evaluated with PET: clinical T3/T4 was significantly predicted by SUVmax 8.25, Total Lesion Glycolysis >42 and Metabolic Tumor Volume > $10cm^3$

Cohort of patients treated with primary surgery: risk factors for clinical understaging are dsyphagia, poor differentiation, and tumor length >3cm (Worrell et al. 2018)

40.4 Primary Surgery

NCCN recommends PET scan

Most common sites of metastasis are liver, lung, bones, adrenal.

PET detects occult metastasis in 10-20% of cases Kim et al. (2009). Among 129 patients with esophageal cancer, PET detected additional sites of disease in 41% and changed management in 38% (Chatterton et al. 2009)

PET for restaging detects interval development of metastatic disease in 8-17% of cases (Vliet et al. 2008)

Chapter 41

Locally Advanced EsoCa

Tumors that are T2N^{+}M0 or T3NxM0 are considered locally-advanced. The high rate of failure with surgery alone has led to development of adjunctive therapies.

41.1 Trimodality Therapy

Trimodality therapy consists of chemoradiation (chemoRT) followed by surgery. Between 2010 and early 2024, this approach was the standard of care for locally-advanced esophageal cancer. In 2024, the ESOPEC trial showed superior survival for *adenocarcinoma* with perioperative "sandwich" FLOT chemotherapy compared to chemoRT. For squamous cell carcinoma, trimodality therapy continues to be the standard of care.

CROSS trial randomized 364 patients with resectable esophageal and gastroesophageal junction tumors (75% adenocarcinoma) to neoadjuvant chemoradiation consisting of 4,140 cGy of radiation with concurrent carboplatin and paclitaxel or surgery alone.(Hagen et al. 2012) Clinical node-positive disease was present in 16%. Pathologic complete response was seen in 23% of adenocarcinoma and 49% of squamous cell carcinomas. Median overall survival was 49 months after trimodality vs 24 months after surgery alone (p=0.003). Survival at 5 years was 47% with trimodality vs 34% with surgery alone. Squamous cell carcinomas appeared to have particular benefit, with a hazard ratio of 0.42 for squamous cell vs 0.74 for adenocarcinoma. Median survival was improved for adenocarcinoma from 27.1 months to 43.2 months, but the median survival for squamous cell increased from 27.1months to 81.6 months for squamous cell. Rate of R0 resection was higher with chemoradiation (92% vs 69% p<0.001) and local recurrence rates lower (14% vs 34% P<0.001), and peritoneal recurrence lower (4% vs 14% P<0.001). Despite the relatively low dose of radiation, in-field recurrences were less than 5%. The primary cause of failure was distant disease

(31%) and local/regional failure (14%). Therapy was well-tolerated with 17% grade 3 toxicity.(Oppedijk et al. 2014)

Ten-year followup of the CROSS trial (Eyck et al. 2021) showed that the primary benefit of CROSS regimen was in reducing local and loco-regional recurrences. There was no difference in isolated distant recurrence betwee the two arms.

NeoResII trial i(Nilsson et al. 2023) investigated interval between end of CROSS neoadjuvant therapy and surgery. Original hypothesis was that prolonged interval between chemoRT and surgery might increase pCR rate. Patients randomized to short interval (4-6 weeks) vs long interval (10-12 weeks). No difference in pCR rate or overall survival. However, bottom quartile for survival was shorter in the prolonged interval group. There does not appear to be an advantage in prolonged interval between chemoradiation and for some patients (perhaps those with more aggressive tumors), prolonged interval may be detrimental.

Alternative to carboTaxol for chemoradiation is FOLFOX (SOG trial (Leichman et al. 2011))

Ongoing PROTECT trial compares FOLFOX to paclitaxel and carboplatin (Messager et al. 2016)

See also Definitive ChemoRT

41.2 Neoadjuvant Chemo (adenocarcinoma)

ESOPEC Trial (**heoppner323?**) compared FLOT chemotherapy with CROSS chemoradiation for *adenocarcinoma* of the esophagus and found better survival with FLOT. FLOT resulted in superior 3-year survival (57% vs 51%). Pathologic CR rate 16.7% vs 10%. Grade 3 toxicity 58% vs 50%. 90-day mortality 3.1% with FLOT vs 5.6% CROSS. pCR rate was much lower than original CROSS trial (23%). Notably, patients with an incomplete pathologic response after CROSS (90%) did not receive adjvant nivolumab, which has since become the standard of care due to the Checkmate 577 trial(Kelly et al. 2021).

POET Trial (Pre-Operative therapy in Esophageal adenocarcinoma Trial) treated 119 patients with adenocarcinoma of the gastroesophageal junction with either neoadjuvant chemotherapy (5-FU, leucovorin, cisplatin) followed by surgery or induction chemotherapy with the same agents, followed by chemoradiation (4000cGy with concurrent cisplatin and etoposide). The study suffered from slow accrual, but there was a suggestion of improved 3-year survival with preoperative chemoradiation (47.4% vs 27.7% p=0.07) as well as better local control (76.5% vs 59%). In addition, chemoradiation was associated with a higher pathologic complete response rate (15.6% vs 2%)(Stahl et al. 2009).

Neo-AEGIS Trial (Reynolds et al. 2017) Randomized patients with GE junction adenocarcinomas to CROSS vs modified MAGIC (prior to 2018) or FLOT (after 2018). Trial included Siewert I, II, and III tumors. Trial was underpowered and

did not show a difference between the regimens.

OEO2 clinical trial (Allum et al. 2009) Randomized trial of preoperative chemotherapy with ECF for esophageal and GE junction cancers. Improved survival with preoperative chemotherapy.

41.2.1 Neoadjuvant Chemotherapy → ChemoRT

TOPGEAR study (Leong et al. 2017) randomized patients with gastric or GE junction adenocarcinoma to neoadjuvant chemo (ECF or FLOT) vs neoadjuvant chemo followed by chemoRT (4500cGy). Higher pCR rate with chemo → chemoRT (17% vs 8%) but no difference in survival at 67mo followup. Higher R0 resection rate with chemo → chemoRT (92% vs 88%) ECF used for 2/3 of patients and FLOT for 1/3.

German trial (Stahl et al. 2009) randomized patients to preoperative chemotherapy (A) vs preoperative chemotherapy followed by preoperative chemoradiation (B). Higher pcR rate in arm B (15.6% vs 2%) and ypN0 resection (64.4% vs 37.7%).

41.3 Postoperative chemoradiation

Intergroup-0116 (Macdonald et al. 2001) (Smalley et al. 2012) treated 556 patients with adenocarcinoma of the stomach or GE junction with surgery along vs surgery followed by postoperative chemoradiation. After a median followup of over 5 years, median overall survival iin the surgery alone group was 27 months vs 36 months in the postoperative chemoradiation group (p=0.005) Decrease in local failure as the first site of failure in the chemoradiation group (19% versus 29%).

Chemoradiation after resection of GE junction tumors (Kofoed et al. 2012) among a group of 211 patients with GE junction adenocarcinoma with positive lymph nodes with improved 3-year disease-free survival (37% vs 24%).

41.4 Restaging

PET is routinely done for restaging esophageal cancer after chemoradiation. Interval metastasis is found in 9% of cases (Noordman et al. 2018). Similar findings in a European multicenteral study (Zijden et al. 2024)

41.5 Active Surveillance

Patients treated with neoadjuvant therapy who have a robust clinical response (as evidenced by PET and EGD) can be treated with intensive surveillance.

EGD is poor predictor of pCR due to low sensitivity(Sarkaria et al. 2009)

41.6 GE Junction

(Siewert, Stein, and Feith 2006)

Chapter 42

Metastatic EsoCa

42.1 Palliative radiation

Palliative radiation vs chemoradiation (Penniment et al. 2018)

Radiation along favored over chemoradiation in the palliaitve setting (Penniment et al. 2018)

42.2 Chemoradiation vs chemotherapy in Stage IV

(Guttmann et al. 2017)

42.3 Stents for malignant disease

(Vakil et al. 2001)

Review of guidelines 2010 Am Society GI (Sharma, Kozarek, and Practice Parameters Committee of American College of Gastroenterology 2010)

42.4 Perc Esophagostomy

Percutaneous transesophageal gastrostomy (PTEG) can be used as an alternative to nasogastric decompression, particularly in malignant obstruction.

Systematic review of 14 studies(Zhu et al. 2022) 3 cases of PTEG for malignant obstruction, all placed under sedation. (Singal et al. 2010) 10 patients treated with PTEG for malignant bowel obstruction. Time from placement to death median 15 days. Unlike venting gastrostomy, all patients required suction to

maintain resolution of malignent bowel obstruction symptoms. (Selby et al. 2019) 38 patients treated with perc transesophageal gastrostomy (PTEG) which was successful in 35/38. Mean catheter duration 61 days with 5/35 requiring tube exchanges. (Rotellini-Coltvet et al. 2023)

17 patients treated with PTEG (Udomsawaengsup et al. 2008)

Chapter 43

Chemoradiation

**This section addresses chemoradiation as primary (definitive) therapy for esophageal cancer. See also Trimodality Therapy

43.1 Phase II Studies

Experience with patients who refuse surgery or are medically unfit:

MD Anderson report of 61 patients out of 622 tri-modality-eligible patients who refused surgery after cCR. 5-year overall survival was 58%. 13 developped local recurrence during surveillance, and 12 had successful salvage esophagectomy (Taketa et al. 2012). The same group compared those who underwent surgery vs definitive chemoradiation in a propensity-matched fashion(Taketa et al. 2013). Irish study of 56 patients aged 70 or older treated with neoadjuvant chemoradiation followed by selective surgery. Median survival was 28 months overall, 47 months for those with cCR, 61 months for primary resection, 46 months for cCRs who did not undergo resection, and 29 months for those with salvage esophagectomy(Furlong et al. 2013).

Castoro(Castoro et al. 2013)

preSANO(Chirieac et al. 2005) Clinical Response evaluation after chemoRT for esophageal cancer with PET and EGD.

RTOG 94-05 clinical trial (Minsky et al. 2002)

43.2 ChemoRT vs Trimodality therapy

The sensitivity of squamous cell carcinoma of the esophagus to chemoradiation has raised the question whether

Stahl Locally advanced squamous cell carcinoma randomized to induction chemotherapy (cisplatin, etopiside, 5FU with leuocovrin) followed by chemoradiation (4000cGy with concurrent ciplatin and etopiside) followed by surgery compared with induction chemotherapy followed by chemoradiation (6400cGy with concurrent cisplatin and etopiside).(Stahl et al. 2005) progression-free survival was better in the trimodality group (64.3% vs 40.7%) Treatment-related morality was substantial in the surgery arm (13% vs 4%). This would be considered an excessive rate of operative mortality by modern standards. Unsurprisingly, there was no difference in overall survival between groups, in part because the surgical group had an excess 9% mortality rate from treatment. Two-year survival in the surgery arm was 40% vs 35% in the definitive chemoradiation arm.

In the French FFCD trial, 444 patients with carcinoma of the esophagus (90% squamous cell) were treated with two cycles of 5-FU and cisplatin with concurrent radiation.(Bedenne et al. 2007) Patients with a partial or complete clinical response to chemoradiation were randomized to either surgery or a boost of radiation. Patients who did not respond to chemoradiation were treated with surgery and were eliminated from the study. Only 259 of the original 444 patients (59%) went on to randomization, with the remainder (those not responding to chemoradiation) treated with surgery. Of the randomized group, median survival was 17.7months in the surgery arm versus 19.3months in the definitive chemoradiation arm. Like the Stahl study, treatment-related mortality in the surgical arm was high (9% versus 1%).

43.3 Active Surveillance

EGD is poor predictor of pCR (Sarkaria et al. 2009)

Chapter 44

Salvage esophagectomy

(Markar et al. 2014)

(Swisher et al. 2002)

SANO clinical trial (Overtoom et al. 2024) found similar outcomes for esophagectomy <12mo vs >12mo after preoperative therapy, but higher rate of respiratory complications in the delayed surgery group.

Chapter 45

Nutrition

45.1 Jejunostomy tubes

Jejunostomy tubes are the conventional method used for nutritional support in patients with esophageal cancer who may under surgery in the future. Jejunostomy avoids potential damage to the (future) gastric conduit most commonly used for reconstruction of the esophagus.

45.2 Gastrostomy tubes

PEG in esophageal cancer (Margolis et al. 2003). PEG placement planned in 119/179 patients with new diagnosis of esophageal cancer. Successful in 103/119. No incidence of tumor inoculation metastasis noted. 61 patients underwent surgery and none had difficulty with gastrostomy closure. PEG patients were more likely to complete chemoRT and had better survival at 12 months.

Case report of PEG causing injury to right gastroepiploic artery (Ohnmacht et al. 2006)

Chapter 46

Esophageal Surgery

Three general approaches exist for surgical therapy.

Trans-thoracic or Ivor Lewis esophagectomy(Visbal et al. 2001) removes the intrathoracic portion of the esophagus and constructs an anastomosis within the chest. The approach include an abdominal phase, during which an esophageal substitute is constructed (usually from stomach). A thoracic phase then removes the intrathoracic esophagus and constructs an anastomosis within the chest cavity.

A McKeown esophagectomy utilizes three surgical fields: abdomen, right chest, and neck. The right chest approach allows dissection of peri-esophageal lymph nodes, and the cervical incision allows removal of the total esophagus.(McKeown 1976) This approach is useful for tumors which involve the proximal thoracic esophagus, to ensure a negative margin. The cervical anastomosis carries a higher risk of anastomotic leak than a thoracic anastomosis, although the morbidity of a cervical anastomosis leak is less serious than that of a leak of a thoracic anastomosis.

A transhiatal esohpagectomy approaches the esophagus from the abdomen through the hiatus and from neck. By blunt dissection the esophagus is freed up without the need for thoracotomy. An esophageal substute is then brought from the abdomen to the neck through the mediastinum.(M. B. Orringer and Sloan 1978) (Mark B. Orringer et al. 2007) The operation is designed to avoid the pulmonary toxicity of the right chest approach. On the other hand, the blunt nature of the mediastinal dissection means that fewer lymph nodes are harvested than with a trans-thoracic approach.

Randomized trial of transthoracic esophagectomy with extended lymph node dissection versus transhiatal esohpagectomy showed fewer pulmonary complications with the transhiatal approach. (Hulscher et al. 2002) Fewer lymph nodes were havested with a transhiatal appraoch. A post-hoc analysis showed that

among patients with 1-8 positive lymph nodes, survival with improved with the extended lymph node dissection.(Omloo et al. 2007)

Minimally-invasive approaches to esophagectomy are now common, with evidence for less perioperative morbidity than an open approach (Biere et al. 2012) (Zhou et al. 2015)

Randomized trial of a hybrid MIE (with laparoscopy and thoracotomy) was associated with lower postoperative complications than open esophagectomy (Christophe Mariette et al. 2019)

High volume centers have lower mortality for esophageal cancer than low-volume centers. (Birkmeyer et al. 2003) (Wouters et al. 2009)

46.0.1 Trans-thoracic vs Transhiatal Esophagectomy

Dutch randomized trial (n=262) cervical vs thoracic anastomosis.(Workum et al. 2021) Thoracic anastomosis associated with lower leak rate (12% vs 34%) and lower rate of recurrent laryngeal nerve injury (0% vs 7.3%) and better quality of life (dysphagia, choking while swallowing, and talking)

46.0.2 GE Junction Adenocarcinoma

Siwert III lesions are considered gastric cancers (Rusch 2004) (Siewert, Stein, and Feith 2006)

Laparoscopy may be helpful in Siewert III tumors (Graaf et al. 2007)

46.0.3 Preoperative Evaluation

Dysphagia can be scored according to Mellow et al (Mellow and Pinkas 1985):

- 0 No dysphagia
- 1 Dysphagia to normal solids
- 2 Dysphagia to soft solids (ground beef, poultry,fish)
- 3 Dysphagia to solids and liquids
- 4 Inability to swallow saliva

46.1 Minimally-invasive Esophagectomy

Higher lymph node yield with MIE vs open approach (Kalff, Fransen, et al. 2022)

46.2 Early Recovery Pathways

ERAS Society Guidlines

46.3 Colon Interposition

Left colon technique based upon blood supply (Peters et al. 1995)

Chapter 47

Survivorship

47.1 Nutritional consequences of esophagectomy

47.1.1 Vitamin D deficiency

Vitamin D deficiency is defined as serum 25(OH)D levels below 20ng/mL

- Replacement with 2000 IU Vitamin D3 daily (Khan and Fabian 2010)

Vitamin D insufficiency is defined as serum 25(OH)D level 20-29ng/mL

- Replacement with 1000-2000 IU Vitamin D3 daily

NIH ODS Vitamin D info

(Baker et al. 2016)

Weight loss (Martin and Lagergren 2009) (Ouattara et al. 2012)

47.2 Cardiac toxicity of radiation

(Beukema et al. 2015) (Frandsen et al. 2015) (Gharzai et al. 2016)

Chapter 48

Surveillance

T1a treated with endoscopic resection EGD every 3 mo for first year, then every 6 months for second year, then annually(Shaheen et al. 2016)

T1b treated with endoscopic resection EGD every 3 mon for first year, then every 4-6 months for seond year, then annually CT chest/abdomen every 12 months for up to 3 years (as clinically indicated)

T1b treated with esophagectomy EGD every 3-6 months for first 2 years, then annually for 3 more years. CT every 6-9 months for first 2 years, then annually up to 5 years.

Stage II or III treated with chemoradiation.

These patients are at risk for local recurrence (Sudo et al. 2014) and some may be candidates for salvage esophagectomy. Most relapses (95%) occur within 24 months. See also (Taketa et al. 2014)

Locally-advanced treated with trimodality therapy

Local/regional relapses are uncommon. (Dorth et al. 2014) (Oppedijk et al. 2014) (Sudo et al. 2013) => NCCN does not recommend EGD. 90% of relapses occur within 36 months of surgery.

CT every 6 months up to 2 years (if patient is a candidate for additional curative-intent therapy)

48.0.1 Recurrence Profile

Dutch cancer registry (Kalff, Henckens, et al. 2022)

Part VII

Gastric Cancer

(PART*) Gastric Cancer

Gastric Ca SCORE

Gastric Cancer SCORE

Anatomy

- Lymph node stations
- D1 vs D2 vs D3 nodal basins

Epidemiology

- Worldwide distribution
- Risk factors

Diagnosis and Staging

- Nodal staging number vs location
- Role of PET scan
- Role of laparoscopy

Operative Treatment

- Reconstruction options

Non-operative Treatments

- Palliative chemotherapy
- Stents

Gastrectomy SCORE

Operative Anatomy

Preoperative Preparation

Operative Details

Complications

- Anastomotic leak
- Bleeding
- Obstruction
- Afferent Loop Syndrome
- Dumping

- Alkaline reflux gastritis

GIST SCORE

GI stromal tumors

- Pathology: Cell of origin/IHC
- Operative treatment

Gastric carciniods

- Pathology - Cell of origin
- Type I
- Type II
- Type III
- Role for endoscopic therapy
- Surgery
  - Tumor resection
  - Antrectomy

Gastric lymphoma

- Low-grade vs high-grade MALT vs non-MALT
- Treatment: operative/non-op
- Indications for surgery

Gastric Polyps

- Indications for resection
- Non-operative treatment of hyperplastic polyps
- SMAD4 mutations

Chapter 49

Gastrectomy

49.1 Proximal gastrectomy

Proximal gastrectomy for small proximal tumors can be performed with a dual-tract reconstruction to take advantage of the reservoir capacity of the distal stomach without the risk of gastroesophageal reflux.

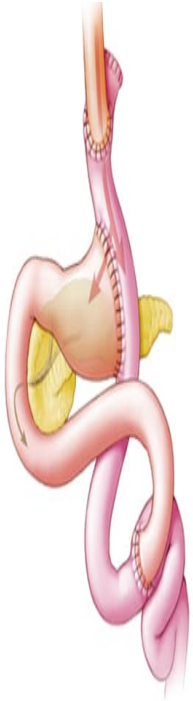

Total vs Subtotal Gastrectomy

Italy: Randomized trial total vs subtotal gastrectomy (Bozzetti et al. 1999). No difference in survival

Chapter 50

Hereditary Diffuse Gastric Cancer

HDGC is a syndrome characterized by early-onset diffuse gastric cancer and increased risk of lobular breast cancer.

Hereditary diffuse gastric cancer was first reported in a New Zealand Maori cohort. The genetic cause was subsequently found to the a deletion in the CDH1 gene.

50.0.1 Penetrance estimates for lifetime risk of DGC

The original estimates of lifetime risk of gastric cancer in those with pathogenic CDH1 mutations were made from a population of patients with strong familiy histories of DGC(Hansford et al. 2015), in this group, the cumulative risk of gastric cancer by 80 years of age was estimated to be to be 70% in men and 56% in women.

The lifetime risk of gastric cancer in more modern cohorts(Roberts et al. 2019) (Xicola et al. 2019), in whom a minority of patients have a family history of gastric cancer, are much lower: 42% in men and 33% in women

50.1 Surveillance for CDH1 carriers

Cancer surveillance as an alternative to prophylactic total gastrectomy in hereditary diffuse gastric cancer: a prospective cohort study Bilal Asif*, Amber Leila Sarvestani*, Lauren A Gamble, Sarah G Samaranayake, Amber L Famiglietti, Grace-Ann Fasaye, Martha Quezado, Markku Miettinen, Louis Korman, Christopher Koh, Theo Heller, Jeremy L Davis Summary Background Loss of function variants in CDH1 are the most frequent cause of hereditary diffuse gastric cancer.

Endoscopy is regarded as insufficient for early detection due to the infiltrative phenotype of diffuse-type cancers. Microscopic foci of invasive signet ring cells are pathognomonic of CDH1 and precede development of diffuse gastric cancer. We aimed to assess the safety and effectiveness of endoscopy for cancer interception in individuals with germline CDH1 variants, particularly in those who declined prophylactic total gastrectomy. Methods In this prospective cohort study, we included asymptomatic patients aged 2 years or older with pathogenic or likely pathogenic germline CDH1 variants who underwent endoscopic screening and surveillance at the National Institutes of Health (Bethesda, MD, USA) as part of a natural history study of hereditary gastric cancers (NCT03030404). Endoscopy was done with non-targeted biopsies and one or more targeted biopsy and assessment of focal lesions. Endoscopy findings, pathological data, personal and family cancer history, and demographics were recorded. Procedural morbidity, gastric cancer detection by endoscopy and gastrectomy, and cancer-specific events were assessed. Screening was defined as the initial endoscopy and all subsequent endoscopies were considered surveillance; follow-up endoscopy was at 6 to 12 months. The primary aim was to determine effectiveness of endoscopic surveillance for detection of gastric signet ring cell carcinoma. Findings Between Jan 25, 2017, and Dec 12, 2021, 270 patients (median age 46 · 6 years [IQR 36 · 5–59 · 8], 173 [64%] female participants, 97 [36%] male participants; 250 [93%] were non-Hispanic White, eight [3%] were multiracial, four [2%] were non-Hispanic Black, three [1%] were Hispanic, two [1%] were Asian, and one [<1%] was American Indian or Alaskan Native) with germline CDH1 variants were screened, in whom 467 endoscopies were done as of data cutoff (April 30, 2022). 213 (79%) of 270 patients had a family history of gastric cancer, and 176 (65%) reported a family history of breast cancer. Median follow-up was 31 · 1 months (IQR 17 · 1–42 · 1). 38 803 total gastric biopsy samples were obtained, of which 1163 (3%) were positive for invasive signet ring cell carcinoma. Signet ring cell carcinoma was detected in 76 (63%) of 120 patients who had two or more surveillance endoscopies, of whom 74 had occult cancer detected; the remaining two individuals developed focal ulcerations each corresponding to pT3N0 stage carcinoma. 98 (36%) of 270 patients proceeded to prophylactic total gastrectomy. Among patients who had a prophylactic total gastrectomy after an endoscopy with biopsy samples negative for cancer (42 [43%] of 98), multifocal stage IA gastric carcinoma was detected in 39 (93%). Two (1%) participants died during follow-up, one due to metastatic lobular breast cancer and the other due to underlying cerebrovascular disease, and no participants were diagnosed with advanced stage (III or IV) cancer during follow-up. Interpretation In our cohort, endoscopic cancer surveillance was an acceptable alternative to surgery in individuals with CDH1 variants who declined total gastrectomy. The low rate of incident tumours (>T1a) suggests that…

Advanced (T3) tumors found during endoscopic surveillance all had mucosal abnormalities found at EGD

Consensus guidelines (2020)(Blair et al. 2020) Recommend surveillance in whom family history of gastric cancer is weak

REcommend 28-30 random biopsies

revirew (Pilonis et al. 2021) Ann rev med 72:263 2022

guidelines (Post et al. 2015) j med genet 52:361

total gast (Chen et al. 2011)ann surg oncol 2011:18. kingham

Cambridge: Endoscopic surveillance in HDGC. 145 patients from 76 families with a family history of gastric cancer and CDH1 mutations (see blair and vanderpost). Pathogenic variasnt of CDH1 in 92 (63%). Prophylatic total gastrecromy done in 36 (25%)

During surveilance 58/145 (58%) were found to have invasive signet ring cell carcinoma.

Of those with CDH1 mutations, 53% had (49/91) had invasive signet ring cell carcinoma diagnosed

Invasive signet ring cell carcinoma detected in 6/41 (15%) with no CDH1 pathogenic mutations

Total gastrectom in 36 of whom 32 (89%) had signet ring cell carcinoma on pathology.

Prophylactic total gastrectomy with CDH1 mutation in 28 patients, of whom 26 (93%) had signet ring cell carcinoma.

6/13 invasive signet ring cell carcinoma found on random biopsies later developped visible lesions and underwent gastrectomy (see addpneix p8) progressed to more advanced

Chapter 51

Gastric GIST

51.1 Genetics

- Mutation of KIT receptor tyrosine kinase in 80%
  - KIT exon 9 mutations have lower response rate to imatinib and shorter progression-free survival than exon 11 mutations (especially at dose of 400mg daily)
- Mutation in PDGRFA receptor tyrosine kinase in 5-10%. Most mutations respond to imatinib except D842V (which may respond to avapritinib)
- No mutation of KIT or PDGFRA in 10-15%. Most will have functional inactivation of SDH complex and evidenced by lack of SDHB on IHC. These patients should be tested for germline SDH mutations. These tumors tend to occur in the stomach in younger patients.

Tyrosine kinase inhibitors:

- imatinib - first line therapy
- Sunitinib treatment is indicated for patients with imatinib-resistant tumors or imatinib intolerance.
- Regorafenib is indicated for patients with disease progression on imatinib or sunitinib.
- Ripretinib is indicated for patients who have received prior treatment with 3 or more kinase inhibitors, including imatinib.

51.2 Surgery

Surgical resection ideally involved a negative histologic margin. A wide resection margin is not required, nor is lymph node dissection unless nodes are clinically involved. (**dematteo51?**)

51.3 Positive margins after resection

ACOSOG working group (**mccarter53?**) studies 819 patients undergoing resection of GIST under Z9000 and Z9001 clinical trials. 72 patients (8.8%) had an R1 resection, of whom 21 had intraperitoneal rupture or bleed. Factors associated with R1 resection included tumor size >10cm, rectum location, and tumor rupture. Disease recurrence in patients with R1 resections was primarily due to associated tumor rupture. There was no difference in recurrence-free survival for patients underoing R1 vs R0 resection.

Norweigan report (Hølmebakk et al. 2019) of 401 patients wtih GIST of whom 47had R1 resection and 52 with tumor recurrence. In patients without rupture, there was no difference in 5-year recurrence-free survival for R1 vs R0 resection. In multivariable analysis, tumor rupture but not R1 resection was associates with recurrence.

Chapter 52

Locally-Advanced Gastric

Locally-advanced gastric cancer (T3 or N^+) is generally treated with some form of adjuvant therapy, which has been shown to improve upon the outcomes with surgery alone.

52.1 Preoperative Chemotherapy

FLOT chemotherapy (Al-Batran et al. 2019) with 5FU, oxaliplatin and Taxotere superior for neoadjuvant chemotherapy compared with epirubicin, oxaliplatin and 5FU (MAGIC regimen).

Matterhorn trial evaluated the addition of anti-PD-L1 MAb **durvalumab** to FLOT for stage I-IVa adenocarcinoma of stomach and GE junction. Both groups received 4 cycles of FLOT every 15 days. Durvalumab group received 2 doses preop and 2 doses postop with FLOT in addition to 10 monthly doses of durvalumab. Surgery was performed 4-8 weeks after the last dose of chemotherapy. Longer disease-free survival and trend to longer overall survival with the addition of durvalumab without additional toxicity.(Janjigian et al. 2025)

MAGIC study randomized 503 patients to perioperative 'sandwich' chemotherapy consisting of epirubicin, cisplatin, and 5-FU versus surgery alone. In the perioperative chemotherapy group, 4 cycles were administered prior to surgery, and 4 cycles afterwards. Tumors of the esophagus or gastroesophageal junction comprised 26% of the study population. While over 90% of patients assigned to the chemotherapy arm completed their preoperative chemotherapy, only 66% completed their postoperative therapy. Survival at 5 years was 36% in the perioperative chemotherapy group, compared with 24% in the surgery group ($p<0.001$).(Cunningham et al. 2006)

ACCORD-07 clinical trial (Ychou et al. 2011): surgery +/- neoadjuvant cisplatin+5FU. Improved R0 resection rate but no difference in survival, perhaps

due to poor accrual.

FFCD trial randomized patients to preoperative chemotherapy with 2 or 3 cycles of cisplatin and 5-FU versus surgery alone. Tumors of the lower esophagus or gastroesophageal junction comprised 75% of the study population. Survival at 5 years was longer in the chemotherapy group (38%) versus 24% in the surgery alone group (p=0.02).(Ychou et al. 2011)

RESONANCE-II trial of Oxaliplatin + S-1 (SOX) (Wang et al. 2021)

52.2 Postoperative chemotherapy

CLASSIC clinical trial randomized 1033 patients with stage II or III gastric cancer after D2 gastrectomy to 6 months of adjuvant chemotherapy with capecitabine and oxaliplatinversus vs surgery alone. Three-year survival was improved in the chemotherapy group (74% *v* 59%).(Bang et al. 2012) (Noh et al. 2014)

52.3 Postoperative chemoradiation

Intergroup 0116 trial (Macdonald et al. 2001) (Smalley et al. 2012) Surgery +/- postoperative chemoradiation. Surgical quality control was poor, as 90% were treated a limited (R1) lymph node dissection. Long-term followup, however (Smalley et al. 2012) showed a persistent benefit of postoperative chemoradiation.

ARTIST trial 450 patients treated with a D1 α gastrectomy were randomized to adjuvant capecitibine and cisplatin versus chemoradiation consisting of two cycles of capcitabine/oxaliplatin followed by chemoradiation followed by chemotherapy. Overall 3- year survival did not differ between groups (78.2% vs 74.2% p =0.86). A post-hoc analysis of patients with positive nodes showed a beneficial effect of chemoradiation (77.5% *v* 72.3% p=0.365).(Lee et al. 2012)

CRITICS trial (Cats et al. 2018) treated all patients with preoperative chemotherapy (ECF or CapeOx) followed by surgery. Postoperative patients were then randomized between additional chemotherapy versus chemoradiation. No difference in survival between groups.

CRITICS-II Trial (Slagter et al. 2018) resectable gastric cancer randomized to neoadjuvant chemo (DOC x4) vs chemo (DOC x2) followed by ChemoRT (CROSS) vs ChemoRT (CROSS).

52.4 Preoperative chemoradiation

RTOG 9904: Phase II trial of preoperative chemoradiation for gastric adenocarcinoma(Ajani et al. 2006). Findings of pathologic complete response (pCR) in 20%.

TOPGEAR trial: neoajuvant chemotherapy ± subsequent radiation therapy: chemo+RT had better pCR rate (17% vs 8%). No survival difference between groups.(Leong et al. 2017)

52.5 Preop Immunotherapy

NEONIPIGA trial: MSI-Hi gastric and GE junction cancers treated with neoadjuvant nivolumbab (6 cycles) and ipilumumab (2 cycles) over 12 weeks. Among 29 patients that underwent surgery, 59% pathologic complete response and all patients had R0 resection.(**andre288?**)

MSKCC: MSI-Hi GI cancers treated with dostarlimab. Clinic response rate: rectal 50/50 (100%), colon 28/33 (82%), gastric 8/14 (57%), GE junction 1/3 (33%), esophageadl 1/3 (0%) (Cercek et al. 2025)

Chapter 53

M1 Gastric CA

53.1 Surgery for M1 disease

REGATTA trial: patient with a single unresectable factor (liver metastasis, peritoneal disease, para-aortic lymphdenopathy randomized between gastrectomy -> chemotherapy vs chemotherapy. No improvement in survival with gastrectomy. Trial was closed early due to futility.(Fujitani et al. 2016)

AIO-FLOT3 trial: evaluted FLOT followed by surgical resection in patients with limited metastatic gastric or GEJ adenocarcinoma. Patients were stratified: resectable (A), limited metastatic (B), and extensive metastatic (C). Arm B patients received at least four cycles of FLOT and were considered for surgery if restaging indicated a chance for R0 resection of the primary and complete resection of metastatic lesions. The primary endpoint was overall survival. Results showed that patients in arm B (limited metastatic) who underwent neoadjuvant FLOT and surgery had a median overall survival of **31.3 months**, compared to **15.9 months** for those who did not proceed to surgery, and **10.7 months** for arm C (extensive metastatic, palliative approach). The response rate in arm B was 60%.(Al-Batran et al. 2017)

53.2 Conversion Surgery

Conversion surgery is performed in patients with positive peritoneal cytology or positive peritoneal disease who, after chemotherapy, are found to have coversion of their findings to M0

Japan: 115 patients with advanced gastric cancer underwent second-look laparoscopy. 56 had negative cytology and peritoneal biopsy. 26 patients had positive cytology and negative peritoneal biopsy, of whom 12 had a negative second-look laparoscopy and had conversion surgery (CS). 33 patients had pos-

itive cytology and peritoneal biopsy. The survival of patients with CS was significantly longer than those without CS (median survival time (MST); 41 vs. 11 months, respectively, $P < 0.001$). We observed no difference in overall survival between patients who underwent CS and patients with CY0P0 at the first SL ($P = 0.913$). All patients with P1 received chemotherapy. As peritoneal metastasis of five patients (15.2%) disappeared by chemotherapy, those patients underwent the CS (R0). The survival of patients who underwent CS was significantly longer than those who did not (MST; 31 vs. 10 months, respectively, $P = 0.034$).(Nakamura et al. 2019)

Part VIII

Colon Cancer

Chapter 54

Colectomy

54.1 SCORE

Partial Colectomy CORE

Indications

Operative Anatomy

Preop Prep

- Antibiotics
- Stoma marking
- Ureteral stents

Complications

- Anastomotic leak
- Ureteral injury

54.2 Early Recovery Protocols

ASCRS and SAGES clinical guidelines for enhanced recovery after colorectal surgery (Irani et al. 2023)

ASCRS Guidelines for Early Recovery

Same-day discharge after colectomy or stoma reversal (Paradis et al. 2024)

54.3 Anesthetic Management

Restrictive vs Liberal Fluid Managment (RELIEF Trial) (**myles378?**) 3000 patients undergoing elective major surgery (43% colorectal, 64% cancer, no liver

resection) randomized to restrictive intraoperative fluid management (aim net zero fluid balance in the OR) vs traditional fluid management. Liberal group averaged 3 liters of intraop fluid and 3 liters first 24 hours postop vs restrictive group with 1.8 and 1.9 liters respectively. No difference in mortality or major disability at 1 year postop. More acute kidney injury in restrictive group. More surgical site infections (17% vs 14%) in the restrictive group. Bottom line: No detectable benefit to restrictive fluid strategy

54.4 Extended Node dissection

Short-term outcomes of complete mesocolic excision versus D2 dissection in patients undergoing laparoscopic colectomy for right colon cancer (RELARC): a randomised, controlled, phase 3, superiority tria

Short-term outcomes of a multicentre randomized clinical trial comparing D2 versus D3 lymph node dissection for colonic cancer (COLD trial). Karachun A, Panaiotti L, Chernikovskiy I, Achkasov S, Gevorkyan Y, Savanovich N, Sharygin G, Markushin L, Sushkov O, Aleshin D, Shakhmatov D, Nazarov I, Muratov I, Maynovskaya O, Olkina A, Lankov T, Ovchinnikova T, Kharagezov D, Kaymakchi D, Milakin A, Petrov A. Br J Surg. 2020 Apr;107(5):499-508. doi: 10.1002/bjs.11387. Epub 2019 Dec 24. PMID: 31872869 Clinical Trial.

Part IX

Rectal Cancer

Chapter 55

Rectal Cancer Staging

55.1 MRI staging

Rectal cancer is preferentially evaluated with MRI. At Atrium, this is ordered as "MRI Pelvis without Contrast Rectal Protocol"

Key findings

- Circumferential resection margin
- Extra mesorectal vascular invasion
- Mesorectal lymph nodes
- Extra-mesorectal lymph nodes

MRI has supplanted endoscopic ultrasound (EUS) as the study of choice for staging rectal cancer.

MERCURY group trial demonstrated the predictive value of MRI for rectal cancer(Taylor et al. 2014) (MERCURY Study Group 2006)

55.2 EUS

Endoscopic ultrasound has now been replaced by MRI for initial staging, in part due to interoperater variability

Chapter 56

Rectal Ca Surgery

56.1 Trans-abdominal Rectal Surgery

Trans-abdominal procedures include

- Low anterior resection: Removal of the rectum with an anastomosis between colon and distal rectum
- Hartmann resection: Removal of the rectum with end colostomy. The rectal stump is stapled. The anal sphincters are left in situ
- Abdominoperineal resection: Removal of rectum and anus from both an abdominal and perineal approach. The anal sphincters are removed.

56.2 Low Anterior Resection

56.2.1 Total Mesorectal Excision

Importance of total mesorectal excision was championed by Bill Heald (Heald and Ryall 1986) who emphasized sharp dissection of the mesorecum outside of the visceral fascial envelope. In addition he advocated dissection of the totality of the mesorectum distal to the tumor to avoid leaving behind nodes within the mesorectum distal to the tumor(Quirke et al. 1986) (Nagtegaal and Quirke 2008) (Paty et al. 1994).

Chapter 57

Rectal Adjuvant Therapy

Surgery as sole treatment for rectal cancer is associated with an unacceptable rate of local recurrence. Accordingly, adjunctive stratagies were employed to reduce risk of local recurrence.

57.1 Surgery ⇒ CRT

The original approach to adjuvant therapy for rectal cancer was surgery followed by chemoradiation.

GI Tumor Study Group (GITSG) showed a reduction in local recurrence with postoperative chemotherapy + radiation

NIH Consensus Conference in 1990 recommended adjuvant chemoradation after surgery

57.2 CRT ⇒ Surgery

The next innovation to adjuvant therapy for rectal cancer was chemoradiation prior to surgery, followed by adjuvant chemotherapy.

German Rectal Cancer Study (AIO-94) compared preop and postop chemoradiation in locally-advanced rectal cancer (Sauer et al. 2001). Among 823 patients, local recurrence was 6% in the preoperative group vs 13% in the postop group (p=0.0006). Overall survival was not different, but preop chemoradiation was less toxic. Pathologic complete response rate in the preoperative group as 8%.

NSABP R-03 clinical trial (Roh et al. 2009) randomized 267 patients with T3 or T4 or node-positive rectal cancer to preop vs postop chemoradiation. Disease-free survival was better in the preoperative group, wiht no difference in

overall survival. Pathologic complete response rate in the preop group was 15%. The trial did not meets its accrual targets.

57.3 TME

Total Mesorectal Excision (TME) was introduced to reduce risk of local recurrence by removal of the mesorectum and its lymph nodes.

57.4 TME + ChemoRT

Dutch Rectal Cancer Trial (CKVO 95-04): Demonstrated the benefit of preop radiation in combination with TME(Kapiteijn et al. 2001). Radiation reduced local recurrence form 10.9% to 5.6%

The Dutch trial found a reduction in local recurrence form 10.9% to 5.6% with preoperative radiation with no difference in survival(Kapiteijn et al. 2001). A later update(Gijn et al. 2011) The Medical Research Council C07 trial compared preoperative short-course radiation with selective post-operative chemoradiation and found no difference in local recurrence (4.4% vs 10.6%) and no difference in overall survival.(Sebag-Montefiore et al. 2009)

57.5 Short-course RT

An alternative to preoperative chemoradiation over 6 weeks is to administer radiation alone properative over a five-day period.

Swedish Rectal Cancer Trial compared surgery alone with preoperative short-course therapy consisting of 5 doses of 500cGy of radiation without chemotherapy administered in one week prior to surgery. Local recurrence was 9% in the therapy group vs 26% in the control group, with an improvement in overall survival of 38% vs 80%(Swedish Rectal Cancer Trial et al. 1997). Of note, this trial was performed in the era prior to the widespread use of total mesorectal excision.

Stockholm III trial showed that short-course radiation therapy performed 4-8 weeks prior to surgery resulted in improved rates of pathologic complete response (12% vs 2%) compared with short-course radiation therapy performed the week prior to surgery (Pettersson et al. 2015)

57.6 Total Neoadjuvant

A more modern approach has been to administer chemotherapy in addition to chemoradiation prior to surgery, Total Neoadjuvant Therapy (TNT)

RAPIDO trial randomized 920 patients with T4 or node-positive disease to long-course chemoradiation followed by surgery vs short-course radiation followed by

chemotherapy and surgery. The pCR rate was significantly higher in the short course/chemotherapy/surgery group (28% vs 14%) and disease-specific surival at 3years was higher (30% vs 24%).(Bahadoer et al. 2021) (Valk et al. 2020)

PRODIGE 23 was designed to reduce distant metastasis and improve survival using TNT and randomized 461 patients with T3 or T4 rectal cancers to long-course radiation followed by surgery (standard therapy) vs induction chemotherapy with FOLFIRINOX followed by long-course radiation (TNT) followed by surgery. Rectal surgery with TME was mandatory. Up-front induction chemotherapy followed by chemoradiation was associated with increased 3-year survival (76% vs 69%) and an increase in rate of pathologic complete response of 28% vs 12%. pCR rate was 28% with TNT vs 12% withj standard therapy. (Conroy et al. 2021)

STELLAR trial (Jin et al. 2022) TNT with short-course radiation (5Gy x 5 days) + CAPEOX chemotherapy vs long-course chemoRT with capecitabine. No differences in relapse-free survival or metastasis free survival. Overall survival better with TNT (p=0.03). On subgroup analysis, no group appeared to have more benefit. pCR rate 17% with TNT vs 13.9% with conventional chemoradiation. Positive margins (R1) occurred in 8.5% of TNT patients vs 12.5% in the conventional chemoRT group.

OPRA clinical trial was designed to optimize organ preservation (Garcia-Aguilar et al. 2022). 324 rectal cancer patients staged with MRI randomized to INCT (induction chemo followed by chemoRT) vs CNCT (Chemoradiation followed by chemotherapy). Patients with a response were offered watch and wait. Patients without a response were treated with surgery. No difference in disease-free survival or overall survival or metastasis-free survival. 304 patients were restaged and only 26% were recommended to have surgery. Among 225 patients in watch and wait, somewhat more patients with INCT had recurrences (40% of 105 = 42 patients vs 27% of 102 =32 patients). More organ preservation at 3 years with CNCT (60% CNCT vs 47% INCT).See also (Smith et al. 2015)

57.7 Selective Adjuvant

Selective adjuvant therapy approaches reserves adjuvant therapy for high-risk patients, and treats low-risk patients with surgery alone.

MERCURY study group has examined selective approaches to adjuvant chemoradiation in low-risk patients with rectal cancer. (Taylor et al. 2011), (Strassburg et al. 2011)

German OCUM group (Kreis et al. 2016) (Ruppert et al. 2018)

Canadian [Quicksilver Trial] (https://jamanetwork.com/journals/jamaoncology/fullarticle/2730134)

57.8 Neoadjuvant ImmunoTx

Mismatch repair protein deficient (MSI-high) colorectal cancer (due to either Lynch Syndrome or BRAF-1 mutation) responds pooly to chemotherapy but responds well to immunotherapy with PD-L1 blockade

MSKCC trial of neoadjuvant PD-L1 blockade with 6 months of dostarlimab for 12 patients with MMR-deficient (MSI-high) rectal cancer resulted in 100% clinical response rate (Cercek et al. 2022). No patients were subsequently treated with either chemoradiation or surgery as originally planned.

PICC trial (Hu et al. 2022) Chinese trial of PD-L1 blockade with neoadjuvant toripalimab + colecoxib vs toripalimab for 3 months in 34 patients with MMR-deficient locally-advanced (T3/4 or N+) colorectal cancer. All patients were then treated with surgery. Pathologic complete response in 88% of dual-therapy patients and 65% of monotherapy. Grade 3 toxicity in 1/34 patients. Previous neoadjuvant chemo in 25%. Rectal cancer in 18%.

NICHE trial (Chalabi et al. 2024) 115 patients with dMMR locally-advanced colon cancer treated with a neoadjuvant immunotherapy. Pathologic complete response in 68%. No recurrences with a median followo up of 26 months.

57.9 Neoadjuvant Chemotherapy

The PROSPECT clinical trial (Schrag et al. 2023) randomized patients with T2/3 recctal cancer to neoadjuvant therapy with chemoradiation vs FOLFOX. 585 in the FOLFOX group and 543 in the chemoradiotherapy group. FOLFOX was noninferior to chemoradiotherapy for disease-free survival and the groups were similar with respect to overall survival. In the FOLFOX group, 53 patients (9.1%) received preoperative chemoradiotherapy (if the primary tumor decreased in size by <20% or if FOLFOX was discontinued because of side effects) and 8 (1.4%) received postoperative chemoradiotherapy.

Part X

Anal Cancer

Chapter 58

Anal Squamous Cell Carcinoma

NCCN Guidelines

Surgical Clinics Review Article: (Young et al. 2020)

58.1 Chemoradiation

Chemoradiation is now the standard for anal squamous cell carcinoma of the anal canal and for perianal cancers (except for small T1 lesions). Nigro protocol is the standard approach.(Nigro et al. 1983)

58.1.1 Restaging after chemoRT

Based on the results of the ACT-II study, it may be appropriate to follow patients who have not achieved a complete clinical response with persistent anal cancer up to 6 months following completion of radiation therapy and chemotherapy as long as there is no evidence of progressive disease during this period of follow-up. Persistent disease may continue to regress even at 26 weeks from the start of treatment.(James et al. 2013)

58.2 Anal Intraepithelial Neoplasia

Review of diagnosis and treatment (Siddharthan, Lanciault, and Tsikitis 2019)

HPV vaccination has been shown to reduce the incidence of AIN in at-risk populations, particularly those <26 years of age (Wei et al. 2023)

Part XI

Sarcoma

Chapter 59

Soft Tissue Neoplasms

59.1 Desmoid Tumors

DeFi Phase 3 trial of Nirogacestat (Gounder et al. 2023)

Milan Consensus Guidelines 2023 (Kasper et al. 2024)

59.2 Lipomatous Tumors

Use of mdm2 IHC/FISH for diagnosis of liposarcoma (Weaver et al. 2010)

59.3 Retroperitoneal

59.3.1 Preop Radiation

STRASS trial randomized 266 patients to preop radiation followed by surgical resection vs surgery alone. At a median followup of 43 months, there was no difference in recurrence-free survival. Serious adverse affects were more common in the preop radiation group (24% vs 10%). One patients in the radiation group died of treatment-related toxicity (gastrocolic fistula), compared with none in the surgery alone group (Bonvalot et al. 2020). See commentary: (Cardona 2020)

STRASS2: Ongoing trial of neoadjuvant chemotherapy. (Lambdin et al. 2023)

59.4 Peritoneal mesothelioma

Review (Bridda et al. 2007)

Surgical Oncology Clinics review (Li and Alexander 2018)

References

Ajani, Jaffer A., Kathryn Winter, Gordon S. Okawara, John H. Donohue, Peter W. T. Pisters, Christopher H. Crane, John F. Greskovich, et al. 2006. "Phase II Trial of Preoperative Chemoradiation in Patients with Localized Gastric Adenocarcinoma (RTOG 9904): Quality of Combined Modality Therapy and Pathologic Response." *Journal of Clinical Oncology: Official Journal of the American Society of Clinical Oncology* 24 (24): 3953–58. https://doi.org/10.1200/JCO.2006.06.4840.

Al-Batran, Salah-Eddin, Nils Homann, Claudia Pauligk, Thorsten O. Goetze, Johannes Meiler, Stefan Kasper, Hans-Georg Kopp, et al. 2019. "Perioperative Chemotherapy with Fluorouracil Plus Leucovorin, Oxaliplatin, and Docetaxel Versus Fluorouracil or Capecitabine Plus Cisplatin and Epirubicin for Locally Advanced, Resectable Gastric or Gastro-Oesophageal Junction Adenocarcinoma (FLOT4): A Randomised, Phase 2/3 Trial." *Lancet (London, England)* 393 (10184): 1948–57. https://doi.org/10.1016/S0140-6736(18)32557-1.

Al-Batran, Salah-Eddin, Nils Homann, Claudia Pauligk, Gerald Illerhaus, Uwe M. Martens, Jan Stoehlmacher, Harald Schmalenberg, et al. 2017. "Effect of Neoadjuvant Chemotherapy Followed by Surgical Resection on Survival in Patients With Limited Metastatic Gastric or Gastroesophageal Junction Cancer: The AIO-FLOT3 Trial." *JAMA Oncology* 3 (9): 1237–44. https://doi.org/10.1001/jamaoncol.2017.0515.

Allum, William H., Sally P. Stenning, John Bancewicz, Peter I. Clark, and Ruth E. Langley. 2009. "Long-Term Results of a Randomized Trial of Surgery with or Without Preoperative Chemotherapy in Esophageal Cancer." *Journal of Clinical Oncology: Official Journal of the American Society of Clinical Oncology* 27 (30): 5062–67. https://doi.org/10.1200/JCO.2009.22.2083.

Bahadoer, Renu R., Esmée A. Dijkstra, Boudewijn van Etten, Corrie A. M. Marijnen, Hein Putter, Elma Meershoek-Klein Kranenbarg, Annet G. H. Roodvoets, et al. 2021. "Short-Course Radiotherapy Followed by Chemotherapy Before Total Mesorectal Excision (TME) Versus Preoperative Chemoradiotherapy, TME, and Optional Adjuvant Chemotherapy in Locally Advanced Rectal Cancer (RAPIDO): A Randomised, Open-Label, Phase 3 Trial." *The Lancet. Oncology* 22 (1): 29–42. https://doi.org/10.1016/S1470-2045(20)30555-6.

Baker, M, V Halliday, RN Williams, and DJ Bowery. 2016. "A Systematic Review of the Nutritional Consequences of Esophagectomy." *Clinical Nutrition*

(Edinburgh, Scotland) 35 (5): 987–97. https://doi.org/10.1016/j.clnu.2015.08.010.

Bang, Yung-Jue, Young-Woo Kim, Han-Kwang Yang, Hyun Cheol Chung, Young-Kyu Park, Kyung Hee Lee, Keun-Wook Lee, et al. 2012. "Adjuvant Capecitabine and Oxaliplatin for Gastric Cancer After D2 Gastrectomy (CLASSIC): A Phase 3 Open-Label, Randomised Controlled Trial." *Lancet (London, England)* 379 (9813): 315–21. https://doi.org/10.1016/S0140-6736(11)61873-4.

Bedenne, Laurent, Pierre Michel, Olivier Bouché, Chantal Milan, Christophe Mariette, Thierry Conroy, Denis Pezet, et al. 2007. "Chemoradiation Followed by Surgery Compared with Chemoradiation Alone in Squamous Cancer of the Esophagus: FFCD 9102." *Journal of Clinical Oncology: Official Journal of the American Society of Clinical Oncology* 25 (10): 1160–68. https://doi.org/10.1200/JCO.2005.04.7118.

Bergeron, Edward J., Jules Lin, Andrew C. Chang, Mark B. Orringer, and Rishindra M. Reddy. 2014. "Endoscopic Ultrasound Is Inadequate to Determine Which T1/T2 Esophageal Tumors Are Candidates for Endoluminal Therapies." *The Journal of Thoracic and Cardiovascular Surgery* 147 (2): 765-771: Discussion 771-773. https://doi.org/10.1016/j.jtcvs.2013.10.003.

Beukema, Jannet C., Peter van Luijk, Joachim Widder, Johannes A. Langendijk, and Christina T. Muijs. 2015. "Is Cardiac Toxicity a Relevant Issue in the Radiation Treatment of Esophageal Cancer?" *Radiotherapy and Oncology: Journal of the European Society for Therapeutic Radiology and Oncology* 114 (1): 85–90. https://doi.org/10.1016/j.radonc.2014.11.037.

Biere, S. S., M. I. van Berge Henegouwen, K. W. Maas, L. Bonavina, C. Rosman, J. R. Garcia, S. S. Gisbertz, et al. 2012. "Minimally Invasive Versus Open Oesophagectomy for Patients with Oesophageal Cancer: A Multicentre, Open-Label, Randomised Controlled Trial." *Lancet* 379 (9829): 1887–92. https://doi.org/10.1016/S0140-6736(12)60516-9.

Birkmeyer, John D., Therese A. Stukel, Andrea E. Siewers, Philip P. Goodney, David E. Wennberg, and F. Lee Lucas. 2003. "Surgeon Volume and Operative Mortality in the United States." *The New England Journal of Medicine* 349 (22): 2117–27. https://doi.org/10.1056/NEJMsa035205.

Blair, Vanessa R., Maybelle McLeod, Fátima Carneiro, Daniel G. Coit, Johanna L. D'Addario, Jolanda M. van Dieren, Kirsty L. Harris, et al. 2020. "Hereditary Diffuse Gastric Cancer: Updated Clinical Practice Guidelines." *The Lancet. Oncology* 21 (8): e386–97. https://doi.org/10.1016/S1470-2045(20)30219-9.

Bonvalot, Sylvie, Alessandro Gronchi, Cécile Le Péchoux, Carol J. Swallow, Dirk Strauss, Pierre Meeus, Frits van Coevorden, et al. 2020. "Preoperative Radiotherapy Plus Surgery Versus Surgery Alone for Patients with Primary Retroperitoneal Sarcoma (EORTC-62092: STRASS): A Multicentre, Open-Label, Randomised, Phase 3 Trial." *The Lancet. Oncology* 21 (10): 1366–77. https://doi.org/10.1016/S1470-2045(20)30446-0.

Bozzetti, F., E. Marubini, G. Bonfanti, R. Miceli, C. Piano, and L. Gennari. 1999. "Subtotal Versus Total Gastrectomy for Gastric Cancer: Five-Year Survival Rates in a Multicenter Randomized Italian Trial. Italian Gastrointestinal

Tumor Study Group." *Annals of Surgery* 230 (2): 170–78. https://doi.org/10.1097/00000658-199908000-00006.

Bridda, Alessio, Ilaria Padoan, Roberto Mencarelli, and Mauro Frego. 2007. "Peritoneal Mesothelioma: A Review." *Medscape General Medicine* 9 (2): 32. https://www.ncbi.nlm.nih.gov/pmc/articles/PMC1994863/.

Cao, Y., C. Liao, A. Tan, Y. Gao, Z. Mo, and F. Gao. 2009. "Meta-Analysis of Endoscopic Submucosal Dissection Versus Endoscopic Mucosal Resection for Tumors of the Gastrointestinal Tract." *Endoscopy* 41 (9): 751–57. https://doi.org/10.1055/s-0029-1215053.

Cardona, Kenneth. 2020. "The STRASS Trial: An Important Step in the Right Direction." *The Lancet. Oncology* 21 (10): 1257–58. https://doi.org/10.1016/S1470-2045(20)30429-0.

Castoro, Carlo, Marco Scarpa, Matteo Cagol, Rita Alfieri, Alberto Ruol, Francesco Cavallin, Silvia Michieletto, et al. 2013. "Complete Clinical Response After Neoadjuvant Chemoradiotherapy for Squamous Cell Cancer of the Thoracic Oesophagus: Is Surgery Always Necessary?" *Journal of Gastrointestinal Surgery: Official Journal of the Society for Surgery of the Alimentary Tract* 17 (8): 1375–81. https://doi.org/10.1007/s11605-013-2269-3.

Cats, Annemieke, Edwin P. M. Jansen, Nicole C. T. van Grieken, Karolina Sikorska, Pehr Lind, Marianne Nordsmark, Elma Meershoek-Klein Kranenbarg, et al. 2018. "Chemotherapy Versus Chemoradiotherapy After Surgery and Preoperative Chemotherapy for Resectable Gastric Cancer (CRITICS): An International, Open-Label, Randomised Phase 3 Trial." *The Lancet. Oncology* 19 (5): 616–28. https://doi.org/10.1016/S1470-2045(18)30132-3.

Cercek, Andrea, Michael B. Foote, Benoit Rousseau, J. Joshua Smith, Jinru Shia, Jenna Sinopoli, Jill Weiss, et al. 2025. "Nonoperative Management of Mismatch Repair-Deficient Tumors." *The New England Journal of Medicine* 392 (23): 2297–2308. https://doi.org/10.1056/NEJMoa2404512.

Cercek, Andrea, Melissa Lumish, Jenna Sinopoli, Jill Weiss, Jinru Shia, Michelle Lamendola-Essel, Imane H. El Dika, et al. 2022. "PD-1 Blockade in Mismatch Repair-Deficient, Locally Advanced Rectal Cancer." *The New England Journal of Medicine* 386 (25): 2363–76. https://doi.org/10.1056/NEJMoa2201445.

Chalabi, Myriam, Yara L. Verschoor, Pedro Batista Tan, Sara Balduzzi, Anja U. Van Lent, Cecile Grootscholten, Simone Dokter, et al. 2024. "Neoadjuvant Immunotherapy in Locally Advanced Mismatch Repair-Deficient Colon Cancer." *The New England Journal of Medicine* 390 (21): 1949–58. https://doi.org/10.1056/NEJMoa2400634.

Chatterton, B. E., I. Ho Shon, A. Baldey, N. Lenzo, A. Patrikeos, B. Kelley, D. Wong, J. E. Ramshaw, and A. M. Scott. 2009. "Positron Emission Tomography Changes Management and Prognostic Stratification in Patients with Oesophageal Cancer: Results of a Multicentre Prospective Study." *European Journal of Nuclear Medicine and Molecular Imaging* 36 (3): 354–61. https://doi.org/10.1007/s00259-008-0959-y.

Chen, Yijun, Kerry Kingham, James M. Ford, James Rosing, Jacques Van Dam, R. Brooke Jeffrey, Teri A. Longacre, Nicki Chun, Allison Kurian, and Jeffrey A. Norton. 2011. "A Prospective Study of Total Gastrectomy for CDH1-

Positive Hereditary Diffuse Gastric Cancer." *Annals of Surgical Oncology* 18 (9): 2594–98. https://doi.org/10.1245/s10434-011-1648-9.

Chirieac, Lucian R., Stephen G. Swisher, Jaffer A. Ajani, Ritsuko R. Komaki, Arlene M. Correa, Jeffrey S. Morris, Jack A. Roth, Asif Rashid, Stanley R. Hamilton, and Tsung-Teh Wu. 2005. "Posttherapy Pathologic Stage Predicts Survival in Patients with Esophageal Carcinoma Receiving Preoperative Chemoradiation." *Cancer* 103 (7): 1347–55. https://doi.org/10.1002/cncr.20916.

Conroy, Thierry, Jean-François Bosset, Pierre-Luc Etienne, Emmanuel Rio, Éric François, Nathalie Mesgouez-Nebout, Véronique Vendrely, et al. 2021. "Neoadjuvant Chemotherapy with FOLFIRINOX and Preoperative Chemoradiotherapy for Patients with Locally Advanced Rectal Cancer (UNICANCER-PRODIGE 23): A Multicentre, Randomised, Open-Label, Phase 3 Trial." *The Lancet. Oncology* 22 (5): 702–15. https://doi.org/10.1016/S1470-2045(21)00079-6.

Cunningham, David, William H. Allum, Sally P. Stenning, Jeremy N. Thompson, Cornelis J. H. Van de Velde, Marianne Nicolson, J. Howard Scarffe, et al. 2006. "Perioperative Chemotherapy Versus Surgery Alone for Resectable Gastroesophageal Cancer." *The New England Journal of Medicine* 355 (1): 11–20. https://doi.org/10.1056/NEJMoa055531.

Dorth, Jennifer A., John A. Pura, Manisha Palta, Christopher G. Willett, Hope E. Uronis, Thomas A. D'Amico, and Brian G. Czito. 2014. "Patterns of Recurrence After Trimodality Therapy for Esophageal Cancer." *Cancer* 120 (14): 2099–2105. https://doi.org/10.1002/cncr.28703.

Dunbar, Kerry B., and Stuart Jon Spechler. 2012. "The Risk of Lymph-Node Metastases in Patients with High-Grade Dysplasia or Intramucosal Carcinoma in Barrett's Esophagus: A Systematic Review." *The American Journal of Gastroenterology* 107 (6): 850–862; quiz 863. https://doi.org/10.1038/ajg.2012.78.

Edwards, Michael A., Kinga Powers, R. Wesley Vosburg, Randal Zhou, Andrea Stroud, Nabeel R. Obeid, John Pilcher, et al. 2025. "American Society for Metabolic and Bariatric Surgery: Postoperative Care Pathway Guidelines for Roux-En-Y Gastric Bypass." *Surgery for Obesity and Related Diseases: Official Journal of the American Society for Bariatric Surgery*, January, S1550-7289(25)00059-0. https://doi.org/10.1016/j.soard.2025.01.005.

Eyck, Ben M., J. Jan B. van Lanschot, Maarten C. C. M. Hulshof, Berend J. van der Wilk, Joel Shapiro, Pieter van Hagen, Mark I. van Berge Henegouwen, et al. 2021. "Ten-Year Outcome of Neoadjuvant Chemoradiotherapy Plus Surgery for Esophageal Cancer: The Randomized Controlled CROSS Trial." *Journal of Clinical Oncology: Official Journal of the American Society of Clinical Oncology* 39 (18): 1995–2004. https://doi.org/10.1200/JCO.20.03614.

Frandsen, Jonathan, Dustin Boothe, David K. Gaffney, Brent D. Wilson, and Shane Lloyd. 2015. "Increased Risk of Death Due to Heart Disease After Radiotherapy for Esophageal Cancer." *Journal of Gastrointestinal Oncology* 6 (5): 516–23. https://doi.org/10.3978/j.issn.2078-6891.2015.040.

Fujitani, Kazumasa, Han-Kwang Yang, Junki Mizusawa, Young-Woo Kim, Masanori Terashima, Sang-Uk Han, Yoshiaki Iwasaki, et al. 2016. "Gastrectomy Plus Chemotherapy Versus Chemotherapy Alone for Advanced Gastric Cancer with a Single Non-Curable Factor (REGATTA): A Phase 3, Randomised Controlled Trial." *The Lancet. Oncology* 17 (3): 309–18. https://doi.org/10.1016/S1470-2045(15)00553-7.

Furlong, Heidi, Gary Bass, Oscar Breathnach, Brian O'Neill, Eamonn Leen, and Thomas N. Walsh. 2013. "Targeting Therapy for Esophageal Cancer in Patients Aged 70 and Over." *Journal of Geriatric Oncology* 4 (2): 107–13. https://doi.org/10.1016/j.jgo.2012.12.006.

Ganz, Robert A., Bergein F. Overholt, Virender K. Sharma, David E. Fleischer, Nicholas J. Shaheen, Charles J. Lightdale, Stephen R. Freeman, et al. 2008. "Circumferential Ablation of Barrett's Esophagus That Contains High-Grade Dysplasia: A U.S. Multicenter Registry." *Gastrointestinal Endoscopy* 68 (1): 35–40. https://doi.org/10.1016/j.gie.2007.12.015.

Garcia-Aguilar, Julio, Sujata Patil, Marc J. Gollub, Jin K. Kim, Jonathan B. Yuval, Hannah M. Thompson, Floris S. Verheij, et al. 2022. "Organ Preservation in Patients With Rectal Adenocarcinoma Treated With Total Neoadjuvant Therapy." *Journal of Clinical Oncology: Official Journal of the American Society of Clinical Oncology* 40 (23): 2546–56. https://doi.org/10.1200/JCO.22.00032.

Gharzai, Laila, Vivek Verma, Kyle A. Denniston, Abhijeet R. Bhirud, Nathan R. Bennion, and Chi Lin. 2016. "Radiation Therapy and Cardiac Death in Long-Term Survivors of Esophageal Cancer: An Analysis of the Surveillance, Epidemiology, and End Result Database." *PloS One* 11 (7): e0158916. https://doi.org/10.1371/journal.pone.0158916.

Gijn, Willem van, Corrie A. M. Marijnen, Iris D. Nagtegaal, Elma Meershoek-Klein Kranenbarg, Hein Putter, Theo Wiggers, Harm J. T. Rutten, et al. 2011. "Preoperative Radiotherapy Combined with Total Mesorectal Excision for Resectable Rectal Cancer: 12-Year Follow-up of the Multicentre, Randomised Controlled TME Trial." *The Lancet. Oncology* 12 (6): 575–82. https://doi.org/10.1016/S1470-2045(11)70097-3.

Gounder, Mrinal, Ravin Ratan, Thierry Alcindor, Patrick Schöffski, Winette T. van der Graaf, Breelyn A. Wilky, Richard F. Riedel, et al. 2023. "Nirogacestat, a -Secretase Inhibitor for Desmoid Tumors." *The New England Journal of Medicine* 388 (10): 898–912. https://doi.org/10.1056/NEJMoa2210140.

Graaf, G. W. de, A. A. Ayantunde, S. L. Parsons, J. P. Duffy, and N. T. Welch. 2007. "The Role of Staging Laparoscopy in Oesophagogastric Cancers." *European Journal of Surgical Oncology: The Journal of the European Society of Surgical Oncology and the British Association of Surgical Oncology* 33 (8): 988–92. https://doi.org/10.1016/j.ejso.2007.01.007.

Guttmann, David M., Nandita Mitra, Justin Bekelman, James M. Metz, John Plastaras, Weiwei Feng, and Samuel Swisher-McClure. 2017. "Improved Overall Survival with Aggressive Primary Tumor Radiotherapy for Patients with Metastatic Esophageal Cancer." *Journal of Thoracic Oncology: Official Publication of the International Association for the Study of Lung Cancer* 12

(7): 1131–42. https://doi.org/10.1016/j.jtho.2017.03.026.

Hagen, P. van, M. C. C. M. Hulshof, J. J. B. van Lanschot, E. W. Steyerberg, M. I. van Berge Henegouwen, B. P. L. Wijnhoven, D. J. Richel, et al. 2012. "Preoperative Chemoradiotherapy for Esophageal or Junctional Cancer." *The New England Journal of Medicine* 366 (22): 2074–84. https://doi.org/10.1056/NEJMoa1112088.

Haidry, Rehan J., Jason M. Dunn, Mohammed A. Butt, Matthew G. Burnell, Abhinav Gupta, Sarah Green, Haroon Miah, et al. 2013. "Radiofrequency Ablation and Endoscopic Mucosal Resection for Dysplastic Barrett's Esophagus and Early Esophageal Adenocarcinoma: Outcomes of the UK National Halo RFA Registry." *Gastroenterology* 145 (1): 87–95. https://doi.org/10.1053/j.gastro.2013.03.045.

Hansford, Samantha, Pardeep Kaurah, Hector Li-Chang, Michelle Woo, Janine Senz, Hugo Pinheiro, Kasmintan A. Schrader, et al. 2015. "Hereditary Diffuse Gastric Cancer Syndrome: CDH1 Mutations and Beyond." *JAMA Oncology* 1 (1): 23–32. https://doi.org/10.1001/jamaoncol.2014.168.

Hardacker, Thomas J., DuyKhanh Ceppa, Ikenna Okereke, Karen M. Rieger, Shadia I. Jalal, Julia K. LeBlanc, John M. DeWitt, Kenneth A. Kesler, and Thomas J. Birdas. 2014. "Treatment of Clinical T2N0M0 Esophageal Cancer." *Annals of Surgical Oncology* 21 (12): 3739–43. https://doi.org/10.1245/s10434-014-3929-6.

Heald, R. J., and R. D. Ryall. 1986. "Recurrence and Survival After Total Mesorectal Excision for Rectal Cancer." *Lancet (London, England)* 1 (8496): 1479–82. https://doi.org/10.1016/s0140-6736(86)91510-2.

Hollis, Alexander C., Lauren M. Quinn, James Hodson, Emily Evans, James Plowright, Ruksana Begum, Harriet Mitchell, Mike T. Hallissey, John L. Whiting, and Ewen A. Griffiths. 2017. "Prognostic Significance of Tumor Length in Patients Receiving Esophagectomy for Esophageal Cancer." *Journal of Surgical Oncology* 116 (8): 1114–22. https://doi.org/10.1002/jso.24789.

Hølmebakk, T., B. Bjerkehagen, I. Hompland, S. Stoldt, and K. Boye. 2019. "Relationship Between R1 Resection, Tumour Rupture and Recurrence in Resected Gastrointestinal Stromal Tumour." *The British Journal of Surgery* 106 (4): 419–26. https://doi.org/10.1002/bjs.11027.

Hu, Huabin, Liang Kang, Jianwei Zhang, Zehua Wu, Hui Wang, Meijin Huang, Ping Lan, et al. 2022. "Neoadjuvant PD-1 Blockade with Toripalimab, with or Without Celecoxib, in Mismatch Repair-Deficient or Microsatellite Instability-High, Locally Advanced, Colorectal Cancer (PICC): A Single-Centre, Parallel-Group, Non-Comparative, Randomised, Phase 2 Trial." *The Lancet. Gastroenterology & Hepatology* 7 (1): 38–48. https://doi.org/10.1016/S2468-1253(21)00348-4.

Hulscher, Jan B. F., Johanna W. van Sandick, Angela G. E. M. de Boer, Bas P. L. Wijnhoven, Jan G. P. Tijssen, Paul Fockens, Peep F. M. Stalmeier, et al. 2002. "Extended Transthoracic Resection Compared with Limited Transhiatal Resection for Adenocarcinoma of the Esophagus." *The New England Journal of Medicine* 347 (21): 1662–69. https://doi.org/10.1056/NEJMoa022343.

Irani, Jennifer L., Traci L. Hedrick, Timothy E. Miller, Lawrence Lee, Emily

Steinhagen, Benjamin D. Shogan, Joel E. Goldberg, Daniel L. Feingold, Amy L. Lightner, and Ian M. Paquette. 2023. "Clinical Practice Guidelines for Enhanced Recovery After Colon and Rectal Surgery from the American Society of Colon and Rectal Surgeons and the Society of American Gastrointestinal and Endoscopic Surgeons." *Surgical Endoscopy* 37 (1): 5–30. https://doi.org/10.1007/s00464-022-09758-x.

James, Roger D., Robert Glynne-Jones, Helen M. Meadows, David Cunningham, Arthur Sun Myint, Mark P. Saunders, Timothy Maughan, et al. 2013. "Mitomycin or Cisplatin Chemoradiation with or Without Maintenance Chemotherapy for Treatment of Squamous-Cell Carcinoma of the Anus (ACT II): A Randomised, Phase 3, Open-Label, 2 × 2 Factorial Trial." *The Lancet. Oncology* 14 (6): 516–24. https://doi.org/10.1016/S1470-2045(13)70086-X.

Janjigian, Yelena Y., Salah-Eddin Al-Batran, Zev A. Wainberg, Kei Muro, Daniela Molena, Eric Van Cutsem, Woo Jin Hyung, et al. 2025. "Perioperative Durvalumab in Gastric and Gastroesophageal Junction Cancer." *The New England Journal of Medicine* 393 (3): 217–30. https://doi.org/10.1056/NEJMoa2503701.

Jin, Jing, Yuan Tang, Chen Hu, Li-Ming Jiang, Jun Jiang, Ning Li, Wen-Yang Liu, et al. 2022. "Multicenter, Randomized, Phase III Trial of Short-Term Radiotherapy Plus Chemotherapy Versus Long-Term Chemoradiotherapy in Locally Advanced Rectal Cancer (STELLAR)." *Journal of Clinical Oncology: Official Journal of the American Society of Clinical Oncology* 40 (15): 1681–92. https://doi.org/10.1200/JCO.21.01667.

Kalff, Marianne C., Laura F. C. Fransen, Eline M. de Groot, Suzanne S. Gisbertz, Grard A. P. Nieuwenhuijzen, Jelle P. Ruurda, Rob H. A. Verhoeven, et al. 2022. "Long-Term Survival After Minimally Invasive Versus Open Esophagectomy for Esophageal Cancer: A Nationwide Propensity-Score Matched Analysis." *Annals of Surgery* 276 (6): e749–57. https://doi.org/10.1097/SLA.0000000000004708.

Kalff, Marianne C., Sofie P. G. Henckens, Daan M. Voeten, David J. Heineman, Maarten C. C. M. Hulshof, Hanneke W. M. van Laarhoven, Wietse J. Eshuis, et al. 2022. "Recurrent Disease After Esophageal Cancer Surgery: A Substudy of The Dutch Nationwide Ivory Study." *Annals of Surgery* 276 (5): 806–13. https://doi.org/10.1097/SLA.0000000000005638.

Kapiteijn, E., C. A. Marijnen, I. D. Nagtegaal, H. Putter, W. H. Steup, T. Wiggers, H. J. Rutten, et al. 2001. "Preoperative Radiotherapy Combined with Total Mesorectal Excision for Resectable Rectal Cancer." *The New England Journal of Medicine* 345 (9): 638–46. https://doi.org/10.1056/NEJMoa010580.

Kasper, Bernd, Elizabeth H. Baldini, Sylvie Bonvalot, Dario Callegaro, Kenneth Cardona, Chiara Colombo, Nadège Corradini, et al. 2024. "Current Management of Desmoid Tumors: A Review." *JAMA Oncology* 10 (8): 1121–28. https://doi.org/10.1001/jamaoncol.2024.1805.

Kato, Hiroyuki, Hiroyuki Kuwano, Masanobu Nakajima, Tatsuya Miyazaki, Minako Yoshikawa, Hitoshi Ojima, Katsuhiko Tsukada, Noboru Oriuchi, Tomio Inoue, and Keigo Endo. 2002. "Comparison Between Positron Emission

Tomography and Computed Tomography in the Use of the Assessment of Esophageal Carcinoma." *Cancer* 94 (4): 921–28.

Kelly, Ronan J., Jaffer A. Ajani, Jaroslaw Kuzdzal, Thomas Zander, Eric Van Cutsem, Guillaume Piessen, Guillermo Mendez, et al. 2021. "Adjuvant Nivolumab in Resected Esophageal or Gastroesophageal Junction Cancer." *The New England Journal of Medicine* 384 (13): 1191–1203. https://doi.org/10.1056/NEJMoa2032125.

Khan, Qamar J., and Carol J. Fabian. 2010. "How I Treat Vitamin D Deficiency." *Journal of Oncology Practice* 6 (2): 97–101. https://doi.org/10.1200/JOP.091087.

Kim, Tae Jung, Hyae Young Kim, Kyung Won Lee, and Moon Soo Kim. 2009. "Multimodality Assessment of Esophageal Cancer: Preoperative Staging and Monitoring of Response to Therapy." *Radiographics: A Review Publication of the Radiological Society of North America, Inc* 29 (2): 403–21. https://doi.org/10.1148/rg.292085106.

Kofoed, S. C., A. Muhic, L. Baeksgaard, M. Jendresen, J. Gustafsen, J. Holm, L. Bardram, B. Brandt, J. Brenø, and L. B. Svendsen. 2012. "Survival After Adjuvant Chemoradiotherapy or Surgery Alone in Resectable Adenocarcinoma at the Gastro-Esophageal Junction." *Scandinavian Journal of Surgery: SJS: Official Organ for the Finnish Surgical Society and the Scandinavian Surgical Society* 101 (1): 26–31. https://doi.org/10.1177/145749691210100106.

Kreis, Martin E., R. Ruppert, H. Ptok, J. Strassburg, P. Brosi, A. Lewin, M. R. Schön, et al. 2016. "Use of Preoperative Magnetic Resonance Imaging to Select Patients with Rectal Cancer for Neoadjuvant Chemoradiation–Interim Analysis of the German OCUM Trial (NCT01325649)." *Journal of Gastrointestinal Surgery: Official Journal of the Society for Surgery of the Alimentary Tract* 20 (1): 25-32; discussion 32-33. https://doi.org/10.1007/s11605-015-3011-0.

Lambdin, Jacob, Carrie Ryan, Stephanie Gregory, Kenneth Cardona, Jonathan M. Hernandez, Winan J. van Houdt, and Alessandro Gronchi. 2023. "A Randomized Phase III Study of Neoadjuvant Chemotherapy Followed by Surgery Versus Surgery Alone for Patients with High-Risk Retroperitoneal Sarcoma (STRASS2)." *Annals of Surgical Oncology* 30 (8): 4573–75. https://doi.org/10.1245/s10434-023-13500-9.

Lee, Jeeyun, Do Hoon Lim, Sung Kim, Se Hoon Park, Joon Oh Park, Young Suk Park, Ho Yeong Lim, et al. 2012. "Phase III Trial Comparing Capecitabine Plus Cisplatin Versus Capecitabine Plus Cisplatin with Concurrent Capecitabine Radiotherapy in Completely Resected Gastric Cancer with D2 Lymph Node Dissection: The ARTIST Trial." *Journal of Clinical Oncology: Official Journal of the American Society of Clinical Oncology* 30 (3): 268–73. https://doi.org/10.1200/JCO.2011.39.1953.

Leichman, Lawrence P., Bryan H. Goldman, Pierre O. Bohanes, Heinz J. Lenz, Charles R. Thomas, Kevin G. Billingsley, Christopher L. Corless, et al. 2011. "S0356: A Phase II Clinical and Prospective Molecular Trial with Oxaliplatin, Fluorouracil, and External-Beam Radiation Therapy Before Surgery for Patients with Esophageal Adenocarcinoma." *Journal of Clinical*

Oncology: Official Journal of the American Society of Clinical Oncology 29 (34): 4555–60. https://doi.org/10.1200/JCO.2011.36.7490.

Leong, Trevor, B. Mark Smithers, Karin Haustermans, Michael Michael, Val Gebski, Danielle Miller, John Zalcberg, et al. 2017. "TOPGEAR: A Randomized, Phase III Trial of Perioperative ECF Chemotherapy with or Without Preoperative Chemoradiation for Resectable Gastric Cancer: Interim Results from an International, Intergroup Trial of the AGITG, TROG, EORTC and CCTG." *Annals of Surgical Oncology* 24 (8): 2252–58. https://doi.org/10.1245/s10434-017-5830-6.

Li, Claire Yue, and H. Richard Alexander. 2018. "Peritoneal Metastases from Malignant Mesothelioma." *Surgical Oncology Clinics of North America* 27 (3): 539–49. https://doi.org/10.1016/j.soc.2018.02.010.

Macdonald, J. S., S. R. Smalley, J. Benedetti, S. A. Hundahl, N. C. Estes, G. N. Stemmermann, D. G. Haller, et al. 2001. "Chemoradiotherapy After Surgery Compared with Surgery Alone for Adenocarcinoma of the Stomach or Gastroesophageal Junction." *The New England Journal of Medicine* 345 (10): 725–30. https://doi.org/10.1056/NEJMoa010187.

Maish, Mary S., and Steven R. DeMeester. 2004. "Endoscopic Mucosal Resection as a Staging Technique to Determine the Depth of Invasion of Esophageal Adenocarcinoma." *The Annals of Thoracic Surgery* 78 (5): 1777–82. https://doi.org/10.1016/j.athoracsur.2004.04.064.

Malik, Vinod, Ciaran Johnston, Dermot O'Toole, Julie Lucey, Naoimh O'Farrell, Zieta Claxton, and John V. Reynolds. 2017. "Metabolic Tumor Volume Provides Complementary Prognostic Information to EUS Staging in Esophageal and Junctional Cancer." *Diseases of the Esophagus: Official Journal of the International Society for Diseases of the Esophagus* 30 (3): 1–8. https://doi.org/10.1111/dote.12505.

Mantziari, Styliani, Anastasia Pomoni, John O. Prior, Michael Winiker, Pierre Allemann, Nicolas Demartines, and Markus Schäfer. 2020. "18F- FDG PET/CT-Derived Parameters Predict Clinical Stage and Prognosis of Esophageal Cancer." *BMC Medical Imaging* 20 (1): 7. https://doi.org/10.1186/s12880-019-0401-x.

Margolis, Marc, Pendleton Alexander, Gregory D Trachiotis, Farid Gharagozloo, and Timothy Lipman. 2003. "Percutaneous Endoscopic Gastrostomy Before Multimodality Therapy in Patients with Esophageal Cancer." *The Annals of Thoracic Surgery* 76 (5): 1694–98. https://doi.org/10.1016/S0003-4975(02)04890-7.

Mariette, C., L. Dahan, F. Mornex, E. Maillard, P. A. Thomas, B. Meunier, V. Boige, et al. 2014. "Surgery Alone Versus Chemoradiotherapy Followed by Surgery for Stage I and II Esophageal Cancer: Final Analysis of Randomized Controlled Phase III Trial FFCD 9901." *J Clin Oncol* 32 (23): 2416–22. https://doi.org/10.1200/JCO.2013.53.6532.

Mariette, Christophe, Sheraz R. Markar, Tienhan S. Dabakuyo-Yonli, Bernard Meunier, Denis Pezet, Denis Collet, Xavier B. D'Journo, et al. 2019. "Hybrid Minimally Invasive Esophagectomy for Esophageal Cancer." *New England Journal of Medicine* 380 (2): 152–62. https://doi.org/10.1056/

NEJMoa1805101.

Markar, Sheraz R., Caroline Gronnier, Arnaud Pasquer, Alain Duhamel, Hélène Beal, Jérémie Théreaux, Johan Gagnière, et al. 2016. "Role of Neoadjuvant Treatment in Clinical T2N0M0 Oesophageal Cancer: Results from a Retrospective Multi-Center European Study." *European Journal of Cancer (Oxford, England: 1990)* 56 (March): 59–68. https://doi.org/10.1016/j.ejca.2015.11.024.

Markar, Sheraz R., Alan Karthikesalingam, Marta Penna, and Donald E. Low. 2014. "Assessment of Short-Term Clinical Outcomes Following Salvage Esophagectomy for the Treatment of Esophageal Malignancy: Systematic Review and Pooled Analysis." *Annals of Surgical Oncology* 21 (3): 922–31. https://doi.org/10.1245/s10434-013-3364-0.

Martin, L., and P. Lagergren. 2009. "Long-Term Weight Change After Oesophageal Cancer Surgery." *The British Journal of Surgery* 96 (11): 1308–14. https://doi.org/10.1002/bjs.6723.

McKeown, K. C. 1976. "Total Three-Stage Oesophagectomy for Cancer of the Oesophagus." *The British Journal of Surgery* 63 (4): 259–62. https://doi.org/10.1002/bjs.1800630403.

Mellow, M. H., and H. Pinkas. 1985. "Endoscopic Laser Therapy for Malignancies Affecting the Esophagus and Gastroesophageal Junction. Analysis of Technical and Functional Efficacy." *Archives of Internal Medicine* 145 (8): 1443–46.

MERCURY Study Group. 2006. "Diagnostic Accuracy of Preoperative Magnetic Resonance Imaging in Predicting Curative Resection of Rectal Cancer: Prospective Observational Study." *BMJ (Clinical Research Ed.)* 333 (7572): 779. https://doi.org/10.1136/bmj.38937.646400.55.

Messager, Mathieu, Xavier Mirabel, Emmanuelle Tresch, Amaury Paumier, Véronique Vendrely, Laetitia Dahan, Olivier Glehen, et al. 2016. "Preoperative Chemoradiation with Paclitaxel-Carboplatin or with Fluorouracil-Oxaliplatin-Folinic Acid (FOLFOX) for Resectable Esophageal and Junctional Cancer: The PROTECT-1402, Randomized Phase 2 Trial." *BMC Cancer* 16 (May): 318. https://doi.org/10.1186/s12885-016-2335-9.

Minsky, Bruce D., Thomas F. Pajak, Robert J. Ginsberg, Thomas M. Pisansky, James Martenson, Ritsuko Komaki, Gordon Okawara, Seth A. Rosenthal, and David P. Kelsen. 2002. "INT 0123 (Radiation Therapy Oncology Group 94-05) Phase III Trial of Combined-Modality Therapy for Esophageal Cancer: High-Dose Versus Standard-Dose Radiation Therapy." *Journal of Clinical Oncology: Official Journal of the American Society of Clinical Oncology* 20 (5): 1167–74. https://doi.org/10.1200/JCO.2002.20.5.1167.

Nagtegaal, Iris D., and Phil Quirke. 2008. "What Is the Role for the Circumferential Margin in the Modern Treatment of Rectal Cancer?" *Journal of Clinical Oncology: Official Journal of the American Society of Clinical Oncology* 26 (2): 303–12. https://doi.org/10.1200/JCO.2007.12.7027.

Nakamura, Masaki, Toshiyasu Ojima, Mikihito Nakamori, Masahiro Katsuda, Toshiaki Tsuji, Keiji Hayata, Tomoya Kato, and Hiroki Yamaue. 2019. "Conversion Surgery for Gastric Cancer with Peritoneal Metastasis Based on the

Diagnosis of Second-Look Staging Laparoscopy." *Journal of Gastrointestinal Surgery: Official Journal of the Society for Surgery of the Alimentary Tract* 23 (9): 1758–66. https://doi.org/10.1007/s11605-018-3983-7.

Nigro, Nd, Hg Seydel, B Considine, Vk Vaitkevicius, L Leichman, and Jj Kinzie. 1983. "Combined Preoperative Radiation and Chemotherapy for Squamous Cell Carcinoma of the Anal Canal." *Cancer* 51 (10): 1826. https://doi.org/10.1002/1097-0142(19830515)51:10%3C1826::aid-cncr2820511012%3E3.0.co;2-l.

Nilsson, K., F. Klevebro, B. Sunde, I. Rouvelas, M. Lindblad, E. Szabo, I. Halldestam, et al. 2023. "Oncological Outcomes of Standard Versus Prolonged Time to Surgery After Neoadjuvant Chemoradiotherapy for Oesophageal Cancer in the Multicentre, Randomised, Controlled NeoRes II Trial." *Annals of Oncology: Official Journal of the European Society for Medical Oncology* 34 (11): 1015–24. https://doi.org/10.1016/j.annonc.2023.08.010.

Noh, Sung Hoon, Sook Ryun Park, Han-Kwang Yang, Hyun Cheol Chung, Ik-Joo Chung, Sang-Woon Kim, Hyung-Ho Kim, et al. 2014. "Adjuvant Capecitabine Plus Oxaliplatin for Gastric Cancer After D2 Gastrectomy (CLASSIC): 5-Year Follow-up of an Open-Label, Randomised Phase 3 Trial." *The Lancet. Oncology* 15 (12): 1389–96. https://doi.org/10.1016/S1470-2045(14)70473-5.

Noordman, Bo Jan, Manon C. W. Spaander, Roelf Valkema, Bas P. L. Wijnhoven, Mark I. van Berge Henegouwen, Joël Shapiro, Katharina Biermann, et al. 2018. "Detection of Residual Disease After Neoadjuvant Chemoradiotherapy for Oesophageal Cancer (preSANO): A Prospective Multicentre, Diagnostic Cohort Study." *The Lancet. Oncology* 19 (7): 965–74. https://doi.org/10.1016/S1470-2045(18)30201-8.

Nurkin, Steven J., Hector R. Nava, Sai Yendamuri, Charles M. LeVea, Chumy E. Nwogu, Adrienne Groman, Gregory Wilding, Andrew J. Bain, Steven N. Hochwald, and Nikhil I. Khushalani. 2014. "Outcomes of Endoscopic Resection for High-Grade Dysplasia and Esophageal Cancer." *Surgical Endoscopy* 28 (4): 1090–95. https://doi.org/10.1007/s00464-013-3270-3.

Ohnmacht, G. A., M. S. Allen, S. D. Cassivi, C. Deschamps, F. C. Nichols, and P. C. Pairolero. 2006. "Percutaneous Endoscopic Gastrostomy Risks Rendering the Gastric Conduit Unusable for Esophagectomy." *Diseases of the Esophagus: Official Journal of the International Society for Diseases of the Esophagus* 19 (4): 311–12. https://doi.org/10.1111/j.1442-2050.2006.00588.x.

Omloo, Jikke M. T., Sjoerd M. Lagarde, Jan B. F. Hulscher, Johannes B. Reitsma, Paul Fockens, Herman van Dekken, Fiebo J. W. Ten Kate, Huug Obertop, Hugo W. Tilanus, and J. Jan B. van Lanschot. 2007. "Extended Transthoracic Resection Compared with Limited Transhiatal Resection for Adenocarcinoma of the Mid/Distal Esophagus: Five-Year Survival of a Randomized Clinical Trial." *Annals of Surgery* 246 (6): 992-1000; discussion 1000-1001. https://doi.org/10.1097/SLA.0b013e31815c4037.

Oppedijk, Vera, Ate van der Gaast, Jan J. B. van Lanschot, Pieter van Hagen, Rob van Os, Caroline M. van Rij, Maurice J. van der Sangen, et al. 2014. "Patterns of Recurrence After Surgery Alone Versus Preoperative Chemoradiotherapy and Surgery in the CROSS Trials." *Journal of Clinical Oncology:*

Official Journal of the American Society of Clinical Oncology 32 (5): 385–91. https://doi.org/10.1200/JCO.2013.51.2186.

Orringer, M. B., and H. Sloan. 1978. "Esophagectomy Without Thoracotomy." *The Journal of Thoracic and Cardiovascular Surgery* 76 (5): 643–54.

Orringer, Mark B., Becky Marshall, Andrew C. Chang, Julia Lee, Allan Pickens, and Christine L. Lau. 2007. "Two Thousand Transhiatal Esophagectomies: Changing Trends, Lessons Learned." *Annals of Surgery* 246 (3): 363-372; discussion 372-374. https://doi.org/10.1097/SLA.0b013e31814697f2.

Ouattara, Moussa, Xavier Benoit D'Journo, Anderson Loundou, Delphine Trousse, Laetitia Dahan, Christophe Doddoli, Jean Francois Seitz, and Pascal-Alexandre Thomas. 2012. "Body Mass Index Kinetics and Risk Factors of Malnutrition One Year After Radical Oesophagectomy for Cancer." *European Journal of Cardio-Thoracic Surgery: Official Journal of the European Association for Cardio-Thoracic Surgery* 41 (5): 1088–93. https://doi.org/10.1093/ejcts/ezr182.

Overtoom, Hidde C. G., Ben M. Eyck, Berend J. van der Wilk, Bo J. Noordman, Pieter C. van der Sluis, Bas P. L. Wijnhoven, J. Jan B. van Lanschot, Sjoerd M. Lagarde, and SANO study group*. 2024. "Prolonged Time to Surgery in Patients with Residual Disease After Neoadjuvant Chemoradiotherapy for Esophageal Cancer." *Annals of Surgery*, August. https://doi.org/10.1097/SLA.0000000000006488.

Paradis, Tiffany, Stephan Robitaille, Anna Wang, Camille Gervais, A. Sender Liberman, Patrick Charlebois, Barry L. Stein, Julio F. Fiore, Liane S. Feldman, and Lawrence Lee. 2024. "Predictive Factors for Successful Same-Day Discharge After Minimally Invasive Colectomy and Stoma Reversal." *Diseases of the Colon and Rectum* 67 (4): 558–65. https://doi.org/10.1097/DCR.0000000000003149.

Paty, P. B., W. E. Enker, A. M. Cohen, and G. Y. Lauwers. 1994. "Treatment of Rectal Cancer by Low Anterior Resection with Coloanal Anastomosis." *Annals of Surgery* 219 (4): 365–73. https://doi.org/10.1097/00000658-199404000-00007.

Pech, O., A. Behrens, A. May, L. Nachbar, L. Gossner, T. Rabenstein, H. Manner, et al. 2008. "Long-Term Results and Risk Factor Analysis for Recurrence After Curative Endoscopic Therapy in 349 Patients with High-Grade Intraepithelial Neoplasia and Mucosal Adenocarcinoma in Barrett's Oesophagus." *Gut* 57 (9): 1200–1206. https://doi.org/10.1136/gut.2007.142539.

Pech, Oliver, Andrea May, Hendrik Manner, Angelika Behrens, Jürgen Pohl, Maren Weferling, Urs Hartmann, et al. 2014. "Long-Term Efficacy and Safety of Endoscopic Resection for Patients with Mucosal Adenocarcinoma of the Esophagus." *Gastroenterology* 146 (3): 652–660.e1. https://doi.org/10.1053/j.gastro.2013.11.006.

Penniment, Michael G., Paolo B. De Ieso, Jennifer A. Harvey, Sonya Stephens, Heather-Jane Au, Christopher J. O'Callaghan, Andrew Kneebone, et al. 2018. "Palliative Chemoradiotherapy Versus Radiotherapy Alone for Dysphagia in Advanced Oesophageal Cancer: A Multicentre Randomised Controlled Trial

(TROG 03.01)." *The Lancet. Gastroenterology & Hepatology* 3 (2): 114–24. https://doi.org/10.1016/S2468-1253(17)30363-1.

Peters, J. H., J. W. Kronson, M. Katz, and T. R. DeMeester. 1995. "Arterial Anatomic Considerations in Colon Interposition for Esophageal Replacement." *Archives of Surgery (Chicago, Ill.: 1960)* 130 (8): 858-862; discussion 862-863. https://doi.org/10.1001/archsurg.1995.01430080060009.

Pettersson, D., E. Lörinc, T. Holm, H. Iversen, B. Cedermark, B. Glimelius, and A. Martling. 2015. "Tumour Regression in the Randomized Stockholm III Trial of Radiotherapy Regimens for Rectal Cancer." *The British Journal of Surgery* 102 (8): 972–978; discussion 978. https://doi.org/10.1002/bjs.9811.

Phoa, K. Nadine, Frederike G. I. van Vilsteren, Bas L. A. M. Weusten, Raf Bisschops, Erik J. Schoon, Krish Ragunath, Grant Fullarton, et al. 2014. "Radiofrequency Ablation Vs Endoscopic Surveillance for Patients with Barrett Esophagus and Low-Grade Dysplasia: A Randomized Clinical Trial." *JAMA* 311 (12): 1209–17. https://doi.org/10.1001/jama.2014.2511.

Pilonis, ND, Tischkowitz M, Fitzgerald Rc, and di Pietro M. 2021. "Hereditary Diffuse Gastric Cancer: Approaches to Screening, Surveillance, and Treatment." *Annual Review of Medicine* 72 (January): 263–80. https://doi.org/10.1146/annurev-med-051019-103216.

Post, Rachel S. van der, Ingrid P. Vogelaar, Fátima Carneiro, Parry Guilford, David Huntsman, Nicoline Hoogerbrugge, Carlos Caldas, et al. 2015. "Hereditary Diffuse Gastric Cancer: Updated Clinical Guidelines with an Emphasis on Germline CDH1 Mutation Carriers." *Journal of Medical Genetics* 52 (6): 361–74. https://doi.org/10.1136/jmedgenet-2015-103094.

Quirke, P., P. Durdey, M. F. Dixon, and N. S. Williams. 1986. "Local Recurrence of Rectal Adenocarcinoma Due to Inadequate Surgical Resection. Histopathological Study of Lateral Tumour Spread and Surgical Excision." *Lancet (London, England)* 2 (8514): 996–99. https://doi.org/10.1016/s0140-6736(86)92612-7.

Rastogi, Amit, Srinivas Puli, Hashem B. El-Serag, Ajay Bansal, Sachin Wani, and Prateek Sharma. 2008. "Incidence of Esophageal Adenocarcinoma in Patients with Barrett's Esophagus and High-Grade Dysplasia: A Meta-Analysis." *Gastrointestinal Endoscopy* 67 (3): 394–98. https://doi.org/10.1016/j.gie.2007.07.019.

Repici, Alessandro, Cesare Hassan, Alessandra Carlino, Nico Pagano, Angelo Zullo, Giacomo Rando, Giuseppe Strangio, et al. 2010. "Endoscopic Submucosal Dissection in Patients with Early Esophageal Squamous Cell Carcinoma: Results from a Prospective Western Series." *Gastrointestinal Endoscopy* 71 (4): 715–21. https://doi.org/10.1016/j.gie.2009.11.020.

Reynolds, J. V., S. R. Preston, B. O'Neill, L. Baeksgaard, S. M. Griffin, C. Mariette, S. Cuffe, et al. 2017. "ICORG 10-14: NEOadjuvant Trial in Adenocarcinoma of the oEsophagus and oesophagoGastric Junction International Study (Neo-AEGIS)." *BMC Cancer* 17 (1): 401. https://doi.org/10.1186/s12885-017-3386-2.

Rice, T. W., D. P. Mason, S. C. Murthy, Jr. Zuccaro G., D. J. Adelstein, L. A. Rybicki, and E. H. Blackstone. 2007. "T2N0M0 Esophageal Cancer." *J*

Thorac Cardiovasc Surg 133 (2): 317–24. https://doi.org/10.1016/j.jtcvs.2006.09.023.

Ripley, R. Taylor, Inderpal S. Sarkaria, Rachel Grosser, Camelia S. Sima, Manjit S. Bains, David R. Jones, Prasad S. Adusumilli, et al. 2016. "Pretreatment Dysphagia in Esophageal Cancer Patients May Eliminate the Need for Staging by Endoscopic Ultrasonography." *The Annals of Thoracic Surgery* 101 (1): 226–30. https://doi.org/10.1016/j.athoracsur.2015.06.062.

Roberts, Maegan E., John Michael O. Ranola, Megan L. Marshall, Lisa R. Susswein, Sara Graceffo, Kelsey Bohnert, Ginger Tsai, Rachel T. Klein, Kathleen S. Hruska, and Brian H. Shirts. 2019. "Comparison of CDH1 Penetrance Estimates in Clinically Ascertained Families Vs Families Ascertained for Multiple Gastric Cancers." *JAMA Oncology* 5 (9): 1325–31. https://doi.org/10.1001/jamaoncol.2019.1208.

Roh, Mark S., Linda H. Colangelo, Michael J. O'Connell, Greg Yothers, Melvin Deutsch, Carmen J. Allegra, Morton S. Kahlenberg, et al. 2009. "Preoperative Multimodality Therapy Improves Disease-Free Survival in Patients with Carcinoma of the Rectum: NSABP R-03." *Journal of Clinical Oncology: Official Journal of the American Society of Clinical Oncology* 27 (31): 5124–30. https://doi.org/10.1200/JCO.2009.22.0467.

Rotellini-Coltvet, Lisa, Alex Wallace, Gia Saini, Sailendra Naidu, Jefferey Scott Kriegshauser, Indravadan Patel, Grace Knuttinen, Sadeer Alzubaidi, and Rahmi Oklu. 2023. "Percutaneous Transesophageal Gastrostomy: Procedural Technique and Outcomes." *Journal of Vascular and Interventional Radiology: JVIR* 34 (11): 1901–7. https://doi.org/10.1016/j.jvir.2023.06.040.

Ruppert, R., T. Junginger, H. Ptok, J. Strassburg, C. A. Maurer, P. Brosi, J. Sauer, et al. 2018. "Oncological Outcome After MRI-Based Selection for Neoadjuvant Chemoradiotherapy in the OCUM Rectal Cancer Trial." *The British Journal of Surgery* 105 (11): 1519–29. https://doi.org/10.1002/bjs.10879.

Rusch, Valerie W. 2004. "Are Cancers of the Esophagus, Gastroesophageal Junction, and Cardia One Disease, Two, or Several?" *Seminars in Oncology* 31 (4): 444–49. https://doi.org/10.1053/j.seminoncol.2004.04.023.

Sarkaria, Inderpal S., Nabil P. Rizk, Manjit S. Bains, Laura H. Tang, David H. Ilson, Bruce I. Minsky, and Valerie W. Rusch. 2009. "Post-Treatment Endoscopic Biopsy Is a Poor-Predictor of Pathologic Response in Patients Undergoing Chemoradiation Therapy for Esophageal Cancer." *Annals of Surgery* 249 (5): 764–67. https://doi.org/10.1097/SLA.0b013e3181a38e9e.

Sauer, R., R. Fietkau, C. Wittekind, P. Martus, C. Rödel, W. Hohenberger, G. Jatzko, et al. 2001. "Adjuvant Versus Neoadjuvant Radiochemotherapy for Locally Advanced Rectal Cancer. A Progress Report of a Phase-III Randomized Trial (Protocol CAO/ARO/AIO-94)." *Strahlentherapie Und Onkologie: Organ Der Deutschen Rontgengesellschaft … [Et Al]* 177 (4): 173–81. https://doi.org/10.1007/pl00002396.

Schrag, Deborah, Qian Shi, Martin R. Weiser, Marc J. Gollub, Leonard B. Saltz, Benjamin L. Musher, Joel Goldberg, et al. 2023. "Preoperative Treatment of Locally Advanced Rectal Cancer." *The New England Journal of Medicine*

389 (4): 322–34. https://doi.org/10.1056/NEJMoa2303269.

Sebag-Montefiore, David, Richard J. Stephens, Robert Steele, John Monson, Robert Grieve, Subhash Khanna, Phil Quirke, et al. 2009. "Preoperative Radiotherapy Versus Selective Postoperative Chemoradiotherapy in Patients with Rectal Cancer (MRC CR07 and NCIC-CTG C016): A Multicentre, Randomised Trial." *The Lancet* 373 (9666): 811–20. https://doi.org/10.1016/S0140-6736(09)60484-0.

Selby, Debbie, Amy Nolen, Cheromi Sittambalam, Karen Johansen, and Robyn Pugash. 2019. "Percutaneous Transesophageal Gastrostomy (PTEG): A Safe and Well-Tolerated Procedure for Palliation of End-Stage Malignant Bowel Obstruction." *Journal of Pain and Symptom Management* 58 (2): 306–10. https://doi.org/10.1016/j.jpainsymman.2019.04.031.

Shaheen, Nicholas J., Gary W. Falk, Prasad G. Iyer, Lauren B. Gerson, and American College of Gastroenterology. 2016. "ACG Clinical Guideline: Diagnosis and Management of Barrett's Esophagus." *The American Journal of Gastroenterology* 111 (1): 30–50; quiz 51. https://doi.org/10.1038/ajg.2015.322.

Shaheen, Nicholas J., Prateek Sharma, Bergein F. Overholt, Herbert C. Wolfsen, Richard E. Sampliner, Kenneth K. Wang, Joseph A. Galanko, et al. 2009. "Radiofrequency Ablation in Barrett's Esophagus with Dysplasia." *The New England Journal of Medicine* 360 (22): 2277–88. https://doi.org/10.1056/NEJMoa0808145.

Sharma, Prateek, Richard Kozarek, and Practice Parameters Committee of American College of Gastroenterology. 2010. "Role of Esophageal Stents in Benign and Malignant Diseases." *The American Journal of Gastroenterology* 105 (2): 258–273; quiz 274. https://doi.org/10.1038/ajg.2009.684.

Siddharthan, Ragavan V., Christian Lanciault, and Vassiliki Liana Tsikitis. 2019. "Anal Intraepithelial Neoplasia: Diagnosis, Screening, and Treatment." *Annals of Gastroenterology* 32 (3): 257–63. https://doi.org/10.20524/aog.2019.0364.

Siewert, J. R., H. J. Stein, and M. Feith. 2006. "Adenocarcinoma of the Esophago-Gastric Junction." *Scandinavian Journal of Surgery: SJS: Official Organ for the Finnish Surgical Society and the Scandinavian Surgical Society* 95 (4): 260–69. https://doi.org/10.1177/145749690609500409.

Singal, Ashwani Kumar, Alexander A. Dekovich, Alda L. Tam, and Michael J. Wallace. 2010. "Percutaneous Transesophageal Gastrostomy Tube Placement: An Alternative to Percutaneous Endoscopic Gastrostomy in Patients with Intra-Abdominal Metastasis." *Gastrointestinal Endoscopy* 71 (2): 402–6. https://doi.org/10.1016/j.gie.2009.10.037.

Slagter, Astrid E., Edwin P. M. Jansen, Hanneke W. M. van Laarhoven, Johanna W. van Sandick, Nicole C. T. van Grieken, Karolina Sikorska, Annemieke Cats, et al. 2018. "CRITICS-II: A Multicentre Randomised Phase II Trial of Neo-Adjuvant Chemotherapy Followed by Surgery Versus Neo-Adjuvant Chemotherapy and Subsequent Chemoradiotherapy Followed by Surgery Versus Neo-Adjuvant Chemoradiotherapy Followed by Surgery in Resectable Gastric Cancer." *BMC Cancer* 18 (1): 877. https://doi.org/10.1186/s12885-

018-4770-2.

Smalley, Stephen R., Jacqueline K. Benedetti, Daniel G. Haller, Scott A. Hundahl, Norman C. Estes, Jaffer A. Ajani, Leonard L. Gunderson, et al. 2012. "Updated Analysis of SWOG-Directed Intergroup Study 0116: A Phase III Trial of Adjuvant Radiochemotherapy Versus Observation After Curative Gastric Cancer Resection." *Journal of Clinical Oncology: Official Journal of the American Society of Clinical Oncology* 30 (19): 2327–33. https://doi.org/10.1200/JCO.2011.36.7136.

Smith, J. Joshua, Oliver S. Chow, Marc J. Gollub, Garrett M. Nash, Larissa K. Temple, Martin R. Weiser, José G. Guillem, et al. 2015. "Organ Preservation in Rectal Adenocarcinoma: A Phase II Randomized Controlled Trial Evaluating 3-Year Disease-Free Survival in Patients with Locally Advanced Rectal Cancer Treated with Chemoradiation Plus Induction or Consolidation Chemotherapy, and Total Mesorectal Excision or Nonoperative Management." *BMC Cancer* 15 (October): 767. https://doi.org/10.1186/s12885-015-1632-z.

Soetikno, Roy, Tonya Kaltenbach, Ronald Yeh, and Takuji Gotoda. 2005. "Endoscopic Mucosal Resection for Early Cancers of the Upper Gastrointestinal Tract." *Journal of Clinical Oncology: Official Journal of the American Society of Clinical Oncology* 23 (20): 4490–98. https://doi.org/10.1200/JCO.2005.19.935.

Speicher, Paul J., Asvin M. Ganapathi, Brian R. Englum, Matthew G. Hartwig, Mark W. Onaitis, Thomas A. D'Amico, and Mark F. Berry. 2014. "Induction Therapy Does Not Improve Survival for Clinical Stage T2N0 Esophageal Cancer." *Journal of Thoracic Oncology: Official Publication of the International Association for the Study of Lung Cancer* 9 (8): 1195–1201. https://doi.org/10.1097/JTO.0000000000000228.

Stahl, Michael, Martin Stuschke, Nils Lehmann, Hans-Joachim Meyer, Martin K. Walz, Siegfried Seeber, Bodo Klump, et al. 2005. "Chemoradiation with and Without Surgery in Patients with Locally Advanced Squamous Cell Carcinoma of the Esophagus." *Journal of Clinical Oncology: Official Journal of the American Society of Clinical Oncology* 23 (10): 2310–17. https://doi.org/10.1200/JCO.2005.00.034.

Stahl, Michael, Martin K. Walz, Martin Stuschke, Nils Lehmann, Hans-Joachim Meyer, Jorge Riera-Knorrenschild, Peter Langer, et al. 2009. "Phase III Comparison of Preoperative Chemotherapy Compared with Chemoradiotherapy in Patients with Locally Advanced Adenocarcinoma of the Esophagogastric Junction." *Journal of Clinical Oncology: Official Journal of the American Society of Clinical Oncology* 27 (6): 851–56. https://doi.org/10.1200/JCO.2008.17.0506.

Strassburg, Joachim, Reinhard Ruppert, Henry Ptok, Christoph Maurer, Theodor Junginger, Susanne Merkel, and Paul Hermanek. 2011. "MRI-Based Indications for Neoadjuvant Radiochemotherapy in Rectal Carcinoma: Interim Results of a Prospective Multicenter Observational Study." *Annals of Surgical Oncology* 18 (10): 2790–99. https://doi.org/10.1245/s10434-011-1704-5.

Sudo, Kazuki, Takashi Taketa, Arlene M. Correa, Maria-Claudia Campagna, Roopma Wadhwa, Mariela A. Blum, Ritsuko Komaki, et al. 2013. "Lo-

coregional Failure Rate After Preoperative Chemoradiation of Esophageal Adenocarcinoma and the Outcomes of Salvage Strategies." *Journal of Clinical Oncology: Official Journal of the American Society of Clinical Oncology* 31 (34): 4306–10. https://doi.org/10.1200/JCO.2013.51.7250.

Sudo, Kazuki, Lianchun Xiao, Roopma Wadhwa, Hironori Shiozaki, Elena Elimova, Takashi Taketa, Mariela A. Blum, et al. 2014. "Importance of Surveillance and Success of Salvage Strategies After Definitive Chemoradiation in Patients with Esophageal Cancer." *Journal of Clinical Oncology: Official Journal of the American Society of Clinical Oncology* 32 (30): 3400–3405. https://doi.org/10.1200/JCO.2014.56.7156.

Swedish Rectal Cancer Trial, B. Cedermark, M. Dahlberg, B. Glimelius, L. Påhlman, L. E. Rutqvist, and N. Wilking. 1997. "Improved Survival with Preoperative Radiotherapy in Resectable Rectal Cancer." *The New England Journal of Medicine* 336 (14): 980–87. https://doi.org/10.1056/NEJM199704033361402.

Swisher, Stephen G., Paula Wynn, Joe B. Putnam, Melinda B. Mosheim, Arlene M. Correa, Ritsuko R. Komaki, Jaffer A. Ajani, et al. 2002. "Salvage Esophagectomy for Recurrent Tumors After Definitive Chemotherapy and Radiotherapy." *The Journal of Thoracic and Cardiovascular Surgery* 123 (1): 175–83. https://doi.org/10.1067/mtc.2002.119070.

Taketa, Takashi, Arlene M. Correa, Akihiro Suzuki, Mariela A. Blum, Pamela Chien, Jeffrey H. Lee, James Welsh, et al. 2012. "Outcome of Trimodality-Eligible Esophagogastric Cancer Patients Who Declined Surgery After Preoperative Chemoradiation." *Oncology* 83 (5): 300–304. https://doi.org/10.1159/000341353.

Taketa, Takashi, Kazuki Sudo, Arlene M. Correa, Roopma Wadhwa, Hironori Shiozaki, Elena Elimova, Maria-Claudia Campagna, et al. 2014. "Post-Chemoradiation Surgical Pathology Stage Can Customize the Surveillance Strategy in Patients with Esophageal Adenocarcinoma." *Journal of the National Comprehensive Cancer Network: JNCCN* 12 (8): 1139–44. https://doi.org/10.6004/jnccn.2014.0111.

Taketa, Takashi, Lianchun Xiao, Kazuki Sudo, Akihiro Suzuki, Roopma Wadhwa, Mariela A. Blum, Jeffrey H. Lee, et al. 2013. "Propensity-Based Matching Between Esophagogastric Cancer Patients Who Had Surgery and Who Declined Surgery After Preoperative Chemoradiation." *Oncology* 85 (2): 95–99. https://doi.org/10.1159/000351999.

Taylor, Fiona G. M., Philip Quirke, Richard J. Heald, Brendan J. Moran, Lennart Blomqvist, Ian R. Swift, David Sebag-Montefiore, Paris Tekkis, Gina Brown, and Magnetic Resonance Imaging in Rectal Cancer European Equivalence Study Study Group. 2014. "Preoperative Magnetic Resonance Imaging Assessment of Circumferential Resection Margin Predicts Disease-Free Survival and Local Recurrence: 5-Year Follow-up Results of the MERCURY Study." *Journal of Clinical Oncology: Official Journal of the American Society of Clinical Oncology* 32 (1): 34–43. https://doi.org/10.1200/JCO.2012.45.3258.

Taylor, Fiona G. M., Philip Quirke, Richard J. Heald, Brendan Moran, Lennart Blomqvist, Ian Swift, David J. Sebag-Montefiore, Paris Tekkis, Gina Brown,

and MERCURY study group. 2011. "Preoperative High-Resolution Magnetic Resonance Imaging Can Identify Good Prognosis Stage I, II, and III Rectal Cancer Best Managed by Surgery Alone: A Prospective, Multicenter, European Study." *Annals of Surgery* 253 (4): 711–19. https://doi.org/10.1097/SLA.0b013e31820b8d52.

Terheggen, Grischa, Eva Maria Horn, Michael Vieth, Helmut Gabbert, Markus Enderle, Alexander Neugebauer, Brigitte Schumacher, and Horst Neuhaus. 2017. "A Randomised Trial of Endoscopic Submucosal Dissection Versus Endoscopic Mucosal Resection for Early Barrett's Neoplasia." *Gut* 66 (5): 783–93. https://doi.org/10.1136/gutjnl-2015-310126.

Udomsawaengsup, S., S. Brethauer, M. Kroh, and B. Chand. 2008. "Percutaneous Transesophageal Gastrostomy (PTEG): A Safe and Effective Technique for Gastrointestinal Decompression in Malignant Obstruction and Massive Ascites." *Surgical Endoscopy* 22 (10): 2314–18. https://doi.org/10.1007/s00464-008-9984-y.

Vakil, N., A. I. Morris, N. Marcon, A. Segalin, A. Peracchia, N. Bethge, G. Zuccaro, J. J. Bosco, and W. F. Jones. 2001. "A Prospective, Randomized, Controlled Trial of Covered Expandable Metal Stents in the Palliation of Malignant Esophageal Obstruction at the Gastroesophageal Junction." *The American Journal of Gastroenterology* 96 (6): 1791–96. https://doi.org/10.1111/j.1572-0241.2001.03923.x.

Valk, Maxime J. M. van der, Corrie A. M. Marijnen, Boudewijn van Etten, Esmée A. Dijkstra, Denise E. Hilling, Elma Meershoek-Klein Kranenbarg, Hein Putter, et al. 2020. "Compliance and Tolerability of Short-Course Radiotherapy Followed by Preoperative Chemotherapy and Surgery for High-Risk Rectal Cancer - Results of the International Randomized RAPIDO-Trial." *Radiotherapy and Oncology: Journal of the European Society for Therapeutic Radiology and Oncology* 147 (June): 75–83. https://doi.org/10.1016/j.radonc.2020.03.011.

Visbal, A. L., M. S. Allen, D. L. Miller, C. Deschamps, V. F. Trastek, and P. C. Pairolero. 2001. "Ivor Lewis Esophagogastrectomy for Esophageal Cancer." *The Annals of Thoracic Surgery* 71 (6): 1803–8. https://doi.org/10.1016/s0003-4975(01)02601-7.

Vliet, E. P. M. van, M. H. Heijenbrok-Kal, M. G. M. Hunink, E. J. Kuipers, and P. D. Siersema. 2008. "Staging Investigations for Oesophageal Cancer: A Meta-Analysis." *British Journal of Cancer* 98 (3): 547–57. https://doi.org/10.1038/sj.bjc.6604200.

Wang, Xinxin, Shuo Li, Yihong Sun, Kai Li, Xian Shen, Yingwei Xue, Pin Liang, et al. 2021. "The Protocol of a Prospective, Multicenter, Randomized, Controlled Phase III Study Evaluating Different Cycles of Oxaliplatin Combined with S-1 (SOX) as Neoadjuvant Chemotherapy for Patients with Locally Advanced Gastric Cancer: RESONANCE-II Trial." *BMC Cancer* 21 (1): 20. https://doi.org/10.1186/s12885-020-07764-7.

Weaver, Joshua, Priya Rao, John R. Goldblum, Michael J. Joyce, Sondra L. Turner, Alexander J. F. Lazar, Dolores López-Terada, Raymond R. Tubbs, and Brian P. Rubin. 2010. "Can MDM2 Analytical Tests Performed

on Core Needle Biopsy Be Relied Upon to Diagnose Well-Differentiated Liposarcoma?" *Modern Pathology: An Official Journal of the United States and Canadian Academy of Pathology, Inc* 23 (10): 1301–6. https://doi.org/10.1038/modpathol.2010.106.

Wei, Feixue, Catharina J. Alberts, Andreia Albuquerque, and Gary M. Clifford. 2023. "Impact of Human Papillomavirus Vaccine Against Anal Human Papillomavirus Infection, Anal Intraepithelial Neoplasia, and Recurrence of Anal Intraepithelial Neoplasia: A Systematic Review and Meta-Analysis." *The Journal of Infectious Diseases* 228 (11): 1496–1504. https://doi.org/10.1093/infdis/jiad183.

Workum, Frans van, Moniek H. P. Verstegen, Bastiaan R. Klarenbeek, Stefan A. W. Bouwense, Mark I. van Berge Henegouwen, Freek Daams, Suzanne S. Gisbertz, et al. 2021. "Intrathoracic Vs Cervical Anastomosis After Totally or Hybrid Minimally Invasive Esophagectomy for Esophageal Cancer: A Randomized Clinical Trial." *JAMA Surgery* 156 (7): 601–10. https://doi.org/10.1001/jamasurg.2021.1555.

Worrell, Stephanie G., Evan T. Alicuben, Daniel S. Oh, Jeffrey A. Hagen, and Steven R. DeMeester. 2018. "Accuracy of Clinical Staging and Outcome With Primary Resection for Local-Regionally Limited Esophageal Adenocarcinoma." *Annals of Surgery* 267 (3): 484–88. https://doi.org/10.1097/SLA.0000000000002139.

Wouters, M. W. J. M., H. E. Karim-Kos, S. le Cessie, B. P. L. Wijnhoven, L. P. S. Stassen, W. H. Steup, H. W. Tilanus, and R. a. E. M. Tollenaar. 2009. "Centralization of Esophageal Cancer Surgery: Does It Improve Clinical Outcome?" *Annals of Surgical Oncology* 16 (7): 1789–98. https://doi.org/10.1245/s10434-009-0458-9.

Xicola, Rosa M., Shuwei Li, Nicolette Rodriguez, Patrick Reinecke, Rachid Karam, Virginia Speare, Mary Helen Black, Holly LaDuca, and Xavier Llor. 2019. "Clinical Features and Cancer Risk in Families with Pathogenic CDH1 Variants Irrespective of Clinical Criteria." *Journal of Medical Genetics* 56 (12): 838–43. https://doi.org/10.1136/jmedgenet-2019-105991.

Ychou, Marc, Valérie Boige, Jean-Pierre Pignon, Thierry Conroy, Olivier Bouché, Gilles Lebreton, Muriel Ducourtieux, et al. 2011. "Perioperative Chemotherapy Compared with Surgery Alone for Resectable Gastroesophageal Adenocarcinoma: An FNCLCC and FFCD Multicenter Phase III Trial." *Journal of Clinical Oncology: Official Journal of the American Society of Clinical Oncology* 29 (13): 1715–21. https://doi.org/10.1200/JCO.2010.33.0597.

Young, Anne N., Elizabeth Jacob, Patrick Willauer, Levi Smucker, Raul Monzon, and Luis Oceguera. 2020. "Anal Cancer." *The Surgical Clinics of North America* 100 (3): 629–34. https://doi.org/10.1016/j.suc.2020.02.007.

Zhang, J. Q., C. M. Hooker, M. V. Brock, J. Shin, S. Lee, R. How, N. Franco, H. Prevas, A. Hulbert, and S. C. Yang. 2012. "Neoadjuvant Chemoradiation Therapy Is Beneficial for Clinical Stage T2 N0 Esophageal Cancer Patients Due to Inaccurate Preoperative Staging." *Ann Thorac Surg* 93 (2): 429-35; discussion 436-7. https://doi.org/10.1016/j.athoracsur.2011.10.061.

Zhou, Can, Li Zhang, Hua Wang, Xiaoxia Ma, Bohui Shi, Wuke Chen, Jianjun

He, Ke Wang, Peijun Liu, and Yu Ren. 2015. "Superiority of Minimally Invasive Oesophagectomy in Reducing In-Hospital Mortality of Patients with Resectable Oesophageal Cancer: A Meta-Analysis." *PloS One* 10 (7): e0132889. https://doi.org/10.1371/journal.pone.0132889.

Zhu, Clara, Rebecca Platoff, Gaby Ghobrial, Jackson Saddemi, Taylor Evangelisti, Emily Bucher, Benjamin Saracco, et al. 2022. "What to Do When Decompressive Gastrostomies and Jejunostomies Are Not Options? A Scoping Review of Transesophageal Gastrostomy Tubes for Advanced Malignancies." *Annals of Surgical Oncology* 29 (1): 262–71. https://doi.org/10.1245/s10434-021-10667-x.

Zijden, Charlène J. van der, Pieter C. van der Sluis, Bianca Mostert, Joost J. M. E. Nuyttens, J. Jan B. van Lanschot, Manon C. W. Spaander, Roelf Valkema, et al. 2024. "Interval Metastases After Neoadjuvant Chemoradiotherapy for Patients with Locally Advanced Esophageal Cancer: A Multicenter Observational Cohort Study." *Annals of Surgical Oncology* 31 (12): 7759–66. https://doi.org/10.1245/s10434-024-15890-w.