Genetics in Colorectal Cancers

Genetics of Colorectal Cancer

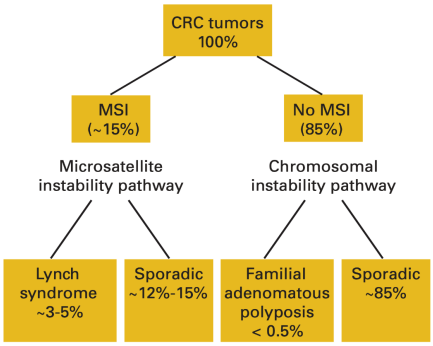

(Chapelle and Hampel 2010)

Lynch Syndrome

- 3% of all colorectal cancers
- Germline mutations of mismatch repair genes
  - *OR* Germline deletions in EPCAM gene
- 80% lifetime risk colorectal cancer
- Early onset ($\tilde{x}$ 45-60yrs)
- Tumors tend to be right-sided

(Eng et al. 2022)

Mismatch Repair Protein Loss in Lynch Syndrome

Lynch Syndrome can be caused by loss of expression of:

- MLH1
- PMS1
- MSH6
- MSH2
- MSH5

Mismatch-repair Deficient Colorectal Cancers

Deficiency in mismatch repair proteins → microsatellite instability

15% of colorectal cancers are MMR-deficient (MSI-High)

- Sporadic - Promoter methylation of MLH1 by BRAF V600E mutation (10%)
- Lynch - Due to mutations in mismatch repair genes (5%) 90% of Lynch tumors are MMR-deficient

Reflex testing for BRAF V600E mutation is essential for MMR-deficient tumors

Mismatch Repair Proteins and Microsatellite Instability

Deficiency in mismatch repair proteins → microsatellite instability

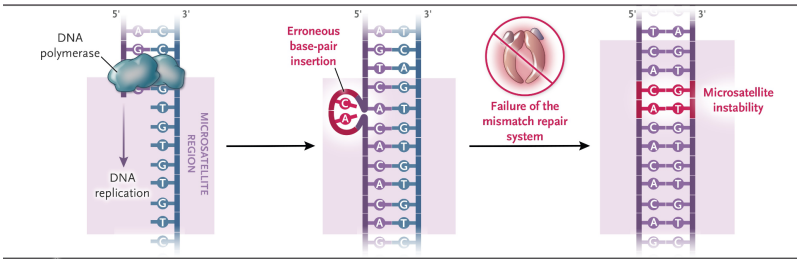

Mismatch Repair and MSI Testing

MMR Protein expression can be detected by immunohistochemistry

- Routine testing of tumor for GI cancers at CMC
- Loss of MLH1 leads to loss of PMS2

Microsatellite Instability can be detected by pCR

- Tumors are not routinely tested for MSI at CMC

97-99%+ concordance between dMMR and MSI-High status

Mismatch Repair -> Microsatellite Instability

Repeat Type	Sequence	Name and Location
Mononucleotide	AGGTAAAAAAAAAAAAAAAAAAAAAAAAAGGGT $(A)_{26}$ shown	*BAT26*, Intron 5 of *MSH2* gene Chromosome 2
Dinucleotide	TGTACACACACACACATCGA $(CA)_{6}$ shown	D5S346 Chromosome 5
Tetranucleotide	ATATTCTATCTATCTATCTATCTATCTG $(TCTA)_{5}$ shown	D14S608 Intergenic region chromosome 14

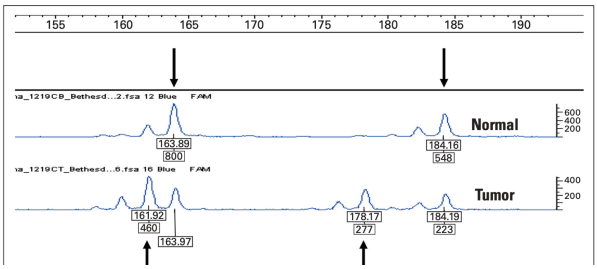

MMR-deficient Tumor Clinical Feaures

- Proximal location
- Poor differentiation
- Mucinous histology
- Better prognosis (in early stage)
- Respond well to immunotherapy (ICI)
- Less responsive to 5-FU chemotherapy (in stage II)

(Taieb et al. 2022)

MMR-deficient Tumors are Immunogenic

Mutational burden from dMMR causes MSI-High tumors to be immunogenic

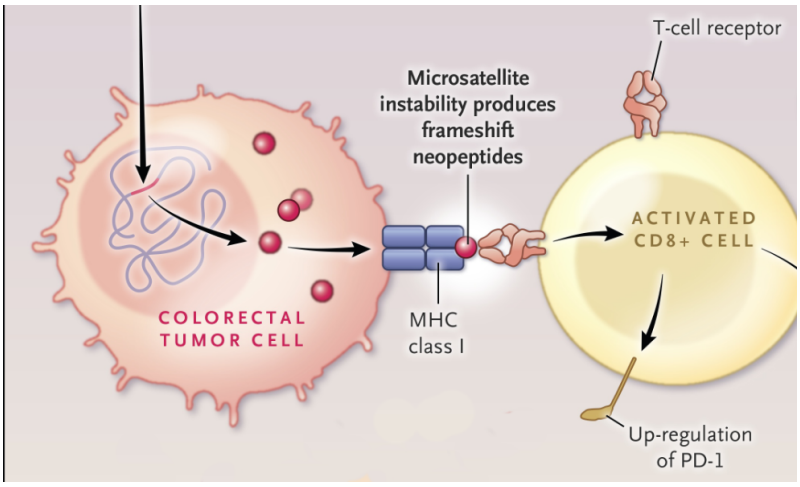

Activated tumor-infiltrating lymphocytes up-regulate PD-1

Tumor PD-L1 Down-regulates Immune Responses

Tumor cells respond to immune activation by ↑ PD-L1

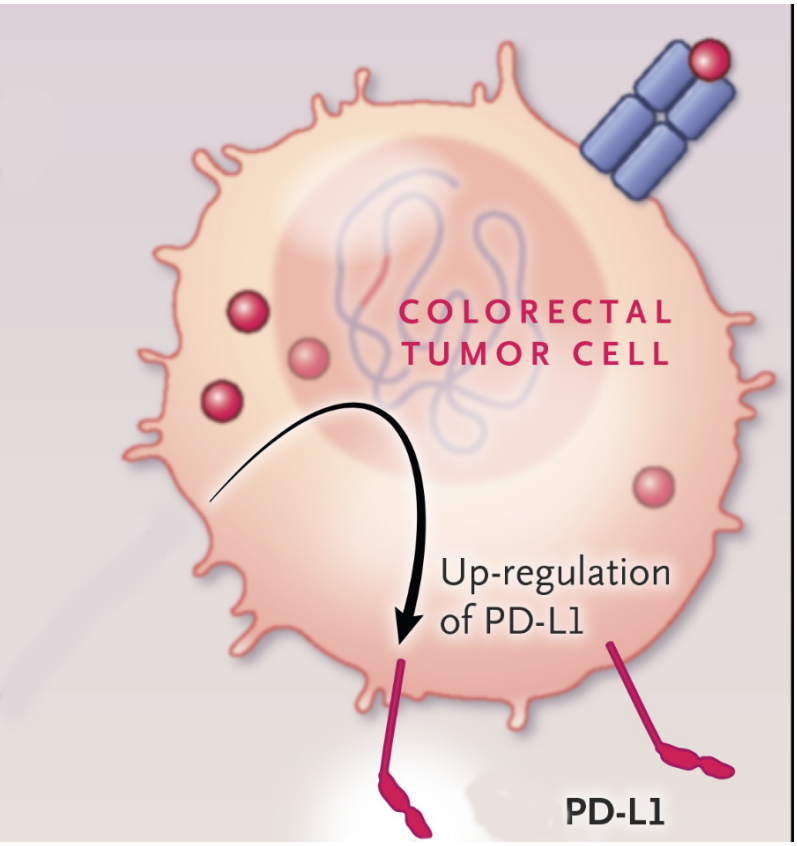
COLORECTAL
TUMOR CELL
Up-regulation
of PD-L1
PD-L1

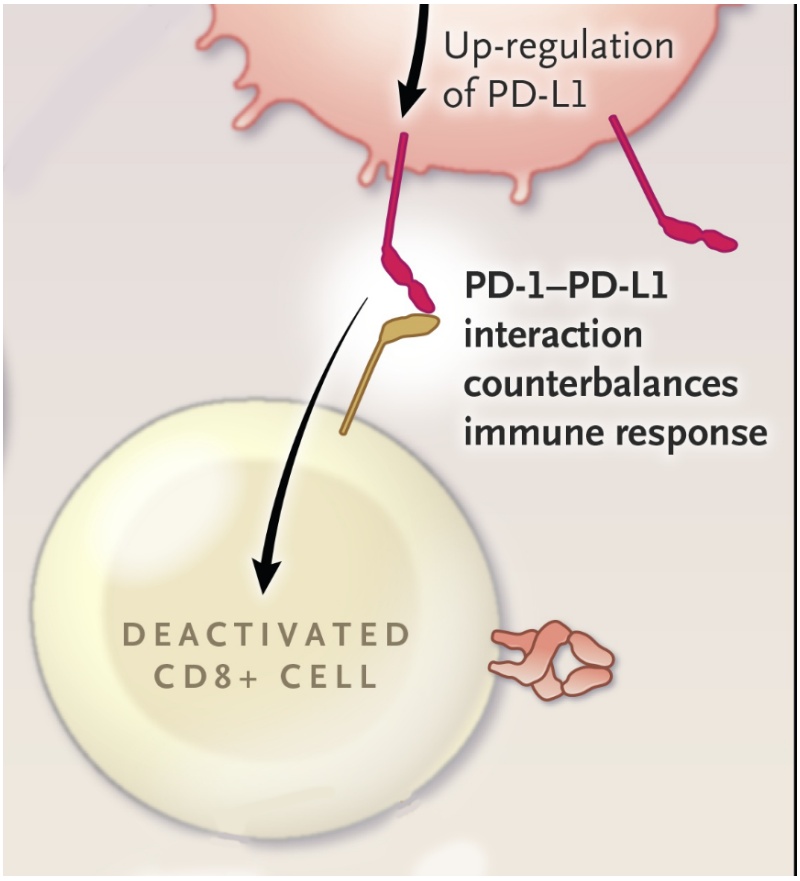

↑ PD-L1 downregulates immune response

Immune Checkpoint Inhibitors

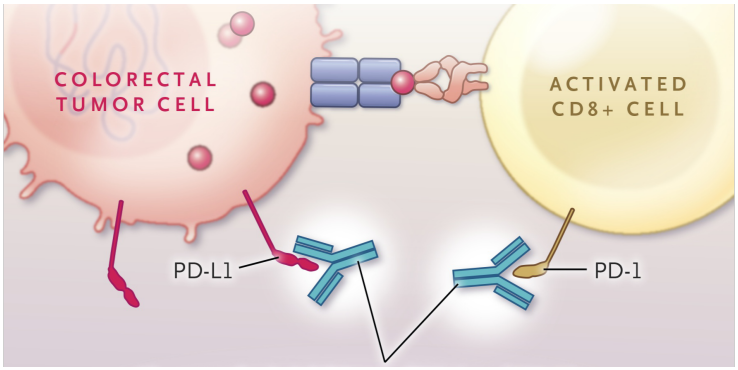

Inhibition of PD-L1 $\leftrightarrow$ PD-1 activates T cells by removing inhibition

PD-L1 expression is higher in MMR-deficient CRC

Immunohistochemistry analysis of 1800 colorectal cancer specimens:

PD-L1 was more often positive in dMMR (18.6%) than in MMR proficient (pMMR) cancers (4.1%; $p < 0.0001$)

(Möller et al. 2021)

MSI-High Colorectal Cancers

Clinical Relevance of Microsatellite Instability in Colorectal Cancer. Journal of Clinical Oncology : Official Journal of the American Society of Clinical Oncology. 2010. de la Chapelle A, Hampel H.

BRAF V600E Colorectal Cancer Features

1. Age >70
2. Female
3. Proximal Right sided tumors
4. MLH1 hypermethylation
5. High grade and poor differentiation
6. More peritoneal and nodal metastasis
7. Less lung metastais

Neoadjuvant Rx for MMR-deficient Colon Cancer - NICHE

115 colon cancer: neoadjuvant nivolumab + ipilimumab /*rightarrow* surgery

109 patients had a pathological response

105 Major pathological respoinse (TRG1 or TRG2)

- 75 pathological complete response

No recurrence of disease at median follow up of 26 months

(Chalabi et al. 2024)

Adjuvant Therapy Stage II MMR-deficient Colon Cancer

ASCO: No benefit of treatment of stage II dMMR colon cancer with 5-FU alone

Ppooled analyses showing no difference in disease-free survival (HR 0.89, 95% CI 0.45-1.74) or overall survival (HR 1.03, 95% CI 0.53-2.02) with adjuvant chemotherapy in this population.

(Ribic et al. 2003)

Adjuvant Therapy of Stage III MMR-deficient Colon Cancer

Oxaliplatin-based chemotherapy (FOLFOX or CapeOX) and atezolizumab (Tecentriq)

ATOMIC trial: atezolizumab + mFOLFOX6 is superior to mFOLFOX6 alone, with a 3-year disease-free survival rate of 86.4% versus 76.6% (hazard ratio 0.50, P .0001)

FAP screening

Colonoscopy age 10-12 EGD for duodenal polyps at age 20-30 CT 1-3 years after colectomy and q5 yers in those with family hx of desmoids

Lynch Non-Colorectal Cancers

- Endometrial (25-60% penetrance)
- Stomach
- Ovarian
- Urinary tract
- Biliary Tract
- Small bowel
- Male breast cancer (1.2% penetrance vs 0.1%)

(Sinicrope 2018)

Lynch Screening

Colonoscopy q1-2 years staring age 20-25

Colon Polyposis: >10 adenomatous polyps

- Classical FAP
- Attenuated FAP (AFAP)
- MUTYH-associated polyposis (MAP)
- Colonic adenomatous polyposis of unknown etiology (CPUE)

Colon Polyposis: >4 hamartomatous polyps

- Puetz-Jaghers
- Juvenile Polyposis Syndrome
- Cowden Syndrome/PTEN Hamartoma Tumor Syndrome

Serrated Colon Polyps

5 serrated polyps/lesions proximal to the rectum, all being 5 mm in size, with 2 being 10 mm in size OR >20 serrated polyps/lesions of any size distributed throughout the large bowel, with 5 being proximal to the rectum

FAP

(FAP) is caused by germline mutations in the APC gene and leads to the development of hundreds to thousands of colorectal adenomas, with nearly 100% risk of colorectal cancer if untreated.

Attenuated FAP

~30 polyps 70% penetrance by age 80 - mean age at dx 50-55

References

Chalabi, Myriam, Yara L. Verschoor, Pedro Batista Tan, et al. 2024. "Neoadjuvant Immunotherapy in Locally Advanced Mismatch Repair-Deficient Colon Cancer." *The New England Journal of Medicine* 390 (21): 1949–58. https://doi.org/10.1056/NEJMoa2400634.

Chapelle, Albert de la, and Heather Hampel. 2010. "Clinical Relevance of Microsatellite Instability in Colorectal Cancer." *Journal of Clinical Oncology: Official Journal of the American Society of Clinical Oncology* 28 (20): 3380–87. https://doi.org/10.1200/JCO.2009.27.0652.

Eng, Cathy, Alexandre A. Jácome, Rajiv Agarwal, et al. 2022. "A Comprehensive Framework for Early-Onset Colorectal Cancer Research." *The Lancet. Oncology* 23 (3): e116–28. https://doi.org/10.1016/S1470-2045(21)00588-X.

Möller, Katharina, Niclas C. Blessin, Doris Höflmayer, et al. 2021. "High Density of Cytotoxic T-Lymphocytes Is Linked to Tumoral PD-L1 Expression Regardless of the Mismatch Repair Status in Colorectal Cancer." *Acta Oncologica (Stockholm, Sweden)* 60 (9): 1210–17. https://doi.org/10.1080/0284186X.2021.1933585.

Ribic, Christine M., Daniel J. Sargent, Malcolm J. Moore, et al. 2003. "Tumor Microsatellite-Instability Status as a Predictor

of Benefit from Fluorouracil-Based Adjuvant Chemotherapy for Colon Cancer." *The New England Journal of Medicine* 349 (3): 247–57. https://doi.org/10.1056/NEJMoa022289.

Sinicrope, Frank A. 2018. "Lynch Syndrome-Associated Colorectal Cancer." *The New England Journal of Medicine* 379 (8): 764–73. https://doi.org/10.1056/NEJMcp1714533.

Taieb, Julien, Magali Svrcek, Romain Cohen, Debora Basile, David Tougeron, and Jean-Marc Phelip. 2022. "Deficient Mismatch Repair/Microsatellite Unstable Colorectal Cancer: Diagnosis, Prognosis and Treatment." *European Journal of Cancer* (Oxford, England : 1990) 175 (November): 136–57. https://doi.org/10.1016/j.ejca.2022.07.020.