One Stage Esophagectomy

2 Stage Ivor Lewis Esophagectomy

Abdominal Phase

- Mobilize stomach
- Divide Left Gastric
- Create conduit
- Transpose conduit $\rightarrow$ chest

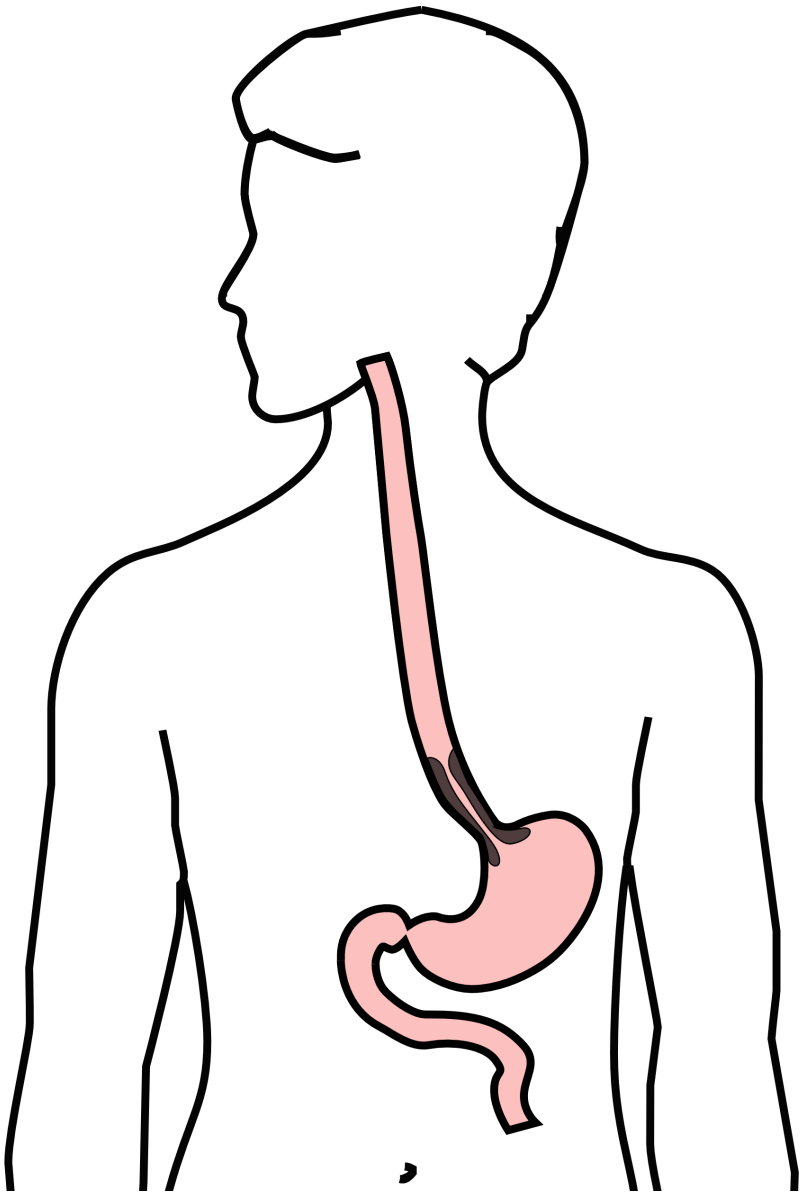

2 Stage Ivor Lewis Esophagectomy

Abdominal Phase

- Mobilize stomach
- Divide Left Gastric
- Create conduit

- Transpose conduit → chest

Chest Phase

- Create anastomosis
- Extract specimen through mini-thoracotomy

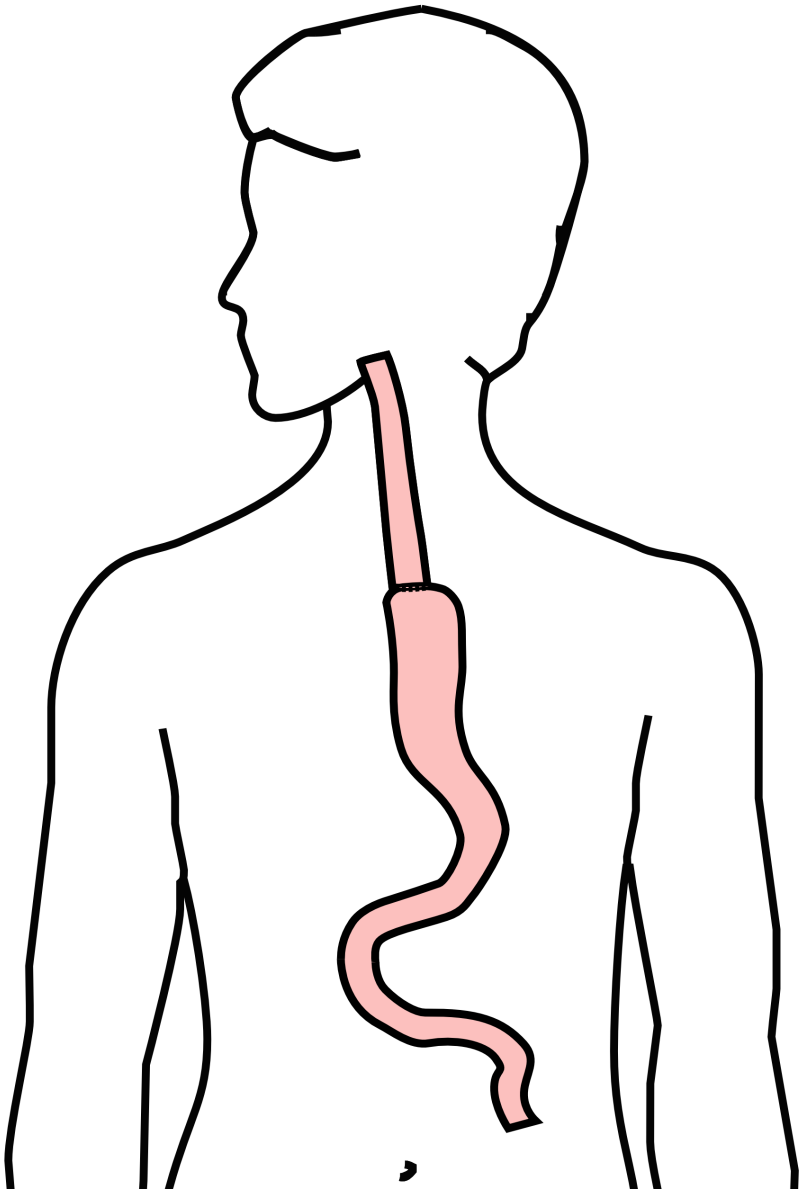

2 Stage Ivor Lewis Esophagectomy - Conduit

- Intracorporeal conduit construction
- Limitations on stretch of stomach
- Limited ability to identify cardia/lesser curve tumors

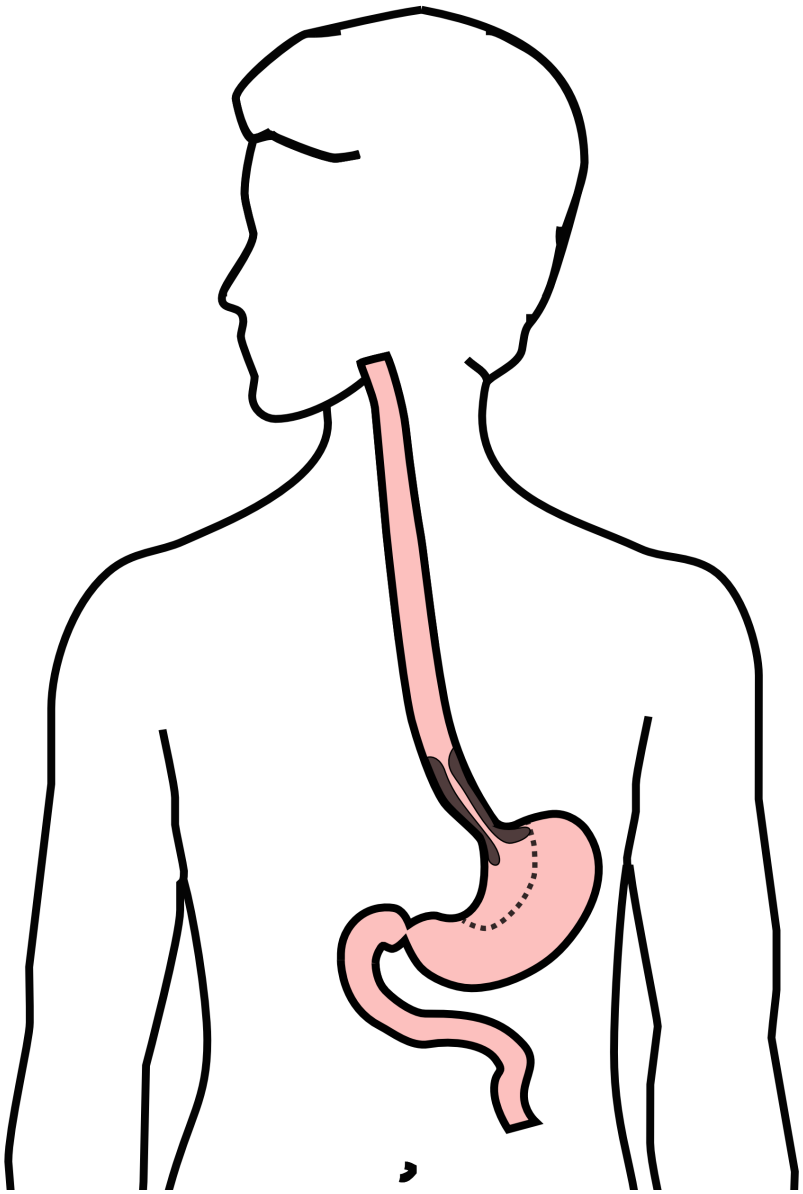

One Stage Esophagectomy "corkscrew"

Allows simultaneous access to abdomen and chest in one prep

Divide esophagus in chest → extra-corporeal construction of conduit → Anastomosis

Extracorporeal construction of conduit:

- Less risk of positive distal margin
- Longer conduit (stretch during construction)

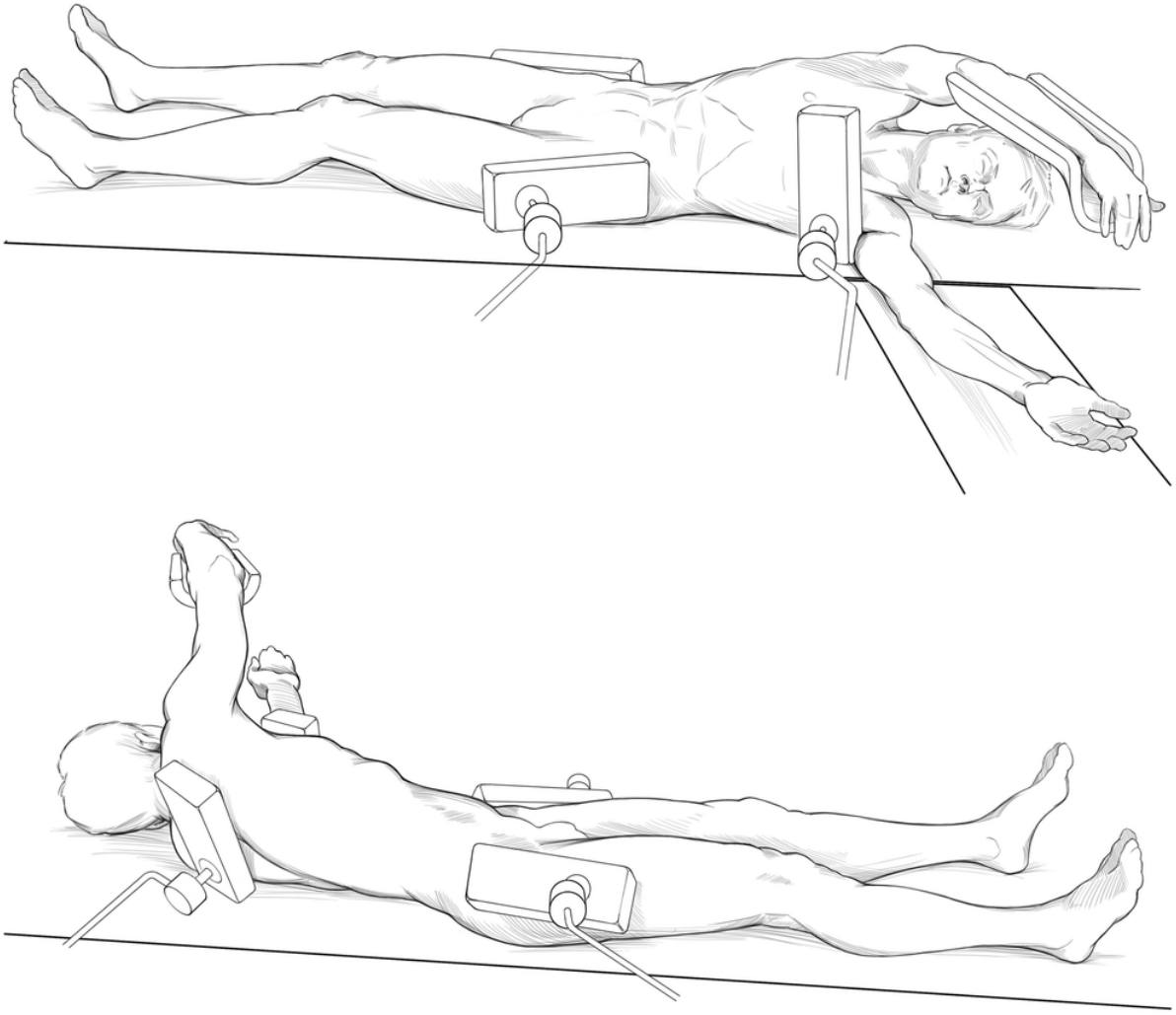

Abdominal Phase I

- Stomach mobilized

- Left gastric artery divided
- Hiatus dissected
- Esophagus looped with Penrose
- Transhiatal drain placed in left and right pleurae

Chest Phase I

- Esophagus dissected from hiatus → cephalad
- Esophagus divided

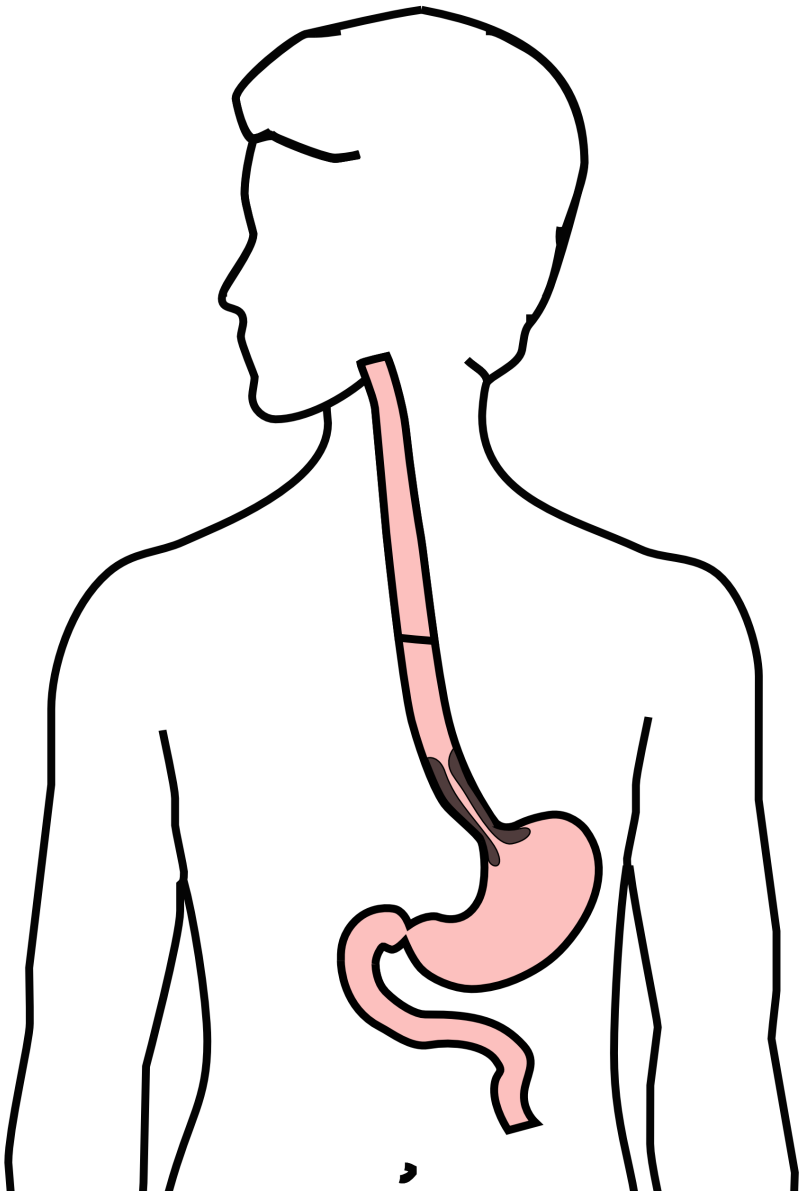

Abdominal Phase II

- Stomach exteriorized
- Pyloromyotomy
- Conduit constructed

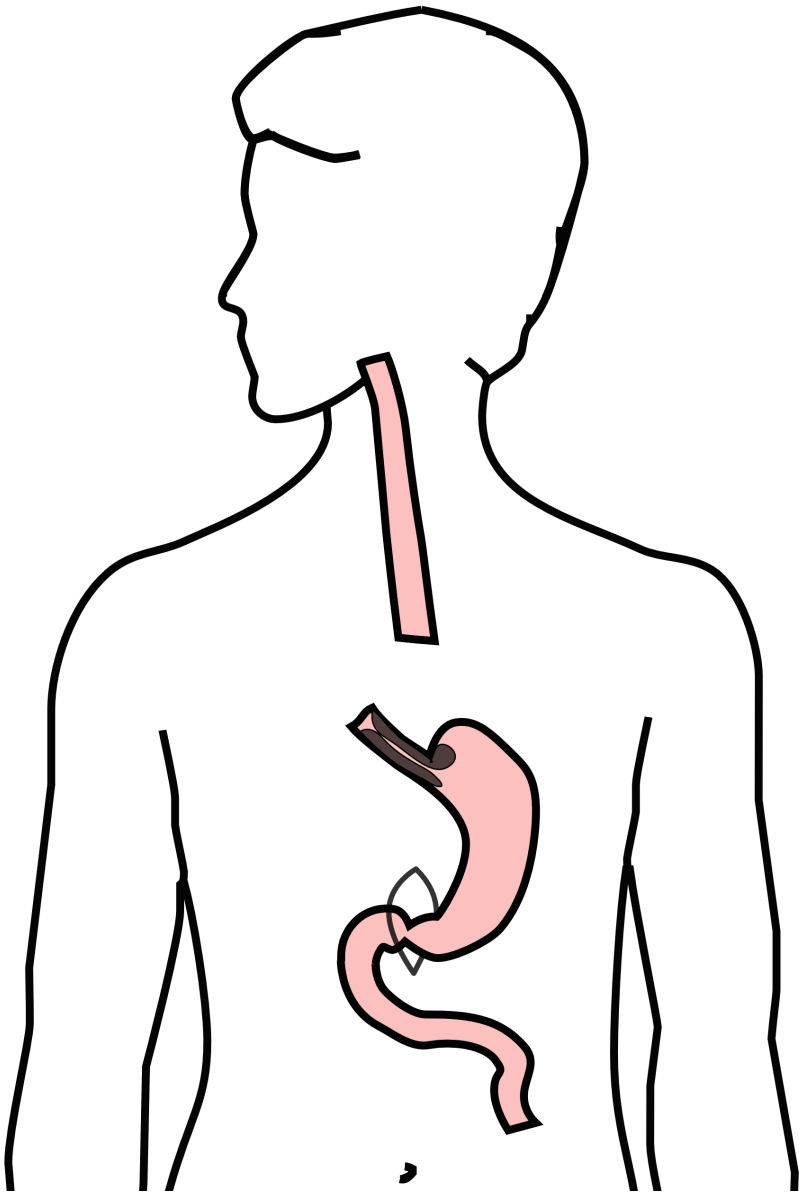

Abdominal Phase II

- Stomach exteriorized
- Pyloromyotomy
- Conduit constructed
  - Place stomach on stretch

– Palpate GE junction/lesser curvature

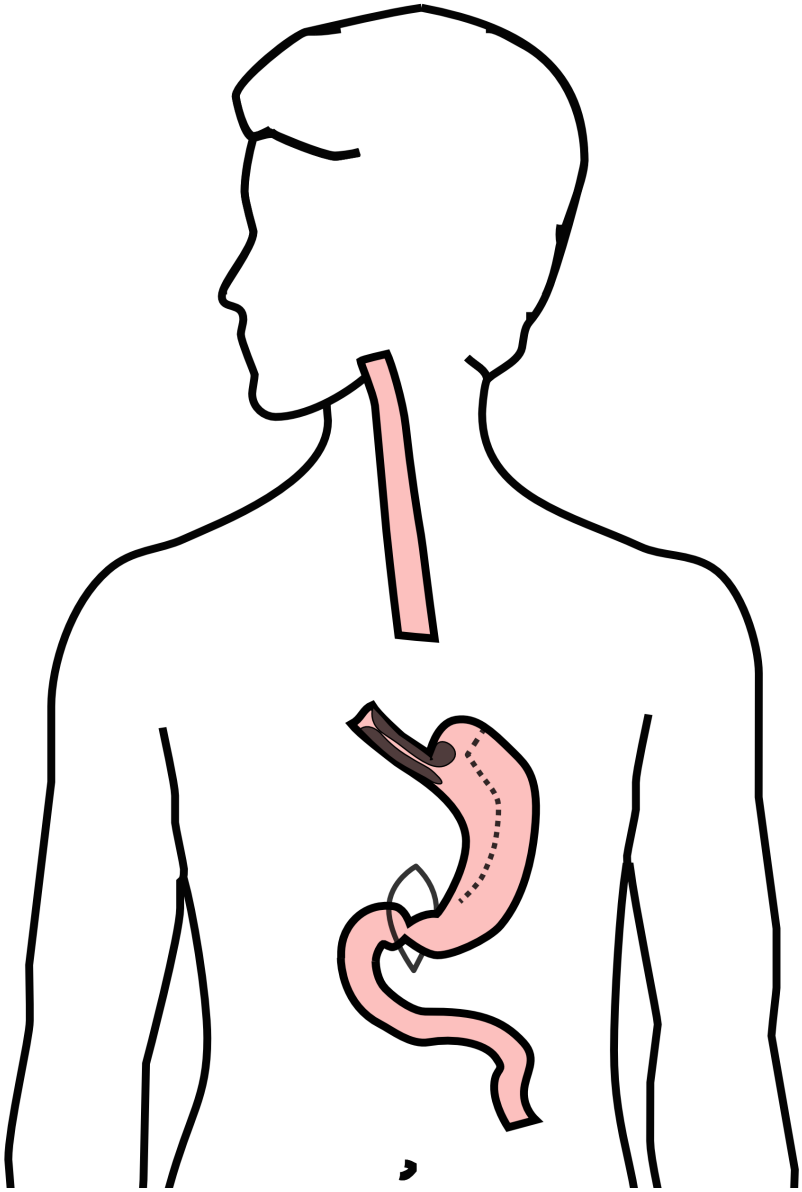

Abdominal Phase II

- Stomach exteriorized
- Pyloromyotomy
- Conduit constructed

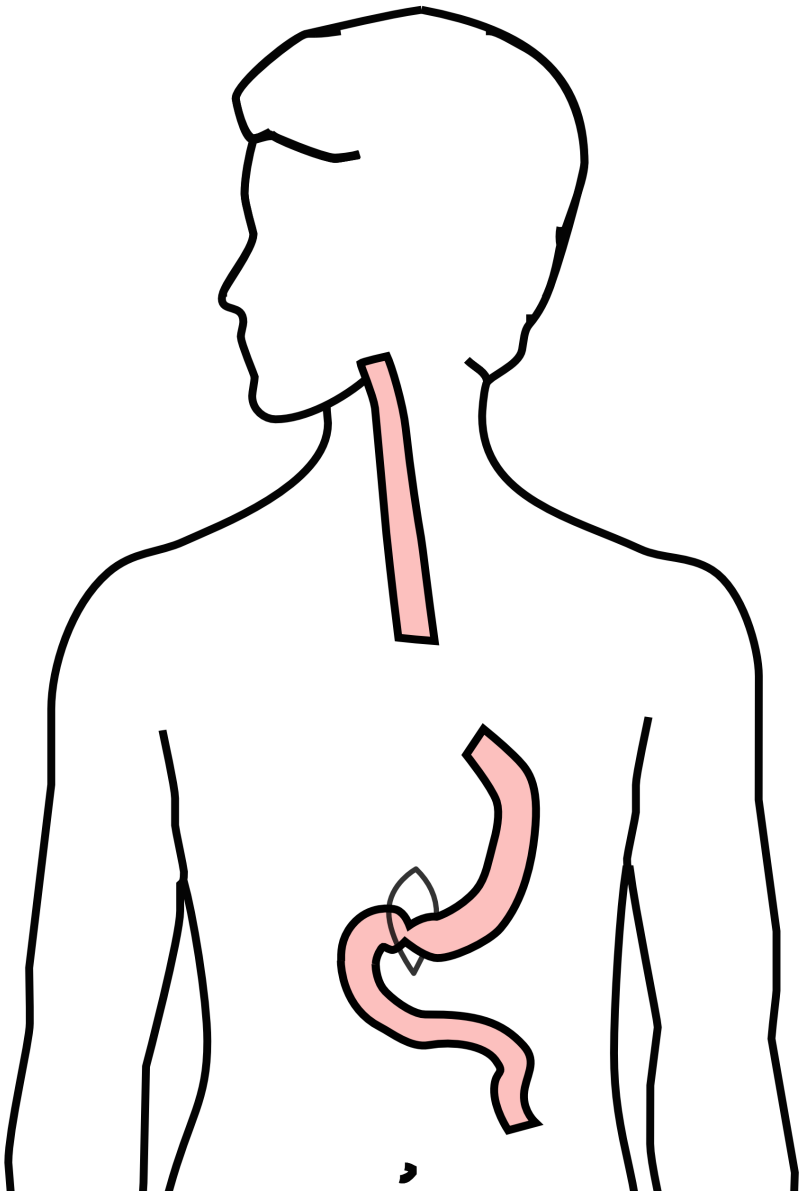

Chest Phase II
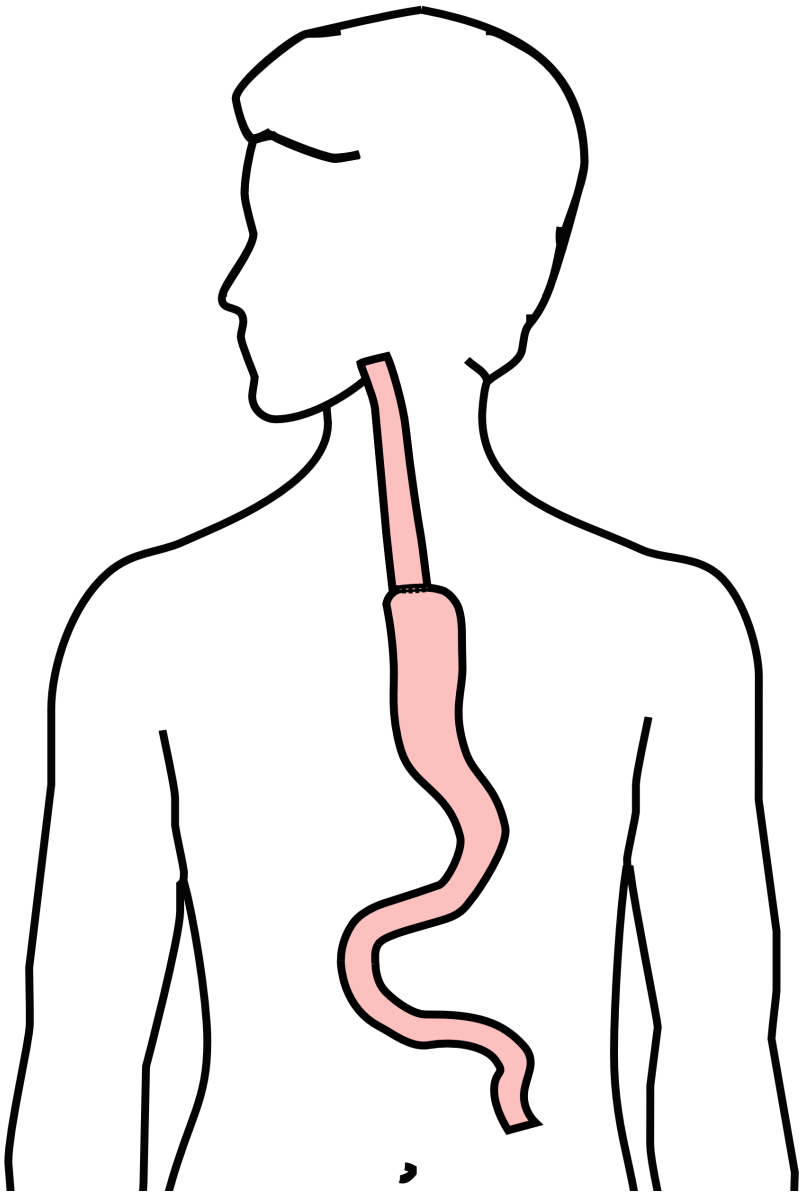
Anastomosis completed