Robot-assisted Esophagectomy

2 Stage Ivor Lewis Esophagectomy

Abdominal Phase

- Mobilize stomach
- Divide Left Gastric
- Celiac lymph node dissection
- Create conduit
- Transpose conduit $\rightarrow$ chest

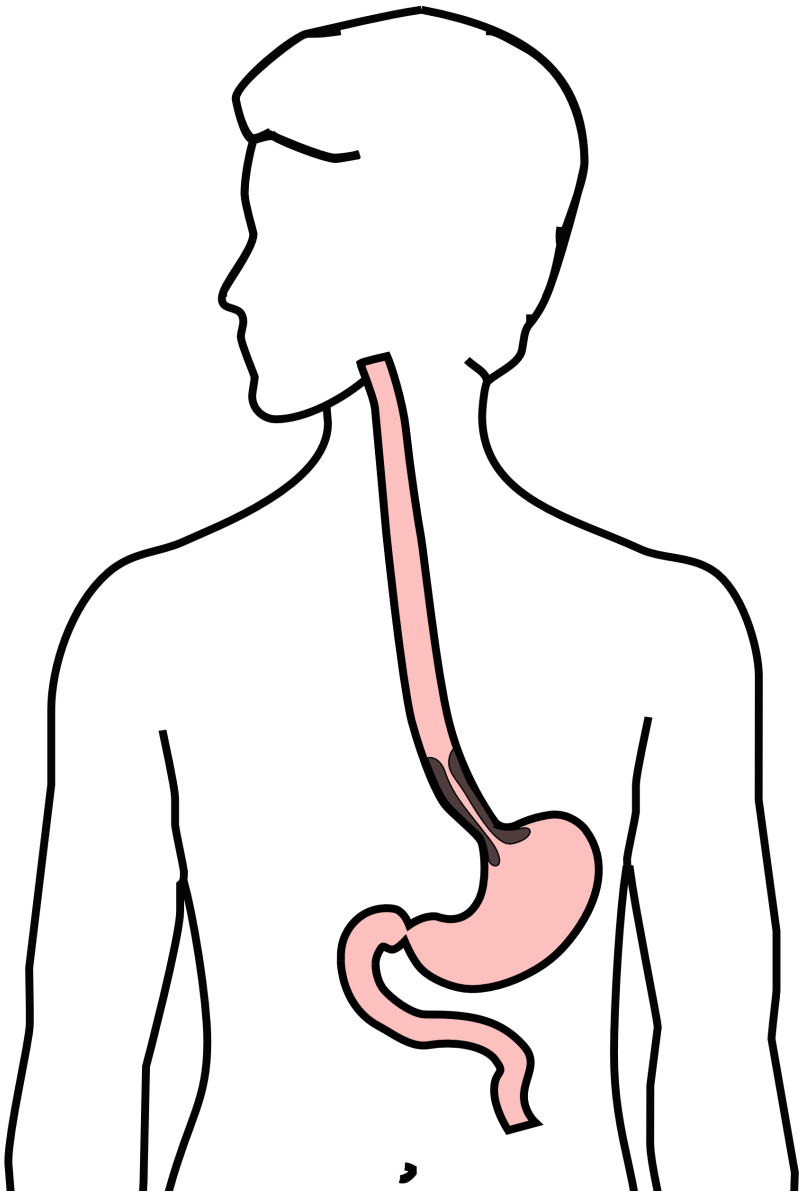

Minimally-invasive Ivor Lewis Esophagectomy

Abdominal Phase

- Mobilize stomach
- Divide Left Gastric
- Create conduit (intracorporeal)

- Suture conduit to GE junction

Chest Phase

- Extract specimen through mini-thoracotomy
- Construct anastomosis

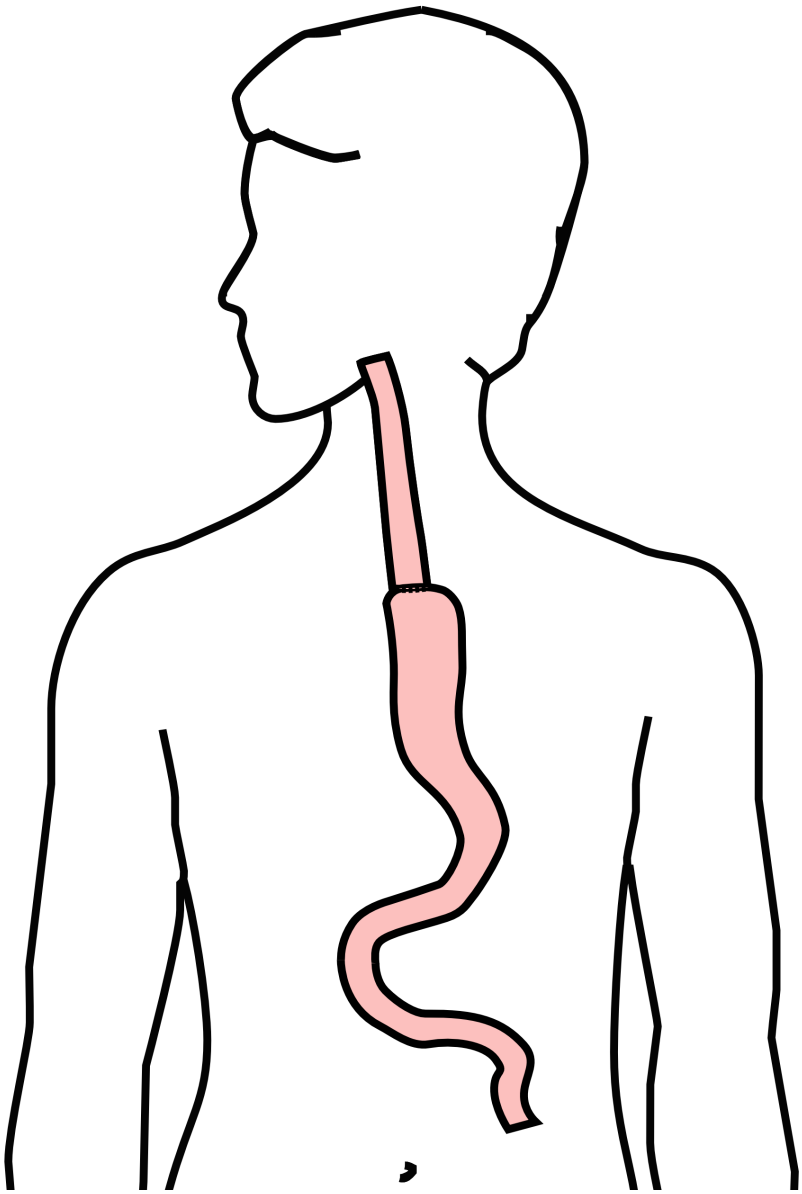

Minimally-invasive Ivor Lewis Esophagectomy - Conduit

- Intracorporeal conduit construction
- Limitations on stretch of stomach
- Limited ability to identify cardia/lesser curve tumors

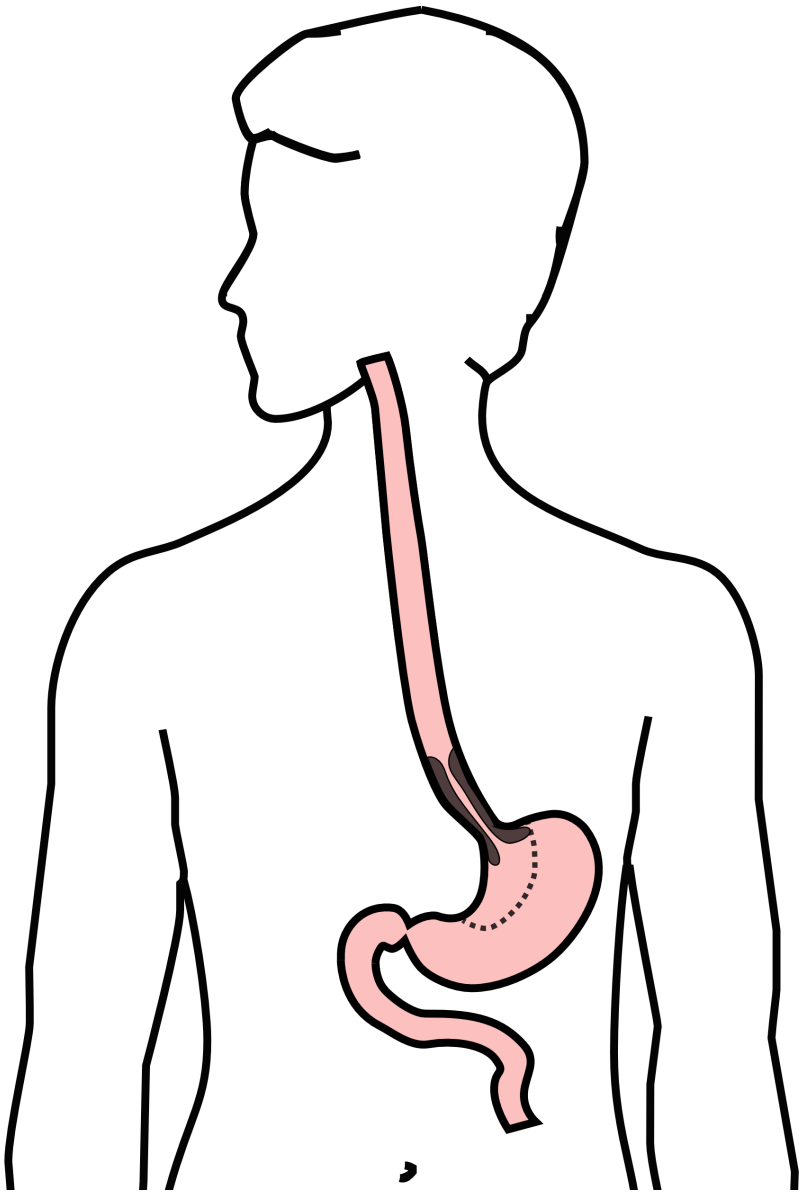

One Stage Esophagectomy "corkscrew"

Allows simultaneous access to abdomen and chest in one prep

- Abdomen I: Mobilize stomach→ Dissect hiatus
- Chest I: Dissect esophagus → Divide esophagus
- Abdomen II: Extract specimen → Construct conduit → Transpose conduit
- Chest II: Anastomosis (circular stapler)

Extracorporeal construction of conduit:

- Less risk of positive distal margin
- Longer conduit (↑stretch during construction)

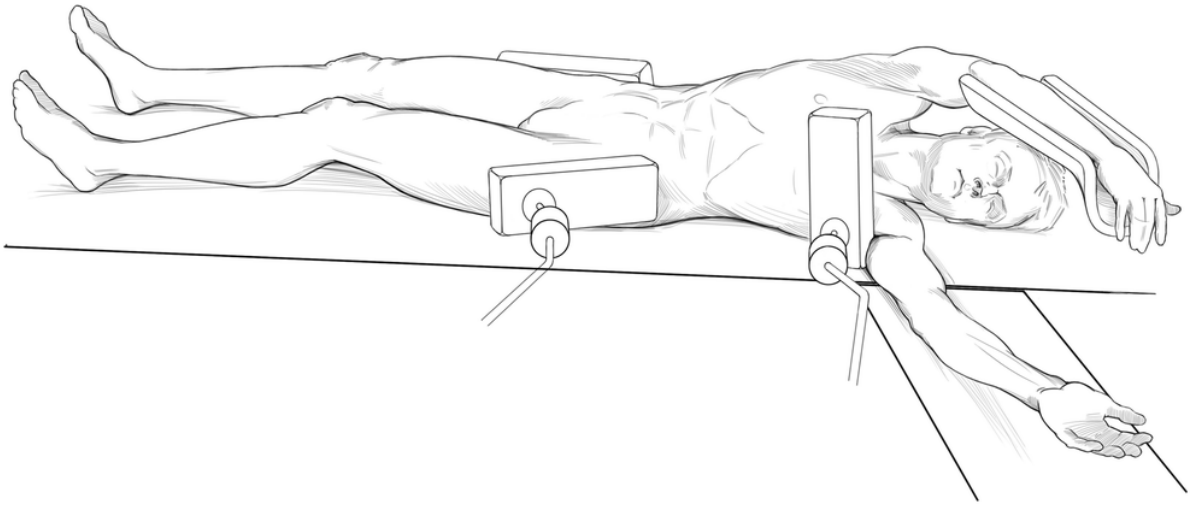

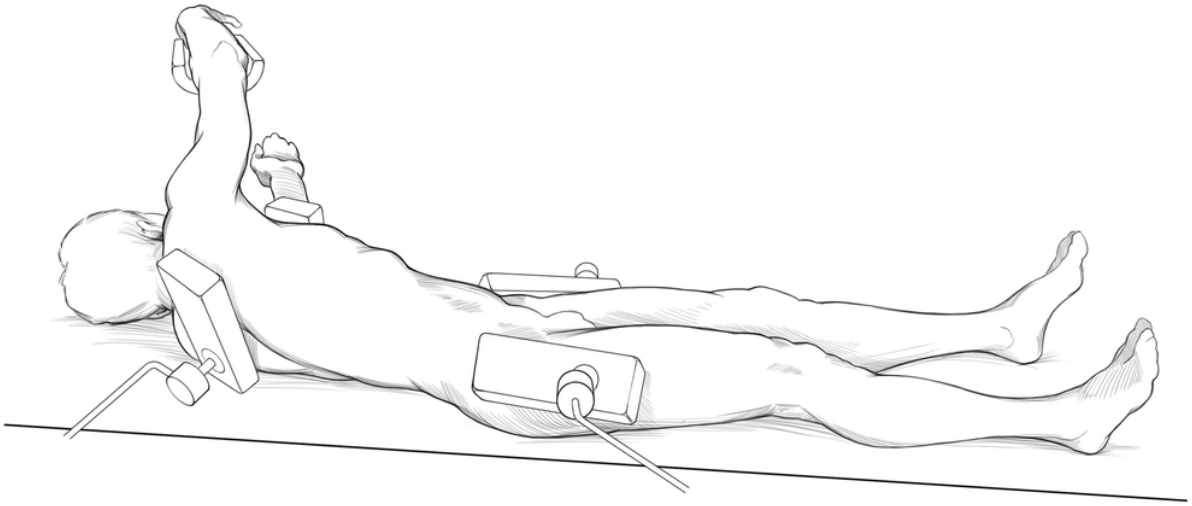

Abdominal Phase I

- Stomach mobilized
- Left gastric artery divided
- Hiatus dissected
- Transhiatal drains placed in left and right pleurae

Chest Phase I

- Esophagus dissected from hiatus $\rightarrow$ cephalad
- Esophagus divided

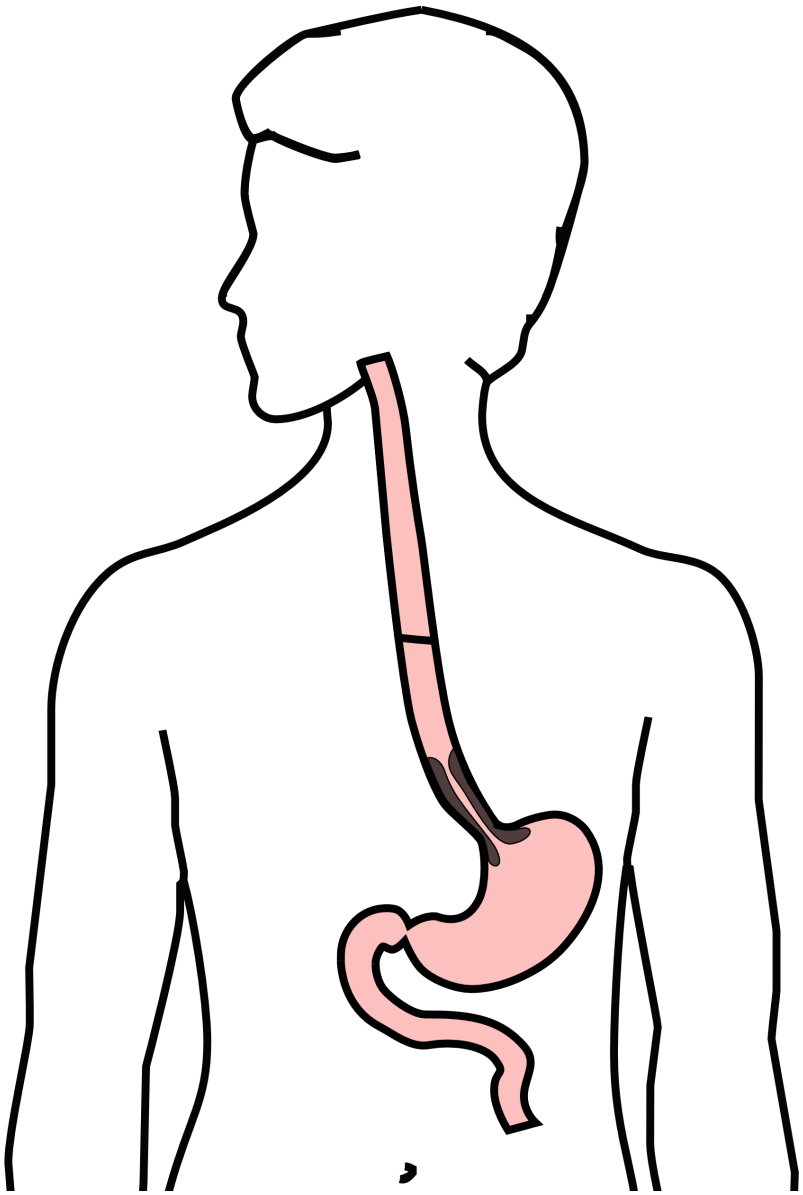

Abdominal Phase II

- Esophagus extracted
- Extracorporeal construction of conduit
- Pyloromyotomy
- Conduit constructed

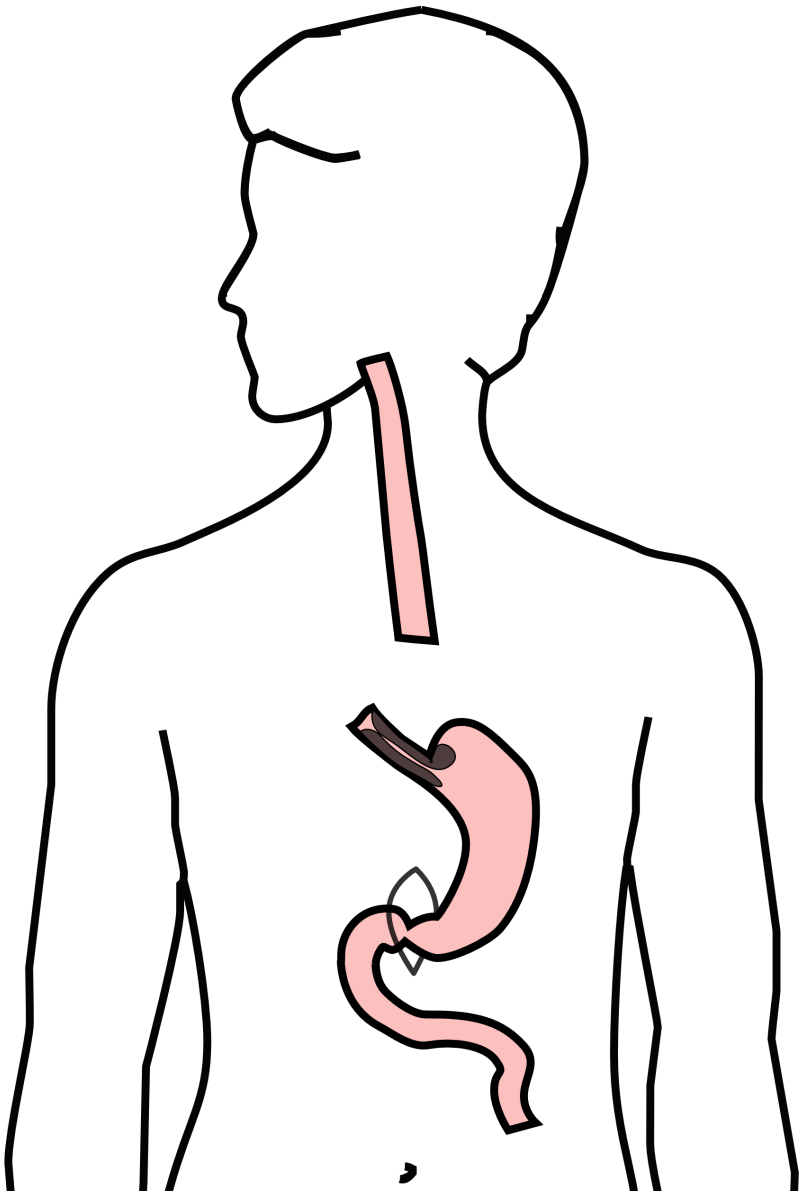

Abdominal Phase II

- Esophagus extracted
- Extracorporeal construction of conduit
- Pyloromyotomy
- Conduit constructed
  - Place stomach on stretch

– Palpate GE junction/lesser curvature

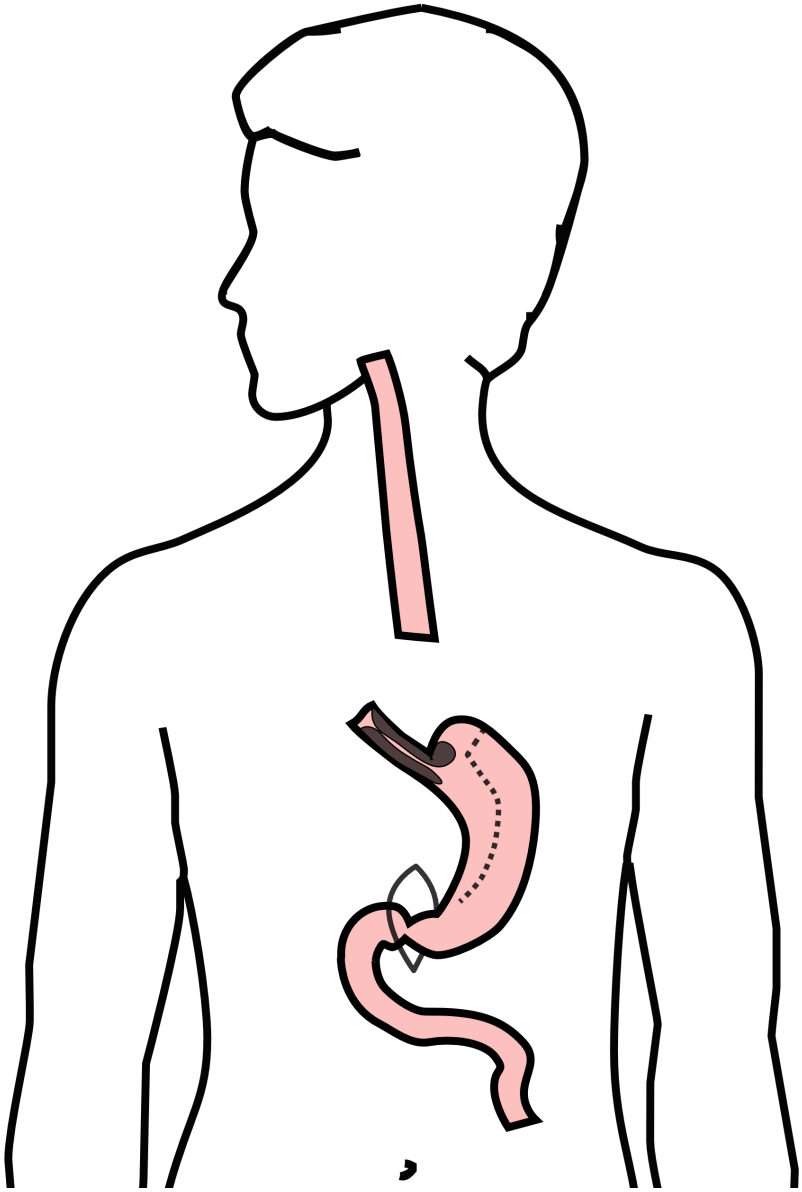

Abdominal Phase II

- Extracorporeal construction of conduit
- Pyloromyotomy
- Conduit constructed

- Conduit transposed into chest (hand-assisted)

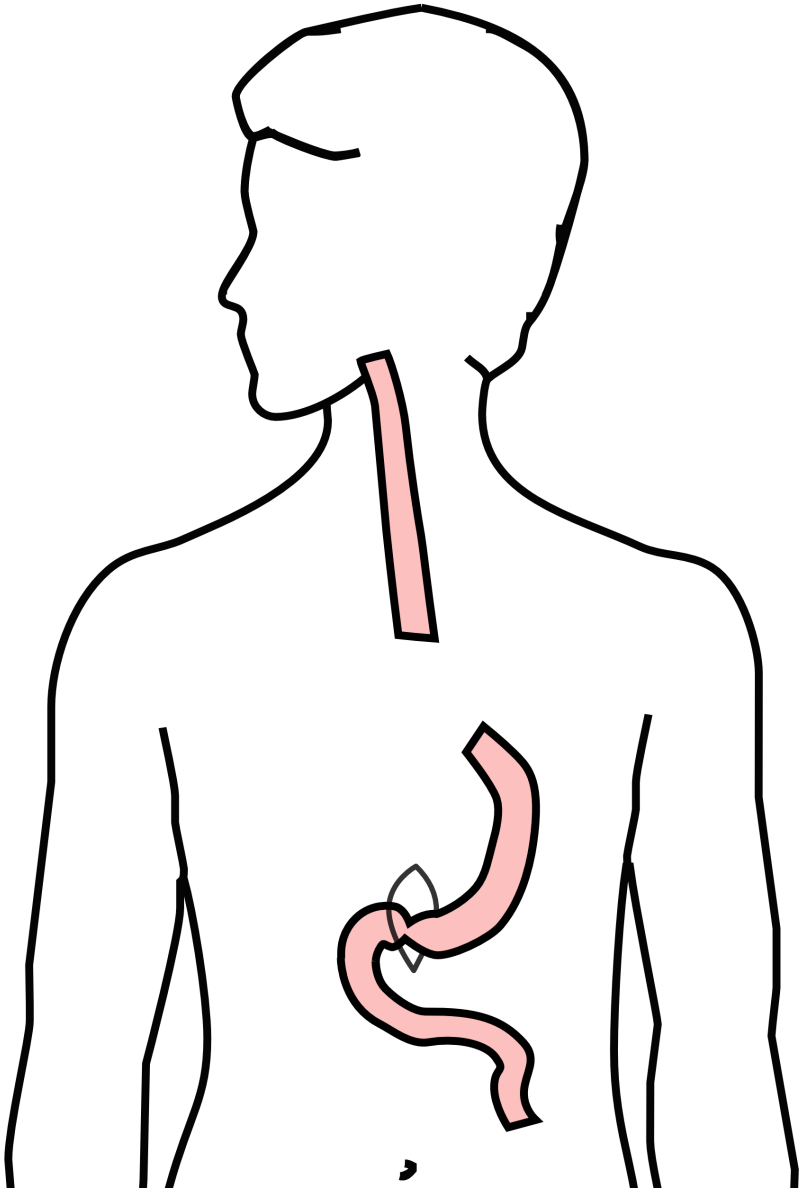

Chest Phase II

Anastomosis completed - 25mm Circular stapler

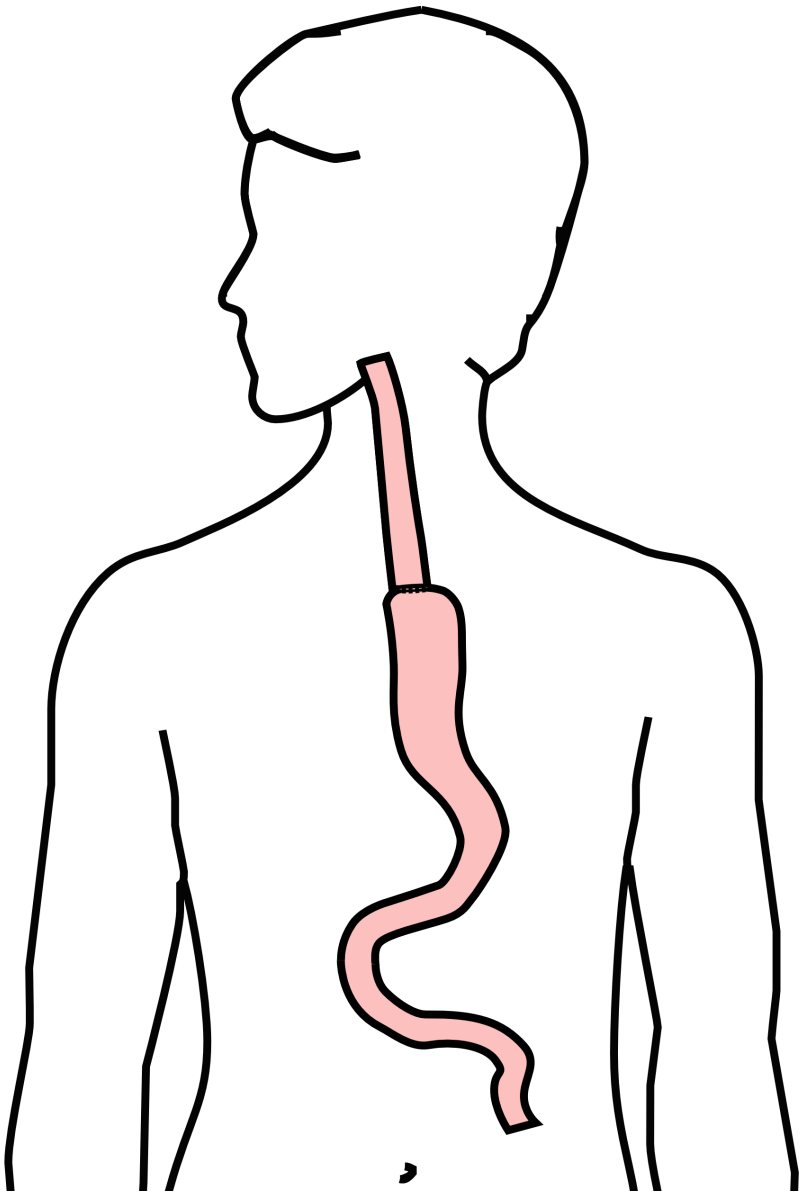

Robotic Esophagectomy Training

- Society for Surgical Oncology Course (Hawkins)
- Case observation at UT Southwestern - Netu Sarkaria (w/Mike Roach)
- ORSI Cadaver Course - Richard van Hillesgberger (w/Mike Roach)

Hybrid Robotic/VATS Esophagectomy

Abdominal Phase Supine - Robotic

- Mobilize stomach
- Celiac lymph node dissection
- Conduit constructed with linear stapler
- Conduit sutured to GE junction

Conduit transposed to Chest

Conduit Sutured to GE junction



Chest Phase Semi-lateral - VATS

- Mobilize and divide esophagus
- Transpose conduit into chest (traction)
- Extract specimen between ribs
- Circular stapled anastomosis (OrVil 25mm)

Robotic Esophagectomy Experience 2021-2024

- 5 cases 2018 co-surgery with Jeff Hagen/Mike Roach
  - Tri-incisional (McKeown):
    - 1 leak + stricture + RLN palsy
    - 1 RLN palsy

Hybrid Robotic/VATS Experience 2025

- 14 cases May - October (5 planned Nov-Jan)
  - Surgical Oncology Block (Friday Room 45): 4
  - Open Robot Time: 10

Hybrid Robotic/VATS Experience

14 cases

- Anatomotic leaks in 2 (14%)
- Delayed gastric emptying in 3
  - Treated with postop pyloric dilation and Botox
  - Somewhat longer length of stay
- Adequate lymph node harvest
- Increased operative time (but improving)

Hybrid Robotic/VATS Problems

Midline abdominal extraction incision required in one patient with large GE junction tumor which could not be extracted between ribs

Difficulty with transposition of conduit into chest via traction

Hybrid Robatic/VATS Modications

Reduction in width of conduit

Widening of hiatus

Prep abdomen into chest phase to allow two-field visualizaiton of transposition

Pyloric drainage procedure

Next Steps

Thoracic robotic phase w/Mike Roach January 2026 (block time)

Move from 25mm OrVil stapler to 27mm CEEA stapler

No plans for linear stapled or hand-sewn anastomosis

Goals

100 robotic esophagectomy cases by January 2029

Recruit replacement GI surgeon by 2028

Robust clinical research platform

January 2029

- Outpatient clinical evaluation and care
- Assist in OR 1-3 days/week
- No night/weekend call
- No primary surgical responsibility
- Option for some remote work from Durham

Clinical Research

Anastomotic leak remains the Achilles heel of esophagectomy

Vascular evaluation of conduit is critical to understanding and preventing leaks

Need a technology for evaluating conduit perfusion

- Reproducible by different surgical teams (across Advocate)
- Quantitation of perfusion
- Mapping of perfusion (relative to final location of anastomosis)

Conduit perfusion will serve as an intermediate endpoint in research to prevent leaks

Collaboration with Winston-Salem

- Machine-learning evaluation of PET in gastric cancer
- Body composition analysis in esophagectomy

Body Composition and Mortality after Esophagectomy

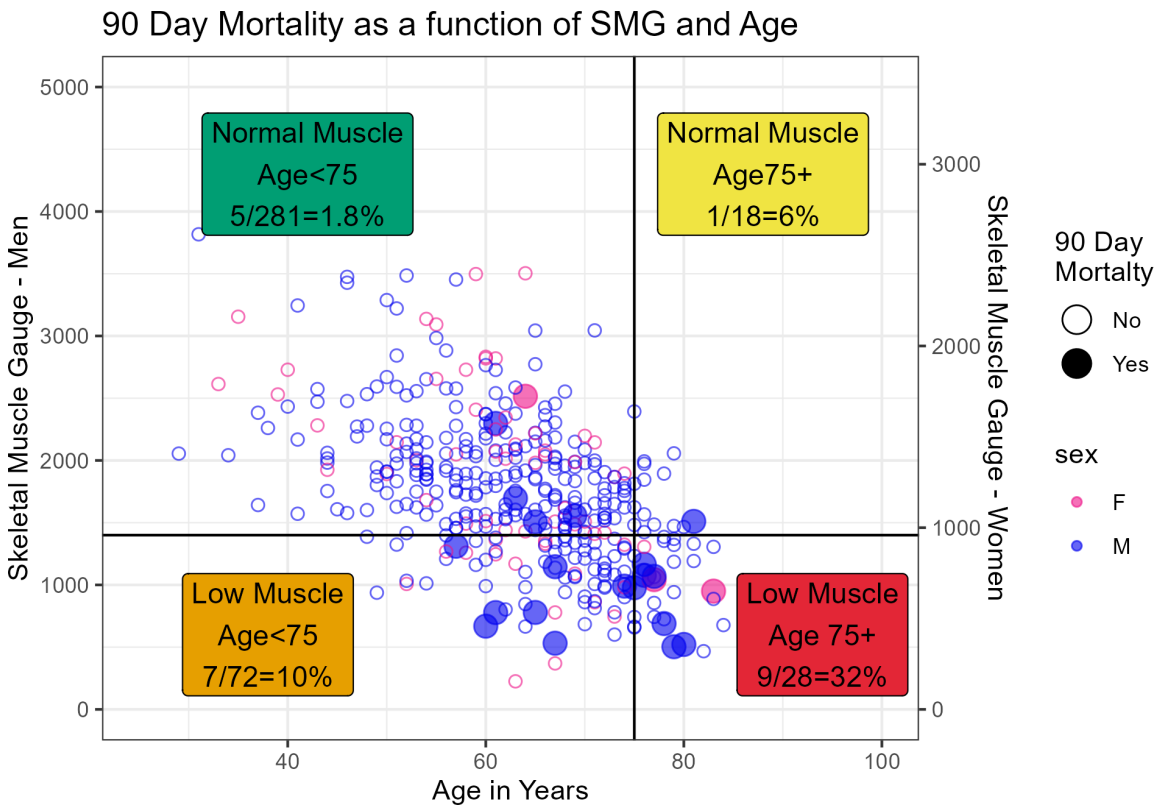

Body Composition and Surgical Decision-making

Retrospective Review of Adenocarcinoma of the Esophagus

Patients stratified by risk of perioperative mortality

- Age
- Body Composition

Two Risk Cohorts:

- High Risk (Highest risk quartile)
- Low Risk (Bottom 3 quartiles)

Low Risk of Perioperative Mortality

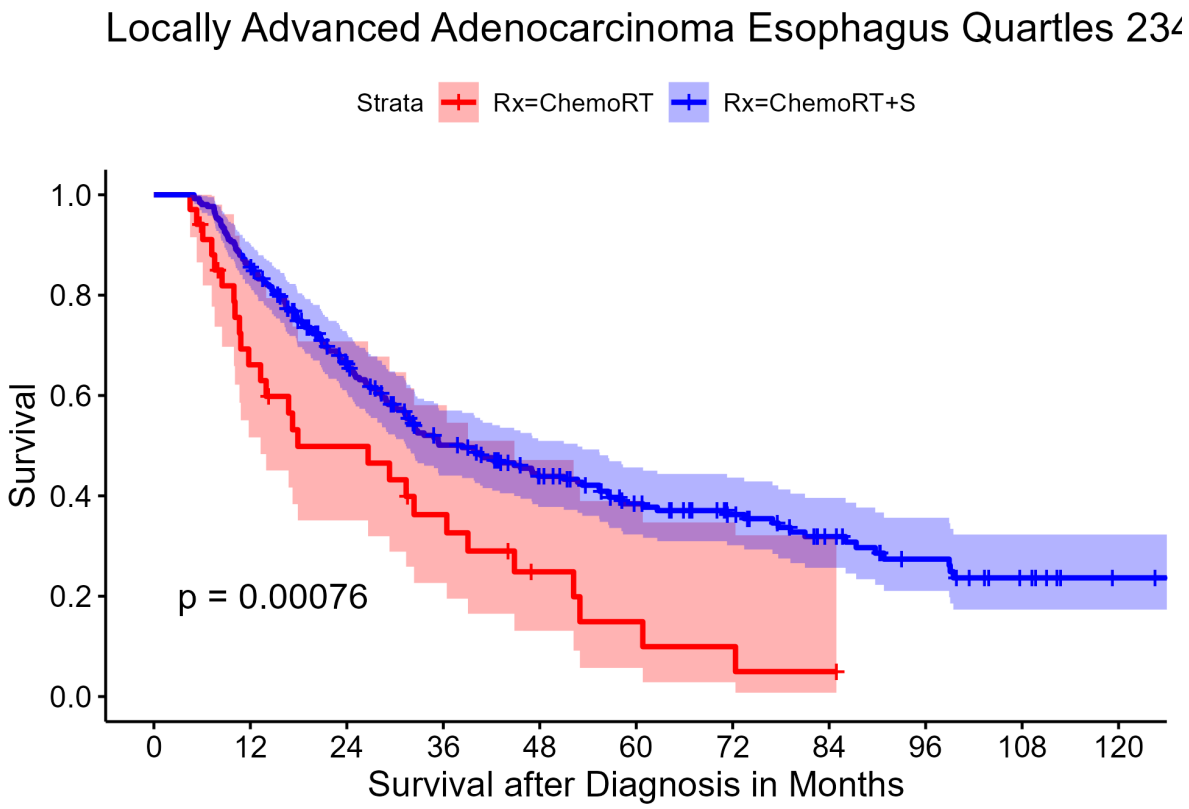
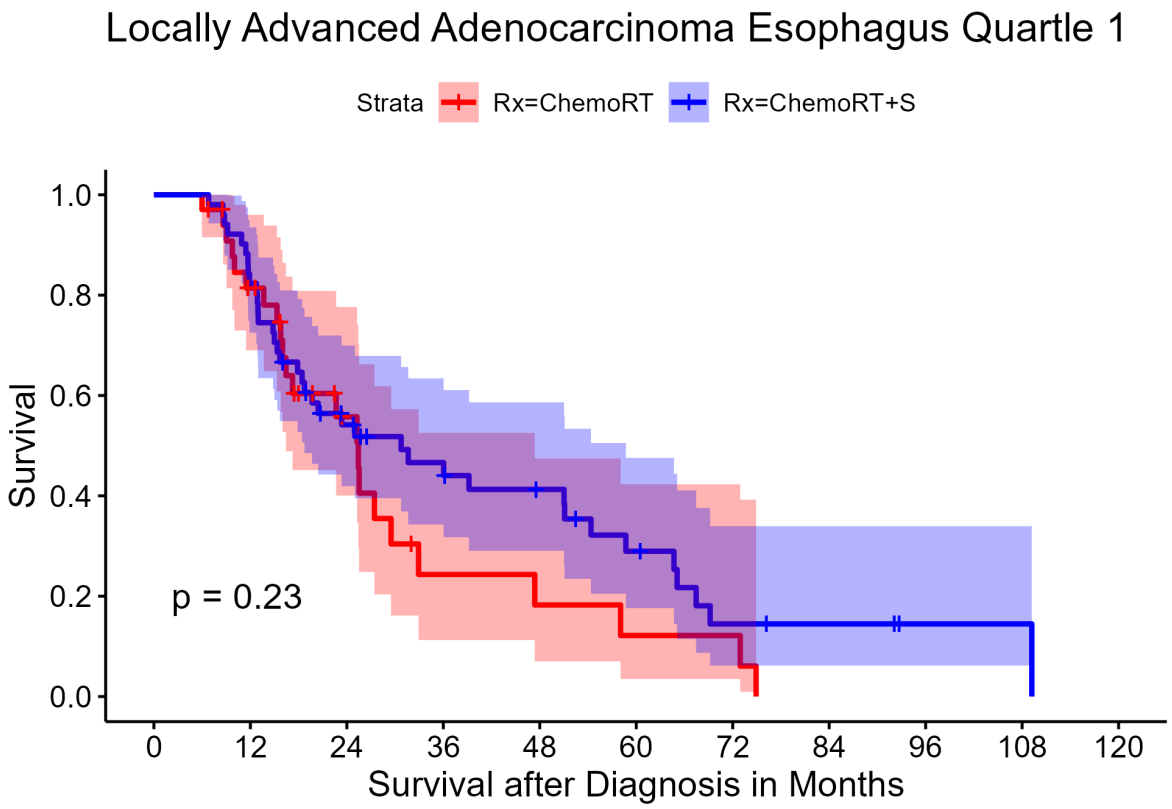
High Risk of Perioperative Mortality