Radiation-Induced Lumbosacral Radiculoplexopathy (RILP)

NotebookLM

Definition & Context

A **delayed, iatrogenic peripheral nerve injury** of the **lumbosacral plexus** occurring as a complication of **pelvic** or **abdominal radiation therapy**.

Common Radiotherapy Contexts:

- Prostate
- Cervical
- Colorectal
- Pelvic Lymphomas

Epidemiological Context (Incidence Rate)

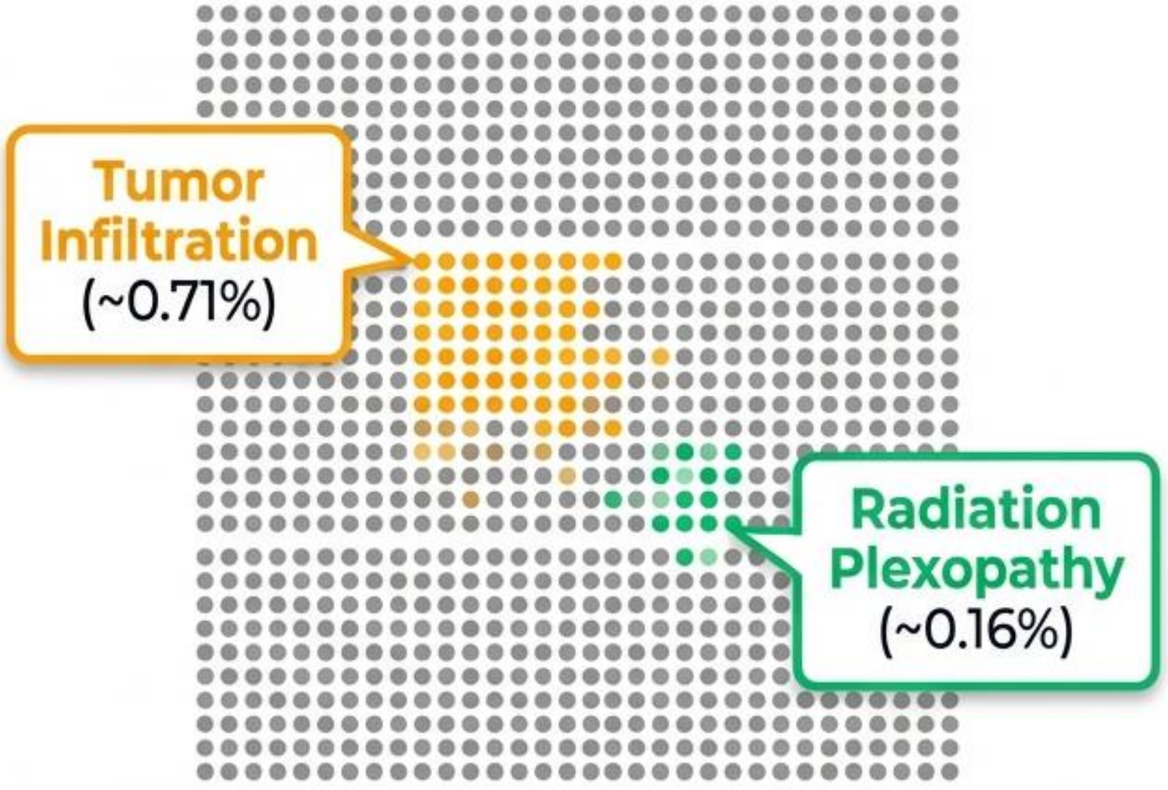

Takeaway: Tumor recurrence is statistically more likely than **radiation injury**.

Board Alert! Always suspect **tumor recurrence first**; RILP is a **diagnosis of exclusion**

NotebookLM

PREMIUM CLINICAL DOSSIER SLIDE:

Pathophysiology: The Mechanics of Delayed Onset

1. Direct DNA Damage

Ionizing radiation permanently damages cellular DNA.

Because the mitotic rate of Schwann cells is extremely slow, the damage remains latent. It is only expressed years or decades later when the cell finally attempts mitosis and undergoes apoptosis.

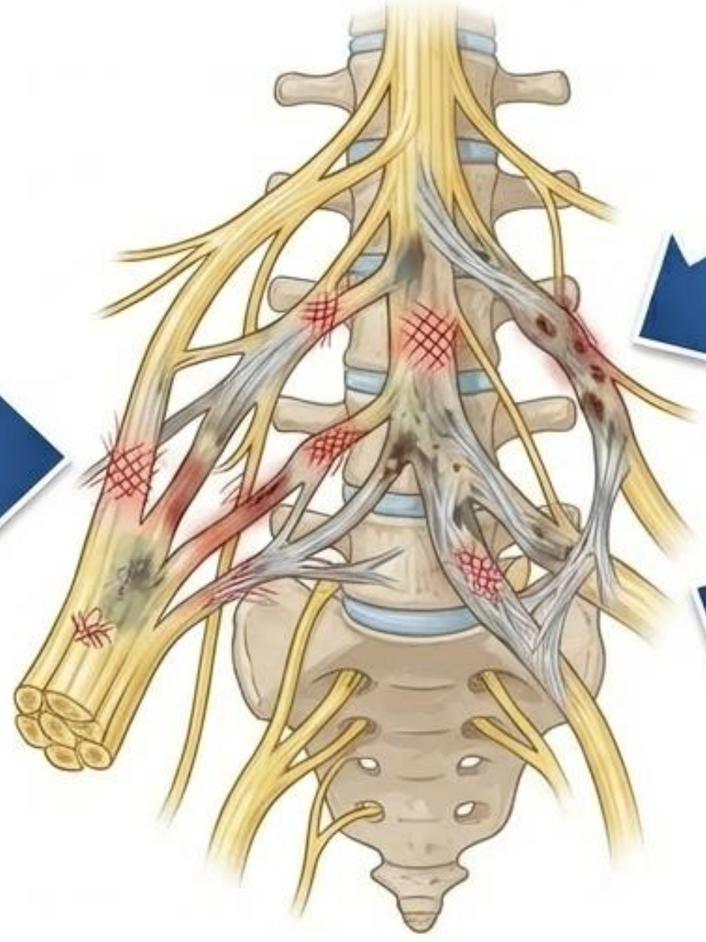

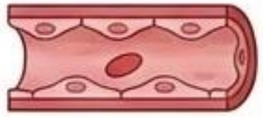

2. Microvascular Ischemia

Radiation causes severe endothelial damage to the vasa nervorum (the delicate blood supply to the peripheral) resulting in gradual ischemic necrosis of the neural tissue.

3. Radiation Fibrosis

Progressive soft tissue and perineural scarring physically compress and entrap the lumbosacral plexus over time.

Board Alert! The decades-long latency of RILP is driven entirely by the ultra-slow turnover rate of Schwann cells masking underlying DNA damage.

NotebookLM

Timeline of Radiation Neuropathy

Acute Phase
Days - Weeks

Transient, mild symptoms. Driven by bioelectrical and vascular permeability changes.
Typically reversible.

Subacute Phase
< 6 Months

Weakness and sensory changes.
Often reversible without structural nerve damage.

Late Phase
1 to 30+ Years

The classic presentation.
Irreversible, progressive **structural nerve damage.**

Can present up to 30+ years post-radiation (e.g., following remote colorectal cancer treatment).

Board Alert! An extensive latency period (decades) does **NOT** rule out a radiation-induced et

NotebookLM

Clinical Features & The Classic Pattern

Motor Findings (Prominent)

Lower Motor Neuron (LMN) signs.

Prominent weakness including foot drop, and compromised hip flexion/abduction.

Severe cases

Paralysis

bladder / bowel dysfunction

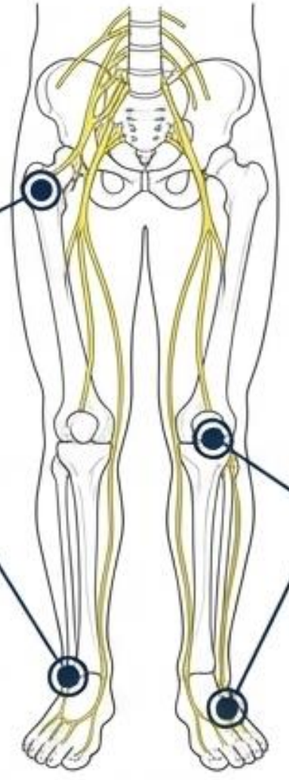

Sensory Findings (Variable)

Paresthesia and numbness, often following distal L4-S1 distributions.

Reflexes

Areflexia or significant hyporeflexia at knees and ankles.

The Classic Pattern Matrix

Laterality: Typically Bilateral but highly Asymmetric.	**Pain Profile:** Painless or mildly painful (contrasts sharply with neoplastic plexopathy).

Board Alert! Bilateral, asymmetric LMN weakness with minimal pain is the hallmark of radiation plexopathy.

NotebookLM

PREMIUM CLINICAL DOSSIER SLIDE:

Natural History & Prognosis

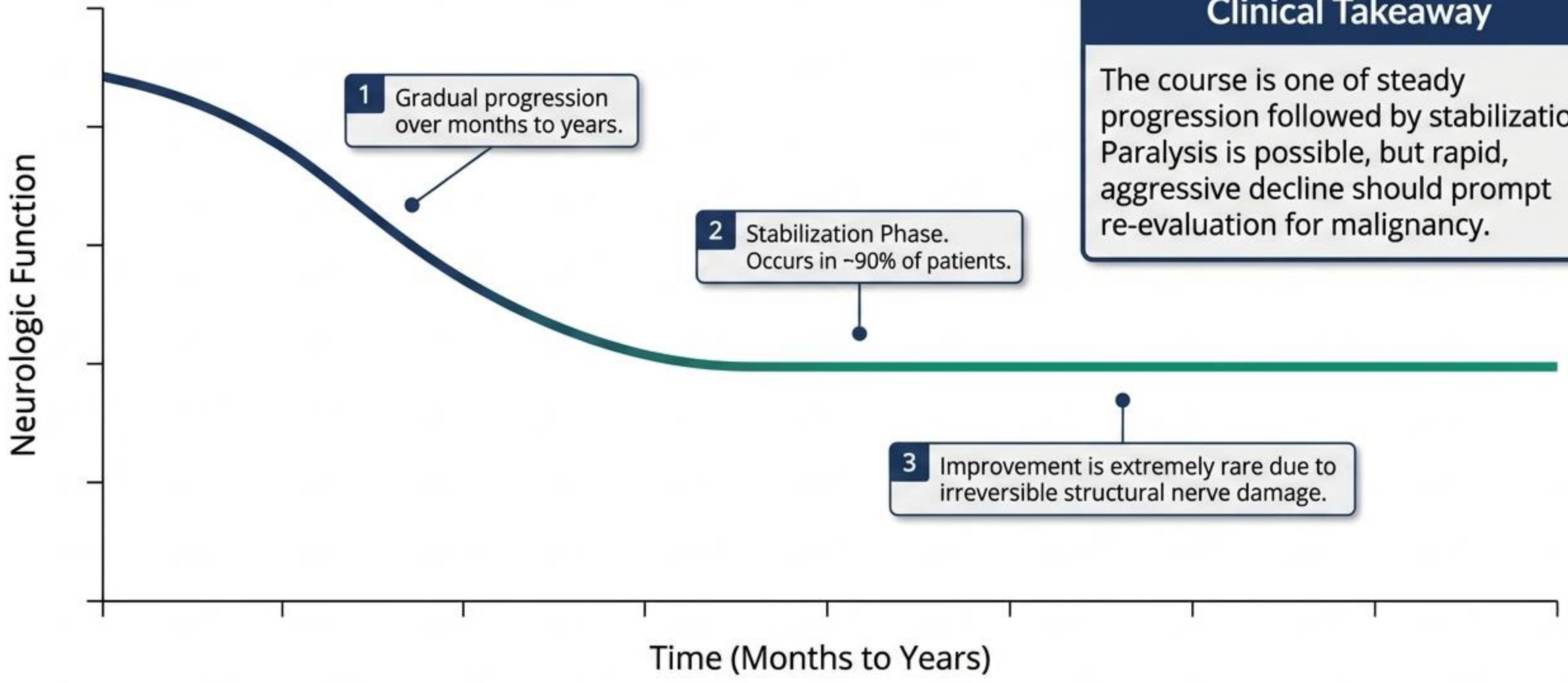

Clinical Takeaway

The course is one of steady progression followed by stabilization. Paralysis is possible, but rapid, aggressive decline should prompt re-evaluation for malignancy.

Board Alert! RILP stabilizes in 90% of cases. Rapid, relentless deterioration suggests tumor.

NotebookLM

Differential Diagnosis: The Crucial Comparison

	Radiation Plexopathy (RILP)	Neoplastic Plexopathy (Tumor)
Pain Profile	Mild, late onset, or completely absent.	Severe, early onset, unrelenting.
Weakness Pattern	Bilateral, highly asymmetric.	Unilateral (follows local structural invasion).
MRI Findings	Diffuse T2 hyperintensity, fatty replacement, no focal mass.	Focal mass effect, nodular enhancement.
EMG Signature	Myokymia (classic hallmark).	Fibrillations, no myokymic discharges.

Systemic Mimics to Consider:
Diabetic amyotrophy, Chronic Inflammatory Demyelinating Polyneuropathy (CIDP), Amyotrophic Lateral Sclerosis (ALS), Leptomeningeal metastasis.

⚠ **Board Alert!** **Painless bilateral weakness = RT. Painful unilateral weakness = Tumor.**

NotebookLM

PREMIUM CLINICAL DOSSIER SLIDE:

Diagnostic Approach: Clinical Algorithm

Step 1: Rule out Malignancy
Modality: Pelvic MRI with contrast / PET-CT.
Look for: Mass effect, nodularity, or tumor recurrence.

Step 2: Rule out Structural Mimics
Modality: CT/MRI bone windows.
Look for: Pelvic Insufficiency Fractures (PIF) mimicking metastatic bone pain.

Step 3: Rule out Systemic & Immune Causes
Modality: Labs (HbA1c, SPEP), CSF analysis.
Look for: Diabetes, CIDP, infectious radiculitis.

Step 4: Confirm Nerve Injury
Modality: EMG/NCS.
Look for: Axonal loss, specific myokymic discharges.

DDx

- Tumor recurrence / metastasis
- Leptomeningeal disease
- Diabetic radiculoplexopathy
- CIDP / immune neuropathy
- ALS

CORE PRINCIPLE: RILP is a Diagnosis of Exclusion.
It is only confirmed when Steps 1-3 are strictly negative

NotebookLM

Objective Investigations: MRI & EMG

Magnetic Resonance Imaging (MRI)

Lumbosacral T2-weighted MRI in sagittal view with fatty changes in the vertebral bodies (white arrows), with subcutaneous atrophy (gray arrows), without cancer recurrence.

- **Acute/Subacute:** Hyperintense edematous changes (T2/STIR) in the plexus.
- **Chronic:** Fatty replacement of bone marrow, prominent muscle atrophy.
- **Crucial Finding:** Total absence of enhancing mass or nodularity.

Electrodiagnostic Testing (EMG/NCS)

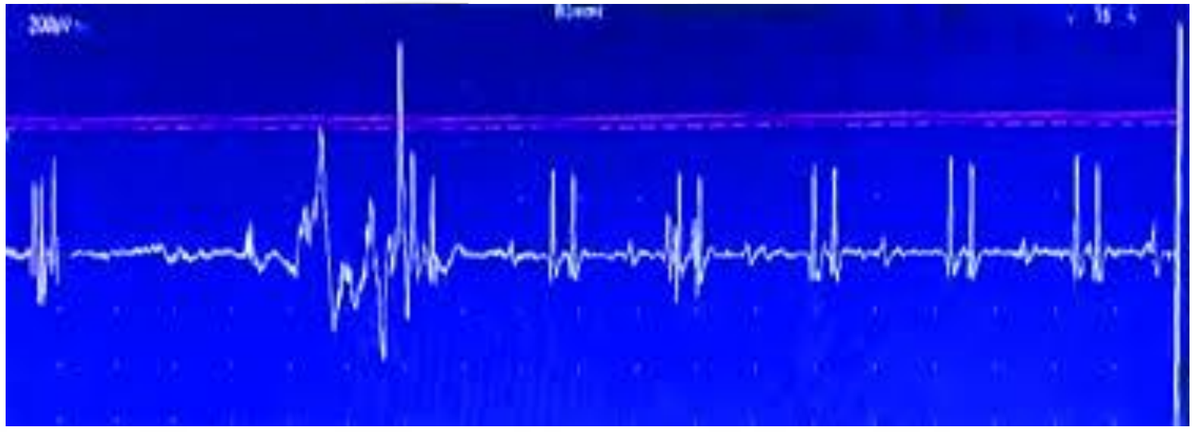

- **Finding:** Motor and sensory axonal loss with reduced amplitudes.

Pathognomonic Clue: Myokymia

Myokymic discharges (slow, irregular firing of motor units) are the classic signature.

Caveat: Present in only ~57% of cases. Absence of myokymia does not rule out RILP!

⚠️ **Board Alert!** Myokymia strongly supports RILP over tumor, but its absence means nothing.

NotebookLM

Other Potential Causes of Myokymic Discharges

Myokymic discharges can also be seen in **other conditions:**

Guillain-Barré
Syndrome

Multiple Sclerosis
(MS)

Pontine Lesions
(*e.g., Tumors*)

Compressive Neuropathies

Hypocalcemic Tetany

Rattlesnake Envenomation
(*Transient*)

Iatrogenic Risk Factors

Key Variables Increasing RILP Probability:

- **Total Radiation Dose:** Risk sharply increases with cumulative doses >50-60 Gy.
- **Fractionation Size:** High dose per fraction (>2 Gy per fraction) is highly neurotoxic.
- **Field Size & Technique:** Large pelvic/para-aortic fields pose higher risk. (Modern IMRT reduces this via precise contouring).
- **Concomitant Chemotherapy:** Concurrent use of neurotoxic agents, specifically Cisplatin, acts synergistically to destroy the plexus.

Board Alert! Suspect RILP highly in cervical cancer patients who received both >60 Gy pelvic RT and weekly Cisplatin.

NotebookLM

Treatment & Clinical Management

Note: No curative or disease-modifying treatment exists for RILP.

Pillar 1: Rehabilitation

- Aggressive PT/OT is mandatory to prevent contractures.
- **Orthotics** (e.g., AFOs for foot drop) for safe mobilization.
- **Goal:** Maintain long-term ambulatory function.

Pillar 2: Symptomatic Rx

- **First-line:** Neuropathic pain management (Gabapentin, Pregabalin, SNRIs).
- **Interventional:** Fluoroscopy-guided caudal injections for refractory radicular pain.

Pillar 3: Clinical Vigilance

- Continuous monitoring for secondary complications.
- **Screen** for late-onset Pelvic Insufficiency Fractures.
- Requires bone density optimization (Vitamin D, Alendronic acid).

Board Alert! **Never prescribe bed rest; strict, continuous physiotherapy is the only intervention that maintains mobility.**

NotebookLM

🌟 Key Exam Pearls

Painless & Bilateral = RT.
Painful & Unilateral = Tumor.
(Know this comparison matrix cold).

Beware the PIF Trap.
Severe **bone pain** in a post-RT patient is often a **Pelvic Insufficiency Fracture**, not necessarily a tumor recurrence.

Myokymia is the magic word.
If an EMG vignette shows myokymic discharges in a pelvic cancer select Radiation Plexopathy.

Latency is a liar.
RILP can present >30 years after the last radiation dose due to the incredibly slow rate of Schwann cell mitosis.

NotebookLM

“Radiation-induced lumbosacral radiculoplexopathy is a delayed, irreversible “diagnosis of exclusion” presenting with “bilateral, asymmetic” lower exemity weakness and “myokymia on EMG”, ocuring “years to decades” after pelvic radiotherapy.”

Mastery Achieved. Ready for Boards.

NotebookLM