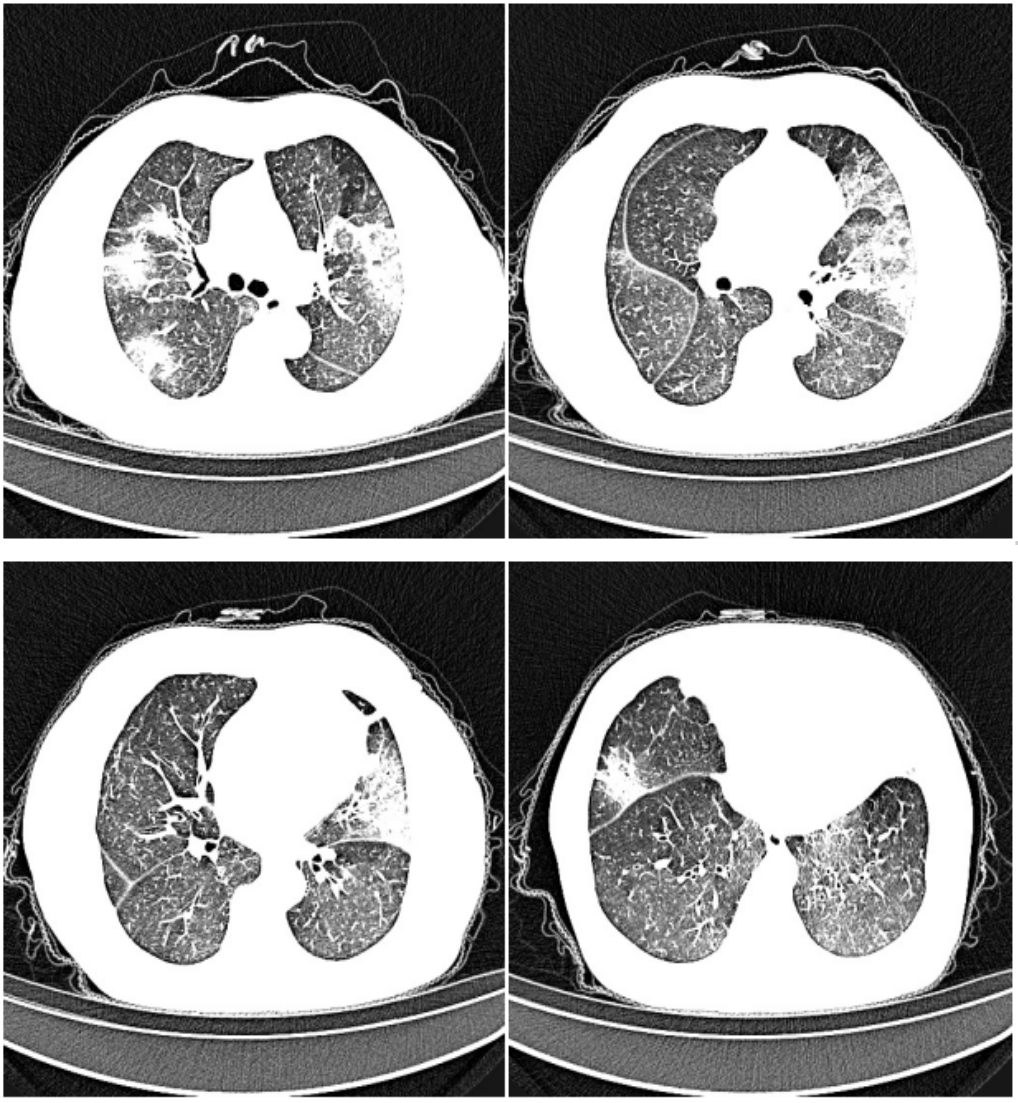

Medical Image Report

Indication: 75-year-old female.

Finding: 双肺散在小片、片状影，小叶间隔增厚，见条索状影，局部呈细网格状改变，病变主要位于双肺上叶和右肺中叶。双侧主支气管及叶支气管通畅，未见明显狭窄或扩张。甲状腺左右叶增大，并见边界欠清的低密度灶，左叶较明显。纵隔结构清晰，主动脉及分支、冠脉钙化；心包增厚；双侧胸腔未见积液。

The two lungs are scattered in small pieces and flaky shadows, and the interlobular septa is thickened. The strip-shaped shadows are seen, and the local changes are fine-grid. The lesions are mainly located in the upper lobe of the two lungs and the middle lobe of the right lung. Bilateral main bronchi and lobar bronchi are unobtrusive with no obvious stenosis or dilation. The left and right lobes of the thyroid gland are enlarged, and low-density foci with less clear boundary are observed. The mediastinal structure was clear, and the aorta and its branches and coronary arteries calcified. Pericardial thickens; No effusion is seen in bilateral thorax.

Conclusion: 双肺散在多发间质性炎症，考虑病毒性肺炎可能；请结合临床和实验室检查；主动脉及分支、冠脉钙化；心包增厚；

The two lungs scattered multiple interstitial inflammation, considering the possibility of viral pneumonia; Please combine clinical and laboratory tests; Calcification of aorta, branches and coronary arteries; Pericardial thickening;