https://doi.org/10.5664/jcsm.9144

JCSM | Journal of Clinical Sleep Medicine

REVIEW ARTICLES

Is REM sleep behavior disorder a friend or foe of obstructive sleep apnea? Clinical and etiological implications for neurodegeneration

Yu Jin Jung, MD, PhD[1]; Eungseok Oh, MD, PhD[2]

[1]Department of Neurology, Daejeon St. Mary's Hospital, College of Medicine, The Catholic University of Korea, Seoul, Republic of Korea; [2]Department of Neurology, Chungnam National University Hospital, College of Medicine, Chungnam National University, Daejeon, Republic of Korea

Rapid eye movement sleep behavior disorder (RBD) is a parasomnia characterized by loss of muscle atonia during rapid eye movement sleep, associated with complex motor enactment of dreams. Obstructive sleep apnea (OSA) is a relatively common sleep disorder characterized by repetitive episodes of upper airway obstruction while sleeping, which can result in hypoxemia and sleep fragmentation. Even though the nature of RBD and OSA is different, OSA may sometimes be accompanied by RBD symptoms. Accordingly, it is reasonable to distinguish these 2 sleep disorders in people with dream enactment behaviors. Although RBD and OSA share similar sleep phenomena, their association has yet to be elucidated. Herein we draw attention to various RBD-mimicking conditions, RBD combined with OSA, and the relationship between RBD and OSA. Furthermore, the clinical implications of OSA in neurodegeneration and the optimized management of RBD combined with OSA are also discussed in this review.

Keywords: REM sleep behavior disorder, obstructive sleep apnea, neurodegeneration, dream enactment behavior

Citation: Jung YJ, Oh E. Is REM sleep behavior disorder a friend or foe of obstructive sleep apnea? Clinical and etiological implications for neurodegeneration. *J Clin Sleep Med*. 2021;17(6):1305–1312.

INTRODUCTION

Rapid eye movement (REM) sleep behavior disorder (RBD) is a parasomnia characterized by loss of muscle atonia during REM sleep associated with complex motor behaviors.[1] Abnormal vocalizations or behaviors often occur simultaneously with dream mentation, leading to dream enactment behaviors (DEB).[2–4] The term *probable RBD* is used if polysomnography (PSG) is not available for the diagnosis of RBD but clinical history for DEB is definitive.[5,6] The prevalence of RBD is estimated at 0.5%–2%,[7,8] but probable RBD is more frequent (4.6%–13%) in older community-dwelling adults.[5,6,9] RBD can be categorized into idiopathic and symptomatic types based on associated symptoms.[2–4] Idiopathic RBD (iRBD) refers to RBD that is not accompanied by any neurological conditions, whereas symptomatic RBD is related to identifiable underlying etiologies, such as medications, narcolepsy, and neurodegenerative diseases like Parkinsonism.[2–4] A strong association between RBD and synucleinopathies including Parkinson's disease (PD), multiple system atrophy, and dementia with Lewy bodies has been established.[10,11] RBD frequently manifests years to decades prior to the onset of the motor symptoms of synucleinopathies,[10,11] and recently it was recognized as a prodromal biomarker for PD.[12,13] As RBD is now appreciated as not only a parasomnia but also a manifestation of prodromal-stage synucleinopathies, some authors prefer to use the term *isolated* rather than *idiopathic*.[14]

The diagnostic criteria for RBD in the *International Classification of Sleep Disorders*, third edition require the exclusion of RBD-mimicking symptoms.[1] Obstructive sleep apnea (OSA) can present with abnormal nocturnal movements or behaviors similar to RBD. However, OSA is a relatively common sleep disorder, unlike RBD, especially in the aging population, with a prevalence of around 60% in men and 40% in women over 60 years old.[15] The main feature of OSA is repetitive episodes of complete (apnea) or partial (hypopnea) upper airway obstruction during sleep, so patients often experience brief sudden arousals due to hypoxic episodes.[16] The apneic and hypopneic events deplete oxygen saturation and increase the risk of cerebrovascular and metabolic diseases, such as hypertension, atrial fibrillation, heart failure, coronary heart disease, stroke, and type 2 diabetes mellitus.[17–19]

Although RBD and OSA have different clinical and pathophysiologic substrates, comorbid OSA in patients with RBD is quite common, with 34%–61% of them manifesting sleep apnea.[2,20] The coexistence of OSA and RBD may be attributed to shared risk factors, including older-age onset and male predominance. However, it is difficult to distinguish between OSA characterized by sudden arousals following hypoxic episodes similar to RBD and RBD combined with OSA in patients complaining of DEB. It is critical to distinguish these conditions, because treatment options and prognosis of the diseases are very different. However, knowledge about this common comorbidity of RBD with OSA and the association between them is still very limited. Herein, we review various RBD-mimicking conditions, RBD combined with OSA, and the relationship between RBD and OSA. Furthermore, the possible etiological implications of OSA for neurodegeneration and optimized management of RBD combined with OSA are also discussed.

REM SLEEP BEHAVIOR DISORDER MIMICS (PSEUDO-RBD)

Abnormal nocturnal behaviors can occur in various sleep disorders such as non-REM parasomnias (eg, sleepwalking

Table 1—Characteristics of various RBD mimicking conditions in abnormal nocturnal behaviors.

Features	REM Parasomnia RBD	NREM Parasomnia		Nocturnal Seizures	OSA
		Sleepwalking	Sleep Terrors		
Age at onset	Older adult	Childhood and adolescence		Variable	Variable, increased prevalence of age
Time and sleep stage of occurrence	Typically occurs in the last third of the night and starts REM sleep	Usually occurs in the first half of the night and typically in N3 slow-wave sleep		Anytime during night, but usually in NREM sleep	Anytime during night, but more prominent in REM sleep
Family history	No	Frequently positive (in 62%–96%)		May be positive (~39%)	Increased relative risk in first-degree relatives
Behavior semiology	Arousal followed by dream enactment behaviors	Abrupt arousal, potential for confusion and agitation if interrupted vigorously	Sudden arousal with intense screaming, crying, agitation, and heightened autonomic discharge	Stereotypical, paroxysmal events, often with dystonic limb posturing, vocalizations, and confusions	Arousal followed by complex motor behaviors at the end of the apneic events
Event duration	Less than 10 min	1–10 min	Few s to min	Few s to min	Few s to min
Dream recall	Typical recall at times with vivid details	Limited to no recall with confusion		Amnesia to partial/ complete recall with confusion	Variable
Sleep-related injury	Strongly present	May or may not be present	No	May or may not be present	May or may not be present
Trigger factors	Medications (antidepressants), alcohol, caffeine	Sleep deprivation, febrile illness, alcohol, noise, anxiety, psychological stress, sleep apnea		Not typical but may be precipitated by sleep deprivation	Weight gain, alcohol, medications (sedatives)
PSG findings	Abnormal increase in chin or limb EMG activities during REM sleep (RWA)	Abnormal arousal from stage N3 slow-wave sleep followed by return to sleep; increased cyclic alternating pattern		Potentially epileptiform activities on EEG	High apnea-hypopnea index and low oxygen saturation
Treatments	Clonazepam, melatonin	Avoidance of precipitating factors, improving sleep hygiene; if episodes are frequent and severe, consider pharmacotherapy (imipramine, clonazepam, paroxetine)		Antiepileptic drugs	CPAP

CPAP = continuous positive airway pressure, EEG = electroencephalogram, EMG = electromyography, NREM = nonrapid eye movement, OSA = obstructive sleep apnea, PSG = polysomnography, RBD = rapid eye movement sleep behavior disorder, REM = rapid eye movement, RWA = rapid eye movement sleep without atonia.

and sleep terrors), OSA, nocturnal seizures, sleep-related dissociative disorders, trauma-associated sleep disorders, periodic limb movement disorder, as well as RBD (**Table 1**).[3,21] Therefore, these various RBD-mimicking disorders represent the broad spectrum of pseudo-RBD.[3] Among the various examples of pseudo-RBD, OSA is a common sleep disorder in clinical practice. However, only a small number of studies have addressed "pseudo-RBD–associated OSA" (**Table 2**). OSA can be mistaken for true RBD based on the type of abnormal sleep behaviors, such as punching, gesturing, and talking, in addition to violent dreams (eg, being attacked and chased).[22–25] OSA behaviors mimic RBD symptoms since patients carry a history of limb and body movements associated with dream mentation and dreams that appear to be "acted out."[25] Moreover, demographic factors such as age, sex, and older male predominance are also similar to those in RBD.[23] However, video PSG findings in patients with OSA failed to demonstrate REM sleep without atonia (RWA), which is an essential element of RBD.[22–24] Additionally, OSA-induced arousals with DEB occurred only at the end of the apneic events in both non-REM and REM sleep[23] and nasal continuous positive airway pressure (CPAP) treatment not only eliminated snoring and daytime somnolence but also decreased unpleasant dreams and DEB.[22–24] Therefore, OSA and RBD show similar phenomenology and different characteristics at the same time.

The pathophysiology of pseudo-RBD associated with OSA is not completely understood because of its heterogeneous causes and features. Abnormal nocturnal behaviors were observed in patients with severe OSA characterized by a higher apnea-hypopnea index and severe oxyhemoglobin desaturations.[23,24] It has been suggested that OSA-induced arousals during REM sleep with vivid dreaming can result in immediate postarousal DEB with locomotion, agitation, and violence.[24] Therefore, OSA-induced hypnopompic REM sleep parasomnia could be easily misdiagnosed as true RBD.[24] Accordingly, pseudo-RBD symptoms in OSA were supposed to represent a form of confusional arousal after intense apneic episodes with severe oxyhemoglobin desaturations.[23] However, it is unclear why not all of the patients with OSA and severe oxyhemoglobin desaturations have disturbed dreams and DEB like in RBD.

Table 2—A summary of studies investigating "pseudo-RBD associated with OSA."

Study	Patient Characteristics			PSG Findings			CPAP Responses
	Number of Patients	Sex (M:F)	Age (y)	AHI	Nadir Oxygen Saturation (%)	REM Sleep Without Atonia (%)	
Oh et al, 2014[22]	1 OSA (pseudo-RBD)	1:0	35	131.8	59	0	Resolution of DEB with control of OSA
Schenck et al, 1989[25]	1 OSA (pseudo-RBD)	1:0	79	Not specified	80	Not specified	Not specified
Nalamalapu et al, 1996[24]	5 OSA (pseudo-RBD)	5:0	61.4 ± 9.1	51–196	68–82	0	3 patients had resolution of DEB with control of OSA
Iranzo and Santamaría, 2005[23]	16 OSA (pseudo-RBD)	11:5	59.6 ± 7.7	67.5 ± 18.7	57.2 ± 18.8	2.7 ± 1.5	13 patients had resolution of DEB with control of OSA
	16 idiopathic RBD	13:3	64.5 ± 5.1	2.5 ± 2.9	Not specified	36.9 ± 35.3	
	20 healthy control patients	16:4	63.0 ± 9.8	3.2 ± 2.8	Not specified	4.3 ± 3.3	

AHI = apnea-hypopnea index, CPAP = continuous positive airway pressure, DEB = dream enactment behaviors, OSA = obstructive sleep apnea, PSG = polysomnography, RBD = rapid eye movement sleep behavior disorder, REM = rapid eye movement.

REM SLEEP BEHAVIOR DISORDER COMBINED WITH OSA

DEB can occur in patients with severe OSA, which was designated as pseudo-RBD in the previous section. However, Jang et al[26] reported that 2 patients presenting with DEB were initially diagnosed with pseudo-RBD associated with severe OSA but finally rediagnosed as true RBD combined with severe OSA. These 2 patients exhibited abnormal behaviors and increased muscle tone during REM sleep after CPAP application.[26] The authors suggested that frequent arousal associated with OSA shortened the REM sleep duration or caused REM sleep fragmentation, which might mask the features of RBD.[26] Complex motor behaviors of RBD were more easily detected if the REM sleep period was increased and the frequency of REM sleep fragmentation was decreased by CPAP treatment in RBD combined with severe OSA.[26] Successful CPAP treatment allows REM sleep rebound, extending the duration and density of REM sleep.[27] An approximate 20% of REM sleep rebound was confirmed by CPAP titration.[28]

It is important to distinguish pseudo-RBD associated with OSA from RBD combined with OSA because of different clinical implications and treatment options. OSA combined with RBD has been differentiated from OSA without RBD via cardiac ^{123}I-metaiodobenzylguanidine scintigraphy.[29] The ^{123}I-metaiodobenzylguanidine uptake in the OSA combined with RBD group showed severe reductions compared with OSA without RBD. Therefore, cardiac ^{123}I-metaiodobenzylguanidine scintigraphy is a useful tool in distinguishing RBD combined with OSA from pseudo-RBD associated with OSA.[29] Cardiopulmonary coupling (CPC) analysis can also be used to screen RBD among patients reporting DEB. CPC analysis is an electrocardiogram-based method to assess sleep stability and sleep apnea phenotypes.[30] An RBD group showed similar CPC profiles compared to normal control patients, whereas an RBD combined with OSA group and OSA group had a worse CPC profile.[31] Therefore, if patients with RBD show poor sleep quality in CPC, then pseudo-RBD associated with OSA or RBD concomitant with OSA should be suspected. However, detailed history-taking is the basic approach used to differentiate pseudo-RBD from true RBD. Video PSG is mandatory to establish an accurate diagnosis of RBD. However, DEB and RWA are episodic and may not always be detected during video PSG monitoring in clinical practice. Moreover, decreased REM sleep duration and delayed REM sleep latency during the first night may affect the PSG variation nocturnally.[32] Therefore, PSG evaluation for RBD is recommended on more than 1 day.[33] Although the diagnostic rate of confirmation was increased up to 95% when PSG was combined with video analysis in a recent study,[34] there are still concerns about missed diagnoses of RBD, especially in patients with RBD accompanied by OSA. If the symptoms of OSA are controlled by CPAP, then RBD-mimicking symptoms of OSA disappear and RBD features are prominently observed in patients with OSA with RBD.[23] Therefore, CPAP treatment is an acceptable option to screen patients with severe OSA for RBD or patients with diagnostic uncertainty. In a recent study, the prevalence of comorbid OSA in patients with RBD was 89.2% and treatment with CPAP improved the self-reported RBD symptoms in 45.8% of such patients.[35] In addition, the quantitative scoring of tonic and phasic electromyography activity during REM sleep showed high sensitivity and specificity in differentiating iRBD and RBD from OSA.[36,37]

IMPACT OF REM SLEEP BEHAVIOR DISORDER ON OSA

The influence of RBD on the severity of OSA has been a matter of debate. One of the hallmarks of RBD is the loss of muscle atonia during REM sleep, which might have a positive effect on the severity of OSA. A long-standing hypothesis states that the preservation of muscle tone in RBD may be a protective factor for OSA because it prevents upper airway collapse in apneic periods of OSA. Emerging evidence suggests that patients with a combination of OSA and RBD have fewer severe sleep apnea parameters, such as higher nadir oxygen saturation and shorter duration of apnea and hypopnea than in patients with OSA but without RBD.[38,39] Effectively, REM sleep–related electromyography activity has been inversely associated with the severity

of OSA in patients with RBD.[38] These results also suggest that increased electromyography activity due to RBD protected against reduced nadir oxygen saturation in patients with PD and OSA.[40] In addition, the protective effect of RWA for OSA is greater in the supine position than in the lateral position in patients with iRBD.[41] According to the CPC results, patients with RBD and OSA exhibit more stable sleep patterns compared with patients with OSA.[31] Taken together, RWA in RBD may potentially be a natural protective mechanism against severe OSA and play a central role in the pathophysiology of OSA.[38] However, these studies are limited by small sample size, lack of long-term follow-up, and group heterogeneity with idiopathic and symptomatic RBD. Furthermore, it is unclear whether the protective effect of RBD on OSA severity could be extended to cardiovascular and metabolic complications of OSA.

In contrast, the protective role of RWA in RBD combined with OSA was not established in other studies.[42,43] Zhang et al[42] emphasized that sleep-disordered breathing (SDB), defined by an apnea-hypopnea index greater than 5 events/h in that study, was more frequent and more severe in patients with PD and RBD than in those without RBD. In addition, the RBD and RBD screening questionnaire scores were higher in frequency among patients with PD and SDB than in those without SDB, and a significant inverse correlation was found between RBD screening questionnaire scores and mean oxygen saturation.[42] Even if the muscle tone of chin was maintained in patients with PD and RBD, RWA had no or negative influence on the severity of apnea during REM sleep.[42,43]

The association between RBD and SDB in which the presence of one could worsen the other is caused by the anatomical proximity to the lower brain stem.[42] The subcoeruleus nucleus in the lower brain stem is implicated in muscle tone inhibition during REM sleep in animal models and it is particularly involved in the control of muscle atonia during REM sleep in humans.[44] In addition, the tone of upper airway muscles is regulated by serotoninergic neurons in the caudal raphe nuclei, which contribute to SDB.[45,46] Another possible explanation is that the autonomic dysfunction of patients with PD and RBD may contribute to the occurrence or aggravation of SDB.[47] The nucleus ambiguus supplies efferent motor fibers to the vagus nerve that inhibit the heart rate via preganglionic parasympathetic neurons as well as the efferent motor fibers of the glossopharyngeal nerve that control the upper airway muscles. Accordingly, the progressive autonomic denervation in patients with PD and RBD might be strongly associated with the lack of coordination of the upper airway muscle that reduces the threshold of apnea occurrence.[48,49] Therefore, the influence of RBD on OSA is intricately interconnected with complex neural circuits and various neurotransmitters. Further large-scale cohort and longitudinal studies are needed to corroborate these findings.

INFLUENCE OF OSA ON REM SLEEP BEHAVIOR DISORDER: IMPLICATIONS FOR NEURODEGENERATION

RBD may be one of the strongest predictors of neurodegeneration, especially in synucleinopathies.[10,11] In a recent systematic review and meta-analysis, 32% of the patients with iRBD were converted to neurodegenerative diseases after a mean follow-up of 4.75 years and almost half (43%) converted to PD, followed by dementia with Lewy bodies (25%).[50] The estimated risk of iRBD for neurodegenerative disease was approximately 97%, with a follow-up of 14.2 years.[50] In addition, PSG-proven RBD has been recognized as a prodromal marker for PD with the highest likelihood ratio (LR=130).[13]

Recently, nationwide population-based studies have provided epidemiological evidence linking OSA with subsequent PD diagnosis.[51–54] However, the design of these cohort studies could not identify whether OSA was a prodromal risk factor for PD or merely one of the early symptoms of prodromal PD.[51–54] The focus should be on OSA that truly affects the neurodegenerative process in patients with iRBD. Bugalho et al[39] found that cognitive, urinary, and gastrointestinal dysfunction and daytime sleepiness were worse in the group with RBD and OSA than in those with RBD without OSA. Patients with PD and OSA had worse Mini-Mental State Examination scores than those without OSA, but patients with PD and RBD and OSA showed worse results than the 2 aforementioned groups.[40] The cognitive deterioration appeared to be influenced by the coexistence of RBD and OSA.[40] According to the "cognitive reserve theory,"[55] a detrimental effect of OSA can accelerate the cognitive dysfunction of the small cognitive reservoir from the beginning or in patients who already carry cognitive defects.[56]

OSA induces neurodegenerative changes via 2 integral processes: intermittent hypoxemia and sleep fragmentation.[57] Intermittent hypoxemia stimulates oxidative stress–induced neuroinflammation, which has been implicated in the pathogenesis of cognitive decline in older adults as well as in neurodegenerative diseases.[58,59] Intermittent hypoxia-induced upregulation of nuclear factor-kappa B, which is the master transcriptional switch of inflammation, has been associated with increased production of inflammatory markers such as tumor necrosis factor-α, interleukin-6, and C-reactive protein in patients with OSA.[60–63] These inflammatory markers have the potential to progress to neurodegeneration in individuals with OSA.[64] Moreover, sleep fragmentation can independently induce cognitive decline in older patients with OSA.[65] Chronic sleep fragmentation induces the cortical expression of tumor necrosis factor-α, and mice treated with a tumor necrosis factor-α neutralizing antibody showed no sleepiness and learning deficits associated with sleep fragmentation.[66] Accordingly, similar to intermittent hypoxia, sleep fragmentation induces oxidative stress and neuroinflammation. Another emerging concept is the glymphatic system, which is mainly activated during sleep.[67,68] Sleep fragmentation disrupts the smooth circulation of cerebrospinal fluid and the clearance of misfolded proteins, which results in increased accumulation of amyloid-β, tau, and α-synuclein and accelerated neurodegeneration.[69] Moreover, the effects of intermittent hypoxemia and sleep fragmentation on the locus coeruleus (LC) may have significant implications for PD pathophysiology, especially with regard to cognitive dysfunction. In an in vivo model of sleep apnea, repetitive hypoxia induced irreversible damage of the noradrenergic neurons in the LC.[70] Sleep fragmentation also reduced neuronal excitability in the LC and axonal projections into the

Figure 1—Hypothetical mechanistic relationship between REM sleep behavior disorder, obstructive sleep apnea, and neurodegeneration.

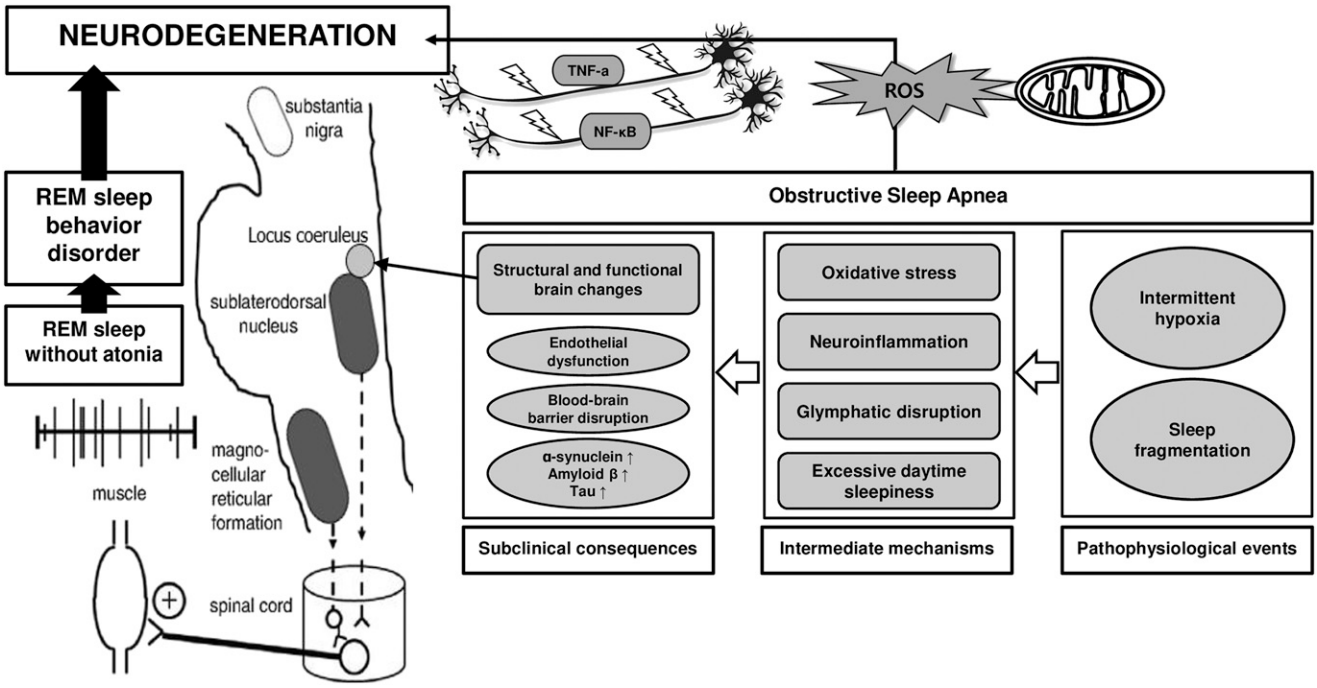

A direct pathway from the sublaterodorsal nucleus and an indirect pathway from the magnocellular reticular formation to the spinal interneurons might contribute to muscle atonia during REM sleep. Lesions in the caudal brainstem involving these pathways are thought to eliminate atonia during REM sleep, leading to RBD. In RBD, a neurodegenerative process already occurs and OSA may hypothetically play an additive role in accelerating neurodegeneration via several mechanisms induced by repetitive hypoxia and sleep fragmentation. OSA is likely to have a deleterious impact on multiple brain areas, especially on the locus coeruleus, and promote the accumulation of abnormal proteins, such as α-synuclein, amyloid-β, or tau. NF-κB = nuclear factor-kappa B, OSA = obstructive sleep apnea, RBD = rapid eye movement sleep behavior disorder, REM = rapid eye movement, ROS = reactive oxygen species, TNF-α = tumor necrosis factor-alpha.

LC, which is the main region of the wake cycle.[71] The noradrenergic neurons of the LC are connected with dopaminergic neurons of the substantia nigra pars compacta and are strongly associated with frontal cognitive function in patients with early PD.[72,73] Finally, excessive daytime sleepiness frequently observed in patients with OSA might increase the risk of neurodegeneration. In patients with OSA, excessive daytime sleepiness is not only the result of nonrestorative nighttime sleep[74] but it might also aggravate neurodegeneration by disrupting the normal sleep-wake cycle. At the same time, excessive daytime sleepiness is an early biomarker in patients with iRBD and causes neuronal loss and α-synuclein deposition in the arousal system during the preclinical stage of PD.[75,76] OSA may hypothetically play an additive role in accelerating neurodegeneration in conditions predisposing to neurodegeneration in patients with iRBD via several mechanisms mentioned above (**Figure 1**). However, further studies are needed to corroborate these hypotheses.

MANAGEMENT OF REM SLEEP BEHAVIOR DISORDER COMBINED WITH OSA

The medical treatment options for RBD are clonazepam and melatonin.[77] Clonazepam has been the traditional treatment for RBD.[77] However, clonazepam should be used with caution in patients with concomitant OSA due to worsening of sleep apnea or its onset even at a low dose.[78,79] Moreover, the treatment outcomes with clonazepam have not been complete in patients with RBD combined with OSA.[80] Although there are no prospective, randomized controlled trials comparing clonazepam with melatonin yet,[81] melatonin is considered as a first-line drug for treatment of RBD due to favorable treatment outcomes in terms of reduced risk of injury and fewer adverse effects.[82] In 4 patients with RBD with concomitant OSA, prolonged release of melatonin (2 mg) led to a clinical improvement in RBD symptoms of all treatment-naïve patients with OSA.[83] However, the proportion of RWA measured by PSG showed considerable variation between patients, and no symptomatic improvement was observed with melatonin.[83] Another management option is CPAP, which is the gold-standard treatment for moderate to severe OSA.[16] However, few studies have discussed the effect of CPAP on patients with RBD accompanied by OSA. Gabryelska et al[35] reported that CPAP treatment improved the self-reported RBD symptoms in patients with RBD accompanied by OSA. However, compliance with CPAP did not show statistical difference between individuals who experienced an improvement in RBD with CPAP and those who did not.[35] The severity of OSA also did not influence the RBD response to CPAP treatment.[35] In that study, 50% of the CPAP users and 52.9% of

the non-CPAP users noticed an improvement in their RBD symptoms after lifestyle change.[35] Lifestyle modifications such as weight loss through a hypocaloric diet and moderate exercise, avoidance of smoking and drinking, and increase sleep hygiene are common recommendations for patients with OSA.[84]

Patients diagnosed with concomitant RBD and OSA should first use the CPAP, followed by medications for remaining RBD symptoms. CPAP is a safe and effective treatment for OSA[16] and may enhance the effectiveness and safety of medical treatment for RBD, such as clonazepam and melatonin. Further studies investigating the efficacy and long-term benefits of CPAP in preventing neurodegeneration in patients with concomitant RBD and OSA are necessary. Moreover, other therapeutic modalities of OSA, such as oral devices (eg, mouthpiece) or surgery of the upper airway or jaw, can be considered in patients with RBD accompanied by OSA.[85]

CONCLUSIONS

Although RBD and OSA may occasionally share similar manifestations of DEB and reciprocal modulation, they are different sleep disorders with different effects on the brain. RBD is initiated at the brain stem and spreads to the limb muscles in a top-down manner, whereas in OSA, upper airway obstruction occurs first, followed by apneic episodes affecting the brain in a bottom-up manner. It is essential to distinguish pseudo-RBD associated with OSA from RBD concomitant with OSA, because these 2 conditions have different clinical implications for neurodegeneration as well as different treatment options. Video PSG is mandatory to establish accurate diagnosis, and CPAP treatment is necessary to confirm the diagnosis in patients with clinical uncertainty. Furthermore, CPAP is the first treatment option for patients diagnosed with concomitant RBD and OSA. Further studies are needed to establish the role of OSA as a trigger of neurodegeneration and to determine whether RBD is a friend or foe of OSA.

ABBREVIATIONS

CPAP, continuous positive airway pressure
CPC, cardiopulmonary coupling
DEB, dream enactment behavior
iRBD, idiopathic rapid eye movement sleep behavior disorder
LC, locus coeruleus
OSA, obstructive sleep apnea
PD, Parkinson's disease
PSG, polysomnography
RBD, rapid eye movement sleep behavior disorder
REM, rapid eye movement
RWA, rapid eye movement sleep without atonia
SDB, sleep-disordered breathing

REFERENCES

1. American Academy of Sleep Medicine. *International Classification of Sleep Disorders*. 3rd ed. Darien, IL: American Academy of Sleep Medicine; 2014.
2. Olson EJ, Boeve BF, Silber MH. Rapid eye movement sleep behaviour disorder: demographic, clinical and laboratory findings in 93 cases. *Brain*. 2000;123(2):331–339.
3. Schenck CH, Mahowald MW. REM sleep behavior disorder: clinical, developmental, and neuroscience perspectives 16 years after its formal identification in SLEEP. *Sleep*. 2002;25(2):120–138.
4. Boeve BF. REM sleep behavior disorder: updated review of the core features, the REM sleep behavior disorder-neurodegenerative disease association, evolving concepts, controversies, and future directions. *Ann N Y Acad Sci*. 2010;1184(1):15–54.
5. Adler CH, Hentz JG, Shill HA, et al. Probable RBD is increased in Parkinson's disease but not in essential tremor or restless legs syndrome. *Parkinsonism Relat Disord*. 2011;17(6):456–458.
6. Boot BP, Boeve BF, Roberts RO, et al. Probable rapid eye movement sleep behavior disorder increases risk for mild cognitive impairment and Parkinson disease: a population-based study. *Ann Neurol*. 2012;71(1):49–56.
7. Frauscher B, Gschliesser V, Brandauer E, et al. REM sleep behavior disorder in 703 sleep-disorder patients: the importance of eliciting a comprehensive sleep history. *Sleep Med*. 2010;11(2):167–171.
8. Kang SH, Yoon IY, Lee SD, Han JW, Kim TH, Kim KW. REM sleep behavior disorder in the Korean elderly population: prevalence and clinical characteristics. *Sleep*. 2013;36(8):1147–1152.
9. Mahlknecht P, Seppi K, Frauscher B, et al. Probable RBD and association with neurodegenerative disease markers: a population-based study. *Mov Disord*. 2015;30(10):1417–1421.
10. St Louis EK, Boeve AR, Boeve BF. REM sleep behavior disorder in Parkinson's disease and other synucleinopathies. *Mov Disord*. 2017;32(5):645–658.
11. Zhang F, Niu L, Liu X, Liu Y, Li S, Yu H, Le W. Rapid eye movement sleep behavior disorder and neurodegenerative diseases: An update. *Aging Dis*. 2020;11(2):315–326.
12. Cova I, Priori A. Diagnostic biomarkers for Parkinson's disease at a glance: where are we? *J Neural Transmission*. 2018;125(10):1417–1432.
13. Heinzel S, Berg D, Gasser T, Chen H, Yao C, Postuma RB; MDS Task Force on the Definition of Parkinson's Disease. Update of the MDS research criteria for prodromal Parkinson's disease. *Mov Disord*. 2019;34(10):1464–1470.
14. Högl B, Stefani A, Videnovic A. Idiopathic REM sleep behaviour disorder and neurodegeneration—an update. *Nat Rev Neurol*. 2018;14(1):40–55.
15. Heinzer R, Vat S, Marques-Vidal P, et al. Prevalence of sleep-disordered breathing in the general population: the HypnoLaus study. *Lancet Respir Med*. 2015;3(4):310–318.
16. Gottlieb DJ, Punjabi NM. Diagnosis and management of obstructive sleep apnea. *JAMA*. 2020;323(14):1389–1400.
17. Adderley NJ, Subramanian A, Toulis K, et al. Obstructive sleep apnea, a risk factor for cardiovascular and microvascular disease in patients with type 2 diabetes: findings from a population-based cohort study. *Diabetes Care*. 2020;43(8):1868–1877.
18. Xu H, Wang J, Yuan J, et al. Implication of apnea-hypopnea index, a measure of obstructive sleep apnea severity, for atrial fibrillation in patients with hypertrophic cardiomyopathy. *J Am Heart Assoc*. 2020;9(8):e015013.
19. Punjabi NM, Caffo BS, Goodwin JL, et al. Sleep-disordered breathing and mortality: a prospective cohort study. *PLoS Med*. 2009;6(8):e1000132.
20. Wing YK, Lam SP, Li SX, et al. REM sleep behaviour disorder in Hong Kong Chinese: clinical outcome and gender comparison. *J Neurol Neurosurg Psychiatry*. 2008;79(12):1415–1416.
21. Kryger M, Roth T, Dement WC. *Principles and Practice of Sleep Medicine*. 6th ed. Philadelphia, PA: Elsevier; 2017.
22. Oh EH, Kim DJ, Kim KT, Kim S-J, Noh KH, Cho J-W. A patient with obstructive sleep apnea syndrome presenting with REM sleep behavior disorder mimicking symptoms. *J Korean Sleep Res Soc*. 2014;11(2):72–75.
23. Iranzo A, Santamaría J. Severe obstructive sleep apnea/hypopnea mimicking REM sleep behavior disorder. *Sleep*. 2005;28(2):203–206.
24. Nalamalapu U, Goldberg R, DiPhillipo M, Fry JM. Behaviors simulating REM behavior disorder in patients with severe obstructive apnea. *Sleep Res*. 1996;25:311.

25. Schenck CH, Milner DM, Hurwitz TD, Bundlie SR, Mahowald MW. A polysomnographic and clinical report on sleep-related injury in 100 adult patients. *Am J Psychiatry*. 1989;146(9):1166–1173.
26. Jang HJ, Kim B, Ryu HS, Lee G-H, Lee S-A. Two cases of REM sleep behavior disorder combined with severe obstructive sleep apnea: misdiagnosed as "pseudo-REM sleep behavior disorder" by diagnostic polysomnography. *J Korean Sleep Res Soc*. 2013;10(2):62–65.
27. Aldrich M, Eiser A, Lee M, Shipley JE. Effects of continuous positive airway pressure on phasic events of REM sleep in patients with obstructive sleep apnea. *Sleep*. 1989;12(5):413–419.
28. Brillante R, Cossa G, Liu PY, Laks L. Rapid eye movement and slow-wave sleep rebound after one night of continuous positive airway pressure for obstructive sleep apnoea. *Respirology*. 2012;17(3):547–553.
29. Miyamoto T, Miyamoto M, Suzuki K, et al. Comparison of severity of obstructive sleep apnea and degree of accumulation of cardiac 123I-MIBG radioactivity as a diagnostic marker for idiopathic REM sleep behavior disorder. *Sleep Med*. 2009; 10(5):577–580.
30. Thomas RJ, Mietus JE, Peng CK, Goldberger AL. An electrocardiogram-based technique to assess cardiopulmonary coupling during sleep. *Sleep*. 2005;28(9): 1151–1161.
31. Park Y, Choi S, Joo E. Electrophysiological difference in obstructive sleep apnea with and without REM sleep behavior disorder: cardiopulmonary coupling analysis. *J Sleep Disord Ther*. 2017;6(261):1000261.
32. Suetsugi M, Mizuki Y, Yamamoto K, Uchida S, Watanabe Y. The effect of placebo administration on the first-night effect in healthy young volunteers. *Prog Neuropsychopharmacol Biol Psychiatry*. 2007;31(4):839–847.
33. Burns JW, Consens FB, Little RJ, Angell KJ, Gilman S, Chervin RD. EMG variance during polysomnography as an assessment for REM sleep behavior disorder. *Sleep*. 2007;30(12):1771–1778.
34. Zhang J, Lam SP, Ho CK, et al. Diagnosis of REM sleep behavior disorder by video-polysomnographic study: is one night enough? *Sleep*. 2008;31(8): 1179–1185.
35. Gabryelska A, Roguski A, Simpson G, Maschauer EL, Morrison I, Riha RL. Prevalence of obstructive sleep apnoea in REM behaviour disorder: response to continuous positive airway pressure therapy. *Sleep Breath*. 2018;22(3):825–830. .
36. McCarter SJ, St Louis EK, Sandness DJ, et al. Diagnostic REM sleep muscle activity thresholds in patients with idiopathic REM sleep behavior disorder with and without obstructive sleep apnea. *Sleep Med*. 2017;33:23–29.
37. McCarter SJ, St Louis EK, Duwell EJ, et al. Diagnostic thresholds for quantitative REM sleep phasic burst duration, phasic and tonic muscle activity, and REM atonia index in REM sleep behavior disorder with and without comorbid obstructive sleep apnea. *Sleep*. 2014;37(10):1649–1662.
38. Huang J, Zhang J, Lam SP, et al. Amelioration of obstructive sleep apnea in REM sleep behavior disorder: implications for the neuromuscular control of OSA. *Sleep*. 2011;34(7):909–915.
39. Bugalho P, Mendonça M, Barbosa R, Salavisa M. The influence of sleep disordered breathing in REM sleep behavior disorder. *Sleep Med*. 2017;37: 210–215.
40. Huang JY, Zhang JR, Shen Y, et al. Effect of rapid eye movement sleep behavior disorder on obstructive sleep apnea severity and cognition of Parkinson's disease patients. *Chin Med J (Engl)*. 2018;131(8):899–906.
41. Jo S, Kim HW, Jeon JY, Lee SA. Protective effects of REM sleep without atonia against obstructive sleep apnea in patients with idiopathic REM sleep behavior disorder. *Sleep Med*. 2019;54:116–120.
42. Zhang LY, Liu WY, Kang WY, et al. Association of rapid eye movement sleep behavior disorder with sleep-disordered breathing in Parkinson's disease. *Sleep Med*. 2016;20:110–115.
43. Cochen De Cock V, Abouda M, Leu S, et al. Is obstructive sleep apnea a problem in Parkinson's disease? *Sleep Med*. 2010;11(3):247–252.
44. Boeve BF. Idiopathic REM sleep behaviour disorder in the development of Parkinson's disease. *Lancet Neurol*. 2013;12(5):469–482.
45. Fort P, Luppi PH, Sakai K, Salvert D, Jouvet M. Nuclei of origin of monoaminergic, peptidergic, and cholinergic afferents to the cat trigeminal motor nucleus: a double-labeling study with cholera-toxin as a retrograde tracer. *J Comp Neurol*. 1990;301(2):262–275.
46. Manaker S, Tischler LJ. Origin of serotoninergic afferents to the hypoglossal nucleus in the rat. *J Comp Neurol*. 1993;334(3):466–476.
47. Postuma RB, Montplaisir J, Lanfranchi P, et al. Cardiac autonomic denervation in Parkinson's disease is linked to REM sleep behavior disorder. *Mov Disord*. 2011; 26(8):1529–1533.
48. Petko B, Tadi P. *Neuroanatomy, Nucleus Ambiguus*. Treasure Island, FL: StatPearls Publishing; 2020.
49. Martín-Gallego A, González-García L, Carrasco-Brenes A, et al. Brainstem and autonomic nervous system dysfunction: a neurosurgical point of view. *Acta Neurochir Suppl (Wien)*. 2017;124:221–229.
50. Galbiati A, Verga L, Giora E, Zucconi M, Ferini-Strambi L. The risk of neurodegeneration in REM sleep behavior disorder: a systematic review and meta-analysis of longitudinal studies. *Sleep Med Rev*. 2019;43:37–46.
51. Chen JC, Tsai TY, Li CY, Hwang JH. Obstructive sleep apnea and risk of Parkinson's disease: a population-based cohort study. *J Sleep Res*. 2015;24(4): 432–437.
52. Chou PS, Lai CL, Chou YH, Chang WP. Sleep apnea and the subsequent risk of Parkinson's disease: a 3-year nationwide population-based study. *Neuropsychiatr Dis Treat*. 2017;13:959–965.
53. Sheu JJ, Lee HC, Lin HC, Kao LT, Chung SD. A 5-year follow-up study on the relationship between obstructive sleep apnea and Parkinson disease. *J Clin Sleep Med*. 2015;11(12):1403–1408.
54. Yeh NC, Tien KJ, Yang CM, Wang JJ, Weng SF. Increased risk of Parkinson's disease in patients with obstructive sleep apnea: a population-based, propensity score-matched, longitudinal follow-up study. *Medicine (Baltimore)*. 2016;95(2): e2293.
55. Stern Y. Cognitive reserve. *Neuropsychologia*. 2009;47(10):2015–2028.
56. Kaminska M, Lafontaine AL, Kimoff RJ. The interaction between obstructive sleep apnea and Parkinson's disease: possible mechanisms and implications for cognitive function. *Parkinsons Dis*. 2015;2015:849472.
57. Lajoie AC, Lafontaine AL, Kimoff RJ, Kaminska M. Obstructive sleep apnea in neurodegenerative disorders: current evidence in support of benefit from sleep apnea treatment. *J Clin Med*. 2020;9(2):E297.
58. Snyder B, Shell B, Cunningham JT, Cunningham RL. Chronic intermittent hypoxia induces oxidative stress and inflammation in brain regions associated with early-stage neurodegeneration. *Physiol Rep*. 2017;5(9):e13258.
59. Singh A, Kukreti R, Saso L, Kukreti S. Oxidative stress: a key modulator in neurodegenerative diseases. *Molecules*. 2019;24(8):E1583.
60. Htoo AK, Greenberg H, Tongia S, et al. Activation of nuclear factor kappaB in obstructive sleep apnea: a pathway leading to systemic inflammation. *Sleep Breath*. 2006;10(1):43–50.
61. Alberti A, Sarchielli P, Gallinella E, et al. Plasma cytokine levels in patients with obstructive sleep apnea syndrome: a preliminary study. *J Sleep Res*. 2003;12(4): 305–311.
62. Shamsuzzaman AS, Winnicki M, Lanfranchi P, et al. Elevated C-reactive protein in patients with obstructive sleep apnea. *Circulation*. 2002;105(21): 2462–2464.
63. Yokoe T, Minoguchi K, Matsuo H, et al. Elevated levels of C-reactive protein and interleukin-6 in patients with obstructive sleep apnea syndrome are decreased by nasal continuous positive airway pressure. *Circulation*. 2003; 107(8):1129–1134.
64. Baril AA, Carrier J, Lafrenière A, et al.Canadian Sleep and Circadian Network. Biomarkers of dementia in obstructive sleep apnea. *Sleep Med Rev*. 2018;42: 139–148.
65. Cohen-Zion M, Stepnowsky C, Johnson S, Marler M, Dimsdale JE, Ancoli-Israel S. Cognitive changes and sleep disordered breathing in elderly: differences in race. *J Psychosom Res*. 2004;56(5):549–553.
66. Ramesh V, Nair D, Zhang SX, et al. Disrupted sleep without sleep curtailment induces sleepiness and cognitive dysfunction via the tumor necrosis factor-α pathway. *J Neuroinflammation*. 2012;9(1):91.
67. Jessen NA, Munk AS, Lundgaard I, Nedergaard M. The glymphatic system: a beginner's guide. *Neurochem Res*. 2015;40(12):2583–2599.
68. Tarasoff-Conway JM, Carare RO, Osorio RS, et al. Clearance systems in the brain—implications for Alzheimer disease. *Nat Rev Neurol*.2015;11(8):457–470. *Published correction appears in Nat Rev Neurol*. 2016;12(4):248.

69. Boland B, Yu WH, Corti O, et al. Promoting the clearance of neurotoxic proteins in neurodegenerative disorders of ageing. *Nat Rev Drug Discov*. 2018;17(9): 660–688.
70. Zhu Y, Fenik P, Zhan G, et al. Selective loss of catecholaminergic wake active neurons in a murine sleep apnea model. *J Neurosci*. 2007;27(37): 10060–10071.
71. Li Y, Panossian LA, Zhang J, et al. Effects of chronic sleep fragmentation on wake-active neurons and the hypercapnic arousal response. *Sleep*. 2014;37(1): 51–64.
72. Gesi M, Soldani P, Giorgi FS, Santinami A, Bonaccorsi I, Fornai F. The role of the locus coeruleus in the development of Parkinson's disease. *Neurosci Biobehav Rev*. 2000;24(6):655–668.
73. Del Tredici K, Braak H. Dysfunction of the locus coeruleus-norepinephrine system and related circuitry in Parkinson's disease-related dementia. *J Neurol Neurosurg Psychiatry*. 2013;84(7):774–783.
74. He K, Kapur VK. Sleep-disordered breathing and excessive daytime sleepiness. *Sleep Med Clin*. 2017;12(3):369–382.
75. Arnulf I, Neutel D, Herlin B, et al. Sleepiness in idiopathic REM sleep behavior disorder and Parkinson disease. *Sleep*. 2015;38(10):1529–1535.
76. Zhou J, Zhang J, Lam SP, et al. Excessive daytime sleepiness predicts neurodegeneration in idiopathic REM sleep behavior disorder. *Sleep*. 2017;40(5): zsx041.
77. Aurora RN, Zak RS, Maganti RK, et al. Best practice guide for the treatment of REM sleep behavior disorder (RBD). *J Clin Sleep Med*.2010;6(1):85–95. Published correction appears in *J Clin Sleep Med*. 2010;6(2):Table of contents.
78. Kimura K, Tachibana N, Oka Y, Shibasaki H. Obstructive sleep apnea seen in a patient with idiopathic REM sleep behavior disorder in the course of clonazepam treatment. *J Sleep Res*. 1998;7(Suppl 2):134.
79. Schuld A, Kraus T, Haack M, Hinze-Selch D, Pollmächer T. Obstructive sleep apnea syndrome induced by clonazepam in a narcoleptic patient with REM-sleep-behavior disorder. *J Sleep Res*. 1999;8(4):321–322.
80. Li SX, Lam SP, Zhang J, et al. A prospective, naturalistic follow-up study of treatment outcomes with clonazepam in rapid eye movement sleep behavior disorder. *Sleep Med*. 2016;21:114–120.
81. Schenck CH, Montplaisir JY, Frauscher B, et al. Rapid eye movement sleep behavior disorder: devising controlled active treatment studies for symptomatic and neuroprotective therapy—a consensus statement from the International Rapid Eye Movement Sleep Behavior Disorder Study Group. *Sleep Med*.2013;14(8):795–806. *Published correct appears in Sleep Med*. 2014; 15(1):157.
82. McCarter SJ, Boswell CL, St Louis EK, et al. Treatment outcomes in REM sleep behavior disorder. *Sleep Med*. 2013;14(3):237–242.
83. Schaefer C, Kunz D, Bes F. Melatonin effects in REM sleep behavior disorder associated with obstructive sleep apnea syndrome: a case series. *Curr Alzheimer Res*. 2017;14(10):1084–1089.
84. Carneiro-Barrera A, Díaz-Román A, Guillén-Riquelme A, Buela-Casal G. Weight loss and lifestyle interventions for obstructive sleep apnoea in adults: systematic review and meta-analysis. *Obes Rev*. 2019;20(5):750–762.
85. Lorenzi-Filho G, Almeida FR, Strollo PJ. Treating OSA: current and emerging therapies beyond CPAP. *Respirology*. 2017;22(8):1500–1507.

SUBMISSION & CORRESPONDENCE INFORMATION

Submitted for publication September 8, 2020
Submitted in final revised form January 9, 2021
Accepted for publication January 11, 2021
Address correspondence to: Eungseok Oh, MD, PhD, Department of Neurology, Chungnam National University Hospital, School of Medicine, Chungnam National University, 282 Munhwa-ro, Jung-gu, Daejeon 35015, Republic of Korea;
Tel: +82-42-280-7868; Fax: +82-42-252-8654;
Email: massive@cnuh.co.kr, massive@cnu.ac.kr

DISCLOSURE STATEMENT

All authors have seen and approved this manuscript. Work for this study was performed at Daejeon St. Mary's Hospital and Chungnam National University Hospital in South Korea. The authors report no conflicts of interest.