Abdomen, lower back, lumbar spine and pelvis, injury
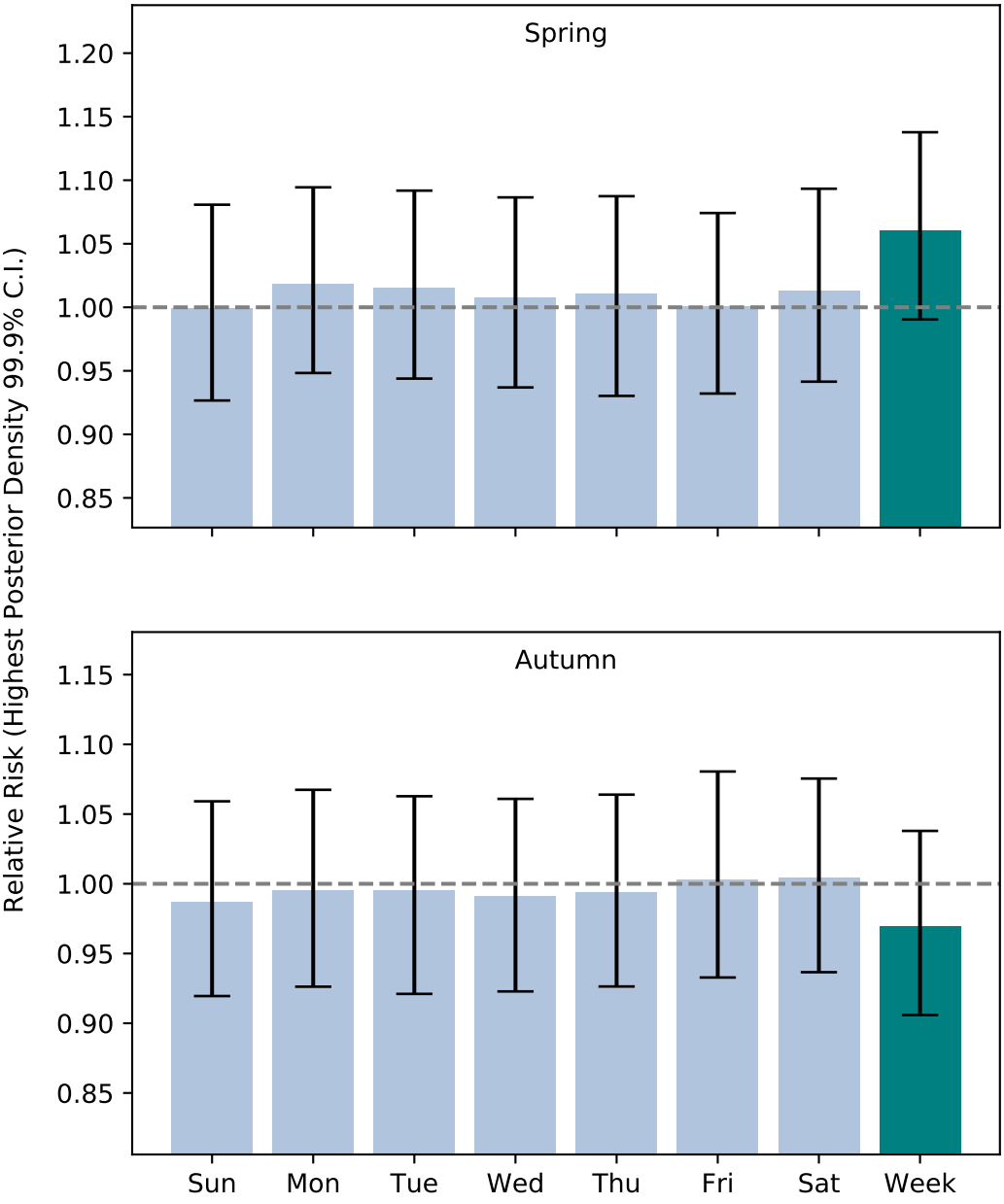
Male, 61-