Testing Medical VLM Generalization on Rare Cases

MedGemma, BiomedCLIP, and MedSigLIP on Open-MELON

Daan Merx, Domas Berulis, Roma den Otter

Introduction

Accurate histopathological classification of melanocytic lesions remains challenging even for expert dermatopathologists, with rare subtypes like Spitz tumors frequently mimicking melanoma. This study evaluates how effectively medical vision-language models (VLMs) generalize to these diagnostically ambiguous cases, comparing caption-based MedGemma against embedding-based classifiers on melanoma vs. nevus classification.

Methodology

We use Open-MELON-VL-2.5K, a histopathology dataset with 913 usable samples (597 melanoma, 316 benign). The dataset has no diagnosis labels, so we assign ground truth via Gemini (gemma-3-27b-it) from caption text.

MedGemma (4B, Q4_K_M quantized) generates captions for each image, classification is by keyword extraction from the output. We test 12 prompt/decoding configurations. As an additional comparison, we extract BiomedCLIP (512-d) and MedSigLIP (1152-d) embeddings and train LogReg, SVM, and Random Forest classifiers.

Results

MedGemma predicts "melanoma" for nearly every sample: 99.4% melanoma recall but only 0.7% nevus recall (50.6% balanced accuracy). Prompt ablation across all 12 configurations confirms this is a model-level limitation, not a prompt engineering problem.

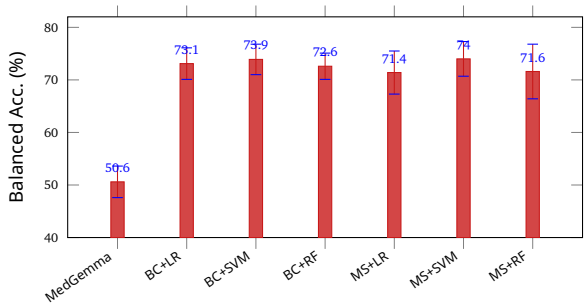

Figure 1: Balanced accuracy (10 trials). BC = BiomedCLIP, MS = MedSigLIP.

Embedding classifiers reach ∼74% balanced accuracy, confirming the images carry visual signal that MedGemma fails to use. Since MedGemma uses MedSigLIP as its vision encoder, and MedSigLIP + SVM matches BiomedCLIP + SVM, the failure is in language generation, not the visual backbone.

Both embedding models fail on the same 35 diagnostically ambiguous cases (Spitz tumors, desmoplastic melanomas, etc.) that challenge even expert dermatopathologists, suggesting a performance ceiling set by genuine morphological ambiguity.

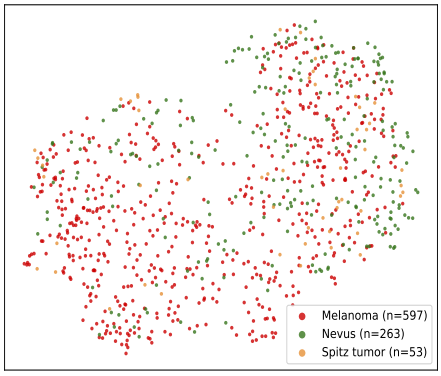

Figure 2: UMAP of MedSigLIP embeddings. Nevus and melanoma only slightly separate, but Spitz tumors scatter across melanoma-dense regions.

Discussion

MedGemma has likely never seen benign melanocytic histopathology during training, so it associates any melanocytic features with melanoma. This explains the near-universal melanoma prediction.

Labels derived from caption text via Gemini rather than expert annotation may also contribute noise to these results.

Future work should target fine-tuning on labeled melanoma histopathology, testing the larger 27B variant, and evaluating MedGemma on domains where it has direct training data (e.g. colon pathology, chest X-rays).

Project page: `https://github.com/helloimdomas/ai-medical-imaging-open`

Department of Biomedical Engineering