

# Cutaneous neurofibromas

## Current clinical and pathologic issues

Nicolas Ortonne, MD, PhD,\* Pierre Wolkenstein, MD, PhD,\* Jaishri O. Blakeley, MD, Bruce Korf, MD, PhD, Scott R. Plotkin, MD, PhD, Vincent M. Riccardi, MD, MBA, Douglas C. Miller, MD, PhD, Susan Huson, MD, Juha Peltonen, MD, PhD, Andrew Rosenberg, MD, Steven L. Carroll, MD, PhD, Sharad K. Verma, PhD, Victor Mautner, MD, Meena Upadhyaya, PhD, and Anat Stemmer-Rachamimov, MD

*Neurology*® 2018;91 (Suppl 1):S5-S13. doi:10.1212/WNL.0000000000005792

### Abstract

#### Objective

To present the current terminology and natural history of neurofibromatosis 1 (NF1) cutaneous neurofibromas (cNF).

#### Methods

NF1 experts from various research and clinical backgrounds reviewed the terms currently in use for cNF as well as the clinical, histologic, and radiographic features of these tumors using published and unpublished data.

#### Results

Neurofibromas develop within nerves, soft tissue, and skin. The primary distinction between cNF and other neurofibromas is that cNF are limited to the skin whereas other neurofibromas may involve the skin, but are not limited to the skin. There are important cellular, molecular, histologic, and clinical features of cNF. Each of these factors is discussed in consideration of a clinicopathologic framework for cNF.

#### Conclusion

The development of effective therapies for cNF requires formulation of diagnostic criteria that encompass the clinical and histologic features of these tumors. However, there are several areas of overlap between cNF and other neurofibromas that make distinctions between cutaneous and other neurofibromas more difficult, requiring careful deliberation with input across the multiple disciplines that encounter these tumors and ultimately, prospective validation. The ultimate goal of this work is to facilitate accurate diagnosis and meaningful therapeutics for cNF.

#### Correspondence

Dr. Wolkenstein  
pierre.wolkenstein@aphp.fr

#### RELATED ARTICLES

Creating a comprehensive research strategy for cutaneous neurofibromas  
Page S1

The biology of cutaneous neurofibromas: Consensus recommendations for setting research priorities  
Page S14

Considerations for development of therapies for cutaneous neurofibroma  
Page S21

Clinical trial design for cutaneous neurofibromas  
Page S31

\*These authors contributed equally to this work.

From the Departments of Pathology (N.O.) and Dermatology (P.W.), French Referral Center for Neurofibromatoses, Henri-Mondor Hospital, AP-HP, University Paris Est Créteil, France; Department of Neurology (J.O.B., S.K.V.), Johns Hopkins University School of Medicine, The Neurofibromatosis Therapeutic Acceleration Program, Baltimore, MD; University of Alabama at Birmingham (B.K.); Cancer Center and Department of Neurology (S.R.P.) and Department of Pathology, Division of Neuropathology (A.S.-R.), Massachusetts General Hospital, Boston; The Neurofibromatosis Institute (V.M.R.), La Crescenta, CA; Department of Pathology & Anatomical Sciences (D.C.M.), University of Missouri School of Medicine, Columbia; Manchester Centre for Genomic Medicine (S.H.), Central Manchester University Hospitals NHS Foundation Trust, Manchester Academic Health Science Centre, UK; Institute of Biomedicine (J.P.), University of Turku, Finland; Department of Pathology and Laboratory Medicine (A.R.), Jackson Memorial Hospital/University of Miami Miller School of Medicine, FL; Department of Pathology and Laboratory Medicine (S.L.C.), Medical University of South Carolina, Charleston; Clinics and Polyclinics of Neurology (V.M.), University Hospital Hamburg-Eppendorf, Hamburg, Germany; and Division of Cancer and Genetics (M.U.), Institute of Medical Genetics, Cardiff University, UK.

Go to [Neurology.org/N](http://Neurology.org/N) for full disclosures. Funding information and disclosures deemed relevant by the authors, if any, are provided at the end of the article.

The Article Processing Charge was funded by The Neurofibromatosis Therapeutic Acceleration Program at Johns Hopkins.

This is an open access article distributed under the terms of the Creative Commons Attribution License 4.0 (CC BY), which permits unrestricted use, distribution, and reproduction in any medium, provided the original work is properly cited.

## Glossary

cNF = cutaneous neurofibromas; NF1 = neurofibromatosis type 1; NOS = not otherwise specified; OCT = optical coherence tomography; pNF = plexiform neurofibromas; QoL = quality of life; US = ultrasound.

There are many clinical features associated with the neurogenetic condition neurofibromatosis type 1 (NF1). However, the feature that affects the majority of NF1 patients is the development of cutaneous neurofibromas (cNF).<sup>1</sup> Neurofibromas are defined as histologically benign (WHO grade I) tumors composed of multiple cell types including Schwann cells, fibroblasts, immune cells (such as mast cells and macrophages), and other elements of nerve.<sup>2</sup> Regardless of their location, all neurofibromas share certain histologic and cellular characteristics.

The most common and prominent location of neurofibromas is the skin (skin is defined in this article as including epidermis and dermis). Discrete lesions are often referred to as dermal or cutaneous neurofibromas. cNF are benign and, unlike plexiform neurofibromas (pNF), are not known to have any malignant potential.<sup>3</sup>

Although not life-threatening, cNF have a major effect upon quality of life (QoL) for most patients with NF1 due to their prevalence and disfigurement.<sup>4–12</sup> Furthermore, the number of cNF increases with age after adolescence and throughout a patient's lifespan. Despite the high prevalence of cNF in people with NF1 and their documented influence on QoL, current treatment is limited to surgical removal or physical destruction.

There have been several efforts to define the various forms of neurofibromas, resulting in a number of classification systems proposed by neurologists, clinical geneticists, dermatologists, pathologists, and basic researchers (table 1).<sup>3,13–16</sup> Some of these schemes are incompatible with one another, which may impede, rather than enhance, the transfer of knowledge from basic and translational science to clinical care. An agreed-upon classification system would facilitate research addressing critical questions such as the comparisons between human disease and *Nf1* mouse models of cNF, whether there are specific responses to treatments based on potential subtypes of cNF, or if cNF might respond similarly or differently to therapies than other neurofibromas (potentially allowing cNF to serve as a surrogate for pNF). This article reviews the terms in current use for cNF and outlines the critical factors contributing to the definition of cNF, with the ultimate goal of creating a draft framework for a classification system to be validated in future prospective studies.

## Methods

This work is the result of 2 multidisciplinary meetings, one sponsored by the Neurofibromatosis Therapeutics Acceleration

Program in 2016, and another by The European Neurofibromatosis Group in 2008. Across these 2 meetings, international experts from within and outside the NF field (with expertise in dermatology, genetics, neurology, neuro-oncology, dermatopathology, neuropathology, regenerative medicine, and plastic surgery) reviewed different aspects of cNF, including clinical features, biology, effects on QoL, and existing proposed classification schemes of neurofibromas (table 1).

A literature search using the terms NF1, cNF, plexiform neurofibroma, dermal neurofibroma, classification, pain, itching, and QoL was completed. Although cNF may be sporadic in some instances, this review is focused on the cNF arising in the context of NF1. The investigators met to review these areas, including critical elements of each proposed classification system, with the intent of using this information as a framework for the longer-term goal of developing a single unified, data-driven classification system for cNF incorporating core features of cNF including pattern of growth (localized or diffuse) and anatomical location (skin, subcutaneous tissue, or deep nerve).

## Results

### Cutaneous neurofibromas: Clinical definitions or descriptors

This article is focused on cNF, which are benign and arise in and are limited to the skin. They are localized but not encapsulated and do not show clear association to myelinated nerves. They present clinically as a well-defined cutaneous lesion, most often as a nodule or plaque.<sup>3</sup> cNF is the preferred term over dermal neurofibroma, as the term cNF distinguishes between discrete neurofibromas of the skin and neurofibromas that arise in deeper tissues but invade into the dermis. The term cNF does not encompass deep, large, or diffusely infiltrating tumors that involve the dermis.<sup>3</sup> However, the skin may also be secondarily involved by extension of a deep or plexiform neurofibroma, either by involvement of cutaneous nerves (i.e., plexiform growth pattern) or by diffuse infiltration of the subcutaneous and cutaneous tissue (i.e., diffuse growth pattern). The importance of distinguishing true cNF from extension of deep neurofibromas into the skin is particularly important when atypical changes are present. The presence of cytologic atypia or proliferation in a cNF represents reactive or degenerative changes and is not worrisome, while similar changes in a plexiform neurofibroma that may involve the skin can be a manifestation of malignant transformation.<sup>17</sup>

### Natural history of cNF

cNF most commonly become clinically apparent after puberty.<sup>1</sup> However, there is a wide range of clinical presentation

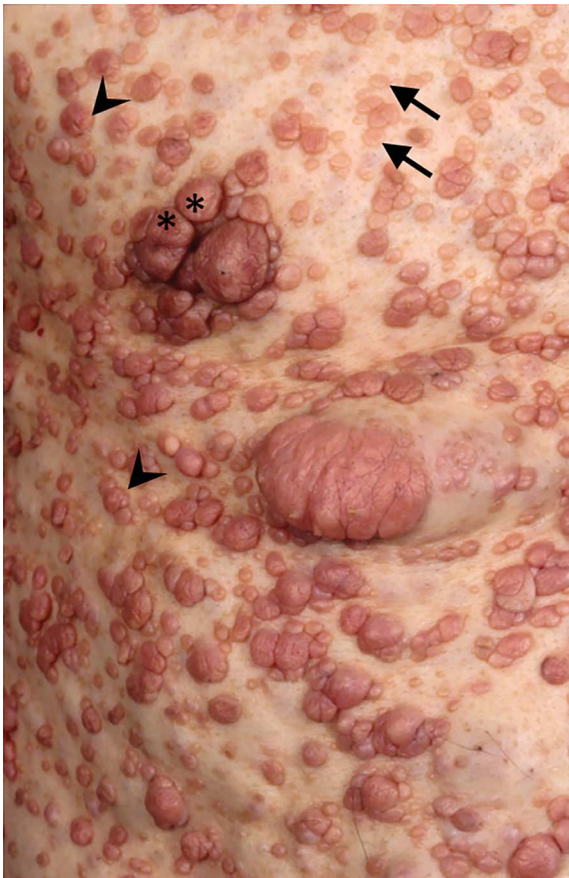
**Table 1** Clinicopathologic classification of neurofibromas

Proposed classification	Proposed by
Cutaneous neurofibromas	Jouhilahti et al. <sup>3</sup>
Subcutaneous neurofibromas	
Intraneural neurofibromas	
Plexiform neurofibromas	
Localized cutaneous neurofibromas	Carroll and Ratner <sup>13</sup>
Diffuse cutaneous neurofibromas	
Localized intraneural neurofibromas	
Plexiform neurofibromas	
Massive soft tissue	
Localized neurofibromas	Rosenberg <sup>14</sup>
Plexiform neurofibromas	
Diffuse neurofibromas	
Pigmented neurofibromas	
Dermal neurofibromas	Huson <sup>15</sup>
Nodular neurofibromas	
Plexiform neurofibromas	
Discrete cutaneous neurofibromas of the dermis and epidermis (endoneurial neurofibroma)	Friedman and Riccardi <sup>16</sup>
Discrete subcutaneous neurofibromas that lie deeper in the skin (perineurial neurofibroma)	
Nodular plexiform neurofibromas (perineurial neurofibroma)	
Diffuse plexiform neurofibromas (epineurial neurofibroma)	
Cutaneous neurofibromas	Goldblum et al. <sup>44</sup>
Subcutaneous neurofibromas	
Diffuse neurofibromas	
Localized cutaneous neurofibromas	Stemmer-Rachamimov, Wolkenstein, and Ortonne (unpublished, 2008)
Localized subcutaneous neurofibromas	
Diffuse cutaneous and subcutaneous neurofibromas	
Localized intraneural neurofibromas	
Plexiform neurofibromas	

with select genotype–phenotype correlations. In the small subset of people with *NF1* microdeletions, cNF are more likely to be apparent earlier in childhood.<sup>18</sup> In contrast, in people with *NF1* deletion in p.Met992del, or a missense mutation affecting p.Arg1809, there are few to no cNF throughout life.<sup>19–22</sup> Additional details around the biology of genotype–phenotype correlations are discussed by Brosseau et al.<sup>23</sup> in this series. In the majority of people with *NF1*, the number of cNF increases with age such that there are more tumors present in older patients.<sup>1</sup> There are no known predictive factors to determine the eventual

number or types of cNF that will appear on an individual with *NF1* (other than the small subsets with specific types of mutation listed above). Furthermore, there is dramatic variability in cNF burden between patients, and even within families harboring the same *NF1* mutation. Retrospective studies suggest that women experience an increase in the size and numbers of cNF during pregnancy.<sup>24–26</sup> Finally, it has been suggested that people with *NF1* have low serum vitamin D concentrations, especially those with many cNF. However, it is not clear if these factors are causative or correlative.<sup>27</sup>

**Figure 1** Polymorphism of cutaneous neurofibromas (cNF) in a single patient



Many different aspects of cNF can be seen in this patient, including sessile cNF (arrows), globular cNF (arrowheads), and pedunculated cNF (asterisks). NF = neurofibromas.

### Clinical features and effect on QoL

Patients and clinicians report multiple different appearances of cNF, ranging from barely visible flat nodules with subtle discoloration to large and pedunculated masses (figure 1). It remains unknown if this variability in appearance is an expression of the various stages of the evolution of a single tumor, or represents different subtypes of cNF. One proposed classification system assigns 1 of 5 subcategories to describe the clinical appearance of cNF<sup>28</sup>: nascent, flat, sessile, globular, or pedunculated (figure 2). The nascent/latent cNF (figure 2A) is not apparent by inspection or palpation of the skin, but can be appreciated by proper imaging techniques, such as high-resolution ultrasound (US) and optical coherence tomography (OCT) imaging, which are discussed by Cannon et al.<sup>29</sup> in this series. The flat cNF (figure 2B) is visible at the skin surface, and is distinguished primarily by its slightly raised surface. The surface may appear thinner and somewhat pale compared to adjacent uninvolved skin, or there may be some increased pigmentation and peripheral coarse hairs (bristles). Flat cNF tend to range in size from 0.5 to 12 millimeters. The sessile cNF (figure 2C) is raised compared to the adjacent skin and there is usually an apparent apex. The height of the apex may be as high

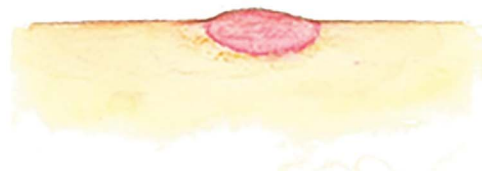as 8–10 mm. The surface and texture are essentially the same as that of the flat lesion. There may be erythema or hyperpigmentation, as well as bristle hirsutism. These lesions typically have a maximal diameter of roughly 1.0 to 10–12 mm. Imaging (US or OCT) may reveal more extensive cNF elements below the surface of the skin. The globular cNF (figure 2D) has a base at the surface of the skin that may be 20–30 mm in diameter, with a comparable height and a globular shape. Moving the raised portion of globular neurofibromas (i.e., above the surrounding uninvolved skin surface) can help a clinical examiner

**Figure 2** Proposed categories of clinically observed cutaneous neurofibromas (cNF) to be considered in the prospective validation study

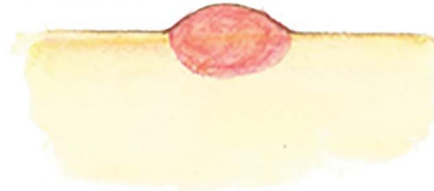
#### A. Nascent/latent cNF



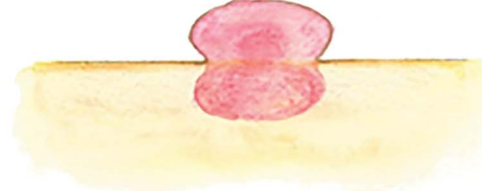
#### B. Flat cNF



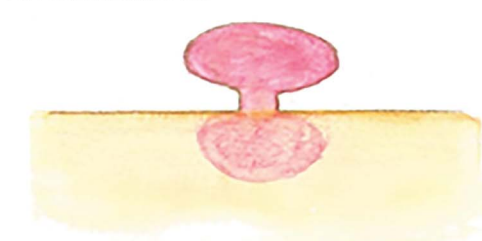
#### C. Sessile cNF



#### D. Globular cNF



#### E. Pedunculated cNF



(A) Nascent/latent cNF. (B) Flat cNF. (C) Sessile cNF. (D) Globular cNF. (E) Pedunculated cNF.

to identify a deeper part of the lesion. The pedunculated cNF (figure 2E) has a stalk that joins the portions above and below the skin surface. The stalk is usually several millimeters long and 1–3 mm in diameter. The diameter of the superficial portion is usually between 5 and 25 millimeters.

Roughly 20% of people with NF1 report pruritus.<sup>30</sup> Chronic pruritus can be an independent factor for altered QoL as it causes sleep disruption as well as the emotional experience of chronic pain.<sup>30</sup> Among those with pruritus, 52.5% complained of pruritus localized to one or more cNF. The pathophysiology of pruritus in NF1 is not well-understood. It is hypothesized that mast cells and components released from their degranulation are a major cause of pruritus, as mast cells are well-known to be present in the cNF microenvironment and may contribute to tumor initiation, progression, and angiogenesis.<sup>31–36</sup> However, it is also possible that pruritus is a manifestation of a neuropathy affecting the small nerve tributaries in the skin, which are integral to the development of these tumors.<sup>30,37</sup> Indeed, anecdotally, people with NF1 report improvement in pruritus after therapy with anti-neuropathic agents such as gabapentin or mast cell stabilizing agents such as ketotifen, indicating that both mechanisms may be active.

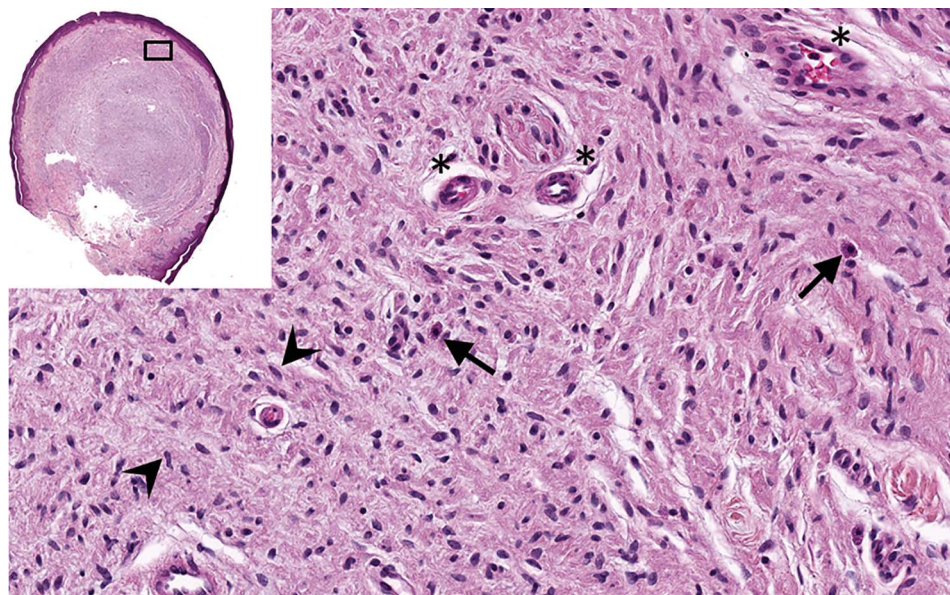
Although cNF are not life-threatening, the majority of patients report cNF-associated disfigurement as their major problem related to NF1. Combined responses from several surveys show that between 97% and 100% of adults with NF1 who participated reported skin lesions and >60% reported moderate to severe visibility of these lesions.<sup>8,9,11,12</sup> In all of these studies, the visibility of disease was independently associated with adverse emotional state, physical symptoms, and poor function

assessed with skin-disease-specific QoL and general health measures.<sup>11,12</sup> The effect of disfigurement on QoL has been evaluated through the use of dermatologic scales such as Skindex.<sup>8,9,12</sup> Using this tool as well as measures of overall disease-associated QoL (i.e., Short Form–36), the burden of disfigurement on QoL in patients with NF1 has been highlighted across multiple studies.<sup>5,6,8–11,38</sup> The greatest effect on QoL from cNF is emotional: patients with more visible tumors report significantly greater overall negative effects on their skin-disease-specific QoL, and visible features of cNF are associated with severe depression. The magnitude of this effect is similar to that reported in the literature for patients with psoriasis, a skin condition traditionally regarded as causing significant disability. These results underscore the link between cNF disease visibility and psychological well-being.<sup>11</sup> As such, reducing deformity is a priority in adult patients with NF1.<sup>11</sup> For example, people with NF1 who graded themselves to be more severely affected expressed greater fear about the appearance of the lesions.<sup>12</sup>

### Histology of cNF

Histologically, all neurofibromas are mixed tumors consisting of cells of diverse lineages. cNF are composed of neoplastic Schwann cells and non-neoplastic elements including mast cells and fibroblasts.<sup>39</sup> There are also often other cells including nerve sheath elements (i.e., perineurial cells) and cells from various skin adnexae (e.g., hair follicles, eccrine sweat glands, sebaceous glands).<sup>13</sup> On occasion, adipocytes may be sequestered in or intrinsic to the lesion.<sup>40</sup> Correspondingly, the use of traditional histologic stains, as well as immunohistochemistry with a variety of biomarkers and electron microscopy, has shown the involvement of S100+ Schwann cells, EMA+ perineurial cells, mast cells, lymphocytes, CD34+ fibroblasts, as well

**Figure 3** Cutaneous neurofibromas (cNF), morphologic aspect



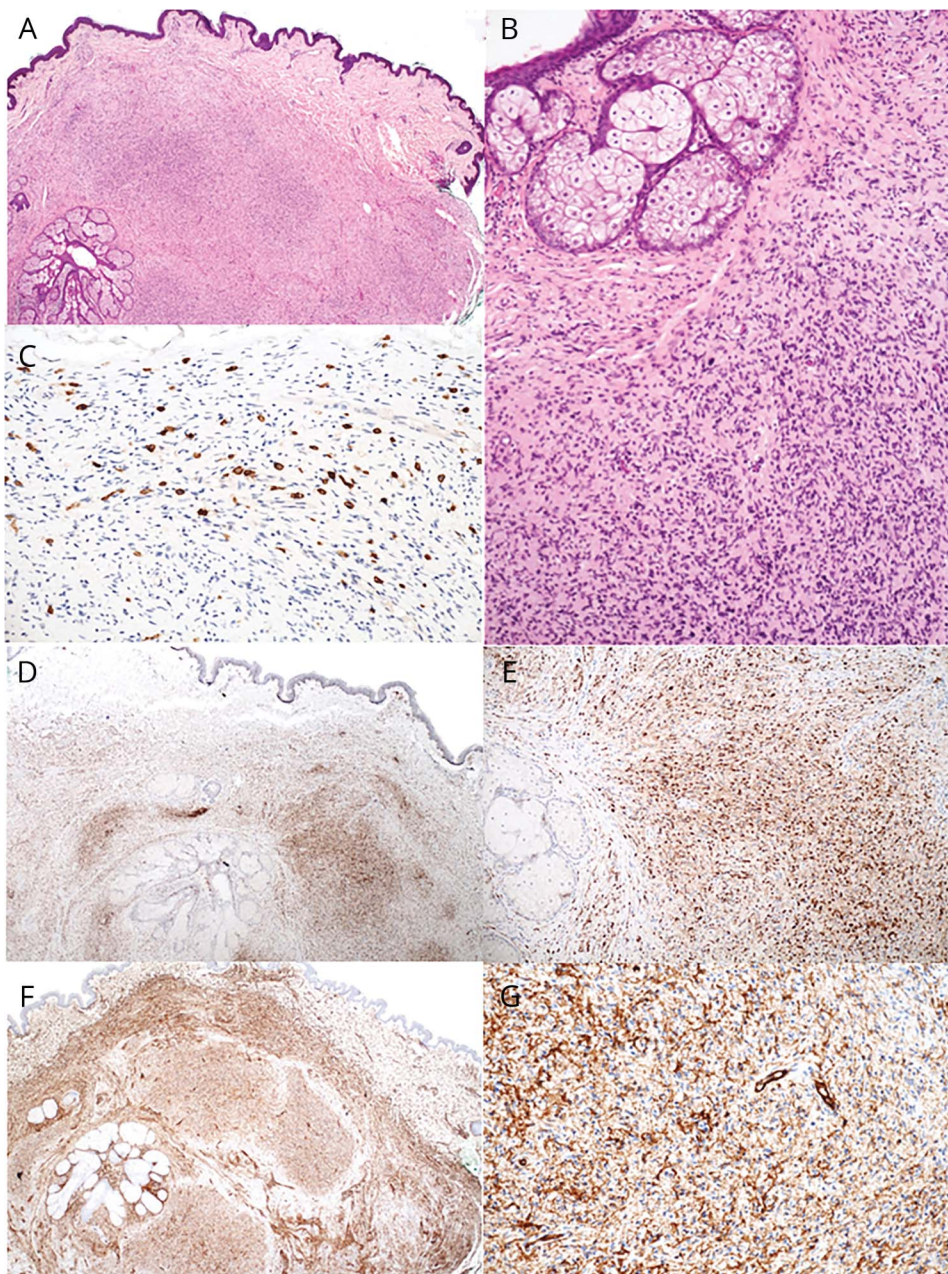
The lesion is made of scattered spindle cells (arrowheads) that correspond to Schwann cells and fibroblasts, admixed with numerous capillaries and veins (asterisks) and mast cells (arrows) (hematoxylin and eosin,  $\times 400$ , and inset  $\times 25$ ).

as axonal elements<sup>41,42</sup> (figures 3 and 4). Pigmented cNF may be associated with melanocytic cells (or the neoplastic Schwann cells that may become melanotic).<sup>43</sup> Other notable features seen on occasion include the formation of Meissner-like corpuscles.<sup>44</sup> It is presumed that the Schwann cells are neoplastic (*NF1*<sup>-/-</sup>) and that the other cells are either present initially or recruited into the lesion, but are not neoplastic (*NF1*<sup>-/+</sup>). However, the definitive cell of origin for human cNF has yet to be defined but has been postulated to be a progenitor cell called a skin-derived precursor cell. Preclinical models suggest that these cells are distinct from the cells that give rise to pNF.<sup>45</sup> There are additional data indicating that multipotent neurofibroma-derived precursor cells, perhaps arising from

stem cells around hair roots closely associated with cNF, are the causative cells.<sup>3</sup> Together, these data suggest that cNF and other forms of neurofibromas may arise from different precursor cells even though they have similar cellular compositions.

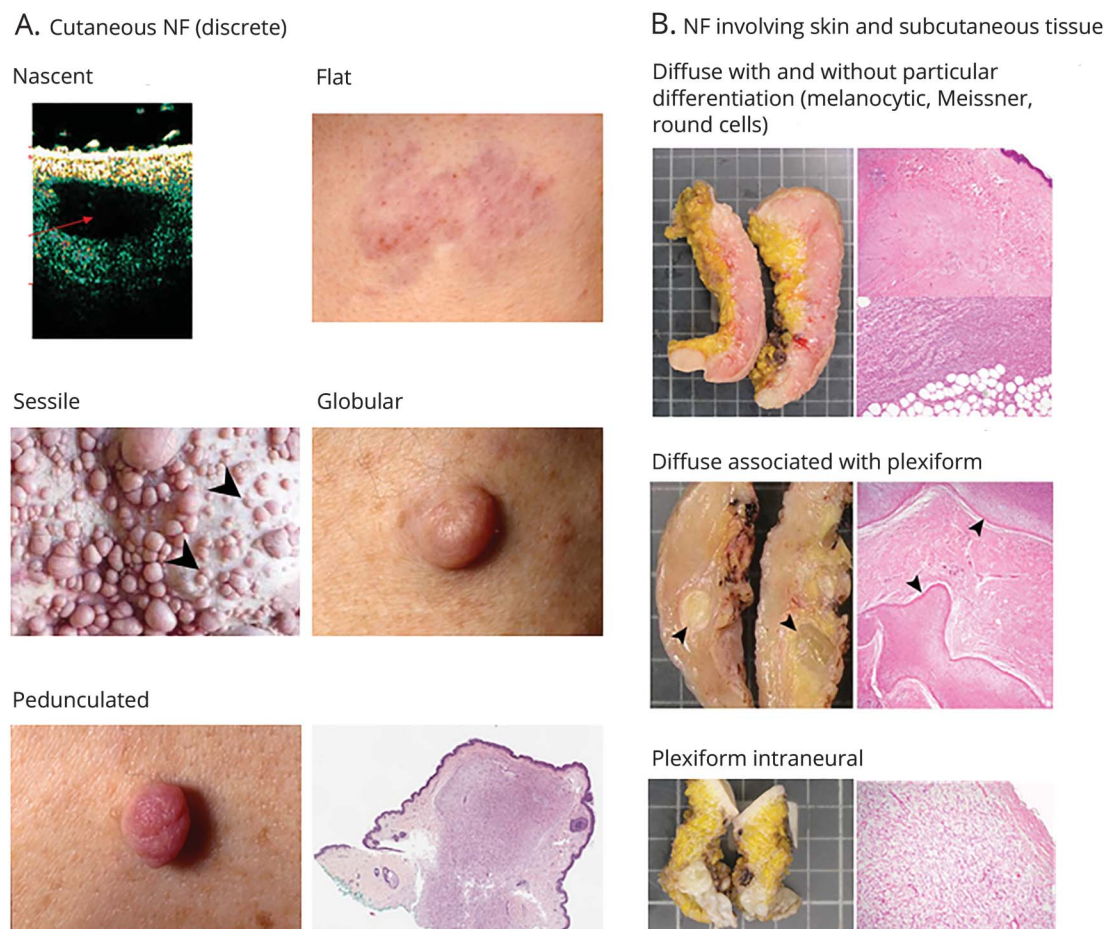
The diverse cellular components of neurofibromas are embedded in an abundant collagenous and often myxoid extracellular matrix. Histologically, cNF cannot be differentiated from neurofibromas elsewhere in the body as the features and cell composition are present in the various forms of neurofibromas. Hence, to accurately identify a lesion as cNF, the surgical specimen must include a margin of uninvolved skin.

**Figure 4** Histopathologic features of cutaneous neurofibromas (cNF)



cNF in which various cell types are evidenced using immunostainings. (A, B) Hematoxylin & eosin at 25 and 200 magnification show a cNF presenting as a self-limiting tumor in the skin with no peripheral capsule and in which numerous spindle cells are seen. (C-G) Immunostainings developed with DAB with antibodies to CD117 (C,  $\times 200$ ), S100 protein (D  $\times 25$  and E  $\times 100$ ), and CD34 (F  $\times 25$  and G  $\times 100$ ). These stains demonstrate numerous mast cells showing strong membrane expression of CD117 (C), Schwann cells displaying heterogeneous cytoplasmic and nuclear expression of S100 protein (D, E), and CD34+ fibroblasts (F,G).

**Figure 5** Unified clinicopathologic aspects of neurofibromas



(A) Clinical pictures show the various subtypes of cutaneous neurofibromas (cNF). This includes digital photographs of nascent (visible by ultrasound, but not the naked eye), flat, sessile, globular, and pedunculated cNF. The ultrasound image is courtesy of Dominique Pichard. The red arrow tip indicates the cNF involving the epidermis and dermis. (B) Gross and histologic pictures show the various NF subtypes involving skin and subcutaneous tissue (diffuse, with or without atypia). The upper panels show a cutaneous and subcutaneous NF with diffuse growth pattern replacing the dermis (upper right picture) and the subcutaneous fat tissue (hematoxylin & eosin,  $\times 25$  and  $\times 100$ ). The middle panels show a neurofibroma involving the dermis and subcutaneous tissue with 2 distinct growth patterns including plexiform (arrowheads) and diffuse (hematoxylin & eosin,  $\times 25$ ). The lower panels show a neurofibroma located entirely in the subcutaneous tissue with a plexiform neurofibroma with intraneural growth pattern (hematoxylin & eosin,  $\times 100$ ).

### Cutaneous neurofibromas as a subset of all neurofibromas: Plan to address the challenges in creating a modern classification system

In addition to classifications already published in articles or textbooks, other unpublished classification systems have been proposed. Two unpublished systems were presented at the European NF meeting (2008) by Ortonne et al. and Stemmer-Rachamimov et al., in which a comprehensive synthesis of clinical and pathologic features was attempted (table 1 and figure 5). These 2 systems are very similar and may be the basis of a new integrated classification system, if validated prospectively. These schemes propose defining neurofibromas by their clinical appearance and histologic features: growth pattern (diffuse/infiltrating or localized), relationship to nerve (intraneural or extraneural, without any perineurial capsule), and anatomic location (cutaneous, cutaneous/subcutaneous, deep). The resulting categories proposed were cutaneous NF (discrete) and larger NF involving skin and subcutaneous tissue

(diffuse, with or without atypia) (table 2). This scheme for cNF (table 2 and figure 5) aims to differentiate classic cNF from deep neurofibromas that may involve skin and subcutaneous tissues. As above, it is important to appreciate that an underlying plexiform NF extending into the skin (plexiform intraneural, diffuse associated with plexiform) has different risk profiles than cNF purely limited to the skin. This histologic distinction cannot be made if the sample provided does not reveal the underlying plexiform lesion and shows only the extraneural diffusely infiltrating portion of the tumor in skin. In such instances, histologic distinction from a true cNF is impossible and the term NF involving skin and subcutaneous tissue; diffuse, not otherwise specified (NOS) is most appropriate. Although molecular information is lacking, there is an opportunity to apply common terminology to classify neurofibromas clinically and pathologically in a systematic fashion. Based on the current state of the field, a modern classification system for cNF will be built on the defined clinical and

**Table 2** Potential unified classification system for cutaneous neurofibromas

A. Cutaneous neurofibromas (discrete)
Clinical variants
• Nascent (seen on ultrasound or similar imaging only)
• Flat
• Sessile
• Globular
• Pedunculated
B. Extensive neurofibromas (with or without atypia)
Histologic variants
• Diffuse with or without particular differentiation (melanocytic, Meissner/round cells)
• Diffuse associated with plexiform (plexiform and diffuse)
• Diffuse, not otherwise specified
• Plexiform intraneural

pathologic features (table 2) with a plan to incorporate molecular and imaging data as they become available. An ongoing study is evaluating the accuracy of this system with a blinded review by dermatopathologists and neuropathologists. The long-term goal is to have an integrated molecular, clinical, and pathologic classification that best reflects the biology of cNF.

As a first step, the term cNF should be reserved for the discrete neurofibroma limited to the skin, which develop into and mainly involve the dermis, never show a plexiform architecture, and never transform into a malignant peripheral nerve sheath tumor. Further research is needed to determine if there are subtypes of cNF. The term diffuse neurofibroma is advisable for neurofibromas that involve the skin and subcutaneous tissues without clear margins. These tumors may have a diffuse, plexiform, or both patterns. Inherent in these terms is an ambiguity between neurofibromas that are clinically localized but have no perineurial capsule and so could be histologically diffuse and those that are clinically more diffuse. In the case of partial biopsies or superficial excisions, one may miss a deeper plexiform organization or the involvement of a definable nerve trunk, and so the category for diffuse, NOS was introduced. It is important to note that the approach for resection and clinical description of the lesion is particularly important for these tumors. The term plexiform is applied to intraneural neurofibromas. These initial definitions will be applied to prospective validation studies across dermatopathologists and neuropathologists to formalize the pathologic definitions of cNF.

## Discussion

cNF are common and a major clinical burden for people with NF1, prominently affecting QoL and emotional well-being as

well as physical comfort. Currently, the only way of treating cNF is removal by procedural methods such as electrocauterization, CO<sub>2</sub> laser, or surgery.<sup>46</sup> Developing effective medical therapies for existing cNF and prevention of cNF are priorities for the majority of adults with NF1. Development of a reliable and widely accepted nosology based on clinical, genetic, and radiologic features of cNF is a crucial step in investigating these tumors to better understand their development and start to uncover opportunities for tumor-specific therapies that will allow reduction in the clinical symptoms and burdens of cNF for people with NF1. The work presented here creates a framework for prospective validation studies to more accurately define cNF. Ultimately, this will facilitate accurate diagnosis of these lesions and the efficient development of therapeutics.

## Author contributions

N. Ortonne: drafting the manuscript, development of recommendations. P. Wolkenstein: drafting the manuscript, development of recommendations. J. Blakeley: drafting the manuscript, development of recommendations. B. Korf: review of manuscript, development of recommendations. S. Plotkin: review of manuscript, development of recommendations. V.M. Riccardi: drafting and review of manuscript, development of recommendations. D.C. Miller: review of manuscript, development of recommendations. S. Huson: review of manuscript, development of recommendations. J. Peltonen: review of manuscript, development of recommendations. A. Rosenberg: review of manuscript, development of recommendations. S. Carroll: review of manuscript, development of recommendations. S. Verma: drafting and review of manuscript, development of recommendations. V. Mautner: review of manuscript, development of recommendations. M. Upadhyaya: review of manuscript, development of recommendations. A. Stemmer-Rachamimov: drafting and review of manuscript, development of recommendations.

## Study funding

This publication was supported by an agreement from The Johns Hopkins University School of Medicine and the Neurofibromatosis Therapeutic Acceleration Program (NTAP). Its contents are solely the responsibilities of the authors and do not necessarily represent the official views of The Johns Hopkins University School of Medicine.

## Disclosure

N. Ortonne reports no disclosures relevant to the manuscript. P. Wolkenstein receives fees from Pierre Fabre Dermatologie. J. Blakeley reports no disclosures relevant to the manuscript. B. Korf reports consulting fees from Novartis. S. Plotkin reports ownership in NFlection and consulting fees from Novartis. V. Riccardi, D. Miller, S. Huson, J. Peltonen, A. Rosenberg, S. Carroll, S. Verma, V. Mautner, M. Upadhyaya, and A. Stemmer-Rachamimov report no disclosures relevant to the manuscript. Go to [Neurology.org/N](http://Neurology.org/N) for full disclosures.



## References

- Duong TA, Bastuji-Garin S, Valeyrie-Allanore L, Sbidian E, Ferkal S, Wolkenstein P. Evolving pattern with age of cutaneous signs in neurofibromatosis type 1: a cross-sectional study of 728 patients. *Dermatology* 2011;222:269–273.
- Jo VY, Fletcher CD. WHO classification of soft tissue tumours: an update based on the 2013 (4th) edition. *Pathology* 2014;46:95–104.
- Jouhilahti EM, Peltonen S, Callens T, et al. The development of cutaneous neurofibromas. *Am J Pathol* 2011;178:500–505.
- Bicudo NP, de Menezes Neto BF, da Silva de Avo LR, Germano CM, Melo DG. Quality of life in adults with neurofibromatosis 1 in Brazil. *J Genet Couns* 2016;25:1063–1074.
- Ferner RE, Thomas M, Mercer G, et al. Evaluation of quality of life in adults with neurofibromatosis 1 (NF1) using the impact of NF1 on quality of life (INF1-QOL) questionnaire. *Health Qual Life Outcomes* 2017;15:34.
- Graf A, Landolt MA, Mori AC, Boltshauser E. Quality of life and psychological adjustment in children and adolescents with neurofibromatosis type 1. *J Pediatr* 2006;149:348–353.
- Granstrom S, Langenbruch A, Augustin M, Mautner VF. Psychological burden in adult neurofibromatosis type 1 patients: impact of disease visibility on body image. *Dermatology* 2012;224:160–167.
- Kodra Y, Giustini S, Divona L, et al. Health-related quality of life in patients with neurofibromatosis type 1: a survey of 129 Italian patients. *Dermatology* 2009;218:215–220.
- Page PZ, Page GP, Ecosse E, Korf BR, Leplege A, Wolkenstein P. Impact of neurofibromatosis 1 on quality of life: a cross-sectional study of 176 American cases. *Am J Med Genet A* 2006;140:1893–1898.
- Vranceanu AM, Merker VL, Park E, Plotkin SR. Quality of life among adult patients with neurofibromatosis 1, neurofibromatosis 2 and schwannomatosis: a systematic review of the literature. *J Neurooncol* 2013;114:257–262.
- Wolkenstein P, Zeller J, Revuz J, Ecosse E, Leplege A. Quality-of-life impairment in neurofibromatosis type 1: a cross-sectional study of 128 cases. *Arch Dermatol* 2001;137:1421–1425.
- Wolkenstein P, Zeller J, Revuz J, Ecosse E, Leplege A. Visibility of neurofibromatosis 1 and psychiatric morbidity. *Arch Dermatol* 2003;139:103–104.
- Carroll SL, Ratner N. How does the Schwann cell lineage form tumors in NF1? *Glia* 2008;56:1590–1605.
- Rosenberg AE. WHO classification of soft tissue and bone, fourth edition: summary and commentary. *Curr Opin Oncol* 2013;25:571–573.
- Huson SM. Neurofibromatosis 1: a clinical and genetic overview. In: Huson SM, Hughes RAC, editors. *The Neurofibromatoses: A Pathogenic and Clinical Overview*. London: Chapman & Hall Medical; 1994:167–168.
- Friedman JM, Riccardi VM. An overview of NF-1: dysplasia and neoplasia. In: Gutmann DH, MacCollin M, Riccardi VM, editors. *Neurofibromatosis: Phenotype, Natural History, and Pathogenesis*. Baltimore: John Hopkins University Press; 1999.
- Beert E, Brems H, Daniels B, et al. Atypical neurofibromas in neurofibromatosis type 1 are premalignant tumors. *Genes Chromosomes Cancer* 2011;50:1021–1032.
- Leppig KA, Kaplan P, Viskochil D, Weaver M, Ortenberg J, Stephens K. Familial neurofibromatosis 1 microdeletions: cosegregation with distinct facial phenotype and early onset of cutaneous neurofibromata. *Am J Med Genet* 1997;73:197–204.
- Pinna V, Lanari V, Daniele P, et al. p.Arg1809Cys substitution in neurofibromin is associated with a distinctive NF1 phenotype without neurofibromas. *Eur J Med Genet* 2015;23:1068–1071.
- Quintans B, Pardo J, Campos B, et al. Neurofibromatosis without neurofibromas: confirmation of a genotype-phenotype correlation and implications for genetic testing. *Case Rep Neurol* 2011;3:86–90.
- Santoro C, Maietta A, Giugliano T, et al. Arg(1809) substitution in neurofibromin: further evidence of a genotype-phenotype correlation in neurofibromatosis type 1. *Eur J Hum Genet* 2015;23:1460–1461.
- Upadhyaya M, Huson SM, Davies M, et al. An absence of cutaneous neurofibromas associated with a 3-bp inframe deletion in exon 17 of the NF1 gene (c.2970-2972 delAAT): evidence of a clinically significant NF1 genotype-phenotype correlation. *Am J Hum Genet* 2007;80:140–151.
- Brosseau JP, Pichard DC, Legius EH. The biology of cutaneous neurofibromas: consensus recommendations for setting research priorities. *Neurology* 2018;91:S14–S20.
- Sbidian E, Duong TA, Valeyrie-Allanore L, Wolkenstein P. Neurofibromatosis type 1: neurofibromas and sex. *Br J Dermatol* 2016;174:402–404.
- Dugoff L, Sujansky E. Neurofibromatosis type 1 and pregnancy. *Am J Med Genet* 1996;66:7–10.
- Roth TM, Petty EM, Barald KF. The role of steroid hormones in the NF1 phenotype: focus on pregnancy. *Am J Med Genet A* 2008;146A:1624–1633.
- Lammert M, Friedman JM, Roth HJ, et al. Vitamin D deficiency associated with number of neurofibromas in neurofibromatosis 1. *J Med Genet* 2006;43:810–813.
- Riccardi VM. An overview of NF-1: dysplasia and neoplasia. In: Riccardi VM. *Neurofibromatosis: Phenotype, Natural History, and Pathogenesis*. Baltimore: The Johns Hopkins University Press; 1992:28–33.
- Cannon A, Jarnagin K, Korf B. Clinical trial design for cutaneous neurofibromas. *Neurology* 2018;91:S31–S37.
- Brenaut E, Nizery-Guermeur C, Audebert-Bellanger S, et al. Clinical characteristics of pruritus in neurofibromatosis 1. *Acta Derm Venereol* 2016;96:398–399.
- Riccardi VM. Pathophysiology of neurofibromatosis: IV: dermatologic insights into heterogeneity and pathogenesis. *J Am Acad Dermatol* 1980;3:157–166.
- Riccardi VM. Cutaneous manifestation of neurofibromatosis: cellular interaction, pigmentation, and mast cells. *Birth Defects Orig Artic Ser* 1981;17:129–145.
- Kamide R, Nomura N, Niimura M. Characterization of mast cells residing in cutaneous neurofibromas. *Dermatologica* 1989;179(suppl 1):124.
- Carr NJ, Warren AY. Mast cell numbers in melanocytic naevi and cutaneous neurofibromas. *J Clin Pathol* 1993;46:86–87.
- Staser K, Yang FC, Clapp DW. Mast cells and the neurofibroma microenvironment. *Blood* 2010;116:157–164.
- Korf BR, Rubenstein AE. Neurofibromatosis: a handbook for patients, families, and health care professionals. *Am J Hum Genet* 2005;77:681.
- Brenaut E, Marcorelles P, Genestet S, Menard D, Misery L. Pruritus: an underrecognized symptom of small-fiber neuropathies. *J Am Acad Dermatol* 2015;72:328–332.
- Krab LC, Oostenbrink R, de Goede-Bolder A, Aarsen FK, Elgersma Y, Moll HA. Health-related quality of life in children with neurofibromatosis type 1: contribution of demographic factors, disease-related factors, and behavior. *J Pediatr* 2009;154:420–425.e1.
- Le LQ, Shipman T, Burns DK, Parada LF. Cell of origin and microenvironment contribution for NF1-associated dermal neurofibromas. *Cell Stem Cell* 2009;4:453–463.
- Val-Bernal JF, Gonzalez-Vela MC. Cutaneous lipomatous neurofibroma: characterization and frequency. *J Cutan Pathol* 2005;32:274–279.
- Brasfield RD, Das Gupta TK. Von Recklinghausen's disease: a clinicopathological study. *Ann Surg* 1972;175:86–104.
- Khalifa MA, Montgomery EA, Ismail N, Azumi N. What are the CD34+ cells in benign peripheral nerve sheath tumors? Double immunostaining study of CD34 and S-100 protein. *Am J Clin Pathol* 2000;114:123–126.
- Fetsch JF, Michal M, Miettinen M. Pigmented (melanotic) neurofibroma: a clinicopathologic and immunohistochemical analysis of 19 lesions from 17 patients. *Am J Surg Pathol* 2000;24:331–343.
- Goldblum JR, Folpe AL, Weiss SW, Enzinger FM, Weiss SW. *Enzinger and Weiss's Soft Tissue Tumors*. Philadelphia: Saunders; 2013.
- Chen Z, Liu C, Patel AJ, Liao CP, Wang Y, Le LQ. Cells of origin in the embryonic nerve roots for NF1-associated plexiform neurofibroma. *Cancer Cell* 2014;26:695–706.
- Verma S, Riccardi VM, Plotkin SR. Considerations for development of therapies for cutaneous neurofibroma. *Neurology* 2018;91:S21–S30.

# Neurology<sup>®</sup>

## Cutaneous neurofibromas: Current clinical and pathologic issues

Nicolas Ortonne, Pierre Wolkenstein, Jaishri O. Blakeley, et al.

*Neurology* 2018;91;S5-S13

DOI 10.1212/WNL.0000000000005792

**This information is current as of July 9, 2018**

<b>Updated Information &amp; Services</b>	including high resolution figures, can be found at: <a href="http://n.neurology.org/content/91/2_Supplement_1/S5.full">http://n.neurology.org/content/91/2_Supplement_1/S5.full</a>
<b>References</b>	This article cites 42 articles, 3 of which you can access for free at: <a href="http://n.neurology.org/content/91/2_Supplement_1/S5.full#ref-list-1">http://n.neurology.org/content/91/2_Supplement_1/S5.full#ref-list-1</a>
<b>Subspecialty Collections</b>	This article, along with others on similar topics, appears in the following collection(s): <b>Nerve tumor</b> <a href="http://n.neurology.org/cgi/collection/nerve_tumor">http://n.neurology.org/cgi/collection/nerve_tumor</a> <b>Neurofibromatosis</b> <a href="http://n.neurology.org/cgi/collection/neurofibromatosis">http://n.neurology.org/cgi/collection/neurofibromatosis</a>
<b>Permissions &amp; Licensing</b>	Information about reproducing this article in parts (figures, tables) or in its entirety can be found online at: <a href="http://www.neurology.org/about/about_the_journal#permissions">http://www.neurology.org/about/about_the_journal#permissions</a>
<b>Reprints</b>	Information about ordering reprints can be found online: <a href="http://n.neurology.org/subscribers/advertise">http://n.neurology.org/subscribers/advertise</a>

*Neurology*® is the official journal of the American Academy of Neurology. Published continuously since 1951, it is now a weekly with 48 issues per year. Copyright © 2018 The Author(s). Published by Wolters Kluwer Health, Inc. on behalf of the American Academy of Neurology. All rights reserved. Print ISSN: 0028-3878. Online ISSN: 1526-632X.

