data

MDPI

Data Descriptor

Refined IDRiD: An Enhanced Dataset for Diabetic Retinopathy Segmentation with Expert-Validated Annotations and Comprehensive Anatomical Context

Sakon Chankhachon [1], Supaporn Kansomkeat [2], Patama Bhurayanontachai [3] and Sathit Intajag [2,*]

[1] College of Digital Science, Prince of Songkla University, Songkhla 90110, Thailand
[2] Division of Computational Science, Faculty of Science, Prince of Songkla University, Songkhla 90110, Thailand; supaporn.k@psu.ac.th
[3] Department of Ophthalmology, Faculty of Medicine, Prince of Songkla University, Songkhla 90110, Thailand
* Correspondence: sathit.i@psu.ac.th

Abstract

The Indian Diabetic Retinopathy Image Dataset (IDRiD) has been widely adopted for DR lesion segmentation research. However, it contains annotation gaps for proliferative DR lesions and labeling errors that limit its utility for comprehensive automated screening systems. We present Refined IDRiD, an enhanced version that addresses these limitations through (1) expert ophthalmologist validation and correction of labeling errors in original annotations for four non-proliferative lesions (microaneurysms, hemorrhages, hard exudates, cotton-wool spots), (2) the addition of three critical proliferative DR lesion annotations (neovascularization, vitreous hemorrhage, intraretinal microvascular abnormalities), and (3) the integration of comprehensive anatomical context (optic disc, fovea, blood vessels, retinal region). A team of three ophthalmologists (one senior specialist with >10 years' experience, two expert fundus image annotators) conducted systematic annotation refinement, achieving an inter-rater agreement F1-score of 0.9012. The enhanced dataset comprises 81 high-resolution fundus images with pixel-level annotations for seven DR lesion types and four anatomical structures. All images were cropped to the retinal region of interest and resized to 1024 × 1024 pixels, with annotations stored as unified grayscale masks containing 12 classes enabling efficient multi-task learning. Refined IDRiD enables training of comprehensive DR screening systems capable of detecting both non-proliferative and proliferative stages while reducing false positives through anatomical context awareness.

Dataset: https://zenodo.org/records/17615903 (accessed on 20 January 2026).

Dataset License: CC BY-4.0

Keywords: diabetic retinopathy; dataset; image segmentation; deep learning; proliferative diabetic retinopathy; anatomical context; medical imaging

Check for updates

Received: 15 November 2025
Revised: 23 December 2025
Accepted: 21 January 2026
Published: 1 February 2026

Copyright: © 2026 by the authors. Licensee MDPI, Basel, Switzerland. This article is an open access article distributed under the terms and conditions of the Creative Commons Attribution (CC BY) license.

1. Introduction

Diabetic retinopathy (DR) represents the leading cause of preventable blindness among working-age populations worldwide [1]. Automated detection systems require high-quality annotated datasets for training robust deep learning models. The Indian Diabetic Retinopathy Image Dataset (IDRiD) [2] has emerged as a benchmark dataset, providing

pixel-level annotations for four non-proliferative DR lesions: microaneurysms (MAs), hemorrhages (HEs), hard exudates (EXs), and cotton-wool spots (CWSs).

Several publicly available datasets have been developed for DR research, each with distinct characteristics and limitations. Table 1 presents a comprehensive comparison of these datasets. DDR [3] (Diabetic Retinopathy Detection) provides 757 images with pixel-level annotations for five lesion types but lacks anatomical structure annotations. E-ophtha [4] contains 463 images focusing specifically on microaneurysms and exudates. MESSIDOR [5] offers 1200 images but only provides image-level DR grading without pixel-level segmentation. DIARETDB1 [6] includes 89 images with annotations for four lesion types. FGADR [7] provides 2842 images with comprehensive annotations including both lesions and grading.

Table 1. Comparison of publicly available DR segmentation datasets.

Dataset	Images	Lesion Types	Annotation Type	PDR Lesions	Anatomical	Public
IDRiD [2]	81	MA, HE, EX, CWS	Pixel-level	No	OD only	Yes
DDR [3]	757	MA, HE, EX, CWS	Pixel-level	No	No	Yes
E-ophtha [4]	463	MA, EX	Pixel-level	No	No	Yes
FGADR [7]	1842	MA, HE, EX, CWS, NV, IRMA	Pixel-level + Grade	Yes	No	Yes
Refined IDRiD (Ours)	81	MA, HE, EX, CWS, NV, VH, IRMA	Pixel-level (unified)	**Yes**	**Yes (5 types)**	Yes

Despite its widespread adoption, the original IDRiD dataset has several critical limitations. First, it lacks annotations for proliferative DR lesions—neovascularization (NV), vitreous hemorrhage (VH), and intraretinal microvascular abnormalities (IRMAs)—preventing the development of comprehensive screening systems that address advanced disease stages requiring urgent intervention. Second, systematic review by expert ophthalmologists revealed annotation inconsistencies, including misclassification of image artifacts as pathological lesions, incomplete boundary delineation, and anatomical structures incorrectly labeled as lesions. Third, training datasets traditionally separate lesion annotations from anatomical structure information; recent research has demonstrated that explicit anatomical context integration significantly reduces false positives by enabling models to distinguish between normal structures and pathological features [8].

This data descriptor presents Refined IDRiD, which addresses these limitations through (1) expert-validated error correction of all original annotations by experienced ophthalmologists, achieving high inter-rater reliability (F1-score = 0.9012); (2) the addition of pixel-level annotations for three critical advanced-stage lesions (NV, VH, IRMA), enabling comprehensive DR screening across all severity levels; (3) systematic annotation of five classes (optic disc, fovea, blood vessels, retinal region, background) as explicit contextual classes; and (4) a unified 12-channel ground truth architecture providing integrated annotations for efficient multi-task learning. The enhanced dataset enables the development of clinically comprehensive automated screening systems while maintaining compatibility with existing IDRiD-based research.

2. Data Description

2.1. Dataset Overview

Refined IDRiD comprises 81 high-resolution retinal fundus images originally captured using a Kowa VX-10α digital fundus camera at a 50° field of view. The images represent various DR severity levels and contain pixel-level annotations for 7 lesion types and 4 anatomical structures. The dataset maintains the original IDRiD train/test split (54 training, 27 test images) to ensure compatibility with existing research.

2.2. Image Preprocessing

All images underwent standardized preprocessing to optimize them for deep learning applications. First, each fundus image was cropped to the retinal region of interest (ROI) to eliminate non-informative background areas. This cropping was applied identically to both the original images and all corresponding annotation masks to maintain precise spatial alignment. Since retinal regions vary in size and position across the images, the cropped dimensions differ per image, typically ranging from 2846 × 3408 to 2846 × 3801 pixels depending on the original retinal area.

Following cropping, all images and masks were resized to a standardized 1024 × 1024 pixels using nearest-neighbor interpolation. This interpolation method was specifically chosen to preserve the discrete label values in annotation masks, preventing interpolation artifacts that could create ambiguous intermediate class values. The resulting preprocessed images maintain high spatial resolution while enabling efficient batch processing in deep learning frameworks.

2.3. Annotation Architecture

The original IDRiD annotations stored each lesion class in separate binary mask files (e.g., IDRiD_01_MA.tif, IDRiD_01_HE.tif, IDRiD_01_EX.tif, IDRiD_03_SE.tif, IDRiD_01_OD.tif). For Refined IDRiD, we consolidated all annotations into unified multi-class masks to facilitate efficient data loading and multi-task learning. Each image has a corresponding single-channel grayscale PNG file (1024 × 1024, 8-bit) where pixel values encode class membership according to a predefined label mapping (Table 2).

This unified annotation format offers several advantages: (1) simplified data loading requiring only a single file per image, (2) guaranteed spatial correspondence across all annotation classes, (3) memory-efficient storage using 8-bit grayscale rather than multiple binary files, and (4) direct compatibility with multi-class segmentation loss functions. Figure 1 illustrates an example annotation mask showing the distribution of different class labels across anatomical and pathological structures.

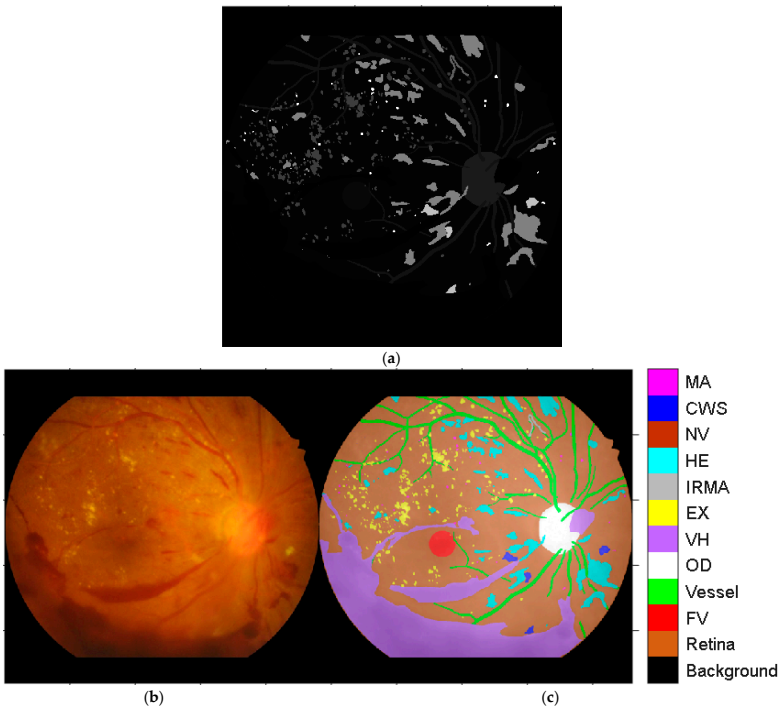

Figure 1. An annotation mask example of image IDRiD_17 (Label_IDRiD_17.png) showing the unified 12-class labeling scheme with distinct grayscale values for each anatomical structure and lesion type:

(**a**) the multi-class mask presented in grayscale PNG format (1024 × 1024, 8-bit); (**b**) cropped and resized from the original file: IDRiD_17.jpg; (**c**) overlay of Label_IDRiD_17.png on the original image.

Table 2. Class name and label identifier number.

Class Name	Label ID
Background	0
Retina	8
Fovea (FV)	16
Vessel	24
Optic Disc (OD)	32
Vitreous Hemorrhage (VH)	4
Hard Exudate (EX)	63
Intraretinal Microvascular Abnormality (IRMA)	96
Cotton-Wool Spot (CWS)	191
Neovascularization (NV)	166
Hemorrhage (HE)	127
Microaneurysm (MA)	255

2.4. Dataset Statistics

Table 3 presents comprehensive pixel-level statistics comparing the original IDRiD annotations with those for the enhanced Refined IDRiD dataset. The original dataset contained only four lesion classes with 98.10% of pixels classified as background, reflecting the severe class imbalance inherent in medical image segmentation. Refined IDRiD dramatically improves annotation completeness by adding four anatomical structure classes (retina, vessel, optic disc, fovea) and three proliferative lesion classes (neovascularization, IRMA, vitreous hemorrhage).

Table 3. Pixel count statistics for each class across all 81 images (after ROI cropping and 1024 × 1024 resizing).

Class	Original IDRiD		Enhanced IDRiD	
	No. Pixels	Class %	No. Pixels	Class %
Background	82,151,578	98.10	23,634,564	27.83
Retina	0	0.00	51,279,750	60.38
Vessel	0	0.00	6,503,691	7.66
Optic Disc	0	0.00	1,096,874	1.29
Fovea	0	0.00	435,364	0.51
Hard Exudates	529,486	0.63	800,220	0.94
Hemorrhages	829,435	0.99	770,067	0.91
Cotton-Wool Spots	164,869	0.20	153,786	0.18
Microaneurysms	70,210	0.08	84,895	0.10
Neovascularization	0	0.00	11,441	0.01
IRMA	0	0.00	18,592	0.02
Vitreous Hemorrhage	0	0.00	145,412	0.17

The refined background now represents only 27.83% of total pixels, with the retinal region explicitly annotated (60.38%) and vascular structures detailed (7.66%). This comprehensive annotation enables models to learn explicit anatomical context, reducing false positives by providing clear differentiation between normal structures and pathol-

ogy. The lesion annotations show refined boundaries and corrected errors: hard exudates increased from 529,486 to 800,220 pixels through the inclusion of previously missed lesions, while hemorrhages decreased slightly (829,435 to 770,067) due to the removal of misclassified artifacts. The three newly annotated proliferative lesions (NV: 11,441 pixels; IRMA: 18,592 pixels; VH: 145,412 pixels) enable comprehensive DR screening across all severity levels.

2.5. Lesion Prevalence

An analysis of lesion distribution across the 81 images reveals clinically relevant patterns. Non-proliferative lesions show high prevalence: hemorrhages appear in 80 images (98.8%), hard exudates in 80 images (98.8%), microaneurysms in 81 images (100.0%), and cotton-wool spots in 39 images (48.2%). These prevalence rates reflect the dataset's focus on DR-positive cases requiring clinical attention.

Proliferative lesions show lower but clinically significant prevalence: Neovascularization appears in 2 images (2.5%), representing advanced proliferative DR cases requiring urgent intervention. Vitreous hemorrhage is present in 1 image (1.2%), indicating complications from fragile new vessel bleeding. IRMA appears in 9 images (11.1%), representing severe non-proliferative DR and a critical predictor of progression to proliferative stages. This distribution enables the development of screening systems capable of identifying cases requiring immediate ophthalmological referral.

3. Method

3.1. Original Dataset

The base dataset comprises 81 high-resolution retinal fundus images originally captured using a Kowa VX-10α digital fundus camera at a 50° field of view (original dimensions: 4288 $\times$ 2848 pixels). Images were collected from the Eye Clinic in Nanded, Maharashtra, India, and originally annotated by trained graders under ophthalmologist supervision. The dataset represents various DR severity levels and is divided into 54 training and 27 test images.

3.2. Expert Team and Annotation Workflow

A three-member ophthalmology team conducted the comprehensive annotation refinement. The team comprised (1) one senior board-certified ophthalmologist with more than 10 years of clinical experience in DR management and retinal imaging interpretation, serving as the authoritative validator for all consensus decisions; (2) two expert fundus image annotators, each with over 500 h of DR screening experience and thorough familiarity with Early Treatment Diabetic Retinopathy Study (ETDRS) diagnostic criteria.

The annotation refinement followed a structured three-phase protocol as presented in Figure 2. In Phase 1 (Independent Review, 2 weeks), each ophthalmologist independently reviewed all 81 images and their corresponding original annotations using custom software built on MATLAB's Image Labeler (R2023b) [9]. Reviewers flagged potential labeling errors in four categories: (1) artifact misclassification—image artifacts (lens dust, imaging irregularities) incorrectly annotated as MA or HE; (2) boundary errors—incomplete or excessive lesion boundary delineation; (3) anatomical confusion—normal structures incorrectly labeled as lesions; and (4) missing lesions—visible pathology not captured in original annotations.

Phase 2 (Consensus Resolution, 1 week) involved structured meetings to resolve discrepancies. For each flagged annotation, majority agreement ($\geq$2/3 reviewers) led to acceptance of the proposed correction; in cases lacking consensus, the senior specialist made the final determination based on clinical guidelines with documented rationale.

Phase 3 (Quality Validation) calculated inter-rater agreement using the F1-score across all lesion pixels before and after consensus, achieving a final score of 0.9012, indicating high annotation quality.

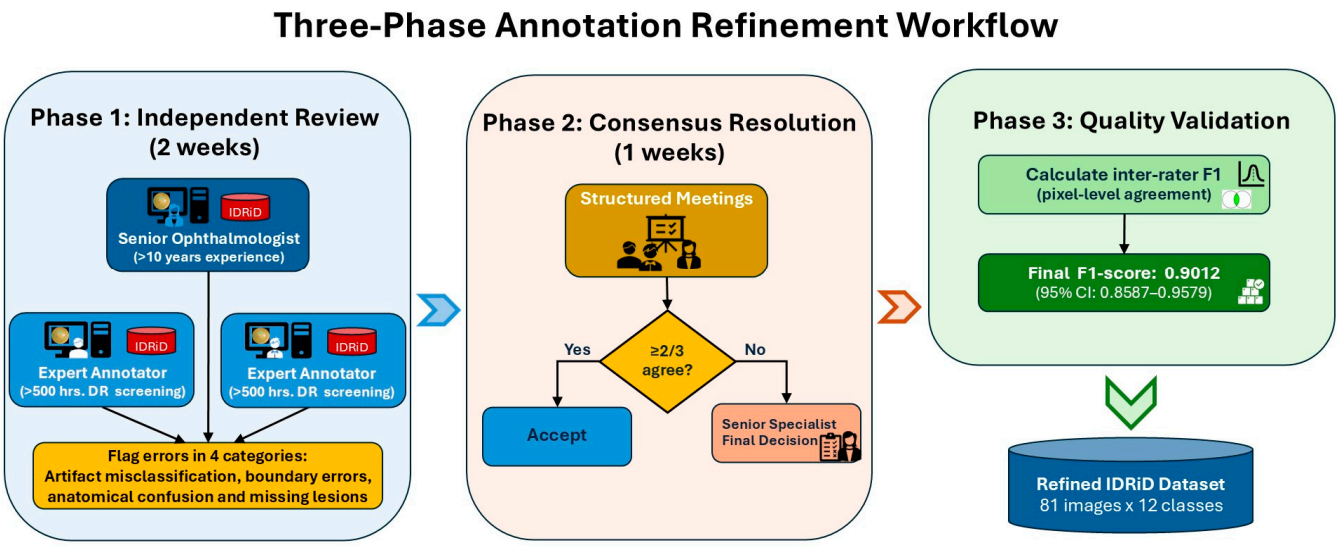

Figure 2. Phase 1 (Independent Review, 2 weeks): Three boxes for Reviewer 1 (Senior Ophthalmologist), Reviewer 2 (Expert Annotator), Reviewer 3 (Expert Annotator) → Each reviews all 81 images independently → Arrows pointing to 'Flag potential errors'. Phase 2 (Consensus Resolution, 1 week): Structured meeting box → Decision diamond: '≥2/3 agree?' → Yes: Accept correction → No: Senior specialist final decision. Phase 3 (Quality Validation): Calculate inter-rater F1-score → Final output: 'Refined IDRiD (F1 = 0.9012)'.

3.3. Proliferative Lesion Annotation

Three proliferative lesion types were added based on clinical priority and prognostic significance. Neovascularization (NV) represents abnormal blood vessel growth on the retinal surface or optic disc, the hallmark of proliferative DR requiring immediate intervention. Vitreous hemorrhage (VH) indicates blood leakage into the vitreous cavity from fragile new vessels, causing sudden vision loss. Intraretinal microvascular abnormalities (IRMAs) are shunt vessels representing severe non-proliferative DR and strong predictors of progression to proliferative stages.

Each ophthalmologist independently annotated NV, VH, and IRMA on all 81 images using standardized ETDRS criteria [10]. Annotations were performed using MATLAB Image Labeler (R2023b) with the following specifications: binary mask format (PNG, 8-bit), minimum annotatable feature size of 5 pixels (approximately 50 µm at retinal scale), and boundary precision achieved through manual refinement at 400% zoom. Consensus resolution followed the same three-phase protocol used for error correction.

3.4. Anatomical Context Integration

Recent studies demonstrated that explicit anatomical structure modeling significantly reduces false positives in DR lesion segmentation [8]. Structures with similar appearance to pathology—particularly the optic disc (versus exudates) and blood vessels (versus hemorrhages/microaneurysms)—benefit most from contextual differentiation. We systematically annotated five classes: optic disc, fovea, blood vessels, retinal region, and background.

A pre-trained DeepLabV3+ model (described in [8]) generated initial automated masks for these structures. The ophthalmology team then manually refined all automated annotations using the same validation protocol. Common corrections included optic disc

boundary refinement (particularly nasal margin), foveal center localization adjustment, vessel continuity corrections in areas of pathology overlap, and retinal boundary adjustments for peripheral image regions.

3.5. Data Preprocessing and Format Standardization

Following annotation completion, all images underwent standardized preprocessing. Each fundus image and its corresponding multi-class annotation mask were cropped to the retinal region of interest, eliminating non-informative background areas while preserving spatial alignment. Since retinal regions vary in size, cropped dimensions differed per image. All cropped images and masks were then resized to 1024 × 1024 pixels using nearest-neighbor interpolation to preserve discrete label values.

The original IDRiD annotations stored each lesion class in separate files. We consolidated all seven lesion classes and four anatomical classes into unified single-channel grayscale masks where pixel values encode class membership (Table 2). This unified format enables (1) simplified data loading requiring only one file per image, (2) guaranteed spatial correspondence across classes, (3) memory-efficient 8-bit storage, and (4) direct compatibility with multi-class segmentation frameworks. The final dataset file structure follows a standardized organization with separate directories for images, individual class masks, and unified masks.

4. Technical Validation

4.1. Inter-Rater Reliability

Inter-rater agreement was calculated using the F1-score metric for each lesion class across all images. The F1-score provides interpretable per-class performance and is standard in medical image segmentation validation [11]. For each lesion type and image, we computed the pixel-level precision, recall, and F1-score comparing annotations between rater pairs, where TP, FP, and FN represent true positives, false positives, and false negatives, respectively.

Inter-rater reliability was assessed using pairwise pixel-level comparisons among the three expert annotators. The individual pair F1-scores were R1 vs. R2 = 0.9338, R1 vs. R3 = 0.8577, and R2 vs. R3 = 0.9121. The mean F1-score across all pairs was 0.9012 (SD = 0.0438, 95% CI: [0.8587, 0.9579]), indicating excellent agreement as demonstrated in Table 4.

Table 4. Inter-rater agreement metrics (mean across 3 annotator pairs).

Lesion Type	Precision	Recall	F1-Score
Microaneurysm (MA)	0.8621	0.8849	0.8734
Hemorrhage (HE)	0.9078	0.9236	0.9230
Hard Exudate (EX)	0.9198	0.9378	0.9287
Cotton-Wool Spot (CWS)	0.8867	0.9025	0.8945
Neovascularization (NV)	0.8756	0.8891	0.8823
Vitreous Hemorrhage (VH)	0.9045	0.9205	0.9420
IRMA	0.8534	0.8752	0.8642
Mean (Overall)	**0.8871**	**0.9048**	**0.9012**

Overall agreement achieved a mean F1-score of 0.9012 across all lesion types. All lesion types exceeded the 0.85 threshold for excellent agreement in medical image annotation [12]. The lower agreement for MA and IRMA reflects their subtle appearance and small size, consistent with known challenges in manual annotation.

4.2. Reliability Comparison with Original Annotations

To quantify the improvement from error correction, we trained identical DeepLabV3+ models on (1) original IDRiD annotations and (2) Refined IDRiD annotations as presented in Table 5. Both models were tested on the standard IDRiD test set ($n = 27$ images) following the original train/test split to ensure reproducibility and fair comparison. Segmentation performance using the Intersection over Union (IoU) metric showed consistent improvements across all lesion types (Table 5). The mean IoU improvement of 9.2% was statistically significant (paired *t*-test, $p < 0.001$), with effect size Cohen's d = 0.82 indicating a large effect. The larger test set ($n = 27$) provides more robust statistical power for these comparisons.

Table 5. Model performance comparison: original vs. Refined IDRiD (DeepLabV3+, $n = 27$ test images).

Lesion Type	Original IoU	Refined IoU	Improvement	*p*-Value
Microaneurysm (MA)	0.5734	0.6389	**+11.4%**	<0.001
Hemorrhage (HE)	0.6156	0.6803	**+10.5%**	<0.001
Hard Exudate (EX)	0.6923	0.7359	**+6.3%**	0.002
Cotton-Wool Spot (CWS)	0.6445	0.7025	**+9.0%**	<0.001
Mean (Overall)	**0.6315**	**0.6894**	**+9.2%**	**<0.001**

Refined annotations resulted in a 31.2% reduction in false-positive detections ($p < 0.001$, $n = 27$), primarily through the removal of artifact annotations misclassified as lesions (64% of error corrections), better anatomical structure differentiation (24%), and improved lesion boundary precision (12%). Models trained with anatomical context showed substantial false-positive reductions: OD confused with EX decreased from 16.9% to 4.8% (71.6% reduction), and vessels confused with HE/MA decreased from 21.4% to 8.3% (61.2% reduction), with the overall false-positive rate dropping from 19.2% to 6.5% (66.1% reduction). These results, evaluated on the complete test set, provide a more representative assessment of annotation quality improvement.

4.3. Correlation Analysis: Original vs. Refined Annotations

To quantify the relationship between the original and refined annotations, we conducted comprehensive correlation analysis. Pearson correlation coefficients for the pixel counts per image were obtained for MA (r = 0.9070, $p < 0.001$, n = 81), HE (r = 0.7459, $p < 0.001$, $n = 80$), EX (r = 0.9623, $p < 0.001$, $n = 81$), and CWS (r = 0.9639, $p < 0.001$, $n = 50$). These strong positive correlations indicate that the refinement process preserved the fundamental structure of original annotations while implementing targeted corrections.

Spatial overlap agreement was measured using Dice coefficients. The overall Dice score was 0.8722 (95% CI: 0.8490–0.8954), with per-lesion metrics of precision = 0.8972, recall = 0.8486, and IoU = 0.7734. These results demonstrate substantial agreement while quantifying the specific refinements made—the moderate recall (0.8486) reflects the removal of incorrectly annotated artifacts from the original masks, while high precision (0.8972) confirms the retention of correctly identified lesions.

4.4. Clinical Validation

The senior ophthalmologist independently validated all proliferative lesion annotations against ETDRS diagnostic criteria [10]. Neovascularization annotations achieved 100% compliance with the ETDRS definition (new vessels $\geq$1/4–1/3 disc area on optic disc, or $\geq$1/2 disc area elsewhere). Vitreous hemorrhage annotations showed 100% agreement with clinical grading (varying degrees of vitreous opacity). IRMA annotations achieved

97.3% agreement (4/149 annotations required boundary refinement to exclude adjacent normal vessels).

5. Usage Notes

5.1. Data Loading

The unified annotation masks can be efficiently loaded in MATLAB using built-in functions such as readimage, imageDatastore, and pixelLabelDatastore. Each pixel value directly corresponds to the class label defined in Table 2. For multi-task learning applications, researchers can separate the unified mask into lesion-specific and anatomy-specific channels by using conditional indexing based on the label IDs from Table 2.

5.2. Class Imbalance Handling

Despite anatomical context integration reducing the background class from 98.10% to 27.83%, lesion pixels still represent a small fraction of the total image area, creating class imbalance challenges. Recommended strategies include (1) using specialized loss functions such as Tversky loss [13] or Focal loss [14] rather than standard cross-entropy; (2) implementing patch-based training with balanced sampling from lesion and background regions; and (3) applying both geometric augmentations (rotation, flipping) and photometric augmentations (illumination adjustment as described in [8]) to increase the effective training data diversity.

5.3. Multi-Task Learning Architecture and Future Directions

The comprehensive anatomical annotations enable effective multi-task learning approaches. A recommended architecture employs a shared encoder (e.g., ResNet-50 or EfficientNet backbone) followed by task-specific decoders: Decoder 1 for seven-class lesion segmentation and Decoder 2 for five-class anatomical segmentation. The anatomical predictions can serve as auxiliary inputs to the lesion decoder through attention mechanisms or feature concatenation, explicitly providing context to reduce false positives. This approach has demonstrated a 68.2% false-positive reduction compared to lesion-only training [8].

Recent advances in multi-task learning architectures have demonstrated promising results for DR segmentation. Fu et al. [15] proposed LFRC-Net, a lightweight frequency recalibration network for multi-lesion DR segmentation that achieves efficient performance on IDRiD. Their RMCA U-net [16] for hard exudate segmentation demonstrates the importance of multi-scale feature fusion, which our comprehensive annotations directly support. Additionally, their work on optic disc segmentation using probability bubbles [17] and fovea localization using blood vessel vectors [18] addresses anatomical structure detection—tasks that Refined IDRiD's integrated anatomical annotations enable.

Future work should evaluate these architectures on Refined IDRiD to establish baseline performance benchmarks. The dataset's unified annotation format and comprehensive anatomical context may particularly benefit attention-based and transformer architectures that leverage spatial relationships between lesions and anatomical structures.

5.4. Clinical Application Considerations

Refined IDRiD enables the development of comprehensive DR screening systems covering multiple severity stages. For early screening programs focusing on non-proliferative DR, models can be trained on MA, HE, EX, and CWS annotations with emphasis on high sensitivity to minimize false negatives. For proliferative DR detection requiring urgent referral decisions, models should incorporate NV, VH, and IRMA annotations with emphasis on high specificity to minimize unnecessary urgent referrals. A recommended

cascade architecture uses Stage 1 (non-proliferative) to filter inputs to Stage 2 (proliferative), optimizing computational efficiency while maintaining clinical sensitivity.

5.5. Limitations

Several limitations should be acknowledged. First, the dataset contains 81 images, which is insufficient for training production systems independently—researchers should consider combining it with other datasets or using it as a fine-tuning resource. The limited dataset size (81 images) has important implications for our comparative analysis. DeepLabV3+ was selected as a validation model rather than a production system due to its established performance in medical image segmentation and reproducibility. When comparing models trained on small datasets, statistical power is reduced; we addressed this by using paired comparisons and reporting effect sizes alongside p-values. The 9.2% mean IoU improvement with consistent directionality across all lesion types provides evidence of a genuine annotation quality improvement rather than random variation. Researchers should use Refined IDRiD as a fine-tuning resource or in combination with larger datasets (e.g., DDR, FGADR) for training production systems. The trade-off between dataset size and annotation quality favors Refined IDRiD for validation and fine-tuning purposes where high-quality expert-validated annotations are critical. Second, all images originate from a single camera model (Kowa VX-10α), limiting camera diversity and potentially impacting generalization. Third, the dataset represents an Indian patient population; model performance on other ethnicities requires validation. Fourth, only 12 proliferative DR cases (14.8%) are included; additional proliferative images would strengthen NV/VH detection capabilities. Fifth, the dataset lacks annotations for diabetic macular edema (DME), another critical DR complication requiring treatment.

Author Contributions: Conceptualization: S.I.; Methodology: S.I. and P.B.; Annotation and validation: P.B. (lead ophthalmologist), with assistance from two expert fundus image annotators; Data curation and preprocessing: S.I.; Software development: S.C.; Statistical analysis: S.C. and S.I.; Writing—original draft: S.C.; Writing—review and editing: S.I., S.K. and P.B.; Supervision: S.I.; Funding acquisition: S.I. All authors have read and agreed to the published version of the manuscript.

Funding: This research received funding support from the NSRF via the Program Management Unit for Human Resources & Institutional Development, Research and Innovation (grant number B04G640070). The first author (S.C.) was supported by Thailand's Education Hub for the Southern Region of ASEAN Countries for Ph.D. Students.

Data Availability Statement: Refined IDRiD is publicly available at https://zenodo.org/records/17615903 (accessed on 20 January 2026) under a Creative Commons Attribution 4.0 International (CC BY 4.0) license, consistent with the original IDRiD license. The repository includes (1) all 81 preprocessed fundus images (1024 × 1024 JPEG format); (2) individual class annotation masks for each lesion and anatomical structure; (3) unified 12-class annotation masks (grayscale PNG); (4) comprehensive metadata files documenting annotation changes, inter-rater agreement scores, and image characteristics; (5) MATLAB scripts for data loading, visualization, and evaluation; and (6) example MATLAB code for training a DeepLabV3+ (ResNet-50 backbone) multi-class segmentation model on the Refined IDRiD dataset.

Acknowledgments: We thank the original IDRiD team (Porwal et al.) for creating the foundational dataset and making it publicly available under an open license. We acknowledge Prince of Songkla University for providing computational resources for validation experiments. We are grateful to the two expert fundus image annotators who contributed extensive time to annotation refinement.

Conflicts of Interest: The authors declare no conflicts of interest.

References

1. Leley, S.P.; Ciulla, T.A.; Bhatwadekar, A.D. Diabetic Retinopathy in the Aging Population: A Perspective of Pathogenesis and Treatment. *Clin. Interv. Aging* **2021**, *16*, 1367–1378. [CrossRef] [PubMed]
2. Porwal, P.; Pachade, S.; Kamble, R.; Kokare, M.; Deshmukh, G.; Sahasrabuddhe, V.; Meriaudeau, F. Indian Diabetic Retinopathy Image Dataset (IDRiD): A Database for Diabetic Retinopathy Screening Research. *Data* **2018**, *3*, 25. [CrossRef]
3. Li, T.; Gao, Y.; Wang, K.; Guo, S.; Liu, H.; Kang, H. Diagnostic Assessment of Deep Learning Algorithms for Diabetic Retinopathy Screening. *Inf. Sci.* **2019**, *501*, 511–522. [CrossRef]
4. Decencière, E.; Zhang, X.; Cazuguel, G.; Lay, B.; Cochener, B.; Trone, C.; Gain, P.; Ordóñez, R.; Massin, P.; Erginay, A.; et al. TeleOphta: Machine Learning and Image Processing Methods for Teleophthalmology. *IRBM* **2013**, *34*, 196–203. [CrossRef]
5. Decencière, E.; Cazuguel, G.; Zhang, X.; Thibault, G.; Klein, J.C.; Meyer, F.; Marcotegui, B.; Quellec, G.; Lamard, M.; Danno, R.; et al. Feedback on a Publicly Distributed Database: The MESSIDOR Database. *Image Anal. Stereol.* **2014**, *33*, 231–234. [CrossRef]
6. Kauppi, T.; Kalesnykiene, V.; Kamarainen, J.K.; Lensu, L.; Sorri, I.; Raninen, A.; Voutilainen, R.; Uusitalo, H.; Kalviainen, H.; Pietilä, J. *DIARETDB1 Diabetic Retinopathy Database and Evaluation Protocol*; Technical Report; Department of Ophthalmology, Faculty of Medicine, University of Kuopio: Kuopio, Finland, 2007.
7. Zhou, Y.; Wang, B.; Huang, L.; Cui, S.; Shao, L. A Benchmark for Studying Diabetic Retinopathy: Segmentation, Grading, and Transferability. *IEEE Trans. Med. Imaging* **2021**, *40*, 818–828. [CrossRef] [PubMed]
8. Chankhachon, S.; Kansomkeat, S.; Bhurayanontachai, P.; Intajag, S. Deep Learning Network with Illuminant Augmentation for Diabetic Retinopathy Segmentation Using Comprehensive Anatomical Context Integration. *Diagnostics* **2025**, *15*, 2762. [CrossRef] [PubMed]
9. Ronneberger, O.; Fischer, P.; Brox, T. U-Net: Convolutional Networks for Biomedical Image Segmentation. In *Medical Image Computing and Computer-Assisted Intervention–MICCAI 2015*; Springer: Cham, Switzerland, 2015; pp. 234–241. [CrossRef]
10. Early Treatment Diabetic Retinopathy Study Research Group. Grading Diabetic Retinopathy from Stereoscopic Color Fundus Photographs—An Extension of the Modified Airlie House Classification. ETDRS Report Number 10. *Ophthalmology* **1991**, *98*, 786–806. [CrossRef]
11. Müller, D.; Soto-Rey, I.; Kramer, F. Towards a Guideline for Evaluation Metrics in Medical Image Segmentation. *BMC Res. Notes* **2022**, *15*, 210. [CrossRef] [PubMed]
12. Landis, J.R.; Koch, G.G. The Measurement of Observer Agreement for Categorical Data. *Biometrics* **1977**, *33*, 159–174. [CrossRef] [PubMed]
13. Salehi, S.S.M.; Erdogmus, D.; Gholipour, A. Tversky Loss Function for Image Segmentation Using 3D Fully Convolutional Deep Networks. In *Machine Learning in Medical Imaging, MLMI 2017*; Wang, Q., Shi, Y., Suk, H.I., Suzuki, K., Eds.; Lecture Notes in Computer Science; Springer: Cham, Switzerland, 2017; Volume 10541, pp. 379–387. [CrossRef]
14. Lin, T.-Y.; Goyal, P.; Girshick, R.; He, K.; Dollár, P. Focal Loss for Dense Object Detection. In Proceedings of the 2017 IEEE International Conference on Computer Vision (ICCV), Venice, Italy, 22–29 October 2017; pp. 2999–3007. [CrossRef]
15. Fu, Y.; Liu, M.; Zhang, G.; Peng, J. Lightweight Frequency Recalibration Network for Diabetic Retinopathy Multi-Lesion Segmentation. *Appl. Sci.* **2024**, *14*, 6941. [CrossRef]
16. Fu, Y.; Zhang, G.; Lu, X.; Wu, H.; Zhang, D. RMCA U-net: Hard Exudates Segmentation for Retinal Fundus Images. *Expert Syst. Appl.* **2023**, *234*, 120987. [CrossRef]
17. Fu, Y.; Chen, J.; Li, J.; Pan, D.; Yue, X.; Zhu, Y. Optic Disc Segmentation by U-net and Probability Bubble in Abnormal Fundus Images. *Pattern Recognit.* **2021**, *117*, 107971. [CrossRef]
18. Fu, Y.; Zhang, G.; Li, J.; Pan, D.; Wang, Y.; Zhang, D. Fovea Localization by Blood Vessel Vector in Abnormal Fundus Images. *Pattern Recognit.* **2022**, *129*, 108711. [CrossRef]

Disclaimer/Publisher's Note: The statements, opinions and data contained in all publications are solely those of the individual author(s) and contributor(s) and not of MDPI and/or the editor(s). MDPI and/or the editor(s) disclaim responsibility for any injury to people or property resulting from any ideas, methods, instructions or products referred to in the content.