VQA Sample Collection

Generated: 2026-02-10 22:45:50
Total Samples: 20

Sample #67: 260210SDE0083

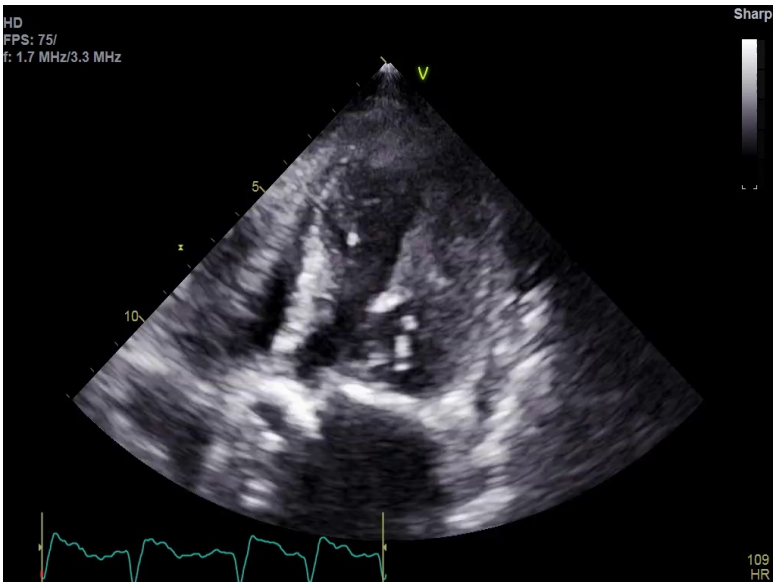

Question: Which of the following conditions is present?

Options:

(A) Left Ventricular Hypertrophy

(B) Mitral Regurgitation

(C) Tricuspid Regurgitation

(D) Aortic Regurgitation

Correct Answer: (A)

Target:	Aortic Stenosis	Type:	Diagnosis
Content:	Diagnosis		

Sample #46: 260210SDE0058

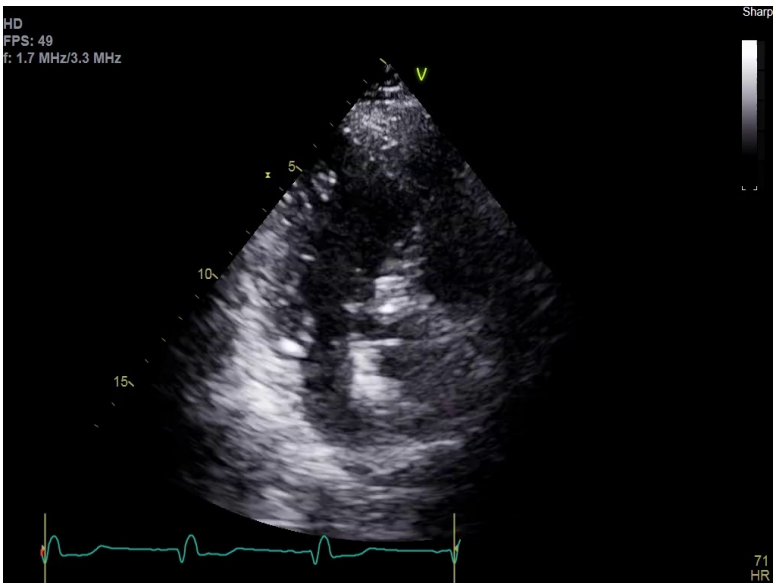

Question: Is a MitraClip device visible?

Options:

(A) No

(B) Yes

Correct Answer: (A)

Target:	MitraClip	Type:	Binary
Content:	Diagnosis		

Sample #10: 260210SDE0010

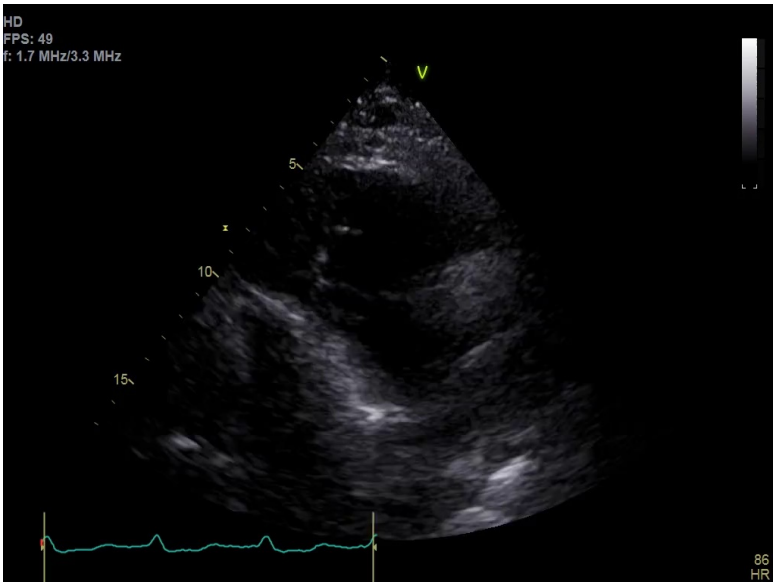

Question: Which of the following conditions is present?

Options:

(A) Tricuspid Stenosis

(B) Pulmonary Hypertension

(C) Right Ventricular Hypertrophy

(D) Pacemaker/ICD Lead

Correct Answer: (D)

Target:	Pacemaker	Type:	Diagnosis
Content:	Diagnosis		

Sample #74: 260210SDE0093

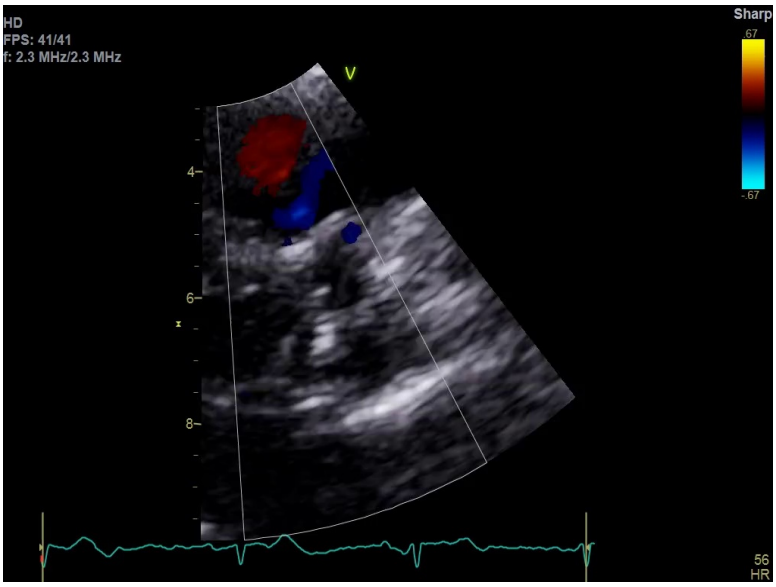

Question: Is there aortic regurgitation?

Options:

(A) No

(B) Yes

Correct Answer: (B)

Target:	Aortic Valve Aortic Regurgitation Jet Type	Type:	Binary
Content:	Diagnosis		

Sample #138: 260210SDE0171

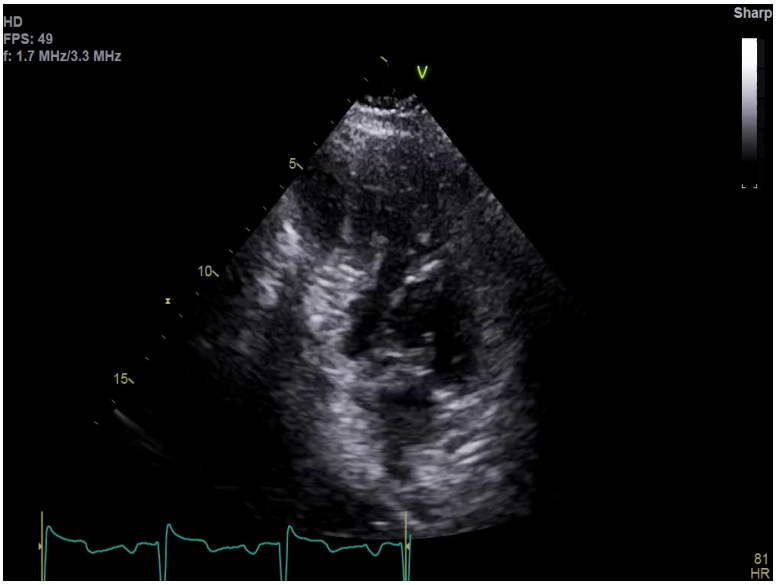

Question: Which of the following statements BEST describes the overall left ventricular systolic function?

Options:

(A) The left ventricular ejection fraction is mildly reduced with regional wall motion abnormalities.

(B) The left ventricular ejection fraction is severely reduced with global hypokinesis. (LVEF 20%)

(C) The left ventricular ejection fraction is normal with no evidence of regional wall motion abnormalities.

(D) The left ventricular ejection fraction is supranormal, with significant left ventricular hypertrophy (HCM / Fabry suspected).

Correct Answer: (A)

Target:	Left Ventricular Ejection Fraction	Type:	Descriptive
Content:	Diagnosis		

Sample #105: 260210SDE0131

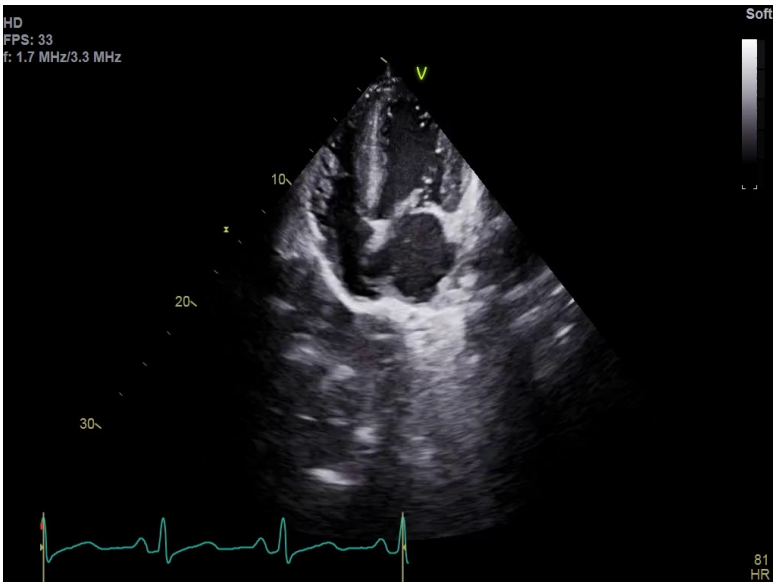

Question: Which of the following conditions is present?

Options:

(A) Left Atrium Dilation and possible LVH

(B) Moderate-Severe Aortic Stenosis

(C) Tricuspid Stenosis

(D) Impella and Pacemaker were seen.

Correct Answer: (A)

Target:	Left Atrial Size	Type:	Diagnosis
Content:	Diagnosis		

Sample #207: 260210SDE0251

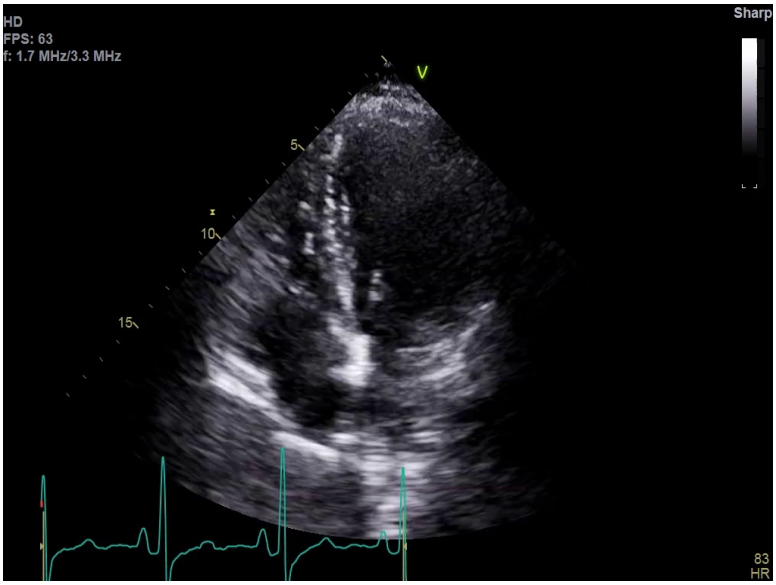

Question: Is there evidence of moderate-severe Pericardial Effusion?

Options:

(A) No

(B) Yes

Correct Answer: (A)

Target:	Pericardial Effusion	Type:	Binary
Content:	Diagnosis		

Sample #230: 260210SDE0277

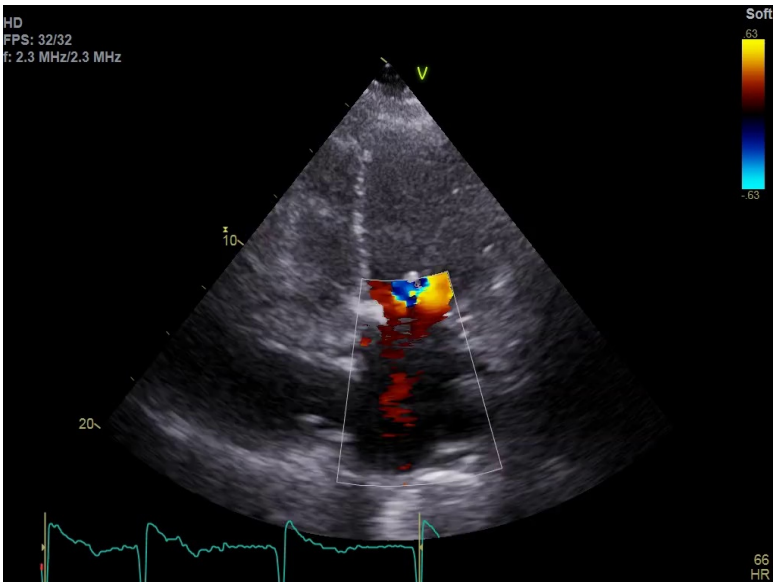

Question: Which echocardiographic view is displayed?

Options:

(A) Parasternal Long Axis

(B) Apical Four Chamber

(C) Subcostal Four Chamber

(D) Apical Two Chamber with Doppler

Correct Answer: (B)

Target:	View	Type:	View
Content:	View		

Sample #126: 260210SDE0157

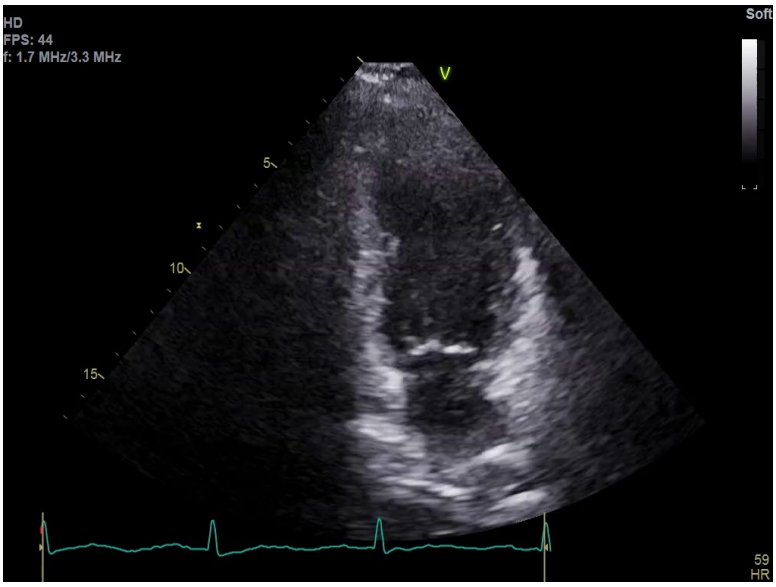

Question: Is Left Ventricular Ejection Fraction normal?

Options:

(A) No

(B) Yes

Correct Answer: (B)

Target:	Left Ventricular Ejection Fraction	Type:	Binary
Content:	Diagnosis		

Sample #213: 260210SDE0257

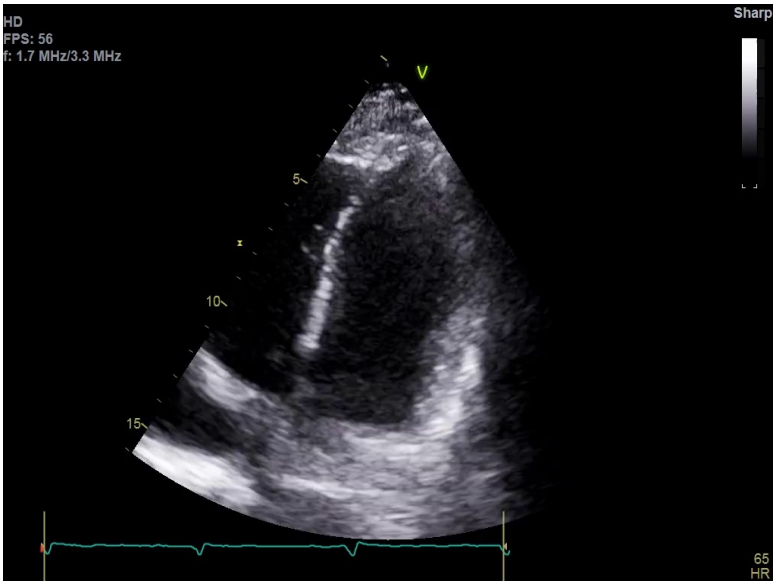

Question: Is there evidence of fluid accumulation around the heart?

Options:

(A) No

(B) Yes

Correct Answer: (A)

Target:	Pericardial Effusion	Type:	Binary
Content:	Diagnosis		

Sample #85: 260210SDE0109

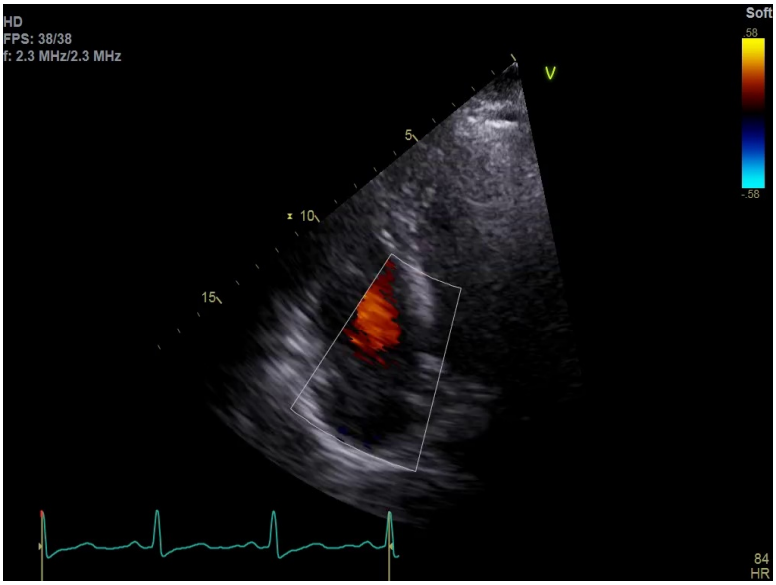

Question: Is Tricuspid Valve Regurgitation present?

Options:

(A) Yes

(B) No

Correct Answer: (B)

Target:	Tricuspid Valve Regurgitation	Type:	Binary
Content:	Diagnosis		

Sample #34: 260210SDE0045

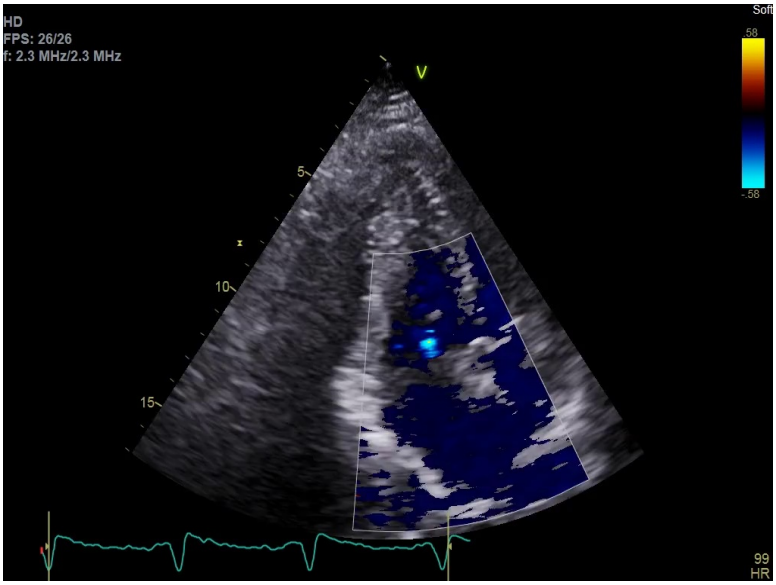

Question: Is aortic regurgitation present?

Options:

(A) No

(B) Yes

Correct Answer: (A)

Target:	TAVR	Type:	Binary
Content:	Diagnosis		

Sample #251: 260210SDE0303

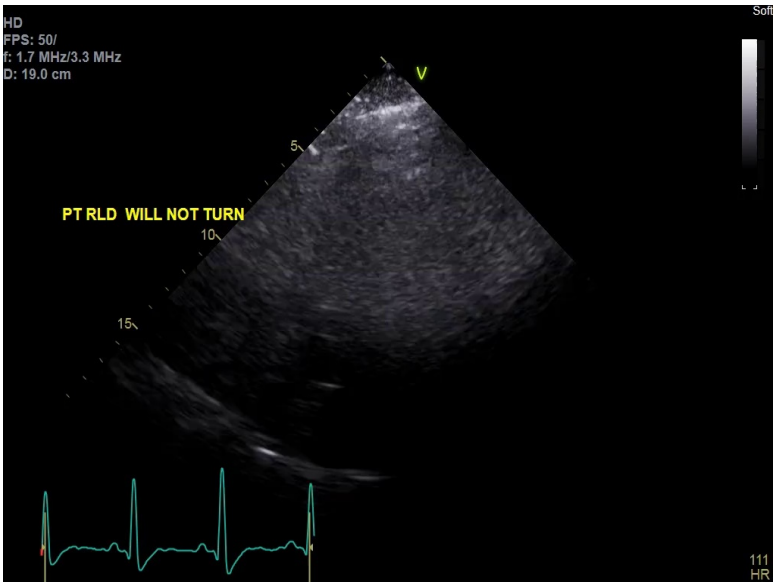

Question: Which echocardiographic view is displayed in this image?

Options:

(A) Parasternal Long Axis

(B) Apical 4-Chamber with Doppler

(C) Subcostal

(D) Apical 2-Chamber

Correct Answer: (B)

Target:	View	Type:	View
Content:	View		

Sample #69: 260210SDE0088

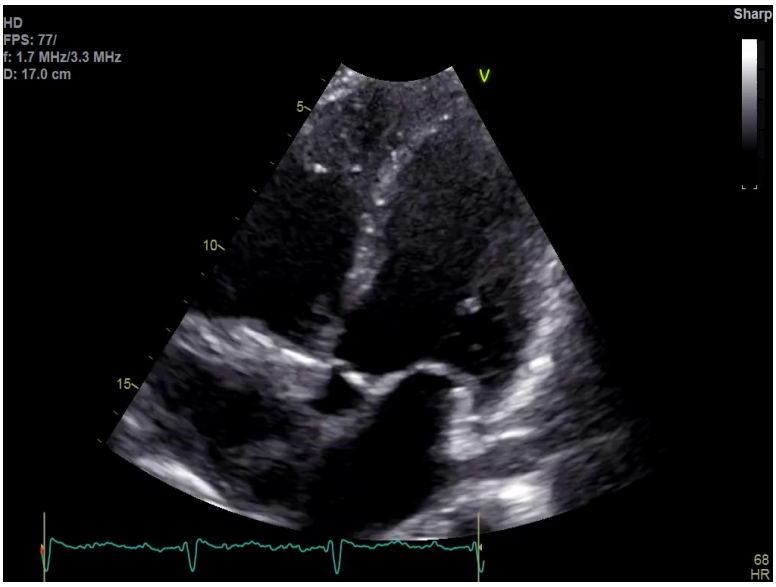

Question: Which of the following statements BEST describes the aortic valve based on the echocardiogram?

Options:

(A) The aortic valve is severely stenotic with a peak velocity exceeding 4 m/s, consistent with severe Aortic Stenosis.

(B) The aortic valve is bicuspid with restricted leaflet motion, demonstrating moderate Aortic Stenosis and mild regurgitation.

(C) Post TAVR/SAVR.

(D) The aortic valve leaflets are mildly thickened, but no significant Aortic Stenosis is present, valve opening is good.

Correct Answer: (D)

Target:	Aortic Stenosis	Type:	Descriptive
Content:	Diagnosis		

Sample #47: 260210SDE0059

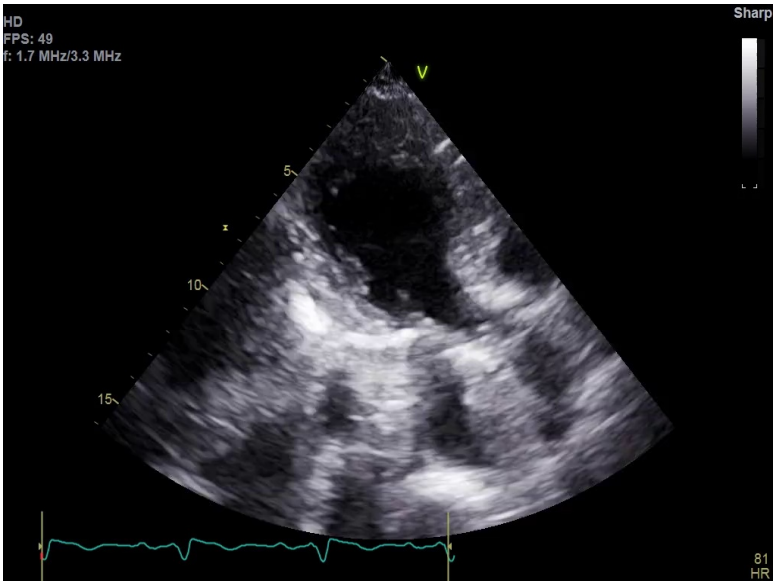

Question: Is a TAVR device present?

Options:

(A) No

(B) Yes

Correct Answer: (A)

Target:	MitraClip	Type:	Binary
Content:	Diagnosis		

Sample #109: 260210SDE0136

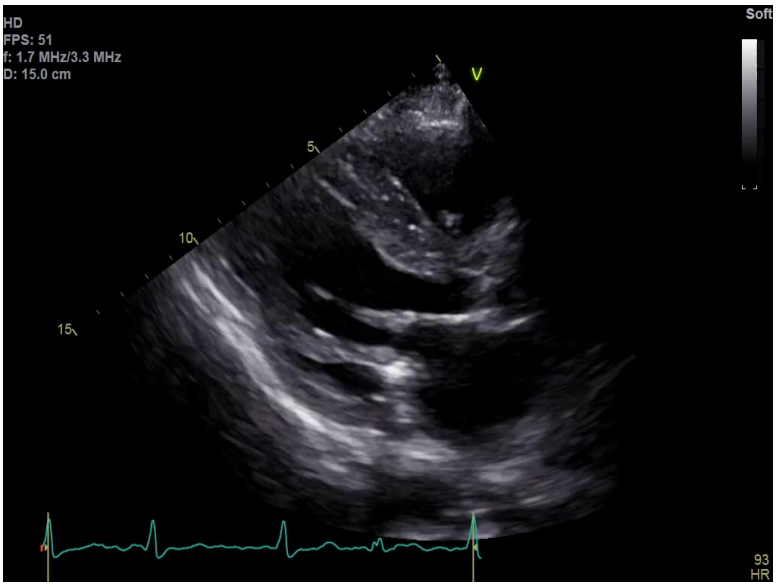

Question: Which of the following BEST describes the assessment of the left atrium?

Options:

(A) The left atrial volume index is moderately increased (significant left atrial enlargement).

(B) The left atrium appears normal in size with no evidence of enlargement or structural abnormalities.

(C) The left atrium is moderately enlarged with spontaneous echo contrast noted, suggesting a risk of thromboembolism.

(D) The left atrium is severely dilated with restricted filling due to constrictive physiology.

Correct Answer: (A)

Target:	Left Atrial Size	Type:	Descriptive
Content:	Diagnosis		

Sample #7: 260210SDE0006

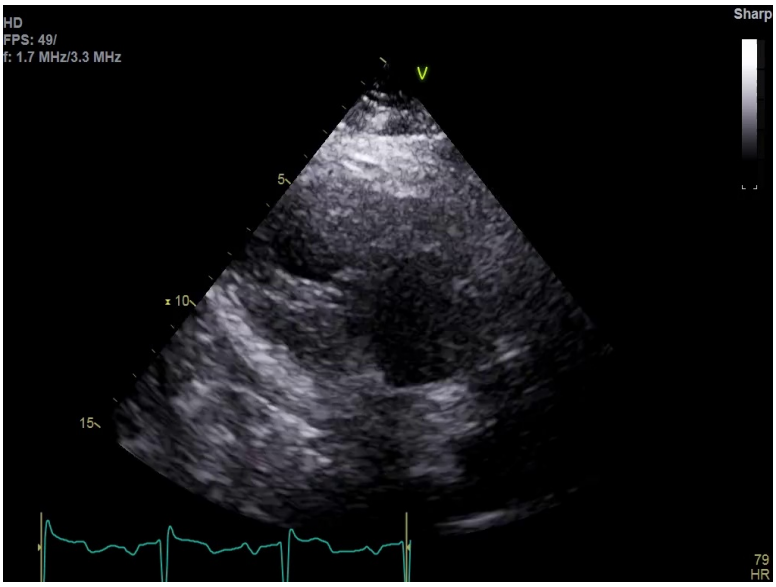

Question: Is a Pacemaker visible?

Options:

(A) No

(B) Yes

Correct Answer: (A)

Target:	Pacemaker	Type:	Binary
Content:	Diagnosis		

Sample #31: 260210SDE0041

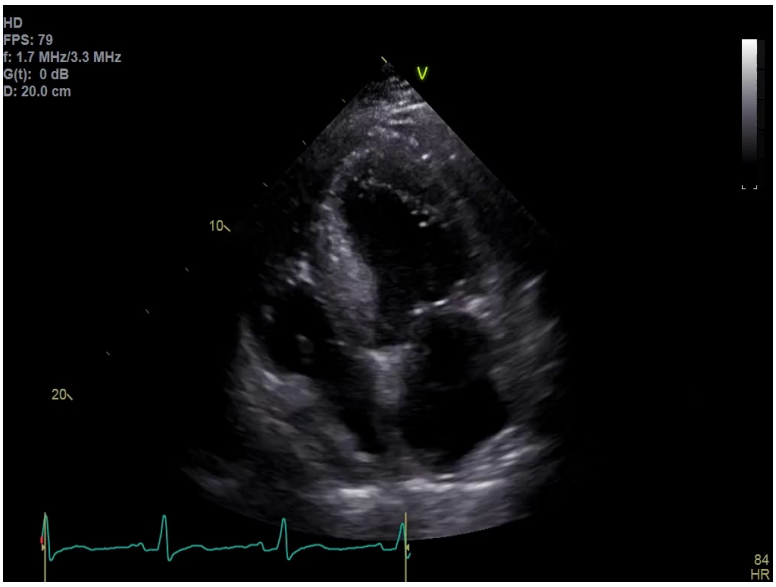

Question: Is aortic rupture present?

Options:

(A) No

(B) Yes

Correct Answer: (A)

Target:	TAVR	Type:	Binary
Content:	Diagnosis		

Sample #102: 260210SDE0128

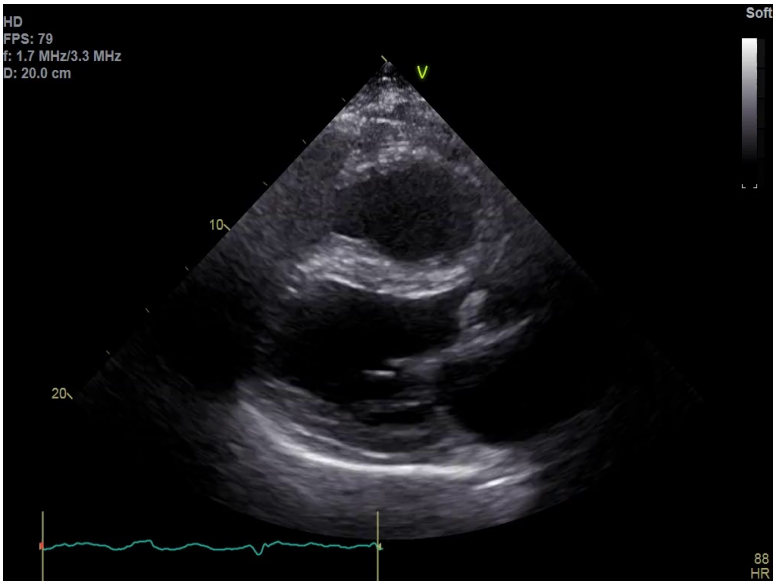

Question: Is there evidence of severe left atrial enlargement?

Options:

(A) Yes

(B) No

Correct Answer: (B)

Target:	Left Atrial Size	Type:	Binary
Content:	Diagnosis		

Sample #56: 260210SDE0070

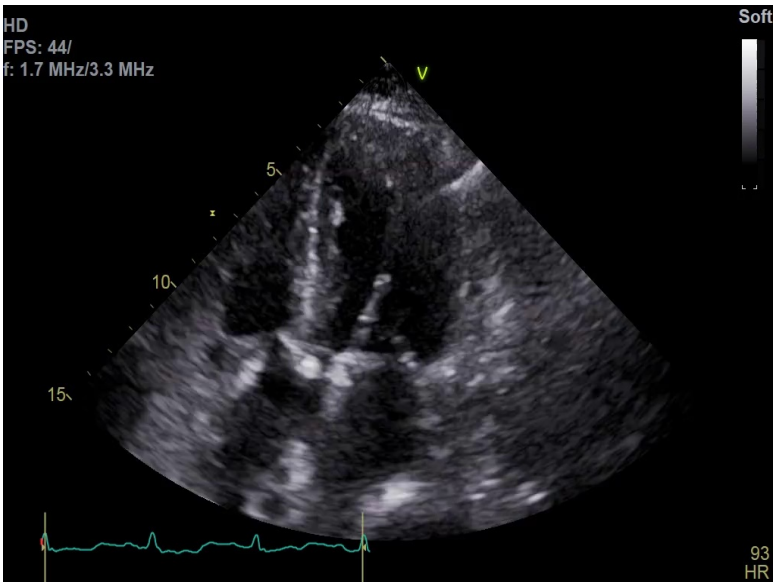

Question: Is Aortic Regurgitation present?

Options:

(A) No. This is not Doppler Image and we cannot evaluate

(B) Yes, AR is present.

Correct Answer: (A)

Target:	Aortic Stenosis	Type:	Binary
Content:	Diagnosis		