# Treatment of diabetic foot ulcers using cultured allogeneic keratinocytes—A pilot study

Hi-Jin You, MD[1]; Seung-Kyu Han, MD, PhD[1]; Jin-Woo Lee, MD, PhD[2]; Hak Chang, MD, PhD[3]

1. Department of Plastic Surgery, Korea University College of Medicine, Seoul, Korea,
2. Department of Orthopaedic Surgery, Yonsei University College of Medicine, Seoul, Korea, and
3. Department of Plastic Surgery, Seoul National University College of Medicine, Seoul, Korea

**Reprint requests:**
Prof. S.-K. Han, Department of Plastic Surgery, Korea University Guro Hospital, 97 Guro-Dong, Guro-Ku, Seoul 152-703, Korea.
Tel: +82 2 2626 3333;
Fax: +82 2 868 6698;
Email: pshan@kumc.or.kr

Presented at the International Wound and Scar Symposium in Beijing, China (September 18, 2010), and the 10th Korea-Japan Congress of Plastic and Reconstructive Surgery in Busan, Korea (June 16–18, 2010).

Manuscript received: February 16, 2011
Accepted in final form: March 5, 2012

DOI:10.1111/j.1524-475X.2012.00809.x

## ABSTRACT

Diabetic foot ulcers often pose a difficult treatment problem. Repeated applications of cell-based products have been reported to result in acceleration of diabetic wound healing. The purpose of this clinical trial study was to report preliminary findings of the efficacy and safety of the cultured allogeneic keratinocyte sheets in the treatment of diabetic foot ulcers. Fifty-nine patients with diabetic foot ulcers were randomized to either the keratinocyte treatment group ($n = 27$) or the control group treated with vaseline gauze ($n = 32$). Except for the application of keratinocytes, treatment of study ulcers was identical for patients in both groups. Either keratinocyte sheet or vaseline gauze was applied at the beginning of the study and weekly thereafter for a maximum of 11 weeks. The maximum follow-up period for each patient was 12 weeks. Complete ulcer healing was achieved in 100% of the treatment group and 69% of the control group ($p < 0.05$). The Kaplan–Meier median times to complete closure were 35 and 57 days for the keratinocyte and control groups, respectively. No adverse events related to the treatment occurred. These results indicate that cultured allogeneic keratinocytes may offer a safe and effective treatment for diabetic foot ulcers.

The current standard treatment for diabetic foot ulcers consists of debridement, control of infection, pressure relief, and lower extremity revascularization when required.[1] Debridement of a diabetic foot ulcer should be carried down to healthy, bleeding tissue. The diagnosis and treatment of infections in the diabetic foot can be complex. Diabetic patients often do not respond to infections with an elevation of body temperature and/or elevation of the white blood cell count. The culturing technique is also important. Simply swabbing the ulcer is not satisfactory and frequently produces inaccurate results. Specimens for culture should be obtained from tissues deep in the wound after debridement. Osteomyelitis is a frequent complication of diabetic foot infections. Osteomyelitis can be detected by a probing test, radiography, scanning with a radioisotope, or magnetic resonance imaging (MRI). Infected ulcers can be treated with topical antimicrobials, systemic antibiotic therapy, and appropriate debridement. Avoidance of weight bearing is essential in the management of diabetic foot ulcers. Pressure should be relieved by using optimal therapeutic footwear, crutches, total contact casts, removable cast walkers, and wheelchairs. Management of ischemia is also critical. Vascular insufficiency should be detected by evaluating pulses in the feet, ankle or toe brachial indices, arteriographic findings, and transcutaneous oxygen pressures. Vascular surgery or percutaneous transluminal angioplasty should be considered for patients with ischemic feet.

However, many of these ulcers are delayed or fail to heal using conventional treatment because attenuated activities of cells with a key role in wound healing contribute to the impairment of tissue restoration.[2,3] Consequently, there is a need for more effective therapies that will stimulate cellular activity of diabetic foot patients.

There is considerable interest in the treatment of diabetic ulcers with biological dressings and/or tissue-engineered products.[4–9] These technologies have been designed to modulate the levels of biologic molecules involving growth factors and extracellular matrices that may promote wound healing.[10,11] Recently, a biological dressing material derived from cultured keratinocytes of a Korean infant's foreskin has been developed. A sheet of the cultured allogeneic keratinocytes contains $> 2 \times 10^7$ cells backed by vaseline gauze. Keratinocytes are known to enhance wound healing by secreting and synthesizing many growth factors and major components of the basement membrane. Cultured keratinocytes have been used as allografts or autografts to cover burn wounds or chronic ulcers for many years. Previous studies have also shown that cultured allogeneic keratinocytes are effective in the treatment of chronic leg ulcers.[12,13]

This pilot study was a randomized phase III clinical trial to determine early healing outcome of a new cultured allogeneic keratinocyte sheet (Kaloderm®; Tego Science, Seoul, Korea) in the management of chronic diabetic foot ulcers. Our

primary hypothesis was that the weekly application of keratinocytes would increase the wound healing rate of chronic diabetic foot ulcers.

## PATIENTS AND METHODS

This was a stratified, randomized, single-blinded, controlled, multicenter study in which patients with diabetic foot ulcers were recruited consecutively from three centers in Korea. The clinical study protocol and informed consent were approved by the appropriate Institutional Review Boards for each participating center (Korea University Guro Hospital, Yonsei University Severance Hospital, and Seoul National University Hospital) and the Food and Drug Administration (FDA) of Korea (study code: TG-KDM-07-201).

### Patients

Patients were screened for eligibility before applying the keratinocyte sheets. The major inclusion criteria were type 1 or 2 diabetes, a foot ulcer > 1.0 $cm^2$ in size that did not exhibit signs of healing for 6 weeks, Wagner grade 1 or 2, and transcutaneous oxygen pressure ≥ 40 mmHg. Patients were excluded from this clinical trial if there was infection, cellulitis, or osteomyelitis diagnosed by MRI and microbiologic culture results. Other exclusion criteria included pregnant or lactating women, ulcers with deep vein thrombosis, venous insufficiency, a concurrent illness or a condition that may interfere with wound healing (e.g., connective tissue disorders), a Charcot deformity, sickle cell disease, diseases with a poor prognosis (including malignant tumors), current treatment with corticosteroids or immunosuppressive agents, and severe malnutrition (serum albumin < 3.0 g/dL).

Before the study, all ulcers were subjected to sharp debridement to remove necrotic or hyperkeratinized tissue and to control infection. The debridement technique was standardized during an initial meeting of the investigators, at which all investigators were instructed to debride the wound until healthy bleeding tissue was reached. In 17 patients, a systemic antibiotic therapy was prescribed. However, during the study period, antibiotics and debridement therapy were not used. Prior antibiotic therapy was acceptable if it was completed 1 week before study entry.

This study comprised an initial visit in which eligible patients were identified based on review of medical records only, a screening visit in which eligibility was determined based on laboratory tests, and the patients were enrolled and randomized into one of the two treatment groups. Randomization schedules were stratified according to clinical center with the use of a permuted-block method with a block size of four to six using the Statistical Analysis System and treatment allocation ratio of 1 : 1 and stratification at the three sites. Between January 2008 and December 2009, 37, 19, and 3 patients with diabetic foot ulcers from the Korea University Guro Hospital, the Yonsei University Severance Hospital, and the Seoul National University Hospital, respectively, were included in the clinical trial. Of these 59 patients, 27 were assigned to the treatment group and 32 were assigned to the control group. Seven patients in the treatment group and six patients in the control group were excluded before completion of the study because of the occurrence of adverse events and protocol violations. Therefore, a per-protocol analysis was conducted on the data available from the 46 patients who completed the study (Figure 1). The relevant patient information at baseline in the two treatment groups is shown in Tables 1–4. Neuropathy was determined by clinical evaluation for peripheral sensory neuropathy using a 10g Semmes-Weinstein monofilament. Neuro-ischemia was defined as neuropathy combined with transcutaneous oxygen pressure < 40 mmHg. In case of neuro-ischemic foot, however, tissue oxygenation was improved ≥ 40 mmHg by percutaneous transluminal angioplasty before the study. There were no statistically significant differences with respect to any clinical characteristics between the two groups. The wound healing results of the keratinocyte and control groups were also compared with intention-to-treat analysis.

### Techniques

Human epidermal keratinocytes isolated from the foreskin of a Korean newborn were cultured according to the Rheinwald and Green method.[14] Cells at an early passage were cultured to form a sheet for 10 days in a 3 : 1 mixture of Dulbecco's Modified Eagle Medium (Gibco, Grand Island, NY) and Ham's F-12 (Hyclone, Logan, UT) with fetal bovine serum (Hyclone) and supplements described elsewhere.[15] The epidermal sheets were chemically detached from the culture vessel, backed with vaseline gauzes, and stored frozen at −70 °C according to the manufacturer's undisclosed protocols.

In the treatment group, the ulcer was cleaned with 3% hydrogen peroxide and saline solution to remove dirt and other debris before applying the keratinocyte sheet. The keratinocyte sheet, which was stored at −70 °C, was thawed at room temperature for 5–10 minutes and cut to the wound size and applied directly to the wound bed as a primary dressing, then covered with a secondary dressing such as polyurethane foam (Medifoam, Ildong Pharmaceutical Co., Seoul, Korea). Dressing changes and application of the keratinocyte sheet were scheduled at weekly intervals. If found necessary, the patient returned to the hospital two to three times a week so that the wound could be examined and only the secondary dressing was changed. In the control group, vaseline gauze (Tego Science) was applied as the primary dressing over the wound. Control group visits and dressing changes were scheduled as in the treatment group. No concomitant biological or biochemical therapy, including growth factors, was allowed.

At every visit, the patients' feet were examined to check for cuts, sores, blisters, redness, calluses, or any other problems. The feet were washed with saline, and corns and calluses were removed gently. Toenails were cut when needed. Moisturizing lotion was applied to prevent the skin from becoming dry. The patients were made to wear soft, absorbent socks or slippers in order to protect their feet from injuries.

All patients with ulcers on weight-bearing sites or sites otherwise subjected to pressure when wearing shoes had pressure off-loaded with the use of foam dressings with a hole on the ulcer site and footwear with cushioning insoles. If clinically appropriate, the use of other weight off-loading devices, such as crutches, half-shoes, half-sandals, and wheelchairs, was allowed (Table 5).

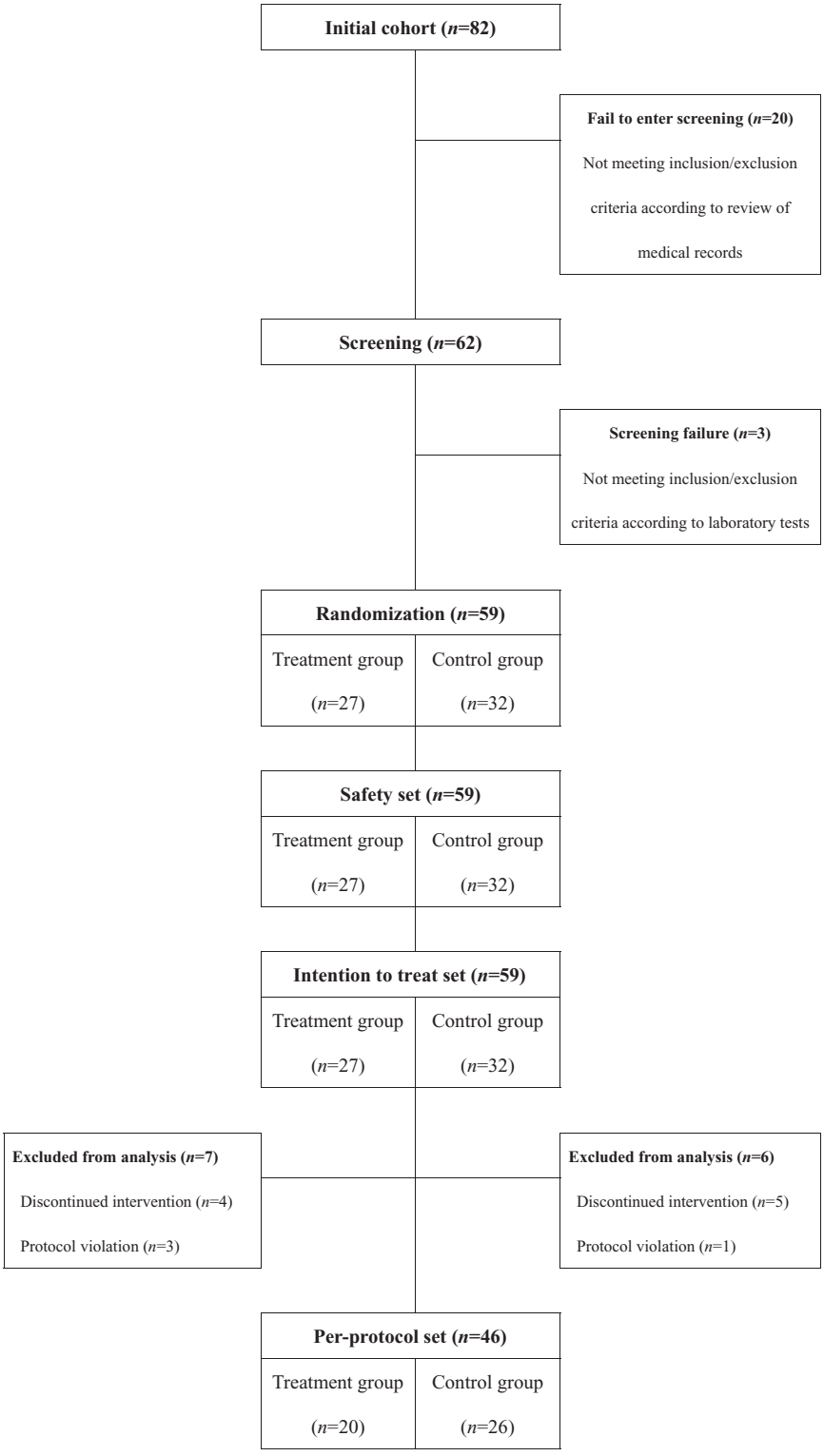


**Figure 1.** A CONSORT diagram illustrating the flow of patients involved in the study.

**Table 1.** Patient characteristics for the keratinocyte-treated and control groups

| | | Treatment group ($n = 20$) | Control group ($n = 26$) |
|---|---|---|---|
| Age (years) | | 63.5 ± 9.0 | 62.4 ± 9.4 |
| Gender | Male (%) | 13 (65) | 19 (73) |
| | Female (%) | 7 (35) | 7 (27) |
| Smoking | Nonsmoker (%) | 13 (65) | 15 (58) |
| | Ex-smoker (%) | 5 (25) | 8 (31) |
| | Smoker (%) | 2 (10) | 3 (11) |
| BMI (kg/m$^2$) | | 23.5 ± 2.7 | 22.8 ± 2.3 |
| HbA1c (%) | | 7.3 ± 1.2 | 7.5 ± 1.3 |
| Hb (g/dL) | | 11.2 ± 1.7 | 11.4 ± 1.8 |
| Albumin (g/dL) | | 4.0 ± 0.4 | 3.9 ± 0.4 |
| WBC (×10$^3$/mm$^3$) | | 7.4 ± 1.7 | 7.9 ± 2.8 |

BMI, body mass index; WBC, white blood cell.

**Table 3.** Comorbidity of patients

| | Treatment group ($n = 20$) | Control group ($n = 26$) |
|---|---|---|
| Cardiac disorder | 8 | 10 |
| Hypertension | 15 | 19 |
| Renal disorder | 7 | 10 |
| Ophthalmic disorder | 5 | 5 |
| Tremor | 3 | 4 |
| Arthritis | 3 | 2 |
| Metabolic disorder | 1 | 3 |
| Pulmonary disorder | 2 | 0 |
| Ileus | 1 | 0 |
| Pruritus | 0 | 1 |

## Evaluation

The wounds were evaluated weekly until complete wound closure or the 12th week visit if not completely healed. Wound evaluation was performed in a single-blinded fashion. The patients did not know whether or not their wounds had been treated with the keratinocytes, but the wound evaluators were aware of the method of treatment.

The primary efficacy criterion was the percentage of patients who achieved complete wound closure within the 12-week study period. The secondary efficacy criterion was the mean percentage of wound area reduction and the mean time required for complete closure in patients who achieved complete healing within 12 weeks. Complete closure was defined as a completely epithelialized state in the absence of discharge and which enabled the patient to shower. The

**Table 2.** Clinical characteristics of the ulcers at baseline

| | | Treatment group ($n = 20$) | Control group ($n = 26$) |
|---|---|---|---|
| Ulcer size (cm$^2$) | Mean ± SD | 4.0 ± 3.5 | 5.2 ± 6.4 |
| | Median | 2.0 | 1.9 |
| | Range (min–max) | 1.0–16.0 | 1.1–21.0 |
| Duration of ulcer (years) | Mean ± SD | 0.33 ± 0.24 | 0.40 ± 0.68 |
| | Median | 0.19 | 0.22 |
| | Range (min–max) | 0.12–1.1 | 0.12–1.6 |
| Wagner grade | Grade I (%) | 7 (35) | 9 (35) |
| | Grade II (%) | 13 (65) | 17 (65) |
| University of Texas grade | Grade 1 (%) | 6 (30) | 9 (35) |
| | Grade 2 (%) | 9 (45) | 8 (31) |
| | Grade 3 (%) | 5 (25) | 9 (34) |
| Ulcer location | Dorsal (forefoot : midfoot : hindfoot) | 11 (8 : 0 : 3) | 16 (10 : 2 : 4) |
| | Plantar (forefoot : midfoot : hindfoot) | 9 (6 : 1 : 2) | 10 (8 : 1 : 1) |
| TcpO2 (mmHg) | | 50.2 ± 10.9 | 54.5 ± 11.0 |
| Risk category | Neuropathy (%) | 13 (65) | 16 (62) |
| | Neuro-ischemia (%) | 2 (10) | 3 (12) |
| | Foot deformity (%) | 13 (65) | 15 (58) |
| | History of ulceration (%) | 9 (45) | 11 (42) |
| Cause of ulcer | Trauma (%) | 4 (20) | 8 (31) |
| | Pressure by shoes (%) | 10 (50) | 12 (46) |
| | Unknown (%) | 6 (30) | 6 (23) |

SD, standard deviation.

**Table 4.** Condition of ulcer

| | | Treatment group ($n = 20$) | Control group ($n = 26$) |
|---|---|---|---|
| Type of exudate | Sanguineous | 2 | 4 |
| | Serosanguineous | 14 | 20 |
| | Serous | 4 | 2 |
| | Purulent | 0 | 0 |
| Amount of exudate | None | 0 | 0 |
| | Small | 17 | 22 |
| | Moderate | 3 | 4 |
| | Large | 0 | 0 |
| Foul odor | | 0 | 0 |
| Tissue type | Slough | 4 | 5 |
| | Eschar | 0 | 0 |
| | Granulation | 13 | 18 |
| | Epithelialization | 3 | 3 |
| | Foreign body | 0 | 0 |
| Tissue adherence | None | 0 | 0 |
| | Loose | 5 | 6 |
| | Firm | 15 | 20 |

wound area was determined by means of the Visitrak Digital Planimetry Wound Measurement System (Smith & Nephew, Hull, UK) by the researchers of the study. Safety was also monitored at the time points indicated by evaluating adverse event reports, laboratory assessments, and vital signs.

Ulcer recurrences and side effects of the healed ulcers were monitored for 6 months after healing by reviewing medical records and/or telephone interviews. Final results of the unhealed ulcers were also followed up accordingly.

**Table 5.** Distribution of off-loading strategies

| | Treatment group ($n = 20$) | Control group ($n = 26$) |
|---|---|---|
| Foam dressing with a hole | 6 | 8 |
| Foam dressing with a hole + use of a crutch | 2 | 4 |
| Foam dressing with a hole + use of a wheelchair | 1 | 1 |
| Foam dressing with a hole + use of a crutch + use of a wheelchair | 1 | 1 |
| Use of a cushioning insole | 2 | 2 |
| Use of a cushioning insole + use of a crutch | 1 | 2 |
| Use of a half-sandal + use of a crutch | 1 | 1 |
| Use of a half-sandal + use of a crutch + use of a wheelchair | 1 | 0 |
| Total | 15 | 19 |

### Statistical analyses

Statistical comparisons for the healing rate, the percentage of wound area reduction, and the time to complete ulcer healing were performed. The median time to closure was also estimated by using the Kaplan–Meier method. A $p$-value $< 0.05$ was considered significant. Data are given as the mean ± standard deviation.

## RESULTS

After 12 weeks, complete wound healing occurred in all patients (100%) in the keratinocyte-treated group and 18 patients (69%) in the control group ($p < 0.05$ [chi-square test and Fisher's exact test], Figure 2).

The mean percentages of wound area reduction were 100 ± 0 and 85 ± 65% in the treatment and control groups, respectively ($p < 0.05$ [Wilcoxon rank-sum test]). The times required for complete healing were 41.5 ± 25.4 and 42.6 ± 19.4 days in the keratinocyte-treated and control groups, respectively ($p = 0.90$ [unpaired $t$-test]). In this analysis, however, comparisons between the two groups were not relevant because the control group excluded eight patients without complete healing. The Kaplan–Meier median time to complete ulcer healing was 35 days for the treatment group and 57 days for the control group (Figure 3).

Adverse events occurred in six patients (30%) in the keratinocyte group as follows: wound infections ($n = 2$); pruritis ($n = 1$); vomiting ($n = 1$); tremor ($n = 1$); and insomnia ($n = 1$). In the control group, adverse events were reported in five patients (19%) as follows: wound infections ($n = 3$); ileus ($n = 1$); and upper respiratory tract infection ($n = 1$). However, none of these events were thought to be related to the study dressings and no significant differences were noted between the two groups ($p = 0.67$ [Pearson's chi-square test]).

No clinically meaningful changes occurred from the baseline clinical and laboratory parameters in any of the patients, including serum chemistry, hematology, urinalysis, and vital signs.

Intention-to-treat analysis showed similar results. Complete wound healing occurred in 85% of the keratinocyte-treated group and 59% of the control group ($p < 0.05$ [chi-square test and Fisher's exact test]). The mean percentages of wound area reduction were 87 ± 49 and 74 ± 67% in the treatment and control groups, respectively ($p < 0.05$ [Wilcoxon rank-sum test]). The times required for complete healing were 41.6 ± 26.1 and 43.6 ± 19.4 days in the keratinocyte-treated and control groups, respectively ($p = 0.78$ [unpaired $t$-test]).

Ulcer recurrences and side effects in the healed ulcers were successfully monitored for 6 months in 16 patients in the treatment group and 15 patients in the control groups. Medical records of the patients who attended routine appointments were reviewed in six patients for the treatment group and seven patients in the control group. Ten patients and eight patients were interviewed over the telephone for the treatment

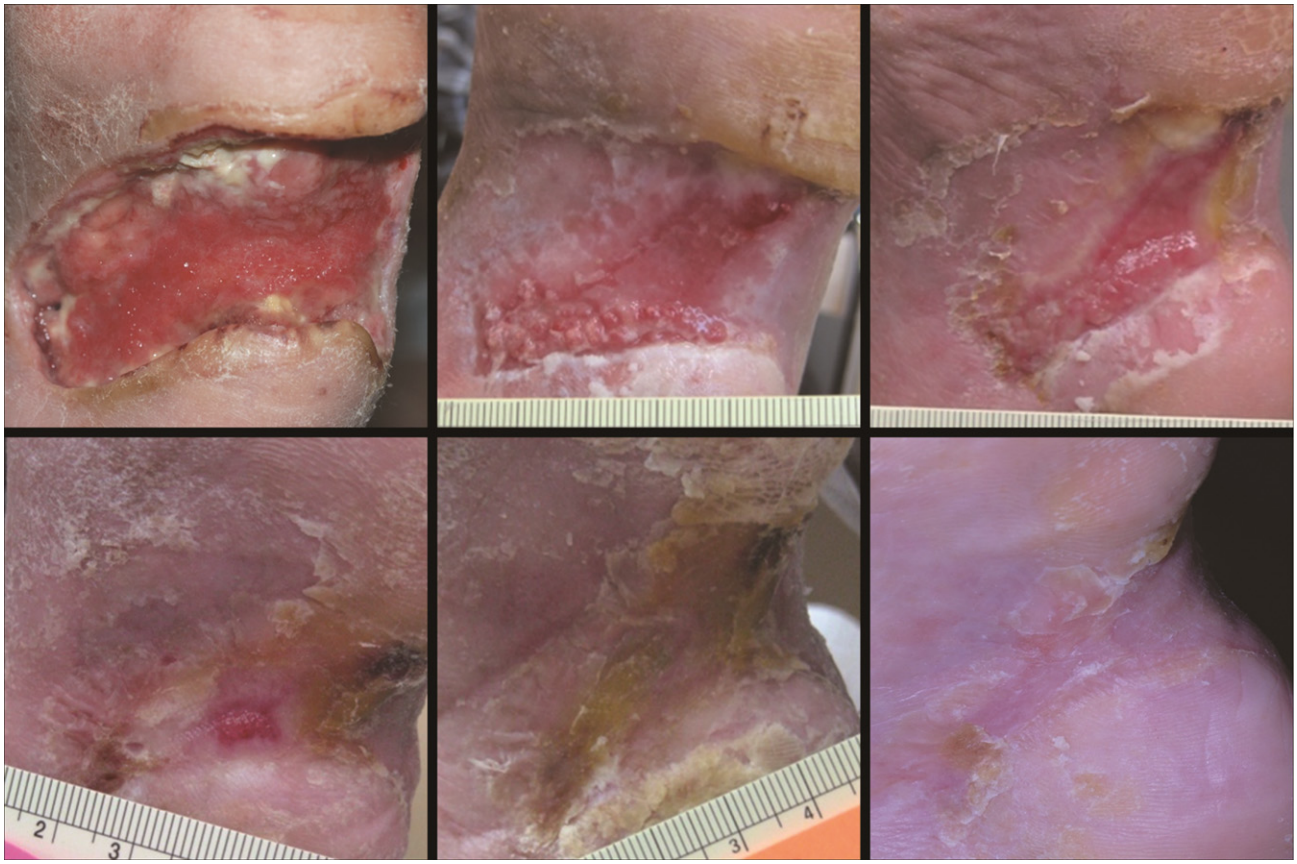

**Figure 2.** A 61-year-old man with diabetes mellitus had a nonhealing ulcer on the midplantar region of his left foot. Before coming to the clinical trial, the patient had been treated for 12 weeks. (Above, left) A preoperative view. (Above, center) Two weeks after the keratinocyte treatment. (Above, right) Three weeks after the keratinocyte treatment. (Below, left) Four weeks after the keratinocyte treatment. (Below, center) Five weeks after the treatment, the wound was completely epithelialized. (Below, right) At the 6-month follow-up, the treated site had a healthy texture.

and control groups, respectively. The incidence of ulcer recurrence was similar in the two groups, with 6.3% (1 of 16) in the treatment group and 6.7% (1 of 15) in the control group. Of the eight patients in the control group whose ulcers did not heal within 12 weeks after treatment, five patients eventually healed within another 2–10 weeks and one patient failed to respond to treatment and subsequently the wound was amputated at the proximal phalanx level. Two patients were lost to follow-up. No side effects related to wound dressings were noticed in both groups.

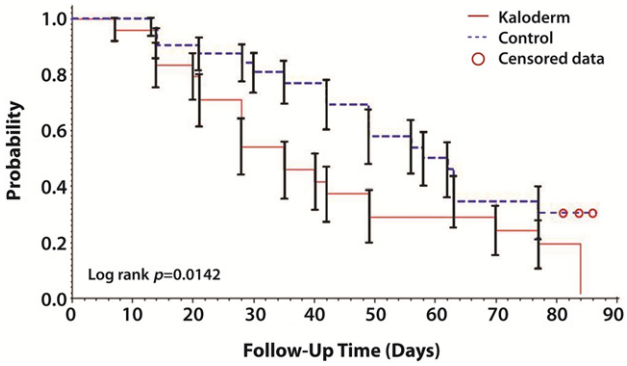


**Figure 3.** Kaplan–Meier diagram showing the results on time to wound closure.

## DISCUSSION

Optimum healing of wounds requires a well-orchestrated integration of the complex biological and molecular events of cell migration, proliferation, extracellular matrix deposition, and remodeling. In diabetic foot ulcers, however, this balance is often lost and the wound remains in the inflammatory stage too long. In addition, dermal fibroblasts from diabetic wounds commonly show decreased proliferative capacity, extracellular matrix and protein synthesis, and growth factor release.[3] The longer the ulcer persists, the greater the possibility that the patient will develop a serious infection that can lead to hospitalization and possible amputation.[7] Therefore, the patient with a diabetic ulcer remains a challenging medical, economic, and social problem.

In uninjured skin, basal keratinocytes at the dermal-epidermal junction undergo differentiation to ultimately create the strong skin barrier to the external environment. In normal acute wounds, epithelialization occurs by an orderly series of events whereby keratinocytes migrate, proliferate, and differentiate to restore barrier function. At the margins of chronic ulcers, however, keratinocytes are commonly only proliferative but fail to migrate because of attenuated cellular activity, including a deficiency in LM-3A32 molecules.[16] Therefore, the ulcers remain open too long.

Allogeneic keratinocytes do not attach and cover the ulcer permanently and are soon replaced by host keratinocytes.[12,17] However, allogeneic keratinocytes promote migration and proliferation of host keratinocytes from the wound edges or remaining hair follicles because allogeneic keratinocytes release not only growth factors (transforming growth factor [TGF]-α, platelet-derived growth factor [PDGF], basic fibroblast growth factor [bFGF], vascular endothelial growth factor [VEGF], and TGF-β) and cytokines (interleukin [IL]-1, 6, 8, and 10) but also extracellular matrices (fibronectin and laminin) and basement membrane components.[11] Eventually, the role of allogeneic keratinocytes in the healing process is to accelerate epithelialization from the wound edges and promote granulation formation.[13]

This randomized, multicenter, controlled clinical study involving cultured allogeneic keratinocyte products showed promising results. The keratinocyte treatment was superior to control treatment in all parameters evaluated in this study, including the complete wound healing rate, reduction in wound size, and time for wound closure. In addition, the safety and tolerability were excellent; no adverse events related to the study treatment occurred. Thus, the addition of cultured allogeneic keratinocytes to a regimen of conventional diabetic foot ulcer management, including debridement, infection control, and pressure off-loading, may result in a significant benefit.

The allogeneic keratinocyte sheets used in this study were manufactured at a facility whose safety criteria and management system were in accordance with Korean Good Manufacturing Practice standards. The keratinocytes impregnated in the sheets were obtained from one Korean neonate and were stored in a cell bank with strict quality control standards in accordance with the Korean FDA guidelines. Verification of the manufacturing system was done through validation of both the manufacturing facility and process; the safety of the manufacturing system was also checked and confirmed every year by Korean FDA inspection. Each manufactured lot of keratinocyte sheets underwent several tests including a sterility test, endotoxin test, mycoplasma test, adventitious virus test, identity test, purity test, and potency test to further ensure safety. As the allogeneic keratinocyte sheets are widely used as a safe and useful therapeutic agent for healing deep second-degree burns in clinical settings in Korea, the authors feel that it is safe to say that the culture system has already been thoroughly verified and validated.

During the methodologic planning for this clinical trial, the sample size was estimated to be sufficiently large to reliably detect the smallest possible difference in the primary outcome based on the result of a previous study.[18] The power of the study was chosen to be 80%, the level of significance was set at 5%, and the drop-out rate was assumed to be 20%. Control treatment was planned to use vaseline gauze because the cultured allogeneic keratinocyte sheet was also backed with vaseline gauze. The keratinocyte sheet or vaseline gauze was set to be applied at weekly intervals because the effect of the keratinocyte sheet had been shown to last for approximately 1 week in previous experiments (unpublished data). The end point of 12 weeks was determined by the protocols of former clinical trials using similar treatments (an epidermal growth factor product and an autologous fibroblast product for treatment of diabetic ulcers) registered in the Korean FDA.

Other studies involving the use of cultured allogeneic keratinocytes by various types of delivery systems of the cells to the wound exist in the literature. Among them, two groups studied them in patients with diabetic foot ulcers. Harvima et al.[12] studied the effect of fresh allogeneic keratinocytes seeded on a nylon mesh in 18 patients with diabetic foot ulcers at weekly intervals and the mean healing time was 64 ± 61 days. Bayram et al.[18] used living allogeneic keratinocytes delivered using microcarriers. A single layer of keratinocyte-loaded microcarriers was applied to the wounds and vaseline gauze was applied over the microcarriers (one dressing/3 days). They reported a 92% mean reduction of the wound area within 30 days. However, the allogeneic keratinocytes used in the two studies were not cryopreserved but were fresh. Therefore, these methods are not available for use immediately and are also not convenient for physicians and patients to use. They are not commercially available. There have been only two studies showing the effects of the commercialized cryopreserved allogeneic keratinocytes—LyphoDerm® (XCELLentis, Gent, Belgium) and CryoCeal® (XCELLentis).[19,20] However, these two products were studied only in patients with venous leg ulcers and not in patients with diabetic ulcers. Harding et al.[19] used LyphoDerm®, formulated into a hydrophilic gel, at weekly intervals and showed that 38% of the patients had complete ulcer healing within 24 weeks. The time to complete ulcer healing was 139.7 ± 5.6 days. Beele et al.[20] used CryoCeal® (XCELLentis), which were cryopreserved cultured allogeneic keratinocytes supported by an inert medical-grade nylon gauze at biweekly intervals. Forty-one percent of patients had complete wound closure within 24 weeks. The time required for complete wound closure ranged from 4.1 to 24.9 weeks. Our study could be the first report demonstrating the efficacy of a commercially available allogeneic keratinocyte product in treatment of diabetic foot ulcers. In addition, comparisons between the results of this study and others using cultured skin derivatives are presented in Table 6.[6,7,9,21] The sequential fibrinogen and thrombin spray application has also offered an elegant nontouch approach to evenly deliver the cells to the wounds.[22] However, comparisons between the results of our study and previous studies are not relevant because the protocols varied widely.

Using the cultured allogeneic keratinocytes for treatment of diabetic foot ulcers has the following advantages. First, cultured keratinocytes are derived from an unrelated allogeneic donor and may be stockpiled. Cell Bank enables a large-scale production, and the keratinocyte sheet can be stored at −70 °C and is stable for 24 months. The keratinocyte sheet is available immediately and convenient to use for physicians and patients. Unlike autologous keratinocytes, no biopsy is necessary and patients do not need to wait for the cells to be processed. The keratinocyte sheet was nearly ready-made when the patient arrived at the clinic. Second, cultured human keratinocytes have a direct antimicrobial effect. Maier et al.[23]

**Table 6.** Comparison of results with the other type of cultured skin derivatives

| Authors (reference number) | Follow-up period | Cultured cell product | Complete healing rate | Median time to complete closure (days) |
|---|---|---|---|---|
| You et al. (this study) | 12 weeks | Kaloderm™ | 100% | 35 |
| | | Control | 69% | 57 |
| Edmonds[6] | 12 weeks | Apligraf™ | 51.5% | 84 |
| | | Control | 26.3% | No data |
| Veves et al.[9] | 12 weeks | Graftskin™ | 56% | 65 |
| | | Control | 38% | 90 |
| Marston et al.[7] | 12 weeks | Dermagraft® | 30% | No data |
| | | Control | 18.3% | No data |
| Caravaggi et al.[21] | 11 weeks | Hyalograft-3D™ | 65.3% | 57 |
| | | Control | 49.6% | 77 |

reported that keratinocytes, usually considered sensitive to bacterial contamination, are able to inhibit bacterial colonization of freshly excised burn wounds and chronic ulcers. Finally, the cultured allogeneic keratinocytes do not elicit a significant immunologic response from the host. This lack of rejection may have been due to the fact that the cultured keratinocytes lost some of their immunologic properties.[24] Experimentally, cultured allogeneic keratinocytes have been shown to inhibit the response to alloantigen for both native T cells and anti-CD3-activated T cells. This inhibition is thought to be due to soluble factors secreted by keratinocytes.[24]

It is important to emphasize that the cultured allogeneic keratinocyte sheet must be used along with other standard principles of diabetic foot ulcer management, including debridement, infection control, pressure off-loading, and revascularization.[2,3] Without adhering to these important principles, the addition of an active adjunctive modality is unlikely to result in improved healing rates. The diabetic foot ulcer patients, who do not exhibit significant signs of wound healing despite good metabolic control, acceptable vascularity (transcutaneous oxygen pressure $\geq$ 40 mmHg), adequate pressure off-loading, and absence of infection,[25,26] may be good responders to allogenic keratinocyte treatment. Before the keratinocyte sheets are applied, the wound condition should also be assessed for appropriateness. The wound bed should be healthy and clean with or without granulation tissue. There should not be any accompanying devitalized tissue, increased drainage, increase in size, or odor. Wound edges should be open to allow for epithelial migration. Periwound tissue should not be macerated or indurated.

The present study had some limitations. First, wound evaluation was performed in a single-blind fashion. The wound evaluators knew whether or not the patients were in the keratinocyte-treated group, which might have affected the results. However, this was unavoidable because the wound evaluators could discriminate between the keratinocyte sheets and the vaseline gauzes. Second, further studies with a larger sample of patients and the long-term outcome after accelerated wound healing are required to establish the effect of the cultured allogeneic keratinocytes with certainty. Third, the primary etiology (neuropathic vs. neuro-ischemic) and anatomical location of the ulcers, which may be important and crucial in the management of diabetic foot ulcers, were not separately selected in the study design. Fourth, studies are necessary to determine the optimal interval for keratinocyte application. Application of the keratinocytes more frequently than once a week might reduce the time to healing. Lastly, there could be a healthy selection bias as the study population is likely to be healthier than the general diabetic foot patients.

Improvement in the understanding of wound healing mechanisms and the field of bioengineering have led to the development of various advanced products, such as growth factors and living skin equivalents.[9] The cultured allogeneic keratinocyte sheet, which is one such new treatment, may be safe and effective for the treatment of nonischemic diabetic foot ulcers without infection. Additional pressure off-loading is crucial for the healing of ulcers.

## ACKNOWLEDGMENTS

This study was supported by grants from Tego Science (Seoul, Korea). This clinical trial was approved by the FDA of Korea (study code: TG-KDM-07-201). None of the authors have any conflict of interest.

## REFERENCES

1. American Diabetes Association. Consensus Development Conference on Diabetic Foot Wound Care: 7–8 April 1999, Boston, Massachusetts. *Diabetes Care* 1999; 22: 1354–60.
2. Han SK, Kim HR, Kim WK. The treatment of diabetic foot ulcers with uncultured, processed lipoaspirate cells: a pilot study. *Wound Rep Reg* 2010; 18: 342–8.
3. Han SK, Kim HS, Kim WK. Efficacy and safety of fresh fibroblast allografts in the treatment of diabetic foot ulcers. *Dermatol Surg* 2009; 35: 1342–8.
4. Teng YJ, Li YP, Wang JW, Yang KH, Zhang YC, Wang YJ, Tian JH, Ma B, Wang JM, Yan X. Bioengineered skin in diabetic foot ulcers. *Diabetes Obes Metab* 2010; 12: 307–15.
5. Steinberg JS, Edmonds M, Hurley DP Jr, King WN. Confirmatory data from EU study supports Apligraf for the treatment of neuropathic diabetic foot ulcers. *J Am Podiatr Med Assoc* 2010; 100: 73–7.
6. Edmonds M. Apligraf in the treatment of neuropathic diabetic foot ulcers. *Int J Low Extrem Wounds* 2009; 8: 11–8.

7. Marston WA, Hanft J, Norwood P, Pollak R, Dermagraft Diabetic Foot Ulcer Study Group. The efficacy and safety of Dermagraft in improving the healing of chronic diabetic foot ulcers: results of a prospective randomized trial. *Diabetes Care* 2003; 26: 1701–5.
8. Marston WA. Dermagraft, a bioengineered human dermal equivalent for the treatment of chronic nonhealing diabetic foot ulcer. *Expert Rev Med Devices* 2004; 1: 21–31.
9. Veves A, Falanga V, Armstrong DG, Sabolinski ML, Apligraf Diabetic Foot Ulcer Study. Graftskin, a human skin equivalent, is effective in the management of noninfected neuropathic diabetic foot ulcers: a prospective randomized multicenter clinical trial. *Diabetes Care* 2001; 24: 290–5.
10. Shevchenko RV, James SL, James SE. A review of tissue-engineered skin bioconstructs available for skin reconstruction. *J R Soc Interface* 2010; 7: 229–58.
11. Spiekstra SW, Breetveld M, Rustemeyer T, Scheper RJ, Gibbs S. Wound-healing factors secreted by epidermal keratinocytes and dermal fibroblasts in skin substitutes. *Wound Rep Reg* 2007; 15: 708–17.
12. Harvima IT, Virnes S, Kauppinen L, Huttunen M, Kivinen P, Niskanen L, Horsmanheimo M. Cultured allogeneic skin cells are effective in the treatment of chronic diabetic leg and foot ulcers. *Acta Derm Venereol* 1999; 79: 217–20.
13. Bolivar-Flores YJ, Kuri-Harcuch W. Frozen allogeneic human epidermal cultured sheets for the cure of complicated leg ulcers. *Dermatol Surg* 1999; 25: 610–7.
14. Rheinwald JG, Green H. Serial cultivation of strains of human epidermal keratinocytes: the formation of keratinizing colonies from single cells. *Cell* 1975; 6: 331–43.
15. Barrandon Y, Green H. Three clonal types of keratinocyte with different capacities for multiplication. *Proc Natl Acad Sci U S A* 1987; 84: 2302–6.
16. Usui ML, Mansbridge JN, Carter WG, Fujita M, Olerud JE. Keratinocyte migration, proliferation, and differentiation in chronic ulcers from patients with diabetes and normal wounds. *J Histochem Cytochem* 2008; 56: 687–96.
17. Vranckx JJ, Hoeller D, Velander PE, Theopold CF, Petrie N, Takedo A, Eriksson E, Yao F. Cell suspension cultures of allogenic keratinocytes are efficient carriers for ex vivo gene transfer and accelerate the healing of full-thickness skin wounds by overexpression of human epidermal growth factor. *Wound Rep Reg* 2007; 15: 657–64.
18. Bayram Y, Deveci M, Imirzalioglu N, Soysal Y, Sengezer M. The cell based dressing with living allogenic keratinocytes in the treatment of foot ulcers: a case study. *Br J Plast Surg* 2005; 58: 988–96.
19. Harding KG, Krieg T, Eming SA, Flour ML, Jawien A, Cencora A, Kaszuba A, Noszcyk W, Willems P, De Deene A, Joos E, De Waele P, Delaey B. Efficacy and safety of the freeze-dried cultured human keratinocyte lysate, LyphoDerm 0.9%, in the treatment of hard-to-heal venous leg ulcers. *Wound Rep Reg* 2005; 13: 138–47.
20. Beele H, de la Brassine M, Lambert J, Suys E, De Cuyper C, Decroix J, Boyden B, Tobback L, Hulstaert F, De Schepper S, Brissinck J, Delaey B, Draye JP, De Deene A, De Waele P, Verbeken G. A prospective multicenter study of the efficacy and tolerability of cryopreserved allogenic human keratinocytes to treat venous leg ulcers. *Int J Low Extrem Wounds* 2005; 4: 225–33.
21. Caravaggi C, De Giglio R, Pritelli C, Sommaria M, Dalla Noce S, Faglia E, Mantero M, Clerici G, Fratino P, Dalla Paola L, Mariani G, Mingardi R, Morabito A. HYAFF 11-based autologous dermal and epidermal grafts in the treatment of noninfected diabetic plantar and dorsal foot ulcers: a prospective, multicenter, controlled, randomized clinical trial. *Diabetes Care* 2003; 26: 2853–9.
22. Harkin DG, Dawson RA, Upton Z. Optimized delivery of skin keratinocytes by aerosolization and suspension in fibrin tissue adhesive. *Wound Rep Reg* 2006; 14: 354–63.
23. Maier K, Ehrhardt G, Frevert J. Antibacterial activity of cultured human keratinocytes. *Arch Dermatol Res* 1992; 284: 119–21.
24. Badiavas EV, Paquette D, Carson P, Falanga V. Human chronic wounds treated with bioengineered skin: histologic evidence of host-graft interactions. *J Am Acad Dermatol* 2002; 46: 524–30.
25. Rhee SM, Han SK, Kim WK. Difference of microbiology according to tissue sampling in bone involved diabetic ulcers. *J Korean Soc Plast Reconstr Surg* 2010; 37: 335–9.
26. Lee JM, Han SK, Gu JH, Jeong SH, Kim WK. Comparison of white blood cell count, erythrocyte sedimentation rate, and C-reactive protein for diagnosis of diabetic foot infection. *J Korean Soc Plast Reconstr Surg* 2010; 37: 346–50.