Randomised controlled clinical trial for autologous fibroblast-hyaluronic acid complex in treating diabetic foot ulcers

• **Objective:** Diabetic foot ulcers (DFUs) often pose a treatment problem. Bioengineered skin substitutes have been reported to result in accelerated diabetic wound healing. The purpose of this clinical trial was to evaluate the efficacy and safety of the autologous fibroblast-hyaluronic acid complex for treating DFUs.

• **Method:** A stratified, randomised, controlled, multicentre study was carried out. Patients with DFUs were allocated to either a treatment group with grafting of an autologous fibroblast-hyaluronic acid complex or a control group with non-adherent foam dressing. Except for application of the fibroblast complex, treatment of the study ulcers was identical for patients in both groups. The maximum follow-up period for each patient was 12 weeks.

• **Results:** Complete ulcer healing was achieved in 84% (26/31 patients) of the treatment group and 34% (11/32 patients) of the control group ($p<0.05$). The times required for complete healing were 36.4±17.6 and 48.4±13.1 days in the treatment and control groups, respectively ($p<0.05$). No adverse events related to treatment occurred.

• **Conclusion:** These results indicate that autologous fibroblast-hyaluronic acid complex may offer a safe and effective treatment for DFUs.

• **Declaration of interest:** This study was supported by grants from ChaBio & Diostech (Seoul, Korea). This clinical trial was approved by the FDA of Korea. None of the authors have any conflicts of interest.

diabetic foot; fibroblast; hyaluronic acid; diabetic foot ulcer; wound healing

There is considerable interest in the treatment of diabetic ulcers with biological dressings and/or tissue-engineered products.[1] These technologies have been designed to modulate the levels of biological molecules including growth factors and extracellular matrices that may promote wound healing. In particular, various types of allogeneic skin substitutes composed of cryopreserved keratinocytes and/or fibroblasts have been made commercially available.[2,3] However, it is difficult for the grafted frozen cells to recover, colonise, and persist in chronic wound beds lacking in oxygen and nutrient supply. Cell activities are impaired because of cryopreservation; in addition, lower rates of recovery have been reported in growth factor expression and angiogenesis.[4–6] To overcome the limitations of such cryopreserved cell allografts, we developed a non-cryopreserved fresh fibroblast allograft method. Our previous studies have demonstrated promising results for the method.[7,8] However, the fate of cultured allogeneic fibroblasts on the wound bed is unknown, and fresh allogeneic fibroblasts may carry the risk of immunological reaction or cross infection in contrast to autologous fibroblasts.[9] Furthermore, it may be difficult for a clinician who cultures cells in a laboratory dedicated to research to use this method for patients, as there are no commercially available non-cryopreserved allogeneic fibroblast products.

A bioengineered dermal substitute comprised of cultured autologous fibroblasts seeded on a hyaluronic acid sheet was developed and used to treat chronic ulcers.[10–13] However, a randomised controlled clinical trial on the autologous fibroblast sheet is lacking. This randomised phase III clinical trial was conducted to determine the efficacy and safety of hyaluronic acid-based autologous fibroblast graft (Hyalograft 3D; ChaBio & Diostech, Seoul, Korea) for managing chronic diabetic foot ulcers (DFUs).

Method

This was a stratified, randomised, controlled, multicentre study in which patients with DFUs were recruited consecutively from two centres in Korea. The clinical study protocol and informed consent were approved by the appropriate institutional review boards for each participating centre (Korea University Guro Hospital and the Catholic Univer-

H.J.You,[1] MD, MSc, Clinical Instructor;
S.K. Han,[1] MD, PhD, Professor;
J.W. Rhie,[2] MD, PhD, Professor;
1 Department of Plastic Surgery, Korea University College of Medicine, Seoul, Korea.
2 Department of Plastic Surgery, The Catholic University of Korea School of Medicine, Seoul, Korea.

Email: pshan@kumc.or.kr

© 2014 MA Healthcare Ltd

RIGHTSLINK
Copyright Clearance Center
ournal of Wound Care. Downloaded from magonlinelibrary.com by 130.179.016.201 on September 12, 2015. For personal use only. No other uses without permission. . All rights reserve

Table 1. Wagner classification

Grade	Lesion
0	Intact skin
1	Superficial ulcer of skin or subcutaneous tissue
2	Ulcer extend into tendon, bone, or capsule
3	Deep ulcer with osteomyelitis or abscess
4	Gangrene of toes or forefoot
5	Midfoot or hindfoot gangrene

sity Seoul St. Mary's Hospital) and the Food and Drug Administration (FDA) of Korea (study code:CBD-CTP-0701).

Patients

This study included an initial visit in which eligible patients were identified based on review of medical records only and a screening visit in which eligibility was determined based on laboratory tests. The major inclusion criteria were 18 years or older with type 1 or 2 diabetes, a foot ulcer ≥1.0cm^2 in size that did not exhibit signs of healing for 6 weeks prior to inclusion, Wagner grade 1 or 2 (University of Texas system 1A, 2A, or 3A; Tables 1 and 2) and adequate circulation as evidenced by transcutaneous oxygen pressure ≥30mmHg. Ulcers on the borders between the dorsal and plantar sides were included. However, patients were excluded if the ulcer was located on the plantar side of the foot, in the case of infection, cellulitis, or osteomyelitis. Osteomyelitis was diagnosed by X-ray and bone-proving test for Wagner grade 1 ulcers and by microbiological culture results for grade 2 ulcers. Other exclusion criteria included pregnant or lactating women, ulcers with deep vein thrombosis, venous insufficiency, concurrent connective tissue diseases that may interfere with wound healing (for example, rheumatoid arthritis and systemic lupus erythematosus); sickle cell disease; Charcot deformity; diseases with a poor prognosis (including malignant tumours); current treatment with corticosteroid, immunosuppressive agents, radiation therapy, or chemotherapy; and malnutrition (albumin <3.0g/dl).

Table 2. The University of Texas wound classification system

Grade/ Stage	0	1	2	3
A	Pre/ postulcerative lesion completely epithelialised	Superficial wound not involving tendon, capsule, or bone	Wound penetrating to tendon or capsule	Wound penetrating to bone or joint
B	Infection	Infection	Infection	Infection
C	Ischaemia	Ischaemia	Ischaemia	Ischaemia
D	Infection and ischaemia	Infection and ischaemia	Infection and ischaemia	Infection and ischaemia

Fig 1. Skin biopsy taken from a patient.(a). Autologous fibroblasts seeded on 8×8cm sized hyaluronic acid sheet (b). The fibroblast sheet is tailored(c). The fibroblast sheet after grafting (d).

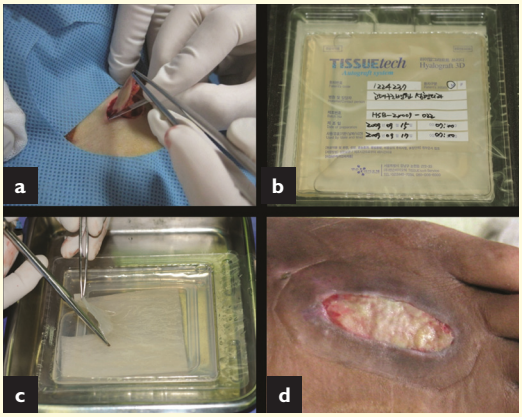

All ulcers were subjected to sharp debridement to remove necrotic or hyperkeratinised tissue and to control infection before the study. The debridement technique was standardised during an initial meeting of the investigators, at which they were all instructed to debride the wound until healthy bleeding tissue was reached. Wound infections were treated with appropriate antibiotics.

The patients were enrolled and randomised into one of the two treatment groups. Randomisation schedules were stratified with the use of a permuted-block method with a block size of four to six using the statistical analysis system and a treatment allocation ratio of 1:1.

Protcol

A skin biopsy (approximately 1cm^2) was performed on each patient who was randomised to the treatment group (Fig 1a). The harvested skin was sent to a commercial laboratory (ChaBio & Diostech) for fibroblast culture. Once the fibroblast number reached >5×10^6, the cells were seeded on 8×8 cm sized three-dimensional, non-woven benzyl ester hyaluronic acid sheet. The fibroblast-hyaluronic acid complex was ready for transplantation seven days after seeding (Fig 1b). The wound was cleaned to remove dirt and other debris with 3% hydrogen peroxide followed by saline solution. The fibroblast sheet was tailored according to the wound size and shape (Fig 1c) and applied directly to the wound bed as a primary dressing (Fig 1d). It was then covered with polyurethane foam (Medifoam, Ildong Pharmaceutical Co., Seoul, Korea) as a secondary dressing. The graft and polyurethane foam were left on the wound for seven days. Dressing changes were scheduled at weekly intervals. If found necessary, the patient returned to the hospital 2–3

© 2014 MA Healthcare Ltd

RIGHTSLINK
Journal of Wound Care. Downloaded from magonlinelibrary.com by 130.179.016.201 on September 12, 2015. For personal use only. No other uses without permission. . All rights reserve

Fig 2. A CONSORT diagram illustrating the flow of patients involved in the study

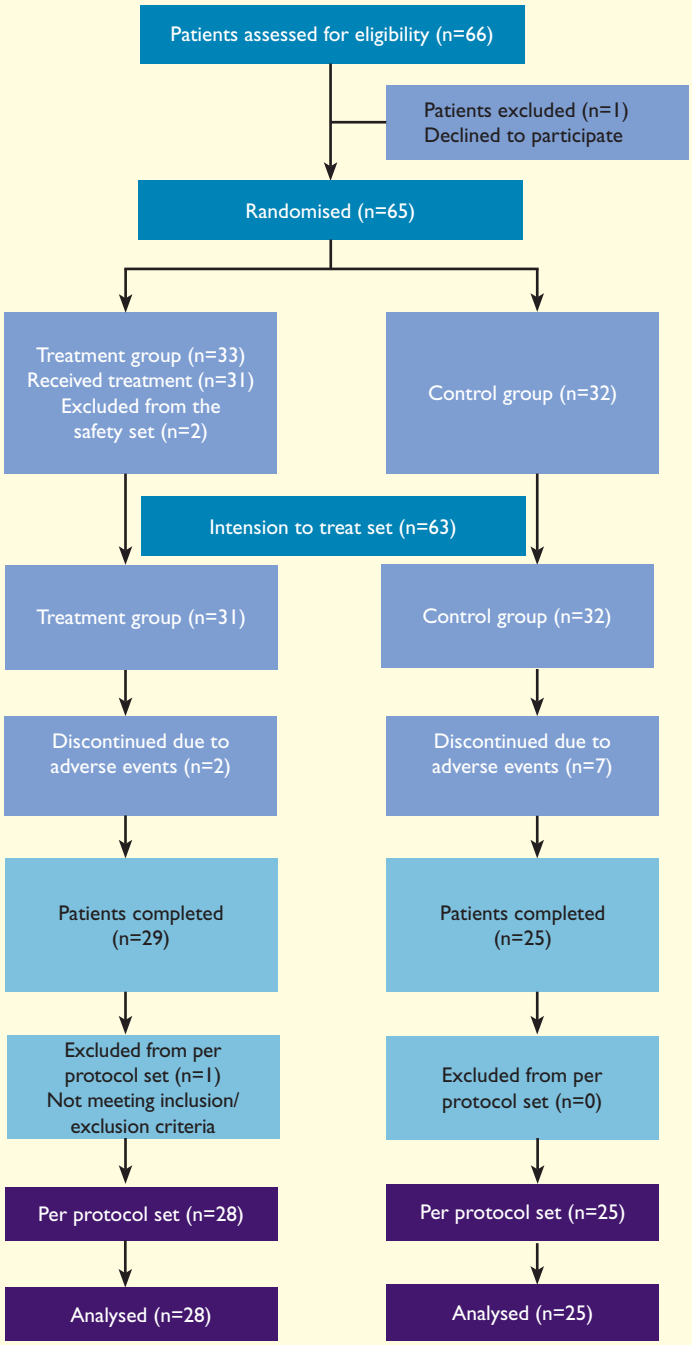

times per week after application of the graft so that the wound could be examined, and only the secondary dressing was changed.

Patients in the control group were treated with the same polyurethane foam dressing without the fibroblast-hyaluronic acid complex. Control group visits and dressing changes were scheduled as for the treatment group. A detailed description of the wound bed and an ulcer area tracing were recorded at every visit.

Evaluation

The wounds were evaluated weekly until complete wound closure or the twelfth-week visit if the wound was not completely healed. The primary efficacy cri-

© 2014 MA Healthcare Ltd

RIGHTSLINK
Journal of Wound Care. Downloaded from magonlinelibrary.com by 130.179.016.201 on September 12, 2015. For personal use only. No other uses without permission. . All rights reserve

Table 3. Patient characteristics

		Treatment group (n=31)	Control group (n=32)
Age (years)		61.2±11.4	63.8±10.7
Gender	Male (%)	21 (68)	22 (69)
	Female (%)	10 (32)	10 (31)
Smoking	Non-smoker (%)	18 (58)	17 (53)
	Ex-smoker (%)	9 (29)	11 (34)
	Smoker (%)	4 (13)	4 (13)
Body mass index(kg/m^2)		23.4±3.6	23.2±3.2
HbA1c (%)		7.1±1.1	7.4±1.3
Hb (g/dL)		11.8±1.7	11.7±1.4
Albumin (g/dL)		4.0±0.5	3.9±0.3
White blood cell ($x10^3$/μL)		6.7±1.7	7.5±2.1

terion was the percentage of patients who achieved complete wound closure within the 12-week study period. The secondary efficacy criterion was the change in mean wound size from baseline to week 12 and the mean time required for complete closure in patients who achieved complete healing within 12 weeks. Complete closure was defined as a completely epithelialised state in the absence of any discharge and which allowed the patient to shower. Wound size was determined by the Visitrak Digital Planimetry Wound Measurement System (Smith & Nephew, UK). Safety was also assessed by evaluating adverse event reports, laboratory assessments, and vital signs throughout the trial.

Statistical analyses

Statistical comparisons for healing rate were performed using Pearson's chi-square test. Changes in wound size were compared using ANCOVA. The time to complete ulcer healing was compared using two sample t-tests. The median time to closure was estimated using the Kaplan–Meier method. A p-value <0.05 was considered significant. Data are given as mean±standard deviation.

Sample size was estimated to be sufficiently large to reliably detect the smallest possible difference in the primary outcome based on the results of several previous clinical trials that used bioengineered skin substitutes.[10] The power of the study was 80%, the level of significance was set to 5%, and drop-out rate was assumed to be 10%.

Table 4. Baseline clinical characteristics of the ulcers

		Treatment group (n=31)	Control group (n=32)
Ulcer size (cm^2)	Mean±SD	3.5±3.7	2.9±2.7
	Median	1.7	2.1
	Range (min–max)	1.0–15.6	1.0–14.3
Duration of ulcer (months)	Mean±SD	6.1±16.4	6.2±19.7
	Median	4.4	3.9
	Range (min–max)	1.5–84.0	1.5–108.0
Wagner grade	Grade I (%)	8 (26)	8 (25)
	Grade II (%)	23 (74)	24 (75)
University of Texas system	1A (%)	8 (26)	8 (25)
	2A (%)	12 (39)	11 (34)
	3A (%)	11 (35)	13 (41)
$TcpO_2$ (mmHg)		54.4±14.0	53.7±12.0

$TcpO_2$ transcutaneous oxygen pressure

Results

Patients

A total of 65 patients with DFUs were included in this clinical trial between December 2007 and April 2012. Of these 65 patients, 33 were assigned to the treatment group and 32 were assigned to the control group. Two patients in the treatment group were excluded before application of the autologous fibroblast-hyaluronic acid complex owing to contamination during cell culture. Therefore, an intention-to-treat analysis was conducted on the data available from the 63 patients who were treated (Fig 1). Baseline patient information of the two groups is shown in Tables 3–5.[14,15] No significant differences were observed with respect to any clinical characteristics between the two groups.

Fibroblasts could be cultured in sufficient numbers for seeding on the hyaluronic acid sheet in all treatment-group patients. About 2–3 weeks were required to obtain >5×10^6 fibroblasts on a monolayer culture.

No clinically meaningful changes occurred in the baseline clinical and laboratory parameters in any of the patients, including serum chemistry, haematology, urinalysis, or vital signs.

Wound healing

Complete wound healing occurred after 12 weeks in 26 patients (84%) in the treatment group and 11 patients (34%) in the control group (p<0.05, Pearson's chi-square test). In the treatment group, complete healing was achieved in 9 out of 11 patients with 3A ulcers compared to 10 out of 12 patients with 2A ulcers (p>0.05, Pearson's chi-square test) and 7 out of 8 patients with 1A ulcers (p>0.05, Pearson's chi-square test), but these differences did not reach statistical significance. In the control group, 4 out of 13 patients with 3A ulcers healed completely compared to 5 out of 11 patients with 2A ulcers (p>0.05 Pearson's, chi-square test) and 2 out of 8 patients with 1A ulcers (p>0.05, Pearson's chi-square test). No significant differences were noted. For the subgroup of patients with 3A ulcers, healing was observed in a significantly higher number of patients in the treatment group compared with

© 2014 MA Healthcare Ltd

RIGHTSLINK

ournal of Wound Care. Downloaded from magonlinelibrary.com by 130.179.016.201 on September 12, 2015. For personal use only. No other uses without permission. . All rights reserve

Table 5. Patient comorbidities

	Treatment group (n=31)	Control group (n=32)
Neuropathy	16	15
Nephropathy	14	12
Cardiac disorders	7	6
Metabolic disorders	5	3
Gastrointestinal disorders	4	3
Respiratory disorders	4	2

the control group, 9 out of 11 patients versus 4 out of 13 patients, respectively ($p<0.05$, Pearson's chi-square test).

The wound size was reduced by 3.0±2.6 (mean±SD) and 2.1±1.5cm^2 in the treatment and control groups, respectively ($p=0.06$ ANCOVA Covariate: baseline size).

The times required for complete healing were 36.4±17.6 and 48.4±13.1 days in the treatment and control groups, respectively ($p<0.05$ two sample t-test). The Kaplan–Meier median time to complete ulcer healing showed a trend to a shorter time in the treatment group compared with that in the control group. The median healing time was 35 days in the treatment group. However, the Kaplan–Meier median time to healing in the control group could not be estimated because more than 50% of subjects did not attain complete wound closure during the 12-week treatment period (Fig 3).

Adverse events

Adverse events occurred in two patients (7%) in the treatment group as two patients developed wound infections. Adverse events were reported in seven patients (22%) in the control group as follows: wound infection (n=5), lower limb fracture (n=1), and upper respiratory tract infection (n=1). However, none of these events were thought to be related to the study dressings, and no significant differences were noted between the two groups ($p=0.15$, Fisher's exact test).

Per-protocol analysis

The per-protocol analysis showed similar outcomes. Complete wound healing occurred in 89% (25/28 patients) of the treatment group and 44% (11/25 patients) of the control group patients ($p<0.05$, Pearson's chi-square test). The wound size was reduced by 2.7±2.2 and 2.4±1.5 cm^2 in the treatment and control groups, respectively ($p=0.07$, ANCOVA Covariate: baseline size). The times required for complete healing were 34.4±15.0 and 48.4±13.1 days in the treatment and control groups, respectively ($p<0.05$, two sample t-test; Fig 4–6).

Fig. 3. A Kaplan–Meier diagram showing the time to wound closure.

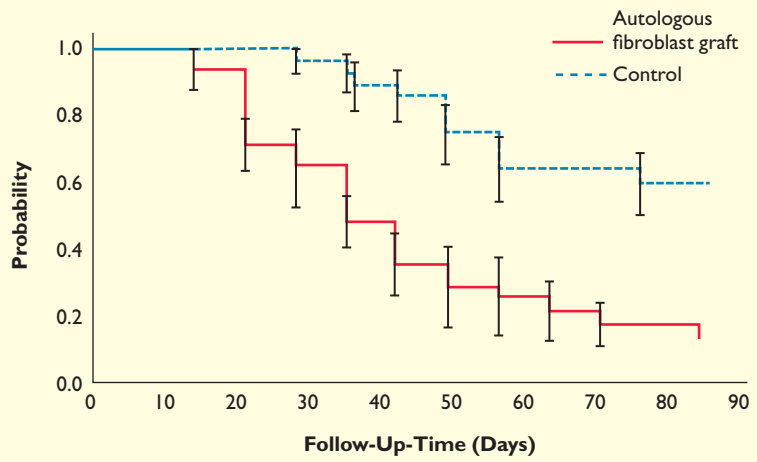

Discussion

In this randomised multicentre controlled clinical study, the use of autologous fibroblast-hyaluronic acid complex was compared with standard care in a larger study population than that used in a previous pilot study.[11] This treatment was superior to the control treatment with respect to complete wound healing rate and time for wound closure. In addition, the safety and tolerability results were excellent; no adverse events related to the study treatment occurred. Therefore, adding the autologous fibroblast-hyaluronic acid complex to a regimen of conventional DFU management, including debridement, infection control, and pressure offloading, may result in significant benefit to the patient.

The control treatment used polyurethane foam because the autologous fibroblast-hyaluronic acid complex was also covered with polyurethane foam as a secondary dressing. The endpoint of 12 weeks was determined by protocols of clinical trials using similar treatments (an epidermal growth factor product and an allogeneic keratinocyte product for diabetic ulcers)[3] registered with the Korean FDA. Plantar ulcers were excluded from our study because

Fig 4. A case in the fibroblast group. Initial view (a). The autologous fibroblasts grafting after 4 weeks (b) and 6 weeks, where the wound has healed completely (c).

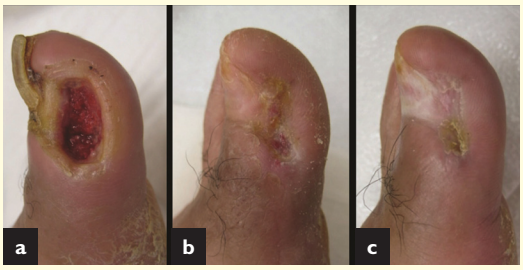

© 2014 MA Healthcare Ltd

RIGHTSLINK
Journal of Wound Care. Downloaded from magonlinelibrary.com by 130.179.016.201 on September 12, 2015. For personal use only. No other uses without permission. . All rights reserve

Fig 5. A case in the fibroblast group. Initial view (a). The autologous fibroblasts grafting after 1 week (b), 2 weeks (c), and 3 weeks, where the wound has healed completely (d)

previous work emphasised that correct off-loading of pressure to the foot is what is fundamental to the healing of plantar foot ulcerations, not the type of dressing.[10,13]

Diabetes influences the normal healing process at the molecular level. Several key factors contribute to impaired wound healing in patients with diabetes including: inadequate blood supply, infection, fibroblast senescence, inhibited keratinocyte migration, slower growth factor production, and an abnormal extracellular matrix (ECM).[16–19] Recently developed bioengineered products are based on the understanding of wound healing process and cell technology. Marston *et al*.[20] studied a cryopreserved human fibroblast-derived dermal substitute (Dermagraft; Shire Regenerative Medicine, Inc., San Diego, CA, USA) in 314 patients compared with conventional treatment. The results showed that 30% of the fibroblast-derived dermal substitute-treated group exhibited complete wound healing at 12 weeks as opposed to 18.3% in the control group ($p<0.05$). A recent multicentre randomised controlled trial[21] in non-infected neuropathic DFUs compared a bilayered living human skin equivalent (Apligraf; Organogenesis Inc., Canton, USA) with conventional therapy. After combining the data from this and a previous study, treatment with the living human skin equivalent was confirmed to result in a higher incidence of complete wound healing compared with that of placebo (55.2% verses 34.3%, $p<0.05$) and a shorter time to wound closure.

Fig 6. A case in the fibroblast group. Initial view (a). The autologous fibroblasts graft after 2 weeks (b), 4 weeks (c) and 5 weeks, where the wound has healed completely (d)

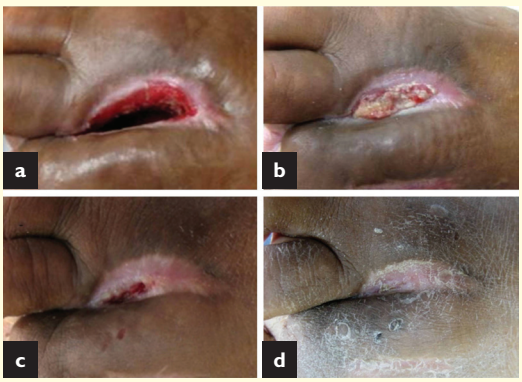

Although allogeneic fibroblasts may survive after transplantation, it is unclear whether they accelerate wound healing as effectively as autologous fibroblasts. Survival and proliferation of autologous fibroblasts seeded on dermal substitutes after transplantation have been reported previously.[22] In our study, complete ulcer healing was achieved at 12 weeks in 84% of the treatment group and 34% of the control group. These results indicate that the effectiveness of autologous fibroblast-hyaluronic acid complex is comparable with or may be even superior to that of other allogeneic skin equivalent products.

Hyaluronic acid is a natural polysaccharide and a major component of the ECM. It is an interesting biomaterial for wound-healing applications, as it promotes mesenchymal and epithelial cell migration and differentiation, thus enhancing collagen deposition and angiogenesis. Its degradation products may stimulate endothelial cell proliferation and migration, modulate the inflammatory process, and promote angiogenesis during different wound healing stages.[23]

Biomaterials employed in tissue engineering must serve as a scaffold for cells as well as contribute to wound healing. The hyaluronic acid matrix is one of the most promising of such biomaterials, as it allows cellular invasion by fibroblasts or endothelial cells and capillary growth. Once seeded on the matrix, fibroblasts adhere to the hyaluronic acid fibers, proliferate, and start to secrete ECM components. The presence of hyaluronic acid helps maintain well-hydrated tissue and may promote natural re-epithelialisation.

Several studies involving the use of autologous fibroblast-hyaluronic acid complex to the wound exist in the literature. A small pilot study with no control group[11] investigated the effect of the fibroblast complex for treating deep (Wagner grade 3), infected with *Staphylococcus aureus* or *Pseudomonas aeruginosa* diabetic foot or leg ulcers. Complete ulcer healing was observed in 7 of 10 patients participating in that study, whereas 2 patients had >70% wound healing after 20–28 weeks of treatment. Caravaggi *et al*.[10] evaluated the clinical efficacy and safety of bioengineered autologous dermal and epi-

© 2014 MA Healthcare Ltd

RIGHTSLINK
Journal of Wound Care. Downloaded from magonlinelibrary.com by 130.179.016.201 on September 12, 2015. For personal use only. No other uses without permission. . All rights reserve

dermal grafts in the management of patients with DFUs. They randomised 79 patients with plantar (n=42) or dorsal (n=37), chronic, non-infected foot ulcers (Wagner grade 1 or 2) to the treatment group with autologous tissue-engineered grafts (n=43) or a control group with non-adherent paraffin gauze (n=36). Complete wound healing was assessed within 11 weeks. Plantar ulcer healing rates were similar in both groups (55% and 50%, respectively). However, the dorsal ulcer healing rate was significantly higher in the treatment group (67%) than that in the control group (31%). The mean healing time in the dorsal treatment group was 63 days. Another clinical trial for the same product[13] evaluated healing over a 12-week period and obtained similar results. However, comparisons between the results of our study and previous studies are not relevant owing to the different protocols used.

Using the autologous fibroblast-hyaluronic acid complex to treat DFUs has the following advantages. The procedure is simple and minimally invasive, and it can be carried out in the outpatient clinic. The complex does not require the freeze-thaw process, which can impair fibroblast activities. Autologous fibroblast-seeded substitutes prevent wound contraction more efficiently compared with allogeneic fibroblast-seeded substitutes as well as promote the epithelialisation of wounds.[22] Moreover, contrary to allogeneic skin substitutes, which require repeated application, only a single application is enough for the autologous fibroblast grafts. Therefore, the entire process can be more cost-effective. In Korea, each application costs approximately £600 GBP. The 1A (University of Texas system) ulcers are usually expected to heal without the use of an expensive fibroblast dressing, while 2A or 3A ulcers, which are slower to heal, can be good candidates for fibroblast treatment.

It is important to emphasise that the autologous fibroblast sheet must be used along with other standard principles of DFU management, including debridement, infection control, pressure off-loading, and revascularisation. Without adhering to these important principles, adding an adjunctive modality is unlikely to result in improved healing rates. Patients with DFUs, who do not exhibit significant signs of wound healing despite good metabolic control, acceptable vascularity (transcutaneous oxygen pressure ≥30mmHg), adequate pressure offloading, and absence of infection may be good responders to autologous fibroblast sheets. The wound condition should be assessed for appropriateness before the grafts are applied. The wound bed should be healthy and clean with or without granulation tissue. There should not be any accompanying devitalised tissue, increased drainage, and increase in size or odour.

Limitations and future work

The present study has limitations. First, the wound evaluations were not performed in a blind fashion. The wound evaluators knew whether or not the patients were in the treatment group, which might have affected the results. However, this was unavoidable because the wound evaluators could recognise the remnant graft material on wound when the dressing was changed. Second, it takes several weeks to isolate and culture fibroblasts, and it is impossible to use autologous fibroblasts for emergency use. However, patients with diabetic ulcers usually do not need prompt coverage because of the time required to prepare and manage the ulcer bed before a grafting procedure. Therefore, the time (3–4 weeks) to culture autologous fibroblasts may not represent an obstacle for its use in this clinical setting. Third, further studies are needed to determine the number of transplanted fibroblasts required for effective wound healing, the fate of the transplanted autologous fresh fibroblasts, and the length of time for fibroblasts to be maintained after grafting and still retain viability. Fourth, studies are necessary to determine the optimal frequency for autologous fibroblast application. Repeated application might reduce the time to healing. Finally, there could have been a healthy selection bias, as the study population was likely to be healthier than the general patients with DFUs.

Conclusion

Improvement in the understanding of wound healing mechanisms and the field of bioengineering have led to the development of various advanced products, such as growth factors and living skin equivalents. The autologous fibroblast-hyaluronic acid complex may be safe and effective for treating non-ischemic dorsal DFUs without infection. ■

References

1. Papanas, N., Eleftheriadou, I., Tentolouris, N., Maltezos, E. Advances in the topical treatment of diabetic foot ulcers. Curr Diabetes Rev 2012; 8: 3, 209–218.
2. Marston, W.A., Hanft, J., Norwood, P., Pollak, R. The efficacy and safety of Dermagraft in improving the healing of chronic diabetic foot ulcers: results of a prospective randomized trial. Diabetes Care 2003; 26: 6, 1701–1705.
3. You, H.J., Han, S.K., Lee, J.W., Chang, H. Treatment of diabetic foot ulcers using cultured allogeneic keratinocytes--a pilot study. Wound Repair Regen 2012; 20: 4, 491–499.
4. De Loecker, W., Koptelov, V.A., Grischenko, V.I., De Loecker, P. Effects of cell concentration on viability and metabolic activity during cryopreservation. Cryobiology. 1998; 37: 2, 103–109.
5. Kano, M., Masuda, Y., Tominaga, T. et al. Collagen synthesis and collagenase activity of cryopreserved heart valves. J Thorac Cardiovasc Surg 2001; 122: 4, 706–711.
6. Liu, K., Yang, Y., Mansbridge, J. Comparison of the stress response to cryopreservation in monolayer and three-dimensional human fibroblast cultures: stress proteins, MAP kinases, and growth factor gene expression. Tissue Eng 2000; 6: 5, 539–554.

© 2014 MA Healthcare Ltd

RIGHTSLINK
Copyright Clearance Center
ournal of Wound Care. Downloaded from magonlinelibrary.com by 130.179.016.201 on September 12, 2015. For personal use only. No other uses without permission. . All rights reserve

7. Han, S.K., Kim, H.S., Kim, W.K. Efficacy and safety of fresh fibroblast allografts in the treatment of diabetic foot ulcers. Dermatol Surg 2009; 35: 9, 1342–1348.

8. Han, S.K., Choi, K.J., Kim, W.K. Clinical application of fresh fibroblast allografts for the treatment of diabetic foot ulcers: a pilot study. Plast Reconstr Surg 2004; 114: 7, 1783–1789.

9. Wong, T., McGrath, J.A., Navsaria, H. The role of fibroblasts in tissue engineering and regeneration. Br J Dermatol 2007; 156: 6, 1149–1155.

10. Caravaggi, C., De Giglio, R., Pritelli, C. et al. HYAFF 11-based autologous dermal and epidermal grafts in the treatment of noninfected diabetic plantar and dorsal foot ulcers: a prospective, multicenter, controlled, randomized clinical trial. Diabetes Care 2003; 26: 10, 2853–2859.

11. Cavallini, M. Autologous fibroblasts to treat deep and complicated leg ulcers in diabetic patients. Wound Repair Regen 2007; 15: 1, 35–38.

12. Uccioli, L. A clinical investigation on the characteristics and outcomes of treating chronic lower extremity wounds using the tissuetech autograft system. Int J Low Extrem Wounds. 2003; 2: 3, 140–151.

13. Uccioli, L., Giurato, L., Ruotolo, V. et al. Two-step autologous grafting using HYAFF scaffolds in treating difficult diabetic foot ulcers: results of a multicenter, randomized controlled clinical trial with long-term follow-up. Int J Low Extrem Wounds 2011; 10: 2, 80–85.

14. Wagner, F.W., Jr. The diabetic foot. Orthopedics 1987; 10: 1, 163–172.

15. Armstrong, D.G., Lavery, L.A., Harkless, L.B. Validation of a diabetic wound classification system. The contribution of depth, infection, and ischemia to risk of amputation. Diabetes Care 1998; 21: 5, 855–859.

16. Gary Sibbald, R., Woo, K.Y. The biology of chronic foot ulcers in persons with diabetes. Diabetes Metab Res Rev 2008; 24: Supple 1, S25–30.

17. Warriner, R.A., 3rd, Cardinal, M. Human fibroblast-derived dermal substitute: results from a treatment investigational device exemption (TIDE) study in diabetic foot ulcers. Adv Skin Wound Care 2011; 24: 7, 306–311.

18. Lev-Tov, H., Li, C.S., Dahle, S., Isseroff, R.R. Cellular versus acellular matrix devices in treatment of diabetic foot ulcers: study protocol for a comparative efficacy randomized controlled trial. Trials 2013; 14: 8.

19. Tsourdi, E., Barthel, A., Rietzsch, H. et al. Current aspects in the pathophysiology and treatment of chronic wounds in diabetes mellitus. BioMed Res Int 2013; 2013: 385641.

20. Marston, W.A. Dermagraft, a bioengineered human dermal equivalent for the treatment of chronic nonhealing diabetic foot ulcer. Expert Rev Med Devices 2004; 1: 1, 21–31.

21. Steinberg, J.S., Edmonds, M., Hurley, D.P., Jr., King, W.N. Confirmatory data from EU study supports Apligraf for the treatment of neuropathic diabetic foot ulcers. J Am Podiatr Med Assoc 2010; 100: 1, 73–77.

22. Morimoto, N., Saso, Y., Tomihata, K. et al. Viability and function of autologous and allogeneic fibroblasts seeded in dermal substitutes after implantation. J Surg Res 2005; 125: 1, 56–67.

23. Moura, L.I., Dias, A.M., Carvalho, E., de Sousa, H.C. Recent advances on the development of wound dressings for diabetic foot ulcer treatment-A review. Acta biomater 2013; 9: 7, 7093–7114.

© 2014 MA Healthcare Ltd

RIGHTSLINK
Journal of Wound Care. Downloaded from magonlinelibrary.com by 130.179.016.201 on September 12, 2015. For personal use only. No other uses without permission. . All rights reserve