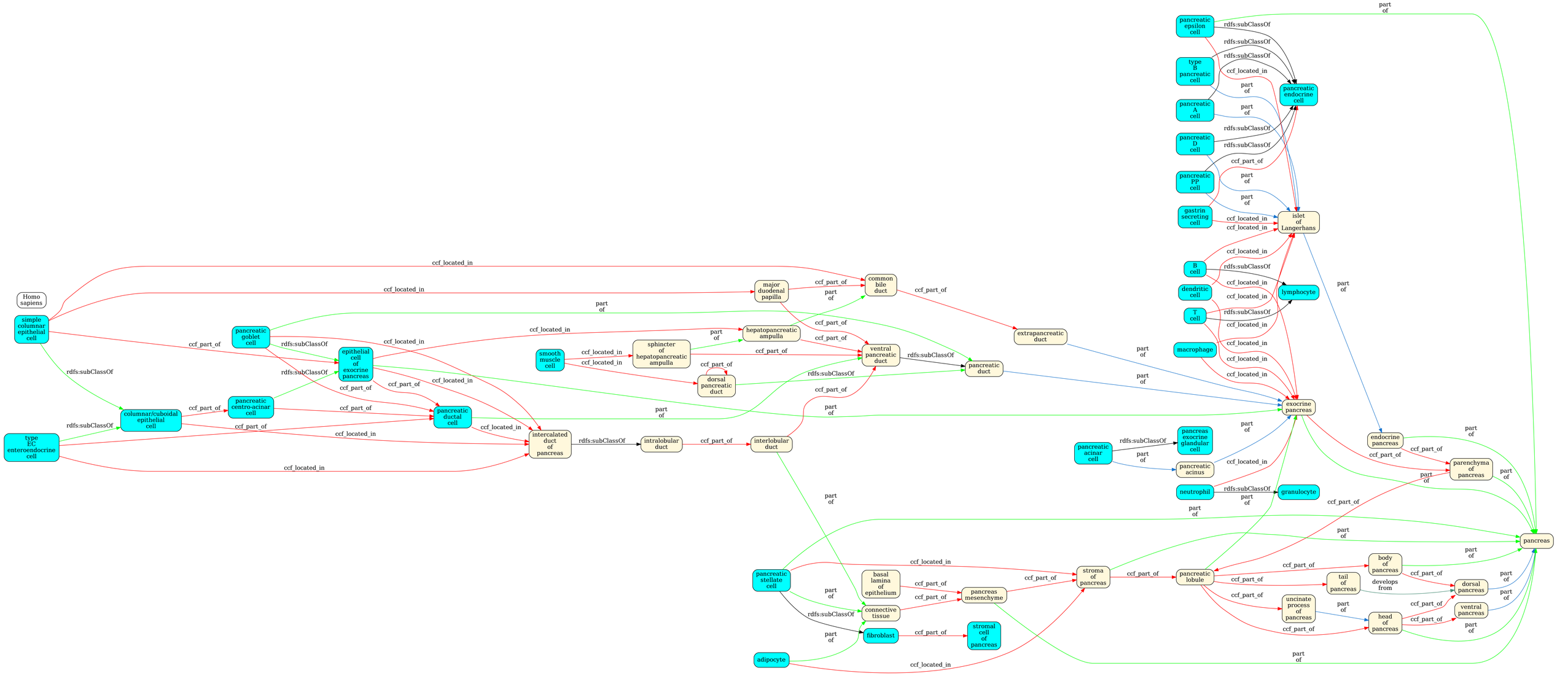
Homo sapiens
simple columnar epithelial cell
pancreatic goblet cell
epithelial cell of exocrine pancreas
columnar/cuboidal epithelial cell
pancreatic centro-acinar cell
pancreatic ductal cell
type EC enteroendocrine cell
intercalated duct of pancreas
intralobular duct
interlobular duct
smooth muscle cell
sphincter of hepatopancreatic ampulla
dorsal pancreatic duct
hepatopancreatic ampulla
major duodenal papilla
common bile duct
ventral pancreatic duct
pancreatic duct
extrapancreatic duct
exocrine pancreas
pancreatic epsilon cell
type B pancreatic cell
pancreatic A cell
pancreatic D cell
pancreatic PP cell
gastrin secreting cell
pancreatic endocrine cell
islet of Langerhans
B cell
dendritic cell
T cell
macrophage
lymphocyte
pancreatic acinar cell
pancreas exocrine glandular cell
pancreatic acinus
neutrophil
granulocyte
endocrine pancreas
parenchyma of pancreas
pancreas
pancreatic stellate cell
basal lamina of epithelium
connective tissue
fibroblast
stromal cell of pancreas
adipocyte
pancreas mesenchyme
stroma of pancreas
pancreatic lobule
body of pancreas
tail of pancreas
uncinate process of pancreas
head of pancreas
dorsal pancreas
ventral pancreas
ccf_located_in
ccf_part_of
rdfs:subClassOf
part of
develops from