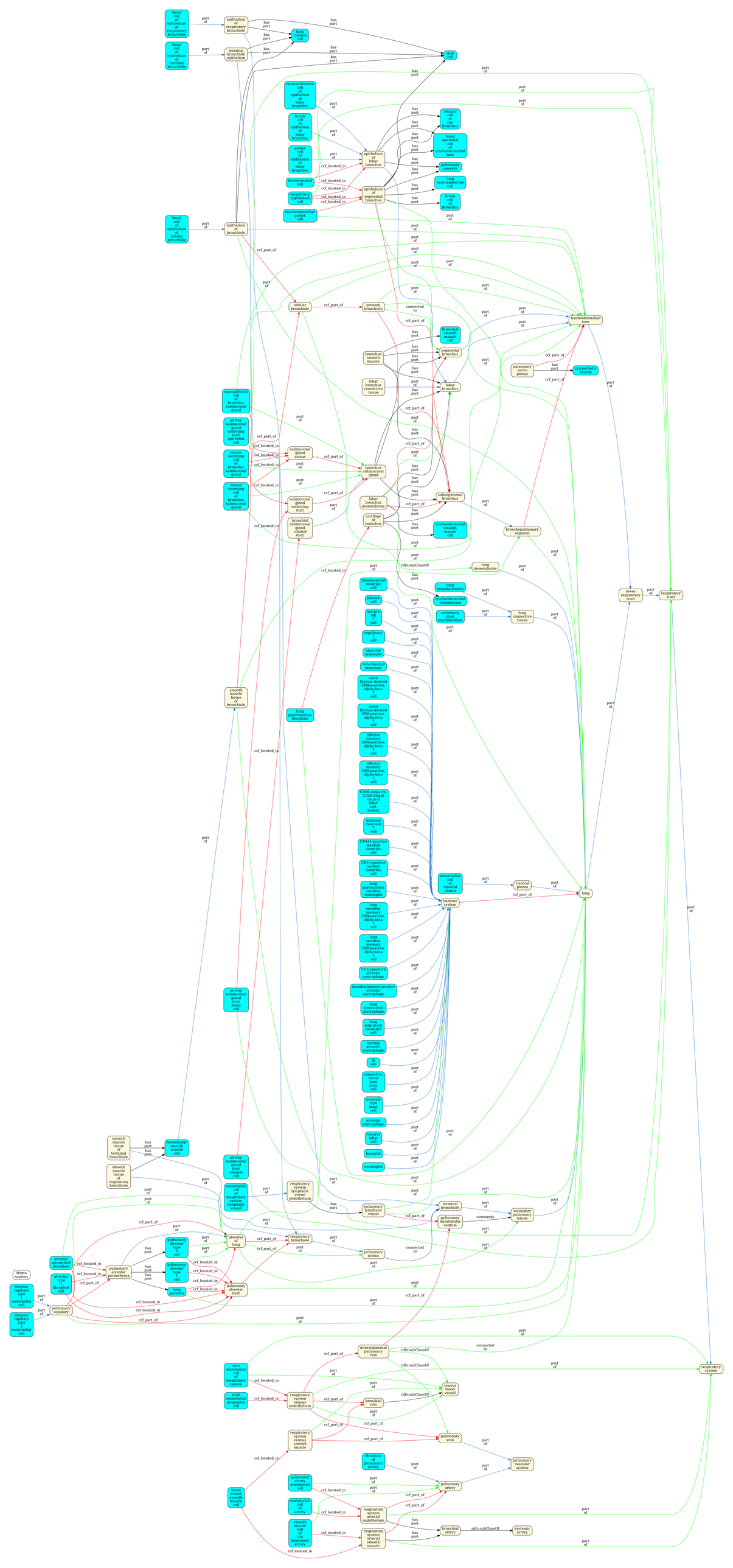
basal cell of epithelium of respiratory bronchiole
part of
epithelium of respiratory bronchiole
has part
lung ciliated cell
basal cell of epithelium of terminal bronchiole
terminal bronchiole epithelium
club cell
neuroendocrine cell of epithelium of lobar bronchus
brush cell of epithelium of lobar bronchus
goblet cell of epithelium of lobar bronchus
deuterosomal cell
respiratory suprabasal cell
tracheobronchial goblet cell
epithelium of lobar bronchus
epithelium of segmental bronchus
ciliated cell of the bronchus
basal epithelial cell of tracheobronchial tree
pulmonary monocyte
lung neuroendocrine cell
brush cell of the bronchus
ccf_located_in
basal cell of epithelium of lobular bronchiole
epithelium of bronchiole
ccf_part_of
lobular bronchiole
primary bronchiole
connected to
tracheobronchial tree
bronchial smooth muscle cell
bronchus smooth muscle
segmental bronchus
pulmonary nerve plexus
sympathetic neuron
lobar bronchus connective tissue
lobar bronchus
myoepithelial cell of bronchus submucosal gland
airway submucosal gland collecting duct epithelial cell
mucus secreting cell of bronchus submucosal gland
serous secreting cell of bronchus submucosal gland
submucosal gland acinus
bronchus submucosal gland
submucosal gland collecting duct
bronchial submucosal gland ciliated duct
lobar bronchus mesenchyme
subsegmental bronchus
cartilage of bronchus
tracheobronchial smooth muscle cell
bronchopulmonary segment
lung mesenchyme
lung megakaryocyte
tracheobronchial chondrocyte
secondary crest myofibroblast
lung connective tissue
lower respiratory tract
respiratory tract
plasmacytoid dendritic cell
plasma cell
mature NK T cell
regulatory T cell
classical monocyte
non-classical monocyte
naive thymus-derived CD4-positive, alpha-beta T cell
naive thymus-derived CD8-positive, alpha-beta T cell
effector memory CD4-positive, alpha-beta T cell
effector memory CD8-positive, alpha-beta T cell
CD16-negative, CD56-bright natural killer cell, human
mucosal invariant T cell
CD141-positive myeloid dendritic cell
CD1c-positive myeloid dendritic cell
lung parenchyma resident eosinophil
lung resident memory CD4-positive, alpha-beta T cell
lung resident memory CD8-positive, alpha-beta T cell
CCL3-positive alveolar macrophage
metallothionein-positive alveolar macrophage
lung interstitial macrophage
lung migratory dendritic cell
cycling alveolar macrophage
ILC cell
connective tissue mast cell
mucosal type mast cell
alveolar macrophage
natural killer cell
basophil
neutrophil
immune system
mesothelial cell of visceral pleura
visceral pleura
lung
smooth muscle tissue of bronchiole
lung bronchial fibroblast
airway submucosal gland basal cell
airway submucosal gland duct ciliated cell
endothelial cell of respiratory system lymphatic vessel
respiratory system lymphatic vessel endothelium
pulmonary lymphatic vessel
terminal bronchiole
pulmonary interlobular septum
secondary pulmonary lobule
surrounds
smooth muscle tissue of terminal bronchiole
smooth muscle tissue of respiratory bronchiole
bronchiolar smooth muscle cell
alveolus of lung
respiratory bronchiole
pulmonary acinus
pulmonary alveolar type 2 cell
pulmonary alveolar type 1 cell
lung pericyte
pulmonary alveolar duct
pulmonary alveolar parenchyma
alveolar adventitial fibroblast
alveolar type 1 fibroblast cell
Homo sapiens
alveolar capillary type 2 endothelial cell
alveolar capillary type 1 endothelial cell
pulmonary capillary
intersegmental pulmonary vein
rdfs:subClassOf
vein endothelial cell of respiratory system
adult endothelial progenitor cell
respiratory system venous endothelium
venous blood vessel
bronchial vein
respiratory system venous smooth muscle
pulmonary vein
pulmonary vascular system
fibroblast of pulmonary artery
pulmonary artery endothelial cell
pulmonary artery
blood vessel smooth muscle cell
endothelial cell of artery
respiratory system arterial endothelium
smooth muscle cell of the pulmonary artery
respiratory system arterial smooth muscle
bronchial artery
systemic artery
has part
part of
ccf_part_of
ccf_located_in