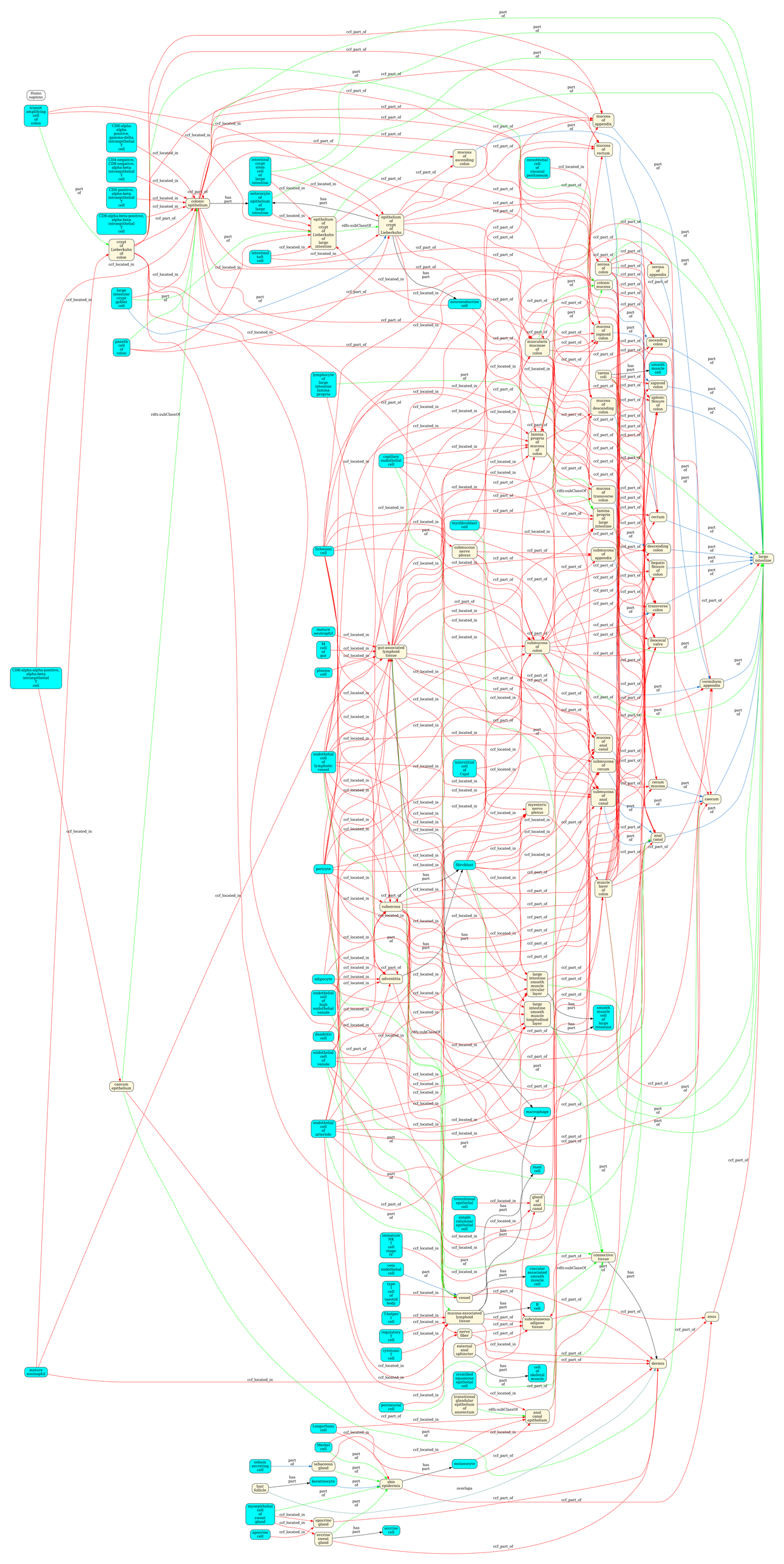
Homo sapiens
transit amplifying cell of colon
CD8-alpha positive, gamma-delta intraepithelial T cell
CD4-negative, CD8-negative, alpha-beta intraepithelial T cell
CD4-positive, alpha-beta intraepithelial T cell
CD8-alpha-beta-positive, alpha-beta intraepithelial T cell
CD8-alpha-alpha-positive, alpha-beta intraepithelial T cell
colonic epithelium
crypt of Lieberkuhn of colon
large intestine crypt goblet cell
paneth cell of colon
intestinal crypt stem cell of large intestine
enterocyte of epithelium of large intestine
epithelium of crypt of Lieberkuhn of large intestine
intestinal tuft cell
epithelium of crypt of Lieberkuhn
mucosa of ascending colon
mucosa of appendix
mucosa of rectum
mesothelial cell of visceral peritoneum
serosa of colon
serosa of appendix
colonic mucosa
neuroendocrine cell
mucosa of sigmoid colon
muscularis mucosae of colon
ascending colon
smooth muscle cell
taenia coli
sigmoid colon
splenic flexure of colon
mucosa of descending colon
lamina propria mucosa of colon
lymphocyte of large intestine lamina propria
capillary endothelial cell
mucosa of transverse colon
lamina propria large intestine
rectum
descending colon
hepatic flexure of colon
transverse colon
ileocecal valve
large intestine
vermiform appendix
cecum
anal canal
myofibroblast cell
Schwann cell
submucous nerve plexus
submucosa of appendix
mature neutrophil
M cell of gut
plasma cell
gut-associated lymphoid tissue
submucosa of colon
mucosa of anal canal
submucosa of cecum
submucosa of anal canal
cecum mucosa
endothelial cell of lymphatic vessel
interstitial cell of Cajal
myenteric nerve plexus
pericyte
fibroblast
muscle layer of colon
subserosa
adventitia
large intestine smooth muscle circular layer
large intestine smooth muscle longitudinal layer
smooth muscle of large intestine
adipocyte
endothelial cell of high endothelial venule
dendritic cell
endothelial cell of venule
cecum epithelium
macrophage
endothelial cell of arteriole
mast cell
transitional epithelial cell
gland of anal canal
simple columnar epithelial cell
immature NK cell stage IV
vein endothelial cell
connective tissue
vascular associated smooth muscle cell
type I cell of carotid body
vessel
mucosa-associated lymphoid tissue
B cell
T-helper cell
regulatory cell
cytotoxic cell
nerve fiber
subcutaneous adipose tissue
anus
external anal sphincter
dermis
stratified squamous epithelial cell
cell of skeletal muscle
perineurial cell
transitional glandular epithelium of anorectum
anal canal epithelium
mature eosinophil
Langerhans cell
Merkel cell
sebaceous secreting cell
sebaceous gland
melanocyte
keratinocyte
skin epidermis
hair follicle
myoepithelial cell of sweat gland
apocrine gland
apocrine cell
eccrine sweat gland
eccrine cell
overlaps
has part
part of
ccf_part_of
ccf_located_in
rdfs:subClassOf