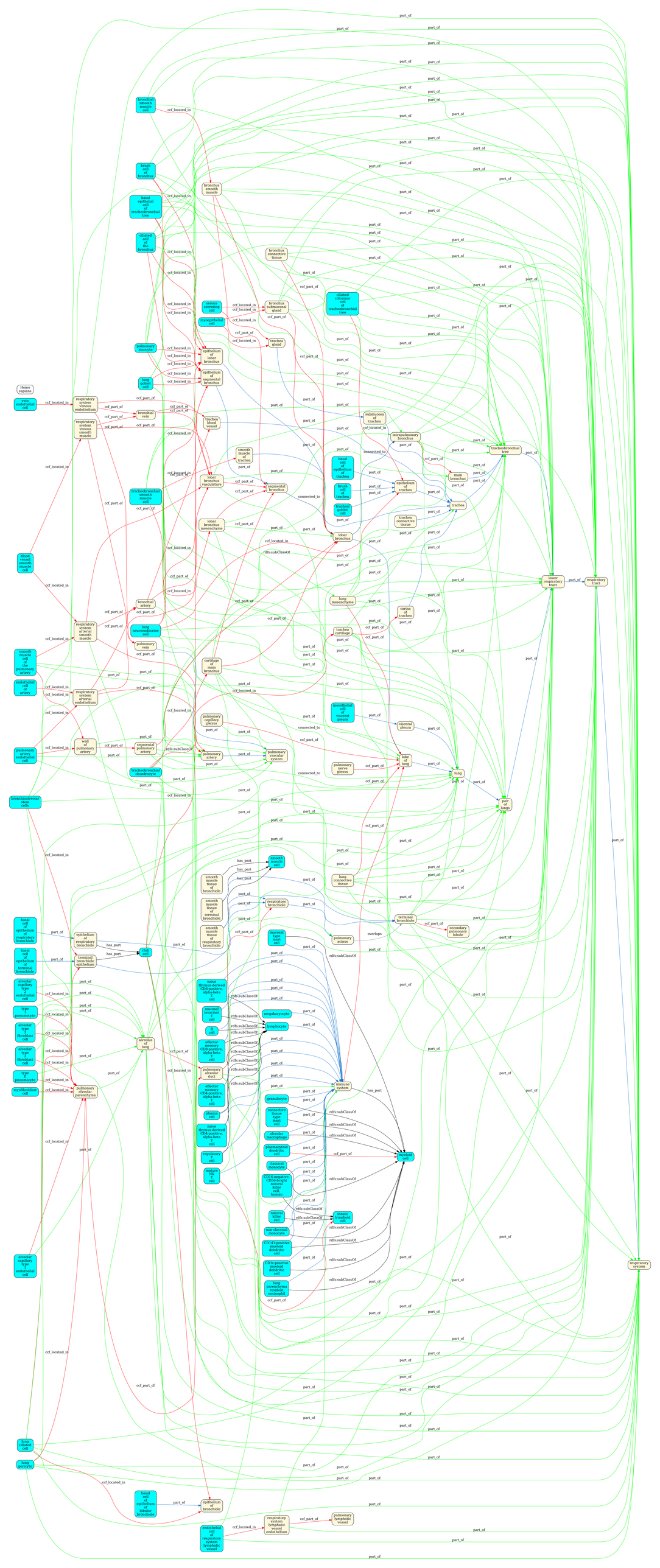
bronchial smooth muscle cell
brush cell of bronchus
basal epithelial cell of tracheobronchial tree
ciliated cell of the bronchus
bronchus smooth muscle
bronchus connective tissue
ciliated columnar cell of tracheobronchial tree
serous secreting cell
myoepithelial cell
bronchus submucosal gland
pulmonary smooth muscle
epithelium of lobar bronchus
trachea gland
lung goblet cell
epithelium of segmental bronchus
Homo sapiens
blood vessel endothelial cell
respiratory system venous endothelium
bronchial vein
respiratory system venous smooth muscle
trachea blood vessel
submucosa of trachea
intrapulmonary bronchus
tracheobronchial tree
smooth muscle of trachea
basal cell of epithelium of trachea
main bronchus
lobar bronchus vasculature
segmental bronchus
brush cell of trachea
epithelium of trachea
tracheobronchial smooth muscle cell
tracheal goblet cell
trachea
lobar bronchus mesenchyme
trachea connective tissue
lobar bronchus
blood vessel smooth muscle cell
lower respiratory tract
respiratory tract
lung mesenchyme
carina of trachea
bronchial artery
respiratory system arterial smooth muscle
lung neuroendocrine cell
pulmonary vein
trachea cartilage
smooth muscle cell of pulmonary artery
cartilage of main bronchus
endothelial cell of pulmonary artery
respiratory system arterial endothelium
mesothelial cell of visceral pleura
visceral pleura
pulmonary capillary endothelial cell
wall of pulmonary artery
segmental pulmonary artery
pulmonary artery
pulmonary vascular system
lobe of lung
pulmonary nerve plexus
lung
tracheobronchial chondrocyte
bronchioalveolar stem cells
zone of lungs
smooth muscle cell
smooth muscle tissue of bronchiole
lung connective tissue
smooth muscle tissue of terminal bronchiole
respiratory bronchiole
terminal bronchiole
secondary pulmonary lobule
smooth muscle tissue of respiratory bronchiole
mucosal type mast cell
pulmonary acinus
basal cell of epithelium of respiratory bronchiole
epithelium of respiratory bronchiole
club cell
basal cell of epithelium of terminal bronchiole
terminal bronchiole epithelium
alveolar capillary type 1 endothelial cell
naive thymus-derived CD8-positive alpha-beta cell
type I pneumocyte
mucosal invariant T cell
ileogaluty cycle
alveolar type 1 fibroblast cell
B cell
lymphocyte
alveolar type 2 fibroblast cell
alveolus of lung
effector memory CD8-positive, alpha-beta cell
pulmonary alveolar duct
type II pneumocyte
effector memory CD4-positive, alpha-beta cell
immune system
myofibroblast cell
pulmonary alveolar parenchyma
granulocyte
plasma cell
connective tissue type fibroblast cell
naive thymus-derived CD4-positive, alpha-beta cell
alveolar macrophage
myeloid cell
plasmacytoid dendritic cell
regulatory T cell
Classical monocyte
mature NK T cell
CD16-negative, CD56-bright natural killer cell, human
natural killer cell
innate lymphoid cell
non-classical monocyte
CD141-positive myeloid dendritic cell
CD1c-positive myeloid dendritic cell
lung parenchyma resident eosinophil
alveolar capillary type 1 endothelial cell
lung ciliated cell
lung pericyte
basal cell of epithelium of lobular bronchiole
epithelium of bronchiole
endothelial cell of respiratory system lymphatic vessel
respiratory system lymphatic vessel endothelium
pulmonary lymphatic vessel
ccf_located_in
ccf_part_of
part_of
has_part
connected_to
overlaps
rdfs:subClassOf