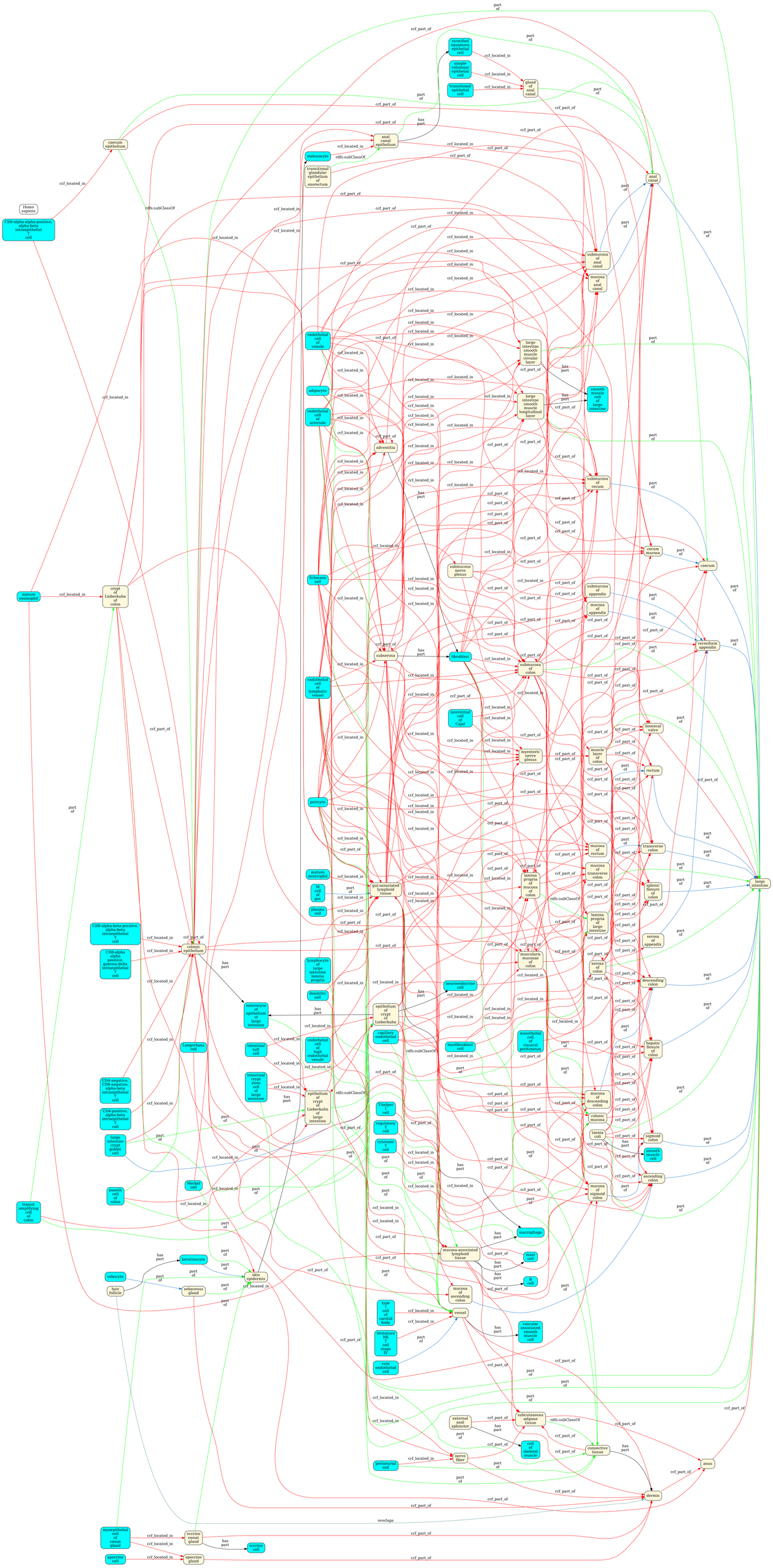
Homo sapiens
CD8-alpha-alpha-positive, alpha-beta intraepithelial T cell
caecum epithelium
transitional glandular epithelium of anorectum
melanocyte
anal canal epithelium
stratified squamous epithelial cell
simple columnar epithelial cell
transitional epithelial cell
gland of anal canal
anal canal
submucosa of anal canal
mucosa of anal canal
endothelial cell of venule
adipocyte
endothelial cell of arteriole
adventitia
large intestine smooth muscle circular layer
large intestine smooth muscle longitudinal layer
smooth muscle cell of large intestine
submucosa of caecum
caecum mucosa
caecum
submucosa of appendix
mucosa of appendix
vermiform appendix
mature eosinophil
crypt of Lieberkuhn of colon
Schwann cell
submucous nerve plexus
subserosa
fibroblast
submucosa of colon
endothelial cell of lymphatic vessel
interstitial cell of Cajal
myenteric nerve plexus
muscle layer of colon
ileocecal valve
rectum
pericyte
mature neutrophil
B cell of gut
plasma cell
gut-associated lymphoid tissue
lamina propria of mucosa of colon
mucosa of rectum
mucosa of transverse colon
transverse colon
splenic flexure of colon
large intestine
CD8-alpha-beta-positive, alpha-beta intraepithelial T cell
CD8-alpha-alpha-positive, gamma-delta intraepithelial T cell
colonic epithelium
lymphocyte of large intestine lamina propria
dendritic cell
enterocyte of epithelium of large intestine
intestinal tuft cell
Langerhans cell
lamina propria of large intestine
muscularis mucosae of colon
serosa of colon
serosa of appendix
descending colon
neuroendocrine cell
epithelium of crypt of Lieberkuhn
capillary endothelial cell
endothelial cell of high endothelial venule
myofibroblast cell
mesothelial cell of visceral peritoneum
hepatic flexure of colon
mucosa of descending colon
colonic mucosa
taenia coli
sigmoid colon
smooth muscle cell
ascending colon
mucosa of sigmoid colon
CD4-negative, CD8-negative, alpha-beta intraepithelial T cell
CD4-positive, alpha-beta intraepithelial T cell
large intestine crypt goblet cell
intestinal crypt stem cell of large intestine
epithelium of crypt of Lieberkuhn of large intestine
paneth cell of colon
transit amplifying cell of colon
Merkel cell
T-helper cell
regulatory T cell
cytotoxic T cell
macrophage
mucosa-associated lymphoid tissue
mast cell
B cell
mucosa of ascending colon
type I cell of carotid body
vessel
immature NK T cell stage IV
vein endothelial cell
vascular associated smooth muscle cell
keratinocyte
sebocyte
hair follicle
sebaceous gland
skin epidermis
external anal sphincter
subcutaneous adipose tissue
connective tissue
nerve fiber
perineurial cell
coil of skeletal muscle
anus
dermis
myoepithelial cell of sweat gland
eccrine sweat gland
eccrine cell
apocrine cell
apocrine gland
part of
ccf_part_of
ccf_located_in
has part
rdfs:subClassOf
overlaps