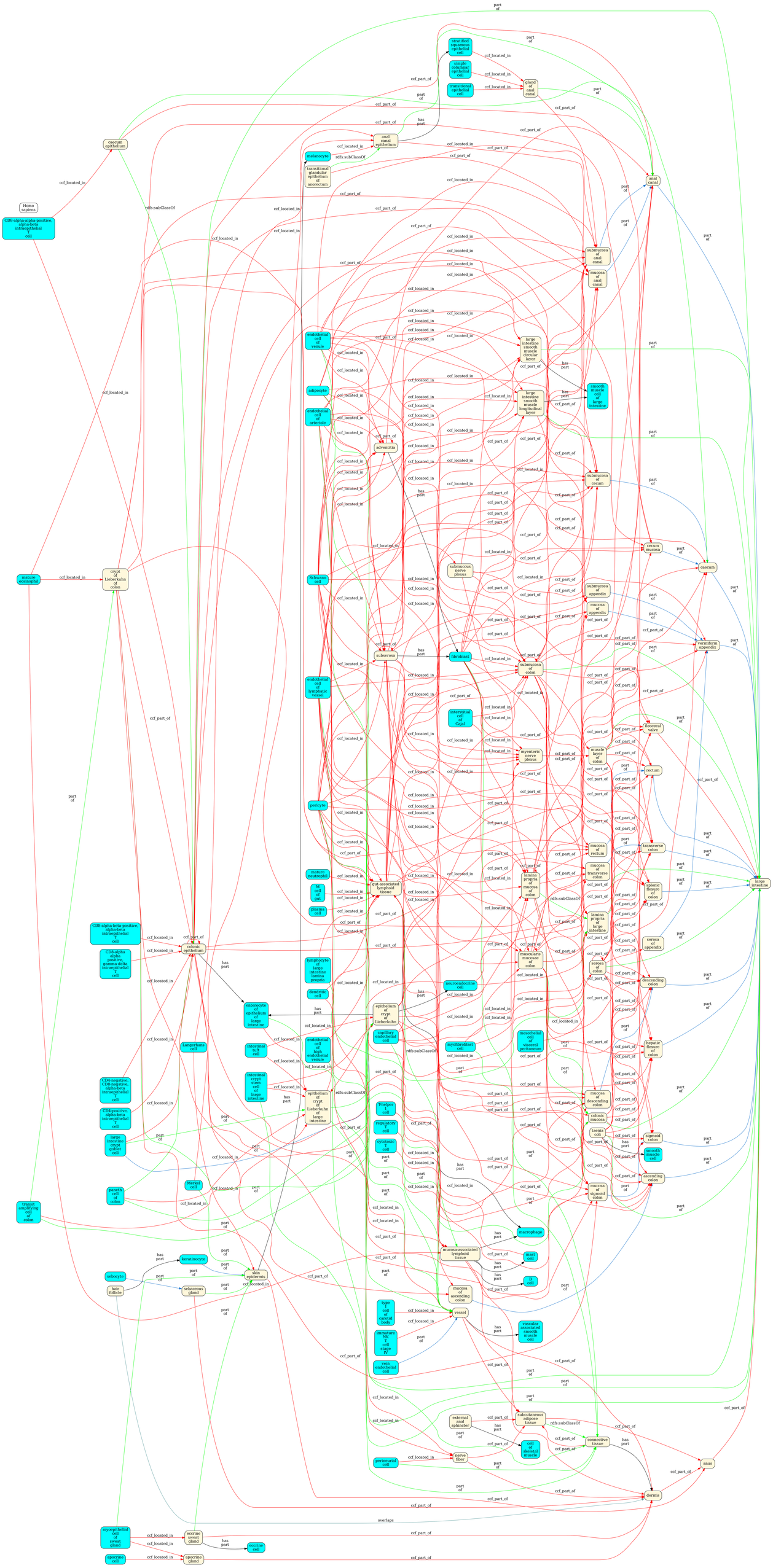
Homo sapiens
CD8-alpha-alpha-positive, alpha-beta intraepithelial T cell
caecum epithelium
anal canal epithelium
stratified squamous epithelial cell
simple columnar epithelial cell
transitional epithelial cell
gland of anal canal
melanocyte
transitional glandular epithelium of anorectum
anal canal
submucosa of anal canal
mucosa of anal canal
endothelial cell of venule
large intestine smooth muscle circular layer
adipocyte
large intestine smooth muscle longitudinal layer
smooth muscle cell of large intestine
endothelial cell of arteriole
adventitia
submucosa of cecum
mature eosinophil
crypt of Lieberkuhn of colon
Schwann cell
submucous nerve plexus
cecum mucosa
cecum
submucosa of appendix
mucosa of appendix
vermiform appendix
subserosa
fibroblast
submucosa of colon
endothelial cell of lymphatic vessel
interstitial cell of Cajal
ileocecal valve
myenteric nerve plexus
muscle layer of colon
rectum
pericyte
mucosa of rectum
transverse colon
mature neutrophil
gut-associated lymphoid tissue
lamina propria of mucosa of colon
splenic flexure of colon
large intestine
ILC3 cell of gut
plasma cell
lamina propria of large intestine
CD8-alpha-beta-positive, alpha-beta intraepithelial T cell
colonic epithelium
CD8-alpha-alpha-positive, gamma-delta intraepithelial T cell
muscularis mucosae of colon
serosa of colon
serosa of appendix
descending colon
lymphocyte of large intestine lamina propria
neuroendocrine cell
dendritic cell
enterocyte of epithelium of large intestine
epithelium of crypt of Lieberkuhn
capillary endothelial cell
myofibroblast cell
mesothelial cell of visceral peritoneum
hepatic flexure of colon
intestinal tuft cell
endothelial cell of high endothelial venule
Langerhans cell
CD4-negative, CD8-negative, alpha-beta intraepithelial T cell
intestinal crypt stem cell of large intestine
epithelium of crypt of Lieberkuhn of large intestine
mucosa of descending colon
CD4-positive, alpha-beta intraepithelial T cell
T-helper cell
colonic mucosa
taenia coli
sigmoid colon
large intestine crypt goblet cell
regulatory T cell
cytotoxic T cell
smooth muscle cell
ascending colon
Merkel cell
paneth cell of colon
mucosa of sigmoid colon
transit amplifying cell of colon
macrophage
keratinocyte
mucosa-associated lymphoid tissue
mast cell
skin epidermis
sebocyte
hair follicle
sebaceous gland
B cell
mucosa of ascending colon
type I cell of carotid body
vessel
vascular associated smooth muscle cell
immature NK T cell stage IV
vein endothelial cell
subcutaneous adipose tissue
external anal sphincter
connective tissue
cell of skeletal muscle
perineural cell
nerve fiber
anus
dermis
myoepithelial cell of sweat gland
eccrine sweat gland
eccrine cell
apocrine cell
apocrine gland
ccf_located_in
ccf_part_of
has part
part of
rdfs:subClassOf
overlaps