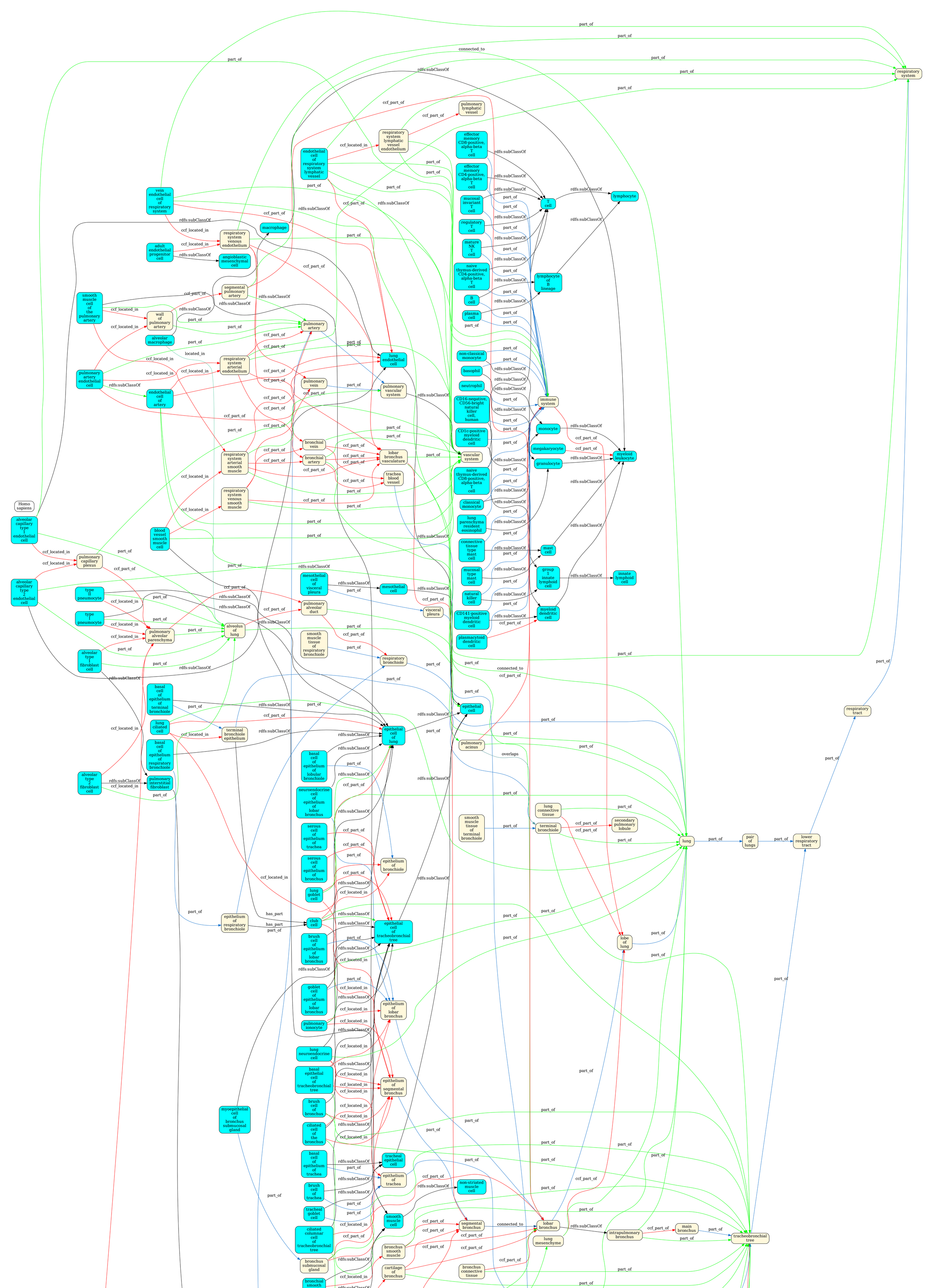
respiratory system
lymphocyte
myeloid leukocyte
innate lymphoid cell
respiratory tract
Homo sapiens
vein endothelial cell of respiratory system
adult endothelial progenitor cell
angioblastic mesenchymal cell
smooth muscle cell of the pulmonary artery
pulmonary artery endothelial cell
endothelial cell of artery
alveolar capillary type 1 endothelial cell
alveolar capillary type 2 endothelial cell
blood vessel smooth muscle cell
basal cell of epithelium of terminal bronchiole
basal cell of epithelium of respiratory bronchiole
lung ciliated cell
alveolar type 1 fibroblast cell
alveolar type 2 fibroblast cell
type II pneumocyte
type I pneumocyte
alveolar macrophage
myoepithelial cell of bronchus submucosal gland
lung pericyte
tracheobronchial chondrocyte
tracheobronchial smooth muscle cell
bronchial smooth muscle cell
macrophage
endothelial cell of respiratory system lymphatic vessel
respiratory system lymphatic vessel endothelium
respiratory system venous endothelium
respiratory system arterial endothelium
respiratory system arterial smooth muscle
respiratory system venous smooth muscle
pulmonary lymphatic vessel
segmental pulmonary artery
wall of pulmonary artery
pulmonary artery
pulmonary capillary plexus
pulmonary alveolar parenchyma
pulmonary alveolar duct
pulmonary vein
pulmonary vascular system
pulmonary interstitial fibroblast
pulmonary ionocyte
bronchial vein
bronchial artery
lobar bronchus vasculature
trachea blood vessel
vascular system
alveolus of lung
mesothelial cell of visceral pleura
mesothelial cell
visceral pleura
smooth muscle tissue of respiratory bronchiole
respiratory bronchiole
terminal bronchiole epithelium
epithelium of respiratory bronchiole
basal cell of epithelium of lobular bronchiole
neuroendocrine cell of epithelium of lobar bronchus
serous cell of epithelium of trachea
serous cell of epithelium of bronchus
lung goblet cell
epithelium of bronchiole
epithelial cell of tracheobronchial tree
club cell
brush cell of epithelium of lobar bronchus
goblet cell of epithelium of lobar bronchus
lung neuroendocrine cell
basal epithelial cell of tracheobronchial tree
brush cell of bronchus
ciliated cell of the bronchus
epithelium of segmental bronchus
basal cell of epithelium of trachea
brush cell of trachea
tracheal goblet cell
tracheal epithelial cell
epithelium of trachea
ciliated columnar cell of tracheobronchial tree
bronchus submucosal gland
smooth muscle cell
bronchus smooth muscle
cartilage of bronchus
epithelial cell of lung
epithelial cell
pulmonary acinus
effector memory CD8-positive, alpha-beta T cell
effector memory CD4-positive, alpha-beta T cell
mucosal invariant T cell
regulatory T cell
mature NK T cell
naive thymus-derived CD4-positive, alpha-beta T cell
B cell
plasma cell
non-classical monocyte
basophil
neutrophil
CD16-negative, CD56-bright natural killer cell, human
CD1c-positive myeloid dendritic cell
naive thymus-derived CD8-positive, alpha-beta T cell
classical monocyte
lung parenchyma resident eosinophil
connective tissue type mast cell
mucosal type mast cell
natural killer cell
CD141-positive myeloid dendritic cell
plasmacytoid dendritic cell
T cell
lymphocyte of B lineage
immune system
monocyte
megakaryocyte
granulocyte
mast cell
group 1 innate lymphoid cell
myeloid dendritic cell
lung connective tissue
smooth muscle tissue of terminal bronchiole
terminal bronchiole
secondary pulmonary lobule
lung
pair of lungs
lower respiratory tract
lobe of lung
intrapulmonary bronchus
main bronchus
tracheobronchial tree
segmental bronchus
lobar bronchus
lung mesenchyme
bronchus connective tissue
non-striated muscle cell
smooth muscle cell of trachea
submucosa of trachea
trachea gland
trachea elastic tissue
trachea non-cartilage connective tissue
trachea connective tissue
trachea
lobar bronchus mesenchyme
tracheal smooth muscle cell
trachealis
carina of trachea
trachea cartilage
stromal cell
fibroblast of pulmonary artery
fibroblast of lung
connective tissue cell
pulmonary nerve plexus
part_of
ccf_part_of
ccf_located_in
rdfs:subClassOf
connected_to
has_part
overlaps
located_in