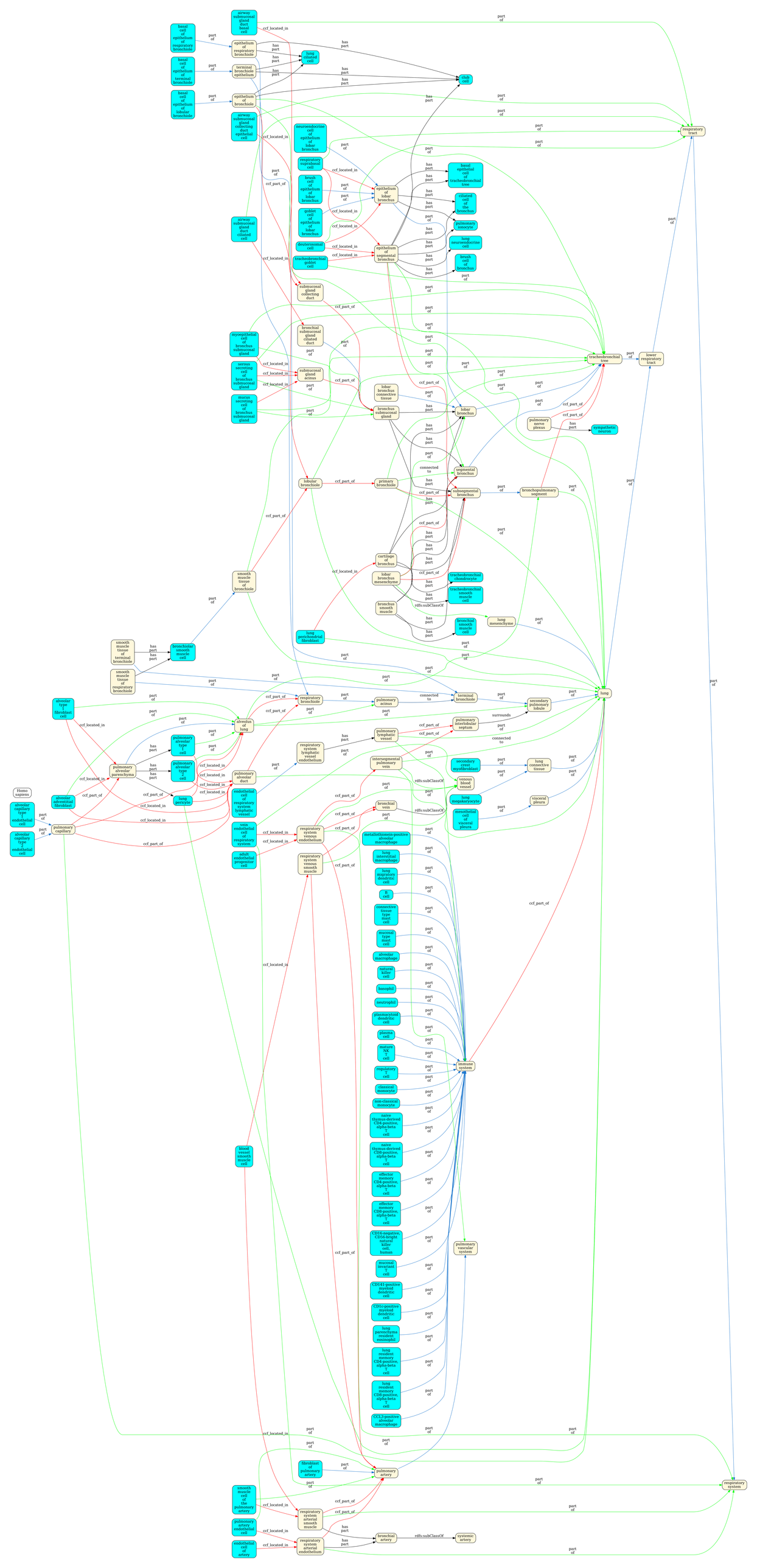
airway submucosal gland duct basal cell
basal cell of epithelium of respiratory bronchiole
epithelium of respiratory bronchiole
basal cell of epithelium of terminal bronchiole
terminal bronchiole epithelium
basal cell of epithelium of lobular bronchiole
epithelium of bronchiole
airway submucosal gland collecting duct epithelial cell
airway submucosal gland duct ciliated cell
myoepithelial cell of bronchus submucosal gland
serous secreting cell of bronchus submucosal gland
mucus secreting cell of bronchus submucosal gland
smooth muscle tissue of terminal bronchiole
smooth muscle tissue of respiratory bronchiole
bronchiolar smooth muscle cell
smooth muscle tissue of bronchiole
alveolar type I fibroblast cell
alveolar capillary type I endothelial cell
alveolar capillary type 2 endothelial cell
Homo sapiens
alveolar adventitial fibroblast
pulmonary capillary
pulmonary alveolar parenchyma
pulmonary alveolar type I cell
pulmonary alveolar type II cell
lung pericyte
alveolus of lung
respiratory bronchiole
pulmonary alveolar duct
endothelial cell of respiratory system lymphatic vessel
vein endothelial cell of respiratory system
adult endothelial progenitor cell
blood vessel smooth muscle cell
lung ciliated cell
club cell
neuroendocrine cell of epithelium of lobar bronchus
respiratory suprabasal cell
brush cell of epithelium of lobar bronchus
goblet cell of epithelium of lobar bronchus
deuterosomal cell
tracheobronchial goblet cell
submucosal gland collecting duct
bronchial submucosal gland ciliated duct
submucosal gland acinus
mucus secreting cell of bronchus submucosal gland
lobular bronchiole
respiratory system lymphatic vessel endothelium
respiratory system venous endothelium
respiratory system venous smooth muscle
respiratory system arterial smooth muscle
respiratory system arterial endothelium
smooth muscle tissue of the pulmonary artery
pulmonary artery endothelial cell
endothelial cell of artery
fibroblast of pulmonary artery
pulmonary artery
epithelium of lobar bronchus
epithelium of segmental bronchus
basal epithelial cell of tracheobronchial tree
ciliated cell of the bronchus
pulmonary neurocyte
lung neuroendocrine cell
brush cell of bronchus
lobar bronchus connective tissue
bronchus submucosal gland
lobar bronchus
primary bronchus
segmental bronchus
subsegmental bronchus
cartilage of bronchus
lobar bronchus mesenchyme
bronchus smooth muscle
tracheobronchial chondrocyte
tracheobronchial smooth muscle cell
bronchial smooth muscle cell
lung mesenchyme
pulmonary nerve plexus
sympathetic neuron
tracheobronchial tree
lower respiratory tract
respiratory tract
bronchopulmonary segment
lung
terminal bronchiole
pulmonary acinus
secondary pulmonary lobule
pulmonary interlobular septum
pulmonary lymphatic vessel
intersegmental pulmonary vein
bronchial vein
venous blood vessel
lung megakaryocyte
mesothelial cell of visceral pleura
visceral pleura
secondary crest myofibroblast
lung connective tissue
immune system
metallothionein-positive alveolar macrophage
lung interstitial macrophage
lung migratory dendritic cell
B cell
connective tissue type mast cell
mucosal type mast cell
alveolar macrophage
natural killer cell
basophil
neutrophil
plasmacytoid dendritic cell
plasma cell
mature NK T cell
regulatory T cell
classical monocyte
non-classical monocyte
naive thymus-derived CD4-positive, alpha-beta T cell
naive thymus-derived CD8-positive, alpha-beta T cell
effector memory CD4-positive, alpha-beta T cell
effector memory CD8-positive, alpha-beta T cell
CD16-negative, CD56-bright natural killer cell, human
mucosal invariant T cell
CD141-positive myeloid dendritic cell
CD1c-positive myeloid dendritic cell
lung parenchyma resident eosinophil
lung resident memory CD4-positive, alpha-beta T cell
lung resident memory CD8-positive, alpha-beta T cell
CCL3-positive alveolar macrophage
pulmonary vascular system
systemic artery
respiratory system
part of
has part
ccf_located_in
ccf_part_of
connected to
surrounds
rdfs:subClassOf