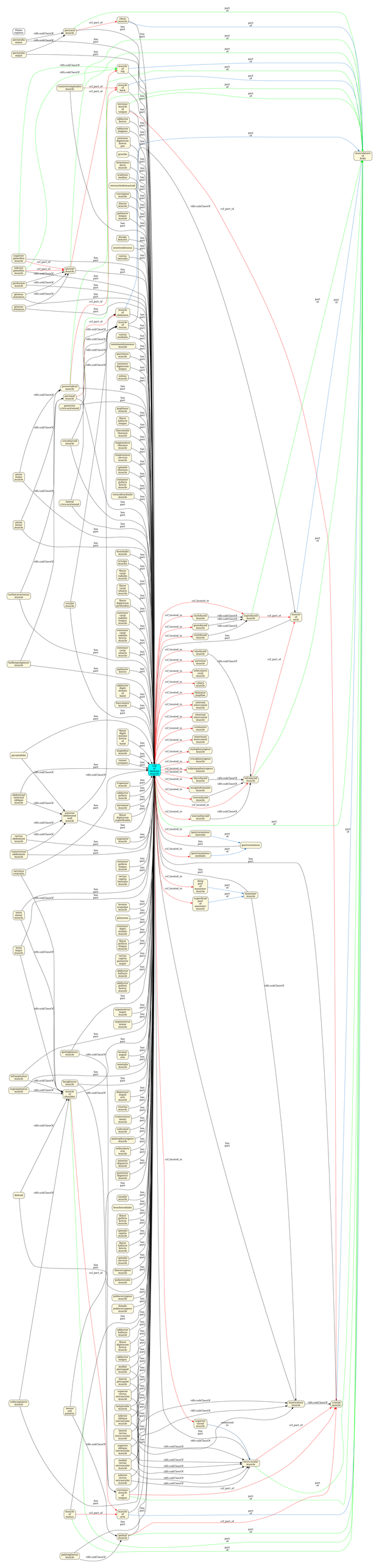
chest muscle
pectoral muscle
thoracoscapular muscle
muscle of neck
muscle of back
transversospinalis muscle
sternocleidomastoid
coracoepaneus muscle
flexor muscle
palmaris brevis muscle
biceps brachii
semitendinosus
rectus femoris
gluteus maximus
gluteus minimus
muscle of arm
muscle of forearm
rectus femoris
semimembranosus muscle
pectineus muscle
extensor longus
soleus muscle
posterior crico-arytenoid
arytenoid muscle
circumflexed muscle
longissimus thoracis muscle
iliocostalis thoracis muscle
extensor brevis muscle
coracobrachialis muscle
internal crico-arytenoid
brachialis muscle
biceps brachii
flexor carpi ulnaris muscle
flexor carpi radialis muscle
flexor digitorum profundus
extensor carpi radialis longus muscle
extensor carpi radialis brevis muscle
extensor digitorum muscle
palmaris brevis
abductor digiti minimi hand
lumbricator muscle
flexor digiti minimi brevis hand
supinator muscle
tensor tympani
tegmen muscle
abductor muscle
accessory muscle
flexor superficialis
spinalis muscle
extensor longus muscle
rectus capitis anterior
levator palpebrae muscle
platysma
extensor digiti minimi muscle
flexor pollicis longus muscle
rectus posterior major
abductor hallucis muscle
abductor pollicis longus muscle
supraspinatus major muscle
supraspinatus minor muscle
levator anguli oris
mentalis muscle
depressor anguli oris muscle
risorius muscle
transversus muscle
nasalis muscle
palatopharyngeus muscle
orbicularis oris muscle
anterior muscle
posterior muscle
nasalis muscle
brachioradialis
flexor pollicis brevis muscle
spinalis capitis muscle
flexor hallucis brevis muscle
spinalis cervicis muscle
flexoscapulo muscle
pubococcygeus muscle
pubococcygeus muscle
female pubococcygeus muscle
abductor muscle
flexor digitorum brevis muscle
abductor longus
rectal pterygoid muscle
lateral pterygoid muscle
superior muscle
temporalis muscle
inferior muscle
lateral rectus muscle
superior oblique extraocular muscle
rectal rectus muscle
inferior muscle
extraocular muscle
extraocular muscle of tongue
muscle of mouth
lateral muscle
palatoglossus muscle
muscle of body
mylohyoid muscle
omohyoid muscle
stylohyoid muscle
omohyoid muscle
anterior muscle
orbicularis oculi muscle
ciliary muscle
dilator pupillae
internal intercostal muscle
external intercostal muscle
cremaster muscle
innermost intercostal muscle
cricopharyngeus muscle
thyrohyoid muscle
occipitofrontalis muscle
sternothyroid muscle
sternohyoid muscle
gastrocnemius medialis
deep part masseter muscle
superficial part masseter muscle
masseter muscle
gastrocnemius
masseter muscle
mandibular muscle
mandibular muscle
mandibular