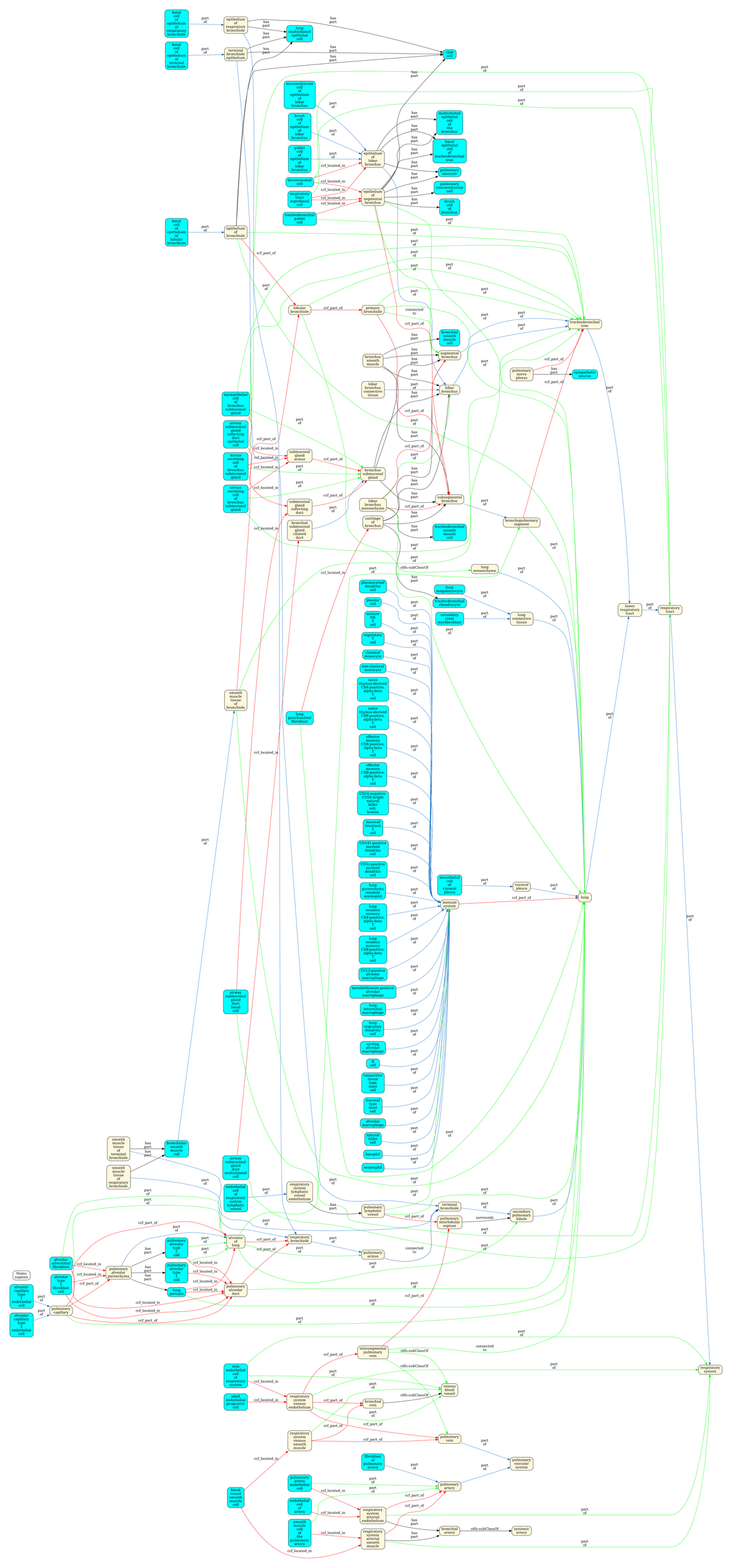
basal cell of epithelium of respiratory bronchiole
epithelium of respiratory bronchiole
lung multiciliated epithelial cell
basal cell of epithelium of terminal bronchiole
terminal bronchiole epithelium
club cell
neuroendocrine cell of epithelium of lobar bronchus
brush cell of epithelium of lobar bronchus
goblet cell of epithelium of lobar bronchus
deuterosomal cell
respiratory tract suprabasal cell
tracheobronchial goblet cell
epithelium of lobar bronchus
epithelium of segmental bronchus
multiciliated epithelial cell of the bronchus
basal epithelial cell of tracheobronchial tree
pulmonary monocyte
pulmonary neuroendocrine cell
brush cell of bronchus
basal cell of epithelium of lobular bronchiole
epithelium of bronchiole
lobular bronchiole
primary bronchiole
tracheobronchial tree
bronchial smooth muscle cell
bronchus smooth muscle
segmental bronchus
pulmonary nerve plexus
sympathetic neuron
lobar bronchus
lobar bronchus connective tissue
myoepithelial cell of bronchus submucosal gland
airway submucosal gland collecting duct epithelial cell
mucus secreting cell of bronchus submucosal gland
serous secreting cell of bronchus submucosal gland
submucosal gland acinus
bronchus submucosal gland
submucosal gland collecting duct
bronchial submucosal gland ciliated duct
lobar bronchus mesenchyme
cartilage of bronchus
subsegmental bronchus
tracheobronchial smooth muscle cell
bronchopulmonary segment
lung mesenchyme
plasmacytoid dendritic cell
plasma cell
mature T cell
regulatory T cell
classical monocyte
non-classical monocyte
naive thymus-derived CD4-positive, alpha-beta T cell
naive thymus-derived CD8-positive, alpha-beta T cell
effector memory CD4-positive, alpha-beta T cell
effector memory CD8-positive, alpha-beta T cell
CD16-negative, CD56-bright natural killer cell, human
mucosal invariant T cell
CD141-positive myeloid dendritic cell
CD1c-positive myeloid dendritic cell
lung parenchyma resident eosinophil
lung resident memory CD4-positive, alpha-beta T cell
lung resident memory CD8-positive, alpha-beta T cell
SIGLEC5-positive alveolar macrophage
metallothionein-positive alveolar macrophage
lung interstitial macrophage
lung mucosal dendritic cell
cycling alveolar macrophage
B cell
connective tissue type mast cell
mucosal type mast cell
alveolar macrophage
natural killer cell
basophil
neutrophil
lung megakaryocyte
tracheobronchial chondrocyte
secondary crest myofibroblast
lung connective tissue
lower respiratory tract
respiratory tract
smooth muscle tissue of bronchiole
lung perichondrial fibroblast
airway submucosal gland duct basal cell
mesothelial cell of visceral pleura
visceral pleura
lung
immune system
smooth muscle tissue of terminal bronchiole
bronchiolar smooth muscle cell
smooth muscle tissue of respiratory bronchiole
airway submucosal gland duct multiciliated cell
endothelial cell of respiratory system lymphatic vessel
respiratory system lymphatic vessel endothelium
pulmonary lymphatic vessel
terminal bronchiole
pulmonary interlobular septum
secondary pulmonary lobule
alveolus of lung
respiratory bronchiole
pulmonary alveolar type I cell
pulmonary alveolar type II cell
lung pericyte
pulmonary alveolar parenchyma
pulmonary alveolar duct
pulmonary acinus
alveolar adventitial fibroblast
alveolar type I fibroblast cell
Homo sapiens
alveolar capillary type I endothelial cell
alveolar capillary type II endothelial cell
pulmonary capillary
intersegmental pulmonary vein
vein endothelial cell of respiratory system
adult endothelial progenitor cell
respiratory system venous endothelium
bronchial vein
venous blood vessel
respiratory system venous smooth muscle
pulmonary vein
fibroblast of pulmonary artery
pulmonary vascular system
pulmonary artery endothelial cell
pulmonary artery
blood vessel smooth muscle cell
endothelial cell of artery
respiratory system arterial endothelium
smooth muscle cell of the pulmonary artery
respiratory system arterial smooth muscle
bronchial artery
systemic artery
respiratory system
part of
has part
ccf_part_of
ccf_located_in
rdfs:subClassOf
connected to
surrounds