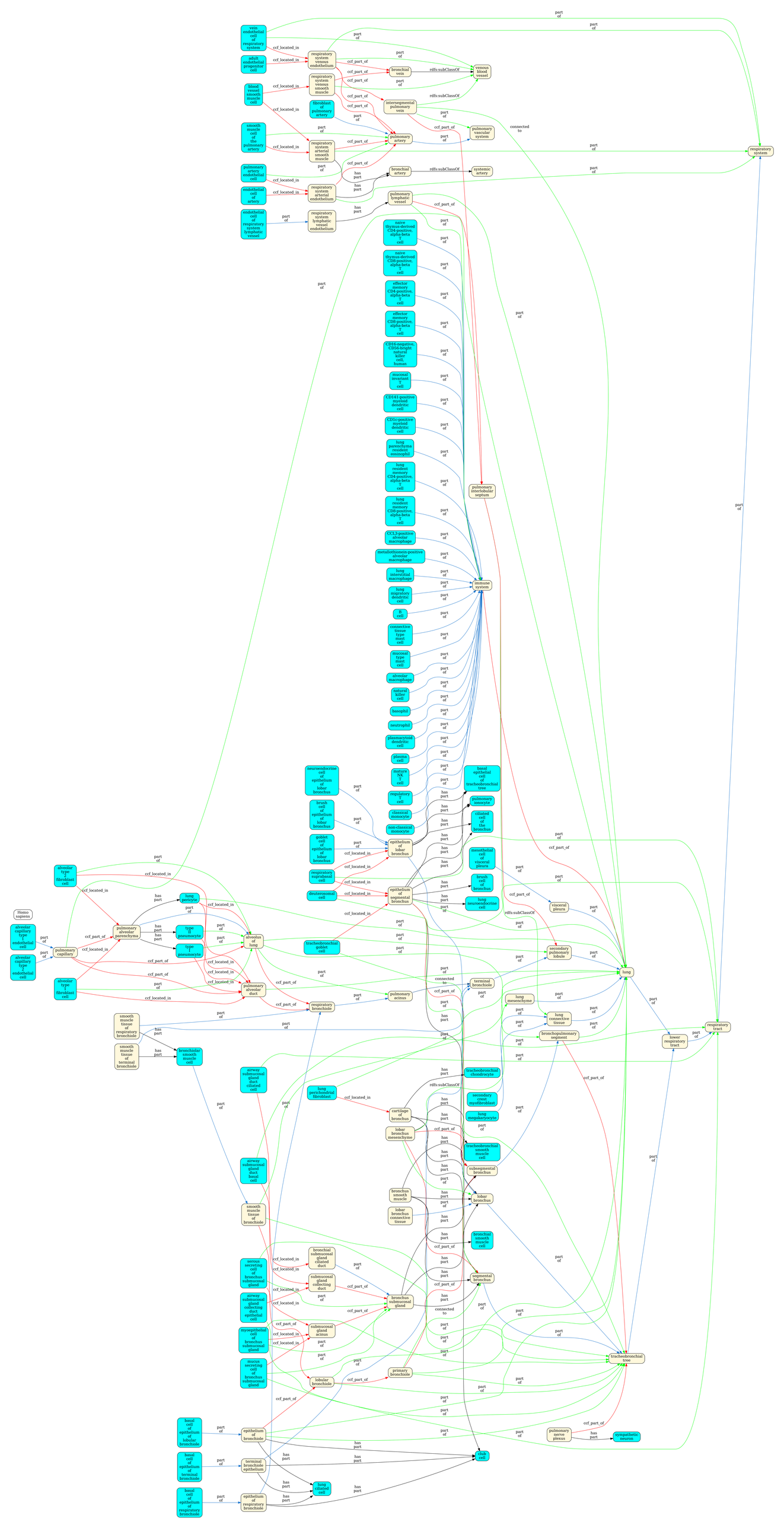
vein endothelial cell of respiratory system
adult endothelial progenitor cell
blood vessel smooth muscle cell
smooth muscle cell of the pulmonary artery
pulmonary artery endothelial cell
endothelial cell of artery
endothelial cell of respiratory system lymphatic vessel
respiratory system venous endothelium
respiratory system venous smooth muscle
fibroblast of pulmonary artery
respiratory system arterial smooth muscle
respiratory system arterial endothelium
respiratory system lymphatic vessel endothelium
bronchial vein
intersegmental pulmonary vein
pulmonary artery
bronchial artery
pulmonary lymphatic vessel
venous blood vessel
pulmonary vascular system
systemic artery
respiratory system
pulmonary interlobular septum
naive thymus-derived CD4-positive, alpha-beta T cell
naive thymus-derived CD8-positive, alpha-beta T cell
effector memory CD4-positive, alpha-beta T cell
effector memory CD8-positive, alpha-beta T cell
CD16-negative, CD56-bright natural killer cell, human
mucosal invariant T cell
CD141-positive myeloid dendritic cell
CD1c-positive myeloid dendritic cell
lung parenchyma resident eosinophil
lung resident memory CD4-positive, alpha-beta T cell
lung resident memory CD8-positive, alpha-beta T cell
CCL3-positive alveolar macrophage
metallothionein-positive alveolar macrophage
lung interstitial macrophage
lung migratory dendritic cell
B cell
connective tissue type mast cell
mucosal type mast cell
alveolar macrophage
natural killer cell
basophil
neutrophil
plasmacytoid dendritic cell
plasma cell
mature NK T cell
regulatory T cell
classical monocyte
non-classical monocyte
immune system
neuroendocrine cell of epithelium of lobar bronchus
brush cell of epithelium of lobar bronchus
goblet cell of epithelium of lobar bronchus
respiratory suprabasal cell
deuterosomal cell
epithelium of lobar bronchus
epithelium of segmental bronchus
basal epithelial cell of tracheobronchial tree
pulmonary ionocyte
ciliated cell of the bronchus
mesothelial cell of visceral pleura
brush cell of bronchus
lung neuroendocrine cell
tracheobronchial goblet cell
visceral pleura
secondary pulmonary lobule
lung
alveolar type fibroblast cell
pulmonary alveolar parenchyma
lung pericyte
type II pneumocyte
type I pneumocyte
alveolus of lung
pulmonary alveolar duct
Homo sapiens
alveolar capillary type endothelial cell
alveolar capillary type 2 endothelial cell
pulmonary capillary
terminal bronchiole
respiratory bronchiole
pulmonary acinus
lung mesenchyme
lung connective tissue
bronchopulmonary segment
lower respiratory tract
respiratory tract
smooth muscle tissue of respiratory bronchiole
smooth muscle tissue of terminal bronchiole
bronchiolar smooth muscle cell
airway submucosal gland duct ciliated cell
lung perichondrial fibroblast
cartilage of bronchus
lobar bronchus mesenchyme
tracheobronchial chondrocyte
secondary crest myofibroblast
lung meganakaryocyte
tracheobronchial smooth muscle cell
subsegmental bronchus
airway submucosal gland duct basal cell
smooth muscle tissue of bronchiole
bronchus smooth muscle
lobar bronchus connective tissue
lobar bronchus
bronchial smooth muscle cell
bronchial submucosal gland ciliated duct
serous secreting cell of bronchus submucosal gland
submucosal gland collecting duct
segmental bronchus
airway submucosal gland collecting duct epithelial cell
bronchus submucosal gland
myoepithelial cell of bronchus submucosal gland
submucosal gland acinus
mucus secreting cell of bronchus submucosal gland
lobular bronchiole
primary bronchiole
tracheobronchial tree
basal cell of epithelium of lobular bronchiole
epithelium of bronchiole
club cell
pulmonary nerve plexus
sympathetic neuron
basal cell of epithelium of terminal bronchiole
terminal bronchiole epithelium
lung ciliated cell
basal cell of epithelium of respiratory bronchiole
epithelium of respiratory bronchiole
part of
has part
ccf_located_in
ccf_part_of
rdfs:subClassOf
connected to