PLATYHELMINTHES

The lecture will cover the introduction on **Cestodes** (General characteristics) and Pseudophyllidean

Important facts:
- Flatworms
- They are Hermaphrodites except for Schistosomes

Divisions:
- Trematodes or flukes
- Cestodes or tapeworm

Cestodes are further divided into two:
- Order Pseudophyllidean- aquatic life cycle and the scolex usually has two opposing sucking organs
- Order Cyclophyllidean- have 4 suckers in the scolex and the vitellaria (glands that produce yolk-filled vitelline cells which are carried to the ootype and placed around the fertilized ovum) is condensed in a mass adjacent to the ovary.

Classification of Trematodes
- Schistosomes (also known as Blood flukes)
- Tissue flukes

CLASS CESTODA

General Characteristics
- Ribbon-like and segmented
- Covered by TEGUMENT (integument of an organism specially parasitic flatworm)
  - ➔ In the tegument there are Microtriches, which are highly specialized microvilli covered covering the entire integument of the cestode, fine hair-like filament that are distributed throughout the surface of the body
- Parts:
  - ➔ Scolex - considered as the organ of attachment for cestode
  - ➔ Neck- region of growth
  - ➔ Strobila- chain of progressive redeveloping proglottids
- Number of segments: 3 to 4000
- Undergo the process of Protandry (condition in which an organism begins life as a male and then changes into a female)
- Segments:
  - ➔ either Craspedote/ Acraspedote
  - ➔ Apolytic/ Anapolytic
  - ★ Craspedote- having an anterior proglottid overlapping the next posterior one
  - ★ Acraspedote-tapeworm segments that do not overlap
  - ★ Apolytic- there is a premature detachment of proglottids or release of the terminal gravid proglottid
  - ★ Anapolytic- gravid proglottids are not shred from the strobili and the eggs are released in another way
- Class cestoda does not have any alimentary tract and vascular system
- Most are monoecious (one reproductive organ which can be either male or female) or Hermaphrodite (having both male and female organs)

Locations of Genital Pore
- Same side of proglottid
- Bilateral
- Ventral surface (usually at the center) with uterine pore
- Irregularly alternate

Vas deferens and vagina have common genital pore
- Open in the ventral surface
- Open in the lateral margin

Scolex
- Can either be globular or pyriform
- Organ of attachment
  1. Bothria (two elongated groups)
  2. Sucking disks (cup-like)
  3. Rostellum (chickenous hooks)

Proglottid
- Progressively matures and it originates from posterior region of the organism
- With completely formed sexual organ
- Common genital pores
  - ➔ On the same side of each proglottid
  - ➔ Irregularly alternate
  - ➔ Bilateral

Female Reproductive Organ
- Mature Uterus
  - ➢ Coiled
  - ➢ Saccular or lobulated
  - ➢ Tube, straight or branched
- Gravid segment
  - ➢ Can be reticulated with ova in capsules
  - ➢ With lateral branches

- ➔ Can be found towards the ventral surface
    1. Vagina
    2. Seminal receptacle
    3. Ovary
    4. Oviduct - joint to spermatic duct
    5. Ootype - egg formation
    6. Vitellaria - important for the nourishment of the egg

Male Reproductive Organ
- ➔ Can be found in the dorsal part of proglottid
    1. Vasa efferentia- manute ducts leading to the testes
    2. Vas deferens
    3. Cirrus- muscular organ that opens to the vagina
- Cirrus
    - ➔ male copulatory organ that can be found in Hymenolepis species and Taena species
- Excretory system
    - ➔ Contains flame cell or protonephridium
- Can either be heteroxenous (one or more intermediate host) or homoxenous (only have one intermediate host)

Physiology
Habitat: Intestinal lumen (ileum, jejunum, colon)
Metabolism:
- ➔ Anaerobic- absorption by tegument
- ➔ Starvation which can lead to decrease in vitamin B

Reproduction
1. Hermaphroditism- self and cross fert
2. Asexual- considered as the intermediate host

Life span: short-lived, 20-25 years for Taena
Life cycle
- requires 1 or more intermediate host
- Hymenolepis nana (requires only one host)
- Ova to larva- happens in intermediate host
- larva to adult- develop in a definitive host

Larva
- ➔ tissue of vertebrates and invertebrates

Types;
1. Solid
    - ➔ Procercoid- 2nd larval stage; bears 6 hooks near the posterior end. Can be found in copepuds. No scolex; with oncospiral hooks
    - ➔ Plerocercoid- 3rd larval stage; has a solid body with a developing scolex & strobili. Elongated and considered as the infective stage. With developing scolex and strobila
2. Vesicular/Bladder
    - ➔ Cysticercus- enlarged central cavity. Has a fluid filled and fully developed bladder. Also known as True Bladder
    - ➔ Cysticercoid- has a solid body with an invaginated scolex with poorly/slightly developed bladder or no bladder and there is a scolex at the apex
    - ➔ Coenurus- several scolices. Has a well-developed cyst with multiple invaginated scolices from the germinal layer
    - ➔ Echinococcus/hydrated cyst- – has a well-developed cyst with brood capsules and with daughter cells.

Pathogenicity
- Minimal intestinal irritation
- Toxic products
- Vitamin B deficiency

Point of differentiation	Pseudophyllidean	Cyclophyllidean
Scolex	Almond shape, with 2 sucking grooves or bothriaw	with 4 muscular suckers globular,club-shaped with or without spines or hooks
Genital pore	Center of the segment	Margin of Segment
Uterine pore	Center of the segment	None
Uterus	Coiled	Sac-like; branched, contains eggs in capsule
Ova	Operculated, immature when laid	Non-operculated, mature when laid
Oncosphere	Ciliated & called coracidium	Non-ciliated but with 3 pairs of hook and called hexacanth embryo
Larva forms	Solid a) Procercoid b) plerocercoid	Cystic a) Procercoid b) plerocercoid

		a) cysticercoids b) cysticercus c) coenurus d) hydatid
Example	D. latum	Hymenolepis species Dipylidium canicum Enchinococcus species Taenia species

Diphyllobotrium latum

Common name: Fish tapeworm or broad tapeworm

- Largest human tapeworm (Length: 10 meters)
- Can live up to 25 years
- Found in great lakes, Scandinava, W. Europe, Japan and South America
- Asymptomatic for light infection
- Heavy infection can lead to Diphyllobothrium Anemia
    - ➔ Chemical that interferes with intrinsic factors and vitamin B12 absorption

Mode of transmission: ingestion of raw or undercooked fresh water fish

- Related species:
    - ➔ D. pacificum
    - ➔ D. cordatum
    - ➔ D. ursi
    - ➔ D. dendriticum
    - ➔ D. lanceolatum
    - ➔ D. dalliae
    - ➔ D. yonagoensis

Life Cycle

- Diagnostic stage: Embryonated eggs
- Infective stage: Procercoid larva
- Coracidum
    - ➔ Liberated from egg shell
    - ➔ Swims freely in the water which is usually ciliated
- Procercoids
    - ➔ Measures 550 microns in length
    - ➔ With 3 pairs of hooklets
- Plerocercoid/ Sparganum
    - ➔ 6 mm in length
    - ➔ invaginated anterior end
    - ➔ With developing scolex and segment
    - ➔ Glistening, opaque white
    - ➔ Infective stage to man

Reservoir host: dogs and cats

Final Host: Man

1st Intermediate Host: copepods:

- ➔ Genus Cyclops & Diaptomus

2nd Intermediate Host: Freshwater

- ➔ fishes: pike, salmon, trout, white fish

Diseases: Diphyllobothriasis/ Broad tapeworm infection

- ➔ Clinical symptoms may be mild
- ➔ Can manifest: systemic toxemia, abdominal discomfort, loss of weight, loss of appetite, and malnutrition
- ➔ The migration of proglottids can cause cholecystitis or cholangitis
- ➔ can also cause mechanical obstruction
- ➔ Bothriocephalus anemia: pernicious type of anemia
    - ➢ Blood picture: macrocytic normochromic anemia with thrombocytopenia and mild leukopenia
- ➔ 40 % have decreased vitamin B12 levels
- ➔ Sparganosis
    - ➢ Affects eye, nose, neck, brain, and abdominal viscera
    - ➢ Can cause intense inflammation and eosinophilia
    - ➢ Due to ingestion of infected scallops
- ➔ Ocular Sparganosis
    - ➢ Edematous swelling of the eyelids, intense pain and irritation

Laboratory Diagnosis

- Eggs: can be demonstrated without concentration techniques
- Examination of proglottids
- Surgical removal of sparganum

Treatment

- Praziquantel (5-10 mg/kg single dose) - Drug of choice
- Niclosamide or Quinacrine hydrochloride- used to kill adult D. latum
- Paramomycine
- 40% ethyl alcohol with Procaine injected into the lesion to kill plerocercoid

Prevention

- Freezing (-18oC) for 24 hours or (-10oC) for 48 hours
- Fish reservoirs should be kept free of raw sewage
- Boiling and filtering of drinking water

- De-worming of reservoir hosts
- Thorough cooking of freshwater fishes
- In endemic areas, feces should not

Morphology

Adult: ivory white

- longest tapeworm of man
- length can range from 3-10 meters
- 4000 proglottids
- Scolex: with sectorial grooves (bothria) and usually almond-shaped

Proglottids

- Broader (2-4 mm long and 10-12 mm wide)
- Male and female reproductive organs can be found and the genital pore can be found in the center of the segment
- Coiled uterus (usually rosette)

Ovum

- 30-50 micrometers
- Posterior part is thickened
- Yellowish to yellow brown
- Immature if found in feces
- 100,000 eggs per day
- Single cell and operculated

CESTODES

CYCLOPHYLLIDEAN

Taenia solium

Common Name: pork tapeworm
Diseases: Taeniasis solium, Pork tapeworm infection, Cysticercosis
Distribution: Cosmopolitan, Mexico, Latin America, Eastern Europe, Africa, Asia
Definitive host: man

Morphology

Ova
- brown, spherical, 31-35 microns in diameter, with 2 radially striated shells
- indistinguishable from T. Saginata
- 30,000-50,000 eggs/segment

Adult
- 2 to 8 meters in length

Scolex
- globular with 4 suckers and armed with rostellum (circular row of hooks)

Proglottid
- 5 x 10 mm in size with 800-1000 proglottids
- complex absorption and reproduction system
- closer to the scolex- no sexual organs
- farther to the scolex- more sexual

Gravid proglottid
- contains 30,000-50,000 eggs;
- uterus exhibit 7-12 lateral branching
- Intermediate host: pig, man

Characteristics

Adult
- Head: Globular scolex with four suckers
- Rostellum with a double crown of hooks. Other references described it as circular row of hooks
- Unsegmented narrow neck and a large body formed by several hundred proglottids
- Entire body is called strobila and may range from 2-8 meters long (slightly smaller compared to Taenia saginata)
- Proglottids 5x 10 mm with 7-12 uterine branches
- 800-1000 proglottids

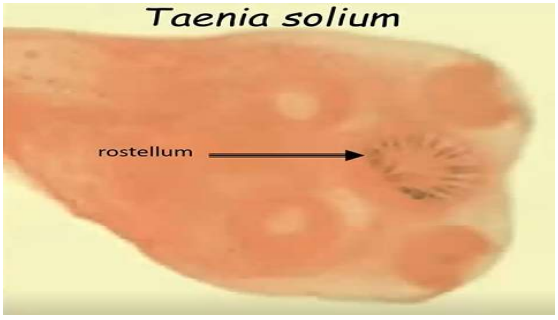

Scolex of Taenia solium with circular row of hooks and the four suckers

Ova
- Eggs of T. solium and T. saginata are indistinguishable (in order to determine whether it is a T. solium or T. saginata medical history should be identified)
- Spherical brown
- Diameter: Measures 31-35 microns
- 2 radially striated shell
- 30,000- 50,000 eggs/segments

Intermediate Host: pig and man
• Definitive Host: Man
• Taenia solium dwells in the small intestine of human where it attached to the intestinal wall with its powerful suckers and hooks.
• Every few days 2-5 gravid proglottids each measuring around 0.5 x 2 cm will detach from the distal area of the body of the worm and are passed in the feces.
• Each proglottid liberates thousands of eggs which are fully embryonated and infective as well as resistant to adverse environment and conditions.
• Eggs are viable up to 2 months in the water, soil and vegetation particularly in humid and warm environment

Pathology

1. Taeniasis solium
   ➔ caused by adult tapeworm

Light infection: asymptomatic
Heavier infection: abdominal discomfort, epigastric pain, vomiting, diarrhea with mild transitory intestinal obstruction
- Characterized by mild transitory intestinal obstruction and may give rise to vague abdominal pain similar to hunger pains
- Caused by the ingestion of raw of insufficiently cooked pork containing cysticercus cellulosae

2. Cysticercosis cellulosae
   ➔ caused by the cysticercus cellulosae

- ➔ Ocular cysticercosis: 2.5% of patients
- ➔ Muscular involvement: 10%
- Caused by the accidental ingestion of T. solium, or thru regurgitation of eggs and gravid segments of the parasite into the stomach
- Cysticercus cellulosae may lodge in vital organs like the brain, spinal cord, heart, liver, eyes etc. giving rise to pressure symptoms
- The presence of growing larva provokes cellular reactions with blood cell infiltration, fibrosis, necrosis of the capsule
    - ➢ Upon ingestion by humans, the eggs outer shell disintegrate in the small intestine, could enter the intestinal wall and blood vessel
    - ➢ Most frequently develops in the voluntary muscle
    - ➢ Larvae completes development in around 2 months (semi-transparent, elongate oval in shape; Length of 0.6-1.8 cm.)
    - ➢ Bladder is fluid-filled, one side is a denser area containing scolex

3. (60-90%) Neurocysticercosis

- ➔ may cause epilepsy (most common with 50-70% of patients) or disordered behavior, intermittent obstructive hydrocephaly, disequilibrium, meningoencephalitis and falling vision

- ➔ Intacranial hypertension-
    - most common cause of this syndrome which is the cysticercotic encephalitis which is a severe form of parenchymal cysticercosis that usually affects children and young women

Clinical Manifestations

Acute inflammatory response, severe brain edema In relation to epilepsy, this can also lead to disordered behavior can be manifested with number of patients with neurocysticercosis

Diagnosis

a) Taeniasis

- ➔ presence of ova or gravid proglottids can be observed through stool examination; scotch tape swab and in the perianal area

b) Cysticercosis

- ➔ presence of antibodies, development of sub-cuticular nodules which provide material for biopsy

c) Surgical removal of intracranial cysts

Laboratory Diagnosis

- Presence of Eggs or proglottids in:
    - ➔ Stool
    - ➔ Perianal area
- Cysticercosis
    - ➔ Presence of antibodies
- Biopsy
- Another way of diagnosing is through surgical removal of intracranial cyst with demonstration of organism.
- Radiographic demonstration of calcified cyst that can be found in the muscle can also be done
- Visualization of cysticercus in the orbit

Treatment

- Praziquantel (Drug of choice)
    - ➔ 5-10 mg/kg single dose for intestinal
    - ➔ Expulsion of scolex
    - ➔ 50 mg/kg per day for 3 days within 15 days for cysticercosis
- Albendazole
    - ➔ 5 mg/kg per day for 8 to 28 days
- Bithionol
- Panomomycin

Prevention and Control

1. A thorough inspection of beef and pork
    a. adequate cooking or freezing
    b. Freezing meat at -20C for 10 days
2. Avoid eating raw pork
3. Proper disposal of human feces
4. Good personal hygiene

Taenia saginata

Common name: Beef tapeworm

Disease: Taeniasis saginata

- ➔ Disturbance in the normal functions of the digestive tract
- ➔ Systemic intoxication

Intermediate host: cow

Definitive Host: humans

Mode of transmission: ingesting infective meat

- Small intestine attached by its scolex
- As proglottid break up in colon releasing eggs

Morphology

Ova

- same with T. solium
- 35x45 micrometers
- round & yellow-brown
- peripheral radial striations
- contain an embryo with 3 hooklets
- 80,000 eggs/segment

Adult

- whitish, opaque in color
- 5-10 meters/ 4-6 meters in length , 12 mm in width
- each gravid proglottid contains 80,000 eggs
- segment: 18x6 mm with a branched uterus (15-30 branches)
- 4 suckers but no hooks (no mouth)
- derives nourishment from intestinal contents
- uterus is median club-shaped, vagina is sphincter

Diagnosis

- ➔ Most patients do not know that they are infected until proglottid crawl out of the anus or proglottid is recovered from the stool. Taeniasis is then diagnose via recovery of eggs in feces, specifically test that involves identification of eggs, proglottids or scolex's characteristics
- ➔ Stool examination- DFS, KTS, Concentration Techniques
- ➔ Perianal Scotch Tape method

Treatment

- Praziquantel
  - ➔ 5-10 mg/kl single dose
- Niclosamide- not locally available

Note: Life cycle of T. saginata: same as T. solium except for the intermediate host

METHODS OF DIFFERENTIATING TAENIA SPECIES

1. Examine the proglottids in the feces
   - ➔ inject dye (India ink or safranin) using gauge 26 needle (counting of uterine branches)
2. Examine the scolex
   - ➔ T. solium: armed with rostellum with 4 muscular suckers
   - ➔ T. saginata: unarmed with 4 muscular suckers

Note: Taenias are virtually identical in morphology, identification can be made by the number of lateral uterine branches, scolex and the gravid proglottid

Differences	**Taenia solium**	**Taenia saginata**
Common name	Pork Tapeworm	Beef Tapeworm
Disease/s	Taeniasis solium CYSTICERCOSIs	Taeniasis saginata
Scolex	Globular in shape with 4 cup-shaped suckers;rostellum and double rows of hooklets	Pyriform in shape with 4 muscular suckers; NO hooklets
Mature Proglottid	Roughly square with unilateral or irregularly alternate genital pore	Irregularly alternate lateral genital pore
Segments	800-1000	1000-2000
Testes	150-200	300-400
Uterine Branch	7-12	15-30
Infective Stage	**Cysticercus cellulosae** - ellipsoidal, translucent, -thin walled bladder with an opaque -invaginated neck and scolex equipped with suckers and hooks **Ova**	**Cysticercus bovis** - pinkish cyst, opaque -with invaginated neck -scolex with 4 suckers

	-matured when laid	

Taiwan taenia/ Taiwan asiatica

➔ Aborigines of Taiwan

Infective Stage: varied

- Cysticercus
  - ➔ Invaginated scolex armed with hooklets
  - ➔ Adult scolex: unarmed (resembles saginata)

Gravid segments: 11-32 branches

Intermediate hosts: Pigs, cattle, goats, wild boar and monkeys

- It resembles Taenia solium

Hymenolepis nana/ Vampirolepis nana

Commonly known as Dwarf Tapeworm

- Most common cause of cestode infection, encountered in the temperate regions and common in children and institutional groups

Found in Rats: Hymenopepis nana variety fraterna

Intermediate Host: fleas

➔ rice and flour beetles (Tenebrio spp)

Definitive host: man, rats, mice

Infective stage:

➔ embryonated ova (Direct Life Cycle)

➔ cysticercoid larva (Indirect Life Cycle)

Disease: Dwarf Tapeworm Infection

➔ Massive infection may follow autoinfection

➔ Little or no pathology that can occur from development of cysticercoid in the villi

Heavy infection:

➔ Enteritis with nausea and vomiting

➔ Diarrhea

➔ Abdominal pain

➔ Headaches

➔ Anorexia

➔ Dizziness

Host Defense:

- Cysticercoid in tissue
  - ➔ Cellular and humoral response
- Indirect
  - ➔ Little or no immunity
  - ➔ Permitting occasional massive internal reinfection
- Immune response is seldom effective against the internal infection

Morphology

<u>Ovum</u>

- 45 µm in diameter;
- Size: 30-55 µm
- differentiated from the egg of H. diminuta
- Oncosphere: six hooks (seen as dark lines at 8 O'clock)

<u>Larva (Cysticercoid)</u>

- Tailed structure w/invaginated scolex
- Lacks a fluid filled bladder
- Develops in insect or human villi (SI)

<u>Adults</u>

- Small, L: 15-50 mm
- Scolex: retractable rostellum w/20-30 Y-shaped hooklets (distinguishing characteristic)
- Segments: wider than long, terminal gravid segments break up and release eggs
- Genital pore: located on the same side

Pathology

- Generalized toxemia- due to the absorption of metabolic wastes of the parasites
- Pruritis ani; intestinal obstruction; periodic diarrhea
- Headache, dizziness, anorexia

Diagnosis

- Fecalysis: eggs
- Light infections: Concentration on alternate days will increase the detection

Treatment

- Praziquantel (25mg/kg single dose)
  - ➔ causes vacuolization and disruption of tegument at the neck region. Causes paralysis and death of Hymenolepis nana
- Niclosamide
  - ➔ effective alternative medication. Its action causes death to the tapeworm by the interference of oxidative phosphor-relation. 40 mg/kg per 1 dose

Control & Prevention

- Preventing fecal contamination of food and water in institutions and crowded areas
- General sanitation: rodent and insect control (especially control of fleas and grain insects)
- Treatment of infected patients
- Personal hygiene

Hymenolepis diminuta

Common Name: Rat Tapeworm
- ➔ Parasites of rats

Human: only an accidental infection
Requires intermediate host
Intermediate Host: insects (beetles, cockroaches, ratfleas) (cysticercoids will mature 20 days after infection)
Definitive Host: rat and man
Infective Stage: Cysticercoid larva

Morphology

Ovum
- hexacanth larva (oncosphere)
- Enclosed in an inner membrane
- Lacks bipolar filaments
- Hooklets: fan-like arrangement
- D: 60-80 µm, bile stained
- has 6 hooks

Adult
- L: 40-60 cm
- scolex is club-shaped: unarmed rostellum with four suckers

Proglottids
- (broader than long) L: 0.75 mm; W: 3.5
- mm
- 3 ovoid testes and 1 ovary
- Genital pores: unilateral
- Uterus: sac-like with eggs

Laboratory Diagnosis
- Fecalysis: eggs
  - ➔ distinguish from H. nana
  - ➔ eggs
  - ➔ whole worm: morphology of scolex
- Light infections:
  - ➔ concentration techniques
  - ➔ repeated examinations

Treatment:
- Praziquantel : 25 mg/kg single dose
- Quinacrine
- Niclosamide

Prevention and Control
1. Preventing fecal contamination of food and water in institutions and crowded areas
2. Protection of food especially the pre-cooked cereals from insects
3. General sanitation; rodent & insect control
4. Treatment of infected patients
5. Personal hygiene
6. Sanitary disposal of human waste

Criteria	**H. nana**	**H. diminuta**
Common Name	Dwarf Tapeworm	Rat Tapeworm
Infection	Dwarf Tapeworm infection	Hymenolepiasis diminuta
Scolex	Globular -Short refractile rostellum -single row of 20-30 small hooks - 4 cup-shaped suckers	-Club-shape -unarmed rostellum -4 suckers
Number of Segments	200	800-1000
Mature Proglottid	-Trapezoidal -4 times as broad as long - single genital pore on its left side - 3 round testes and bilobed ovary	
Gravid proglottid	-Uterus is sacculate -contains 20-180 eggs	-sacculate -filled with egg masses
Ova (has 6 hooklets)	-4 to 8 filaments	-no polar filaments
Habitat	-Upper 2/3 of ileum	Small intestine of rats and mice
Infective Stage	-E. ova -cysticercoid larva	-Cysticercoid larva
Intermediate Host	-None (direct life cycle) -flour fleas, flour beetles (indirect cycle)	-fleas -beetles -cockroaches

Dipylidium caninum

Common name: Double-Pored Tapeworm/ Dog TW / Flea tapeworm / Cucumber tapeworm

- ➔ Very common parasite of dogs and cats worldwide

Accidental Host: Humans
Normal host: canines
Intermediate host: larval stage of the dog or cat flea / dog louse (trichodectes canis)
Habitat: Lumen of small intestine of dogs
Infective stage: cysticercoid larvae
Intermediate hosts:

- Cat fleas (Ctenocephalides felis)
- Dog fleas (Ctenocephalides canis)
- Human fleas (Pulex irritans)

Definitive host: dogs/canines, cats and man
Disease: Dipylidiasis or Dog tapeworm infection (usually self- limiting)

- Intestinal disturbances including:
  - ➔ Indigestion
  - ➔ loss of weight
  - ➔ Epigastric pain
  - ➔ Diarrhea
  - ➔ Anal pruritus
  - ➔ Allergic reactions

Morphology

<u>Adult</u>

- Pale red
- L: 10-70 cm

<u>Scolex</u>

- With 4 suckers
- 1-7 rows (30-150)
- Rose thorn shaped hook
- Rather than containing hooks it contains 1-7 circlets of spine which resides in rustellum causing its rustellum to be club-shaped in appearance

<u>Proglottids</u>

- (60-175 proglottids)
- o mature- pumpkin seed shaped with double set of reproductive organs following self-fertilization, resulting gravid proglottid is full of eggs and enclosed in an embryonated membrane
- o gravid- filled with polygonal-shape uterine egg pocket (8-15 effs in each)

<u>Ova</u>

- subspherical to oval

- hyaline with thick transparent albuminous covering with membranes; each egg contains an oncosphere with 3 pairs of delicate hooklet / 6 hooked oncosphere

Diagnosis

- Stool exam: DFS, KTS, Concentration tech) observe for the eggs and gravid segments that can crawl out the anus
  - ➔ Feces: eggs and proglottids
  - ➔ Single egg may occur but is rare
  - ➔ Proglottids are flattened between 2 slides
  - ➔ Egg capsules: rarely seen in feces
  - ➔ Based on the recovery of characteristic eggs or gravid proglottids

Treatment

- Quinacrine
- Niclosamide
- Praziquantel: 5-10 mg/kg (single dose)

Prevention

- Children should be informed with the danger of playing with dogs
- Flea control of pets would largely eliminate the infection from household pets and children
- Periodic deworming of pet cats and dogs

RAILLIETINA SPECIES

- Found worldwide
- genus of parasitic tapeworms that has chicken, turkey, geese and numerous other domestic and wild birds as final hosts.
- Common in traditional and free ranging poultry
- complex genus of cestodes (family Davianeidae

The most relevant ones are:

- Raillietina cesticillus
  - ➔ the broad-headed tapeworm, up to 13 cm long and 1-3 mm wide, in chicken, turkey and many wild birds; found worldwide
- Raillietina echinobothrida
  - ➔ the nodular tapeworm, up to 25 cm long and 1 -4 mm wide, in chicken, pigeon, pheasants; found worldwide
- Raillietina tetragona
  - ➔ up to 25 cm long and 1-4 mm wide, in numerous domestic and wild birds; found worldwide

- Raillietina bonini
  - ➔ up to 7 cm long and 1.5 mm wide, mainly in pigeons; found in Europe, Near and Middle East (mostly)

Raillietina garrisoni

- Raillietine madagascariensis (originally known)
- Garrison (1911)
- Thailand: 1891 (1st case)
  - ➔ Tokyo
  - ➔ Formosa
  - ➔ Australia
  - ➔ Ecuador
  - ➔ North Iran
- Common intestinal cestode of rodents in the Philippines

Morphology

Ova

- L: 60 cm
- Minute, subglobular scolex
- 4 acetabula
- Rostellum

Scolex

- minute; subglobular, has rostellum with 90-140 hammer shaped hooks

Mature proglottid

- bilobed ovary, surrounded by 36-50 ovoid testes, and has 1-4 spindle eggs per capsule
- Genital pore: opens at the side
- L: 2mm
- Contains 200-400 egg capsules
- Ingested by flour beetle
  - ➔ Tribolium confusum

Pathogenesis

- Asymptomatic
- Medical consultation: proglottids in feces

Diagnosis

- Fecalysis – Proglottids and ova

Treatment

- Praziquantel to expel the worm

Prevention and Control

- Elimination of rodents
- Proper storage of grain products
- Sanitary waste disposal

Echinococcus granulosus

Common name: Hydatid Worm, Hydatid cyst

Key concepts:

- Echinococcosis (hydatid disease)

Intermediate host: Humans

Definitive host: dogs and other canines

Diagnostic stage: Larval stage

Geographical distribution: Australia, New Zealand, South Arica and Africa

- Not typically found in human but can be found in canine

Morphology

Eggs

- cannot be differentiated from the eggs of Taenia
- It resembles Taenia specie

Adult

- shortest tapeworm with only 3 segments; 3-9 mm in length
- consist of scolex, a small neck and 3 proglottids, one at each developing stage (immature, mature and gravid)

Scolex

- Pyriform with 4 suckers and globular with prominent rostellum (double crown of 20-36 hooklets)

Proglottids

- 3 segments - Immature, mature and gravid proglottid

Gravid segment

- hydauterus with its lateral invagination resembles a loosely twisted coil. Uterus has 12-15 branches distended with around 500 eggs.

Larva

Hydatid cyst

- ➔ with 3 major components:

1. Germinal layer
   - ➢ Outermost morphological contour
   - ➢ Responsible for the uptake of essential resources from the host through syncytial membrane
   - ➢ Constitutes the outer part
2. Protoscolex
   - ➢ Asexually buds from the brood capsule
   - ➢ Protrudes from the germinal layer

- ➢ Develops into adult when it infects the definitive host

3. Hyatid fluid
    - ➢ Compose of many proteinaceous and non-portentous materials which are secreted from the parasite as well as absorbed from the host
    - ➢ Harbours tegumental materials shed from the protoscolex and resources derived from metabolic turnover of the germinal layer

Pathogenesis

- Damage produced by the larval forms are mechanical and toxic. Young cyst may lodge in vital organs like the capillary beds of brain or heart valves producing dangerous obstruction. In the bone, they cause erosion leading to fracture. In the abdomen, they grow into tremendous size and burst, followed by anaphylactic reactions caused by the toxic hydatid fluid
- Liver (66%): Obstructive jaundice, Fever, eosinophilia
- Lungs (22%): Coughing with allergic symptoms, Sputum: frothy blood, mucus, hydatid fluid
- Kidneys (3%): Intermittent pain, hematuria, Kidney dysfunction
- Brain: Increased intracranial pressure, Jacksonian epilepsy

Laboratory Diagnosis

- Cross section of a slow-growing tumor with eosinophilia
- ELISA (for screening)
- Roentgenography (production of x-ray images)
- Casoni intradermal test
- Immunoelectrophoresis
- Most specific serologic test
- Arc 5 antigen
- 10% of case (+)

Treatment

- Surgical removal of the cyst;
- Replacement of the cyst fluid with 10% formalin or 2% $AgNO_3$
- Albendazole: 400 mg 2x a day for 4 weeks
- High dose of Mebendazole

Prevention

- Personal hygiene
- Deworming of dogs
- Safeguarding all discarded viscera in slaughterhouses by boiling or dumping into dog proof pits

Echinococcus multilocularis

- Hydatid worm

Synonym: Echinococcus alveolaris
Definitive Host: fox, canines, coyotes, cats
Intermediate Host: rodents and sometimes humans
Mode of transmission:

- ➔ Fecal-oral
- ➔ eating raw plants contaminated w/ DH's feces
- infection may vary with seasonal fluctuations
- Lifespan is inversely proportional with the temperature
- Liver is the most common site where to find the cyst

Morphology

- 3-5 segments (1.2 – 3.7 mm)
- 4 suckers
- No mouth
- No anus
- Scolex is attaches to the strobila with a long thick neck
- Both male and female system is present
- Requires the definitive host to reproduce

Pathogenesis

- Varies:
    - ➔ Some infections may spontaneously disappear
    - ➔ Death

TREMATODES: DIOECIOUS FLUKES

- Most important digenetic trematodes of man
- Delicate cylindrical parasites
- Live typically in pairs in portal blood vessels or in the vessical venules

Human infection: Bilharziasis
- ➔ Teodor Bilharz: 1951

Mode of transmission: Skin penetration of cercariae
Infective stage: CERCARIA
Distribution: China, Japan, Indonesia, Thailand, Cambodia, Philippines

Morphology

Male adult
- Larger than female measuring about 12-20 mm by 0.5 to 0.55 mm in diameter
- Grayish in color and is attached by its suckers to the wall of the vessel
- Attached to the wall of the vessel
- GYNECOPHORAL CANAL on the ventral side which functions to surround almost completely the female adult facilitating copulation

Female adult
- Smaller and are thread-like
- Average size is 26 mm in length by 0.3 mm in diameter

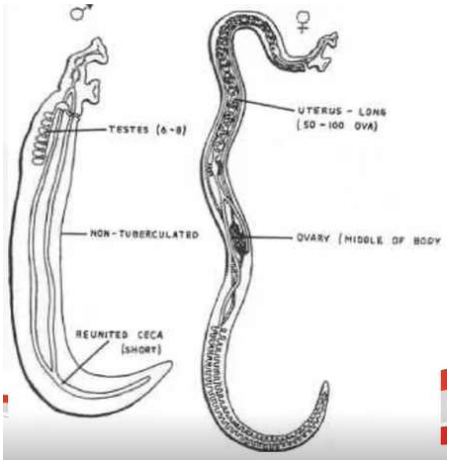

Life cycle of Dioecious Flukes
- Schistosoma mansoni and Schistosoma japonicum is commonly isolated from feces, though occasionally can be obtained from the urine
- Schistosoma haematobium is commonly isolated from the urine (Schistosoma japonicum can sometimes be isolated in urine)

1. Under appropriate conditions the eggs hatch and release **miracidia**, which swim and penetrate specific snail tissue (intermediate hosts)
2. The stages in the snail include two generations of sporocysts (which develop in the snail) and the production of cercariae (which will be release in the snail in free-swimming, stage that penetrate the skin)
3. Upon release from the snail, the infective cercariae swim, penetrate the skin of the human host and shed their forked tails, becoming **schistosomulae** (before it will go to circulation)
4. In the circulation it will migrate to portal blood in liver and mature into adult worm (The schistosomulae migrate via venous circulation to lungs, then to the heart, and then develop in the liver, exiting the liver via the portal vein system when mature)
5. Pair adult worms will migrate to mesenteric venules of the vowel or rectum and lay egg that circulate to the liver and shed in stools and can also lodge in the venous plexus of the bladder

3 Stages of Infection

1. Pre-patent or developmental
- Skin penetration to arrival of adult in venules
- Pathologic changes
  - ➔ Negligible to mild cutaneous lesions
  - ➔ Tissue reactions to immature worms
  - ➔ Associated toxic and allergic reaction

2. Acute stage
- Active eggs deposition and extrusion
- Appearance of eggs in the stool
- Symptoms:
  - ➔ daily fever
  - ➔ epigastric pain
  - ➔ continuous increase in size of the liver
  - ➔ loss of weight
  - ➔ relapse of pain

3. Chronic Stage
- Invasion of the tissues by the migrating larva and adult worms:
  - ➔ Petechial hemorrhage
  - ➔ Small foci of eosinophilia
  - ➔ Neutrophilic infiltration in the lungs
  - ➔ Cough and hemoptysis
  - ➔ Acute inflammation reactions in the liver with fever
- During this stage there is already a stable egg output and tissue proliferation

Laboratory Diagnosis

1. Schistosoma haematobium
   - eggs in urine (dysuria and hematuria)
   - bladder biopsy

2. Schistosoma japonicum
   - recovery of eggs in feces
   - rectal biopsy

3. Circumoval Precipitin Test (COPT)
   - Incubation of eggs and patient's serum

4. Antibody Detection
5. Certain immunodiagnostic technique: ELISA

Treatment

- Praziquantel (40-50 mg/kg single dose)
- Oxamniquine
- Niridazole

Control and Prevention

- Snail Control
- Sanitary disposal of human excreta
- Treatment of infected person

Schistosoma japonicum

Common Name: Oriental Blood Flukes, Visceral Blood Flukes
Main habitat: Superior mesenteric veins
Infective Stage: Cercaria
Intermediate Host: Snail

- Oncomelania hupensis
- Oncomelania oncophora
- Oncomelania formosana
- Oncomelania quadrasi (Philippines)
- Oncomelania nocophara (Japan)
- Oncomelania formosana (Taiwan)

Final Host: man. dogs, cats, carabao, cows, rodents, monkeys
Reservoir Host: wild & domestic animals (sheep, dogs, mice, horses, pigs)
Disease: Visceral or Oriental Schistosomiasis, Katayama's Disease

General Morphology

- Utilize glucose at a fairly fast rate and life span is 3-8 years
- Round, smallest in the Schistosoma specie measuring 50-85 µm x 38-60 µm
- Eggs are characterized by the presence of small lateral spine which is often difficult to detect in microscopic examination

- Distinction that will help in determination is the <u>presence of small lateral spine in the ova</u>

<u>Male</u>

- Ovoidal testes: single row behind acetabulum
- Union of ceca and testes: posterior to the middle haft of the body
- Contains gynecophoral canal
- shorter but sturdier; measuring about 12-20 mm by 0.4-0.5 mm
- with 7 ovoidal testes arranged in single row behind acetabulum

<u>Female</u>

- Longer and slender (15-30 mm)
- Pyramidal ovary: center of the body
- Lays 500-2000 eggs per day
- More delicate than males

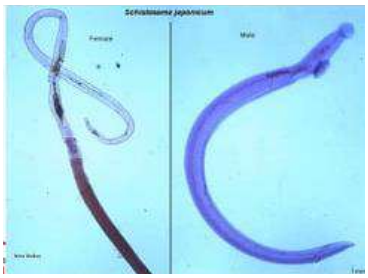

<u>Ova</u>

- Oval to subspherical (D: 46-110 µ)
- Adherent to bits of tissue or RBC's
- Non-operculated
- Manute lateral knob/ curved hook

<u>Miracidium</u>

- <u>Infective stage to snails for 8-12 hours</u>
- Miracidium is attracted by the secretion coming from the snail
- Phototactic and swims actively

<u>Cercariae</u>

- Forked tailed
- Oral sucker (anterior end) and small ventral suckers
- Cercarial penetration is mediated by lytic enzymes
- Stimulus for penetration is the presence of lipid in the skin
- Drugs: dimethylate and niclosamide will help repel cercaria in the skin

Schistosoma mansoni

Common Name: Manson's Blood Flukes
Main habitat: Inferior mesenteric veins
Distribution: Africa, Arabian Peninsula, Brazil
Intermediate Host: Snails

- Biomphalaria (Philippines)
- Tropicorbis (South America)
- Austrolobis (South America)

Definitive Host: Man
Reservoir Host: Rodent
Disease: Intestinal Bilharziasis, Schistosomal Dysentery

General morphology

- Relatively large, measuring around 112-182 µm x 40-75 µm
- Organism is somewhat oblong and possesses a prominent large lateral spine

Male

- 8-9 testes
- Union of ceca: middle haft of the body

Female

- Smallest schistosomes
- Ovary: anterior to the middle haft of the body
- Contains 1-4 ova

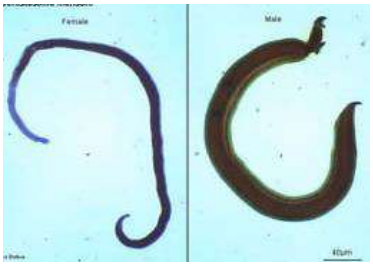

Ova

- Ellipsoidal
- Yellowish brown in color
- Prominent lateral spine
- Measures 112-182 um by 40-75 um
- Appear in the feces 30-40 days after infection

Schistosoma haematobium

Common Name: Vessical Blood Flukes or Bladder flukes
Main habitat: Veins of the urinary bladder
Distribution: Africa, Western Asia, Southern Europe
Intermediate Host: Snail

- Biomphalaria - Africa
- Bulimus - Middle East

Disease: Vessical Schistosoma, Urinary Schistosoma, Schistosoma hematuria

General morphology

- Resembles Schistosoma mansoni in size and shape

Male

- 4-5 testes
- Union with the ceca: posterior to middle haft of the body

Female

- Ovary: posterior to middle of the body
- 20-30 ova

Ova

- Ellipsoidal with prominent terminal spine
- Yellowish brown color
- Oblong measuring 110-170 µm x 38-70 µm
- Presence of large prominent spine that distinguishes the egg from the other Schistosoma specie
- Ellipsoidal with prominent terminal spines measuring about 110-170 um by 38-70 um
- The ovary of an adult is located at the posterior to middle of the body containing 20-30 eggs

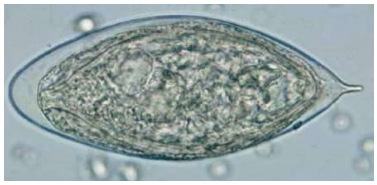

Note:

Human Schistosoma infections are prescribed to increase and spread in endemic areas because of reestablishment of water control projects on a massive scale where snail breeding areas are generated.

Schistosomiasis is considered as the se**cond most serious parasitic infection** after malaria when it comes to mortality and morbidity.

Swimmers itch has been known to occur in persons who have been accidentally infected by cysticercaria of schistosoma

TREMATODES: MONOECIOUS FLUKES

- Monoecious flukes reproduced by self-fertilization or cross-fertilization
- Eggs: supplied with yolks from the vitelline glands are fertilized within the uterus and surrounded by a shell in the mehlis glands. They must be shed in a suitable environment to continue the life cycle.

LUNG OR PULMONARY FLUKES

Paragonimus westermani

Common name: Oriental lung fluke / Lung Fluke
Distribution: Japan, Korea, China, Nepal, Philippines

- Usually reside in pairs in the lungs
- With plumped bodies shaped like coffee beans

Habitat: Lung pockets (in pairs)
Disease: Paragoniamiasis
Clinical Manifestations:

1. Chronic bronchitis
2. Hemoptysis- characterized by dry cough and then later with blood-stained sputum with a foul odor
3. Abdominal & Chest pains, dyspnea
   - ➔ dyspnea- shortness of breath and described sometimes as air hunger
4. Low grade fever, fatigue and generalized myalgia (muscle pain)

Infective stage: Metacercaria
1st IH: snail of Genera

- ➔ Hua (Semisulcospira, Syncera and Thiara, Pomatiopsis, Pomacea)
- ➔ Brotia asperata (Philippines)

2nd IH:

- ➔ Freshwater crabs
- ➔ Crayfish

<u>Ova</u>

- Color: Yellowish to brown or yellowish brown to dark or golden brown
- Flattened operculum measuring: 80-120 µm
- Immature when oviposited

<u>Adult</u>

- Color: Reddish brown

- Tegument is covered with single spaced spines
- Active state: spoon-shaped
- Preserved state: oval, flattened, coffee bean shaped
- Has a lobed testes oblique to each other
- Lobed ovary
  - ➔ Anterior to the testes
- Vitellaria - extreme lateral fields.
- measurement: 1.2 cm long x 0.6 cm wide and 0.4 cm thick

Note: They have 2 large branching testes that are located in the posterior half of the body and it also has a spiny cuticle and suckers that are of equal size.

4 Stages of *P. westermani*

- Miracidium
- Rediae
- Cercaria

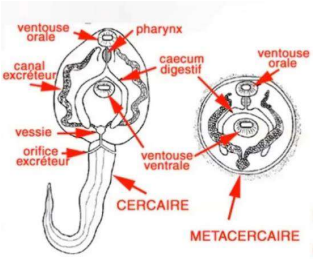

- Metacercaria

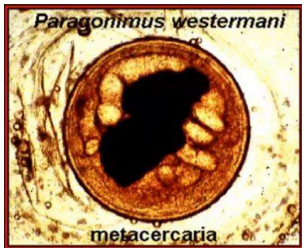

Life cycle

- ➔ Eggs will enter the alveoli. These are coughed up or swallowed passed out in the feces or in the sputum.
- ➔ The egg hatches in the water, enters a specific snail and multiplies and after which, released cercaria will enter the crabs and the crayfish where the metacercaria encyst.
- ➔ When the infected crustacean is eaten, the metacercaria are released from the cyst and will penetrate the gut wall and enter into the peritoneum, the diaphragm and the lungs.

Laboratory Diagnosis

- Eggs in sputum and feces
- X-ray
  - ➔ a typical finding is a ring-shadowed opacity, comprising
- Antibody detection
  - ➔ differentiate Paragonimus from PTB
  1. Complement fixation (CF) test
     - Standard test for Paragonimiasis
     - Highly sensitive for the diagnosis and monitoring chemotherapy
  2. Enzyme immunoassay (EIA) test
- Immunoblot (IB) Assay
  - ➔ uses of crude antigen extract of P. westermani
  - ➔ (+) reactions: 8-kDa antigen- antibody band
  - ➔ Specificity: ≥ 99%

Control and Prevention

- Cook properly crab meat
- Health education to change food habits of the population

Treatment

- Praziquantel (25mg/kg thrice a day for 3 days)
  - Drug of choice
- Biothionol (15-25 mg/kg twice for alternate days for 10-15 days)

HEPATIC/ LIVER FLUKES

Clonorchis sinensis

Common Name: Chinese Liver Fluke/ Oriental Liver Fluke

Distribution: Japan

- Usually infect the liver, gallbladder and bile ducts in man

Habitat: Bile passages / Bile ducts

Infective Stage: Metacercaria

1st IH: Operculated snails

- Bulimus
- Hua
- Alocinina
- Semisulcospira
- Thiara

2nd IH: Freshwater fish

- TIngea tingea
- Barbus barbus

Disease: Clonorchiasis

- Acute Phase:
  - ➔ Abdominal pain, nausea, diarrhea, and eosinophilia (increased number of eosinophil), cholangitis (inflammation of bile duct system), cholelithiasis (gallstone disease), pancreatitis (inflammation of pancreas), cholangiocarcinoma (bile duct cancer)
  - ➔ Irritation of bile duct
  - ➔ Leukocytosis (increased number of leukocytes) and eosinophilia: early infection
  - ➔ Intermittent obstruction of bile ducts

Ova

- Resembles the old fashion electric bulb
- Color: Yellowish brown
- Operculum: Distinctly convex
- Fully embryonated when laid

<u>Adult</u>

- Tapering anterior and rounded posterior
- Ventral sucker is smaller than oral sucker
- Cuticle: smooth and shiny
- Has a highly branched testes

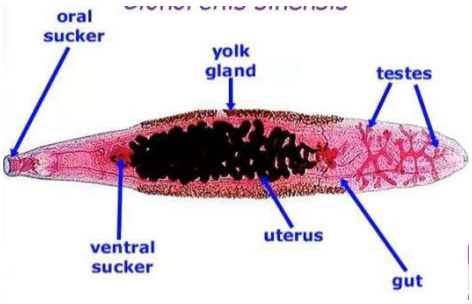

Life Cycle

Human → Egg → Miracidium → Snail → Cercaria → Metacercaria

Laboratory Diagnosis

- Eggs in biliary drainage
- Immunologic tests
- Liver scan
  - ➔ Fecalysis- more practical but the eggs of Clonorchis sinensis are very similar to those of Opistorchis
- Additionally, cyst containing the parasites can sometimes be detected through ultrasound, CT scan or MRI

Treatment

- Praziquantel - drug of choice
- Chloroquine phosphate
- If there is a presence of adult flukes, then it can be resort to surgery

Opisthorchis felineus

Common Name: Cat Liver Fluke

- **Opistorchis viverrin**i- Southeast Asian Liver Fluke
- Found mainly in Northeast Thailand, Laos, Cambodia and Central and Southern Vietnam

Distribution: Italy, Germany, Velarus, Russia, Kazakhstan, Ukraine.
Infective Stage: Metacercaria
Habitat: Distal ducts and occasionally in Pancreatic ducts
1st IH: snails (Bulimus)
2nd IH: freshwater fishes
Disease: Opisthorchiasis

- Asymptomatic
- Mild cases:
  - ➔ Dyspepsia- symptoms of indigestion wherein there is discomfort or pain that occurs in the upper abdomen.
  - ➔ Abdominal pain
  - ➔ Diarrhea
  - ➔ Constipation
  - ➔ Hepatomegaly- enlargement of the liver
  - ➔ Acute phase resembling Katayama fever
    - manifestation of acute schistosomiasis where the typical features: fever,urticarial rash, enlarged liver and spleen, and bronchospasms

Adult

- Testes: lobate and oblique in position
- both Adult and Ova resembles of Clonorchis sinensis

Laboratory Diagnosis

- Ova and parasite (O&P) stool examinations for liver fluke eggs is the only available way to diagnose Opisthorchis infection.
- More than one stool sample is needed to identify the eggs. The eggs of Opisthorchis are similar to the eggs of Clonorchis but can be distinguished by microscopic features.
- Testing the blood for Opisthorchis is not useful for patient management and no blood test to detect the infection is available

Treatment

- Praziquantel or Albendazole - drugs of choice to treat Opisthorchis infection

Fasciola hepatica

Common Name: Common Liver Fluke / Sheep Liver Fluke
Distribution: Areas where sheep and cattle are raised and where humans consume raw watercress (Europe, Middle East and Asia)
Infective Stage: Metacercaria
1st IH: water snail (Lymnaea)
2nd IH: Water Cress
Disease: Liver Rot/ Fascioliasis

Acute Phase (immature fluke found in the liver)	**Chronic phase** (adult fluke- bile duct)
Larval migration to the liver Right quadrant abdominal pain & hypereosinophilia	Intermittent biliary obstruction because of the presence of the adult flukes Inflammation
Manifestation: • Abdominal pain • Hepatomegaly • Fever • Vomiting • Diarrhea • Urticaria and eosinophilia	Occasionally: • Ectopic locations of infection • Intestinal wall • Lungs • Subcutaneous tissue • Pharyngeal mucosa

Ova

- Large and ellipsoidal
- Operculated
- Yellowish to light brown
- Thin-shelled with distinct operculum
- Unsegmented stage in the feces

Adult

- Usually large with a broad body which measures about 20-50 mm in length and 6-12 mm in width
- Cephalic cone: shouldered appearance which is the distinguishing characteristic

- Testes: tandem formation and highly branched
- Vitellaria: branched, found in lateral and posterior portion
- Ovary: branched located posterior to uterus and anterior to testes
- Uterus: Short and coiled

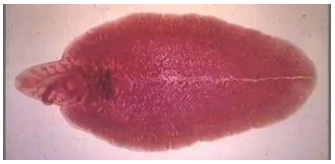

Laboratory Diagnosis

➔ In acute stage, you have to go back to the patient's history, microscopy

1. DFS, Concentration Technique
2. Eggs: duodenal or biliary drainage
3. Morphologically indistinguishable from Fasciolopsis buski eggs.
4. Serologic tests and Radiography
5. Antibody detection
   - Early detection of Fasciola infection and chronic fascioliasis
   - The purpose of this is to rule out pseudofascioliasis
   - Useful for invasive stages of the disease

Fasciola gigantica

Common Name: Giant Liver Flukes

- Same with Fasciola hepatica EXCEPT:
  - ➔ Greater length
  - ➔ Shorter cephalic cone
  - ➔ Larger ventral sucker
  - ➔ Reproductive organ: anterior portion
  - ➔ Bigger ovum

Infective Stage: Metacercaria
Distribution: Infections with F. gigantica have been reported, more rarely in Asia, Africa, and Hawaii
Mode of Transmission

- Ingestion of watercress
- Drinking of water from streams

1st Intermediate Host: Snail
2nd Intermediate Host: Watercress
Disease: Fascioliasis

Laboratory Diagnosis

➔ Same with Fasciola hepatica

Dicrocoelium dendriticum

Common Name: Lanceolate Fluke/ Lancet Fluke

- ***Dicrocoelium hospes-*** Responsible for human infection in west Africa
- Can be found in the bile duct of herbivores

- Common parasite of ruminants but man can be accidental or definitive host

Definitive Host: Herbivores

➔ Herbivores infection happens via ingestion of ants

Infective Stage: Metacercaria
1st Intermediate Host: snail (genus Helicella, Zebrina specie and Cionella specie)
2nd Intermediate Host: Ants (genus formica with metacercaria)
Disease:

- Human infection is rare
- Mild hepato-biliary involvement

<u>Eggs</u>

- 36-48 µm x 20-30 µm
- Thick shelled and Dark-brown
- Operculated shell
- Fully embryonated when shed in feces
- Needs two intermediate host for the complete parasite development

<u>Adult</u>

- Length: 5-15 mm; Width: 1.5-2.5 mm
- Bile ducts of herbivorous
- Common parasite of ruminants but man can be accidental or definitive host

Morphology

- Has a similar morphology with ***<u>Chlonorchis sinensis</u>*** or ***<u>Chinese liver fluke</u>***.
- Dicrocoelium dendriticum is distinguish by the presence of a lobe testes in the anterior of the body, whereas, Chlonorchis sinensis testes is located porterior of the body
- Both are flat with characteristic taper in the posterior and anterior end
- Anterior is distinguished by an oral sucker at the point, acetabulum and the testes
- Posterior is where uterus lie
- Mid-section lies the vitelline glands involved in egg formation

Diagnosis

- Eggs
  - ➔ Feces
  - ➔ Bile
  - ➔ Duodenal fluid

Treatment

- Praziquantel 25 mg/kg

INTESTINAL FLUKES

Heterophyes heterophyes

- Hetero means "different", phyes means "form"
- Human infection occurs in Asia, Egypt and Hawaii
- Minute intestinal flukes

Common Name: Dwarf Intestinal Flukes, Von Seibold Flukes
Habitat: Small intestine (middle & upper portion or the jejunum and duodenum)
Infective Stage: Metacercaria
1st Intermediate Host: Brackish water snail
- Pirenella (Egypt), Cerithidea

2nd Intermediate Host: Fish
- Mugil or Mullet
- Yellow perch (egypt)
- Mugil and Acanthogobius (Japan)

Disease: Heterophyiasis
- Diarrhea
- Colicky abdominal pain
- Fatal myocardial and valvular damage

Adult
- measures 1-2 mm in length
- Cuticle covered with minute scale like spine
- Testes
  - ➔ two, ovoid
  - ➔ Situated near small of ovary
  - ➔ Side by side at the fifth
- Ovary: globular, anterior to testes
- Vitellaria: large polygonal follicle
- Surface is covered by minute spine
- Adult reside in the small intestine of the definitive host

Genital pore
- located posterior-lateral to prominent ventral sucker which is surrounded by genital sucker known as gonotyl
- Length: 1-1.7 mm
- Width: 0.3 to 0.4 mm
- Humans
- Various fish-eating mammals
- Birds

Note: Specimen has a large genital sucker, adult trematode found embedded in the villi and spines (50-80) is digitate that looks like small leafless trees

Eggs
- Yellow brown in color and contains miracidium
- 27 µm x 16 µm

Ova
- Light brown in color, thick shelled
- Operculated, elongated
- Eggs contain embryo specifically miracidium
- Heterophyes heterophyes is indistinguishable from Metagonimus yokogawai but resemble of those clonorchis and opisthorchis

Treatment: Praziquantel

Fasciolopsis buski

Common Name: Largest Intestinal Flukes
Habitat: Small intestine, Large Intestine and Stomach
Infective Stage: Metacercaria
1st Intermediate Host: planorbid snails
- Segmentina
- Hippeutic
- Gyraulus

2nd Infective Stage: Water plants
- Water chestnut
- Water caltrop
- Water hyacinth
- Water bamboo

Disease: Fasciolopsiasis
- Light and asymptomatic
- Heavier infection
  - ➔ Diarrhea
  - ➔ Abdominal pain
  - ➔ Fever
  - ➔ Ascites
  - ➔ Anasarca
  - ➔ Intestinal obstruction

Ovum
- 130-159 µm x 78-98 µm
- Large, with small opened operculum, clear thin shell
- HEN's egg
- Unembryonated when laid
- 3-7 weeks to embryonate
- Yellow-brown, ellipsoidal, thin-shelled, operculated and filled with yolk cells



Adult
- Thick, flesh colored
- Cuticle with transverse row of spines
- Testes
  - ➔ Dendritic and highly branched

- ➔ Posterior haft
- Ovary: Branched, middle of the body
- Vitellaria
  - ➔ Branched
  - ➔ Lateral to cecum
- Metacercaria to adult: 3 months
- Length: 20-75 mm
- Width: 8-20 mm
  - ➔ Flat, leaf shape, blunt anterior end
  - ➔ Angiolating tandem dendritic testes and poorly develop oral and ventral suckers
  - ➔ Branched ovary, vast-vitelline follicle
- Life Span: 1 year

Laboratory Diagnosis

- Fasciola hepatica eggs are indistinguishable

Metagonimus yokogawai

- Meta "posterior", gonimus "genitalia"
- Most common heterophyed trematode in far east

Distribution: Far East, Siberia, Balkan States, Israel, and Spain
Common name: Yokogawa's fluke or Smallest human fluke
Infective Stage: Metacercaria
1st Intermediate Host: Semisulcopsira, Thiara, Hua
2nd Intermediate Host: Freshwater salmonoid fishes
Disease: Metagonimiasis

- Shortening the villus length and adhesion formed between the villi. During 5-10 days during infection there is a decrease in the number of goblet cells that are present in the area
- Heavy infection can cause small bowel diarrhea
- The main symptoms are diarrhea and colicky abdominal pain.
- Migration of the eggs to extraintestinal sites (heart, brain) can occur, with resulting symptoms

<u>Ova</u>

- Similar to Heterophyes heterophyes

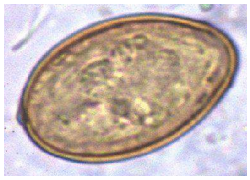

<u>Adult</u>

- Genus metagonimus can be identified by the position of the ventral sucker and genital opening which are fused and displaced in the right-midline of the body
- Testes in the posterior of the body where one is slightly anterior to the other
- Ventral sucker is larger than oral suckers
- Length: 1 mm to 2.5 mm by
- Width: 0.4 mm to 0.75 mm
- Cuticle: covered with minute scalelike spines
- Eggs measure 25-28 microns x 15-17 micrometers

Laboratory diagnosis

- Fecalysis: eggs
- Specific diagnosis: identification of the adult fluke evacuated
  - ➔ antihelminthic therapy
  - ➔ found at autopsy
- Microscopic identification of eggs in the stool. However, the eggs are indistinguishable from those of H. heterophyes and resemble those of Clonorchis and Opistorchis

Treatment: Praziquantel

Echinostoma ilocanum

- Echinos means "hedgehog" in greek, stoma in latin means "mouth or spherical opening", and canis which means "dogs"
- Spinal Collar fluke

Common name: Garrison's Intestinal fluke
Distribution: Population of Ilocano in Luzon, Java, China where dogs are infected
Habitat: Small Intestine
Infective Stage: metacercaria
Mode of transmission: Ingestion of metacercariae encysted in the snail (2nd intermediate host)
Definitive Host: Humans, Dogs, Cats and pigs
1st Intermediate Host: Water Snail

- Gyraulus convexiusculus (Philippines and Java)
- Hippeutis (Philippines)
- Gyraulus prashadi (India)

2nd Intermediate Host: Freshwater Mollusk (Pila conica)
Disease

- Inflammatory reaction
- Ulceration at the sites of attachment
- Intestinal colic and diarrhea

<u>Ova</u>

- Straw-colored with operculum at one end
- Measures 83-116 um by 58-69 um
- Large with thin shell
- Contains undeveloped miracidium

Adult

- Measures 2.5-6.6 mm in length and 1-1.35 mm in width
- Tapered at the posterior end and has 49-51 collar spines
- Elongated, reddish-gray with horse-shoe shaped collar of spines surrounding the dorsal and lateral sides of oral sucker
- Cuticle: with minute spine-like scales
- Oral sucker is at the center of the body; ventral sucker is located at the anterior fifth of the body
- Testes: Bilobed arrange in tandem at the third quarter of the body; lobate; located posterior to ovary
- Ovary: globular; located anterior to the testes
- Uterus: looped, anterior the ovary
- Uterine coil: found between the ovary and ventral sucker
- Vitellaria
    - ➔ with small follicles
    - ➔ lateral border of the posterior ⅔ of the worm

Treatment: c

Laboratory Diagnosis

- DFS

Prevention and Control

- Individuals can avoid infection by not eating raw snails in endemic areas