Received: April 20, 2026 | Accepted: April 23, 2026 | Published: May 04, 2026

Peercite Journal of Surgery and Medicine

ORIGINAL RESEARCH

Table of Contents

Introduction.....1

Case Presentation:.....2

Surgical Management:.....2

Pathological Findings:.....2

Discontinuous Spermatic Cord Involvement and Staging:...2

Therapeutic Considerations:.....2

Key Clinical and Pathologic Features in This Case:.....3

Conclusion:.....3

References:.....4

https://doi.org/10.61641/pjsm.2026.4.S1.7521-7526

Received: April 20, 2026 | Accepted: April 23, 2026 | Published: May 04, 2026

Peercite Journal of Surgery and Medicine

ORIGINAL RESEARCH

Advanced Testicular Mixed Germ Cell Tumor with Discontinuous Spermatic Cord Metastasis: Expanded Case Report

M. V. S. Sai Adithya [1]

K. A. Mohammed Asif [2]

K. Santhosh Kumar [3]

Jagadish Guptha [4]

[1 2 3 4] MS GENERAL SURGERY

Citation: M. V. S. Sai Adithya (2026) Advanced Testicular Mixed Germ Cell Tumor with Discontinuous Spermatic Cord Metastasis: Expanded Case Report Peercite J Surg Med. 4(S1):7521-7526.

Corresponding Author : M. V. S. Sai Adithya

Email: saiaditya25@gmail.com

Copyright: © 2026 by the authors. Licensee MDPI, Basel, Switzerland. This article is an open access article distributed under the terms and conditions of the Creative Commons Attribution (CC BY) license (https:// peercite.org).

Abstract :

Testicular germ cell tumors (TGCTs) are the most common solid malignancies in young men and are highly curable with stage-adapted multimodal therapy (Singla et al., 2025; Di Costanzo et al., 2025; Feldman et al., 2008; Gilligan et al., 2019). Mixed germ cell tumors (MGCTs), containing both seminomatous and non-seminomatous elements, often behave aggressively and are treated as non-seminoma (Singla et al., 2025; Gilligan et al., 2019; Chen et al., 2018). Discontinuous spermatic cord involvement has emerged as a distinctive adverse pathological feature linked to advanced stage (Pena et al., 2021; Alì et al., 2020; Sanfrancesco et al., 2018; Portillo, Rais-Bahrami and Magi-Galluzzi, 2022; Verrill et al., 2017).

Keywords : Testicular germ cell tumors, Mixed germ cell tumors, Seminomatous, non-seminomatous, Aggressive behavior, Multimodal therapy, Stage-adapted treatment, Spermatic cord involvement, Discontinuous spread, Adverse pathological feature, Advanced stage

Introduction:

TGCTs comprise 90–95% of testicular cancers and peak in the third decade of life (Singla et al., 2025; Keskin et al., 2025; Gilligan et al., 2019). Non-seminomatous and mixed tumors frequently present with metastatic disease and require cisplatin-based chemotherapy, achieving 5-year survival >70% even in poor-risk groups (Keskin et al., 2025; Di Costanzo et al., 2025; Feldman et al., 2008; Gilligan et al., 2019 ; Laguna et al., 2001). Pathologic predictors of advanced stage include lymphovascular invasion, large tumor size, and invasion of rete testis and hilar soft tissue (Scandura et al., 2023; Yılmaz et al., 2013; Lobo et al., 2018). The AJCC 8th edition designates discontinuous spermatic cord soft-tissue deposits as metastatic (pM1), reflecting their strong association with advanced clinical stage (Pena et al., 2021; Alì et al., 2020; Sanfrancesco et al., 2018; Portillo, Rais-Bahrami and Magi-Galluzzi, 2022).

Case Presentation:

A 23-year-old man presented with a six-month history of painless, progressively enlarging right testicular swelling. Examination revealed a firm, smooth, non-tender 10 × 5 cm mass with loss of ipsilateral testicular sensation; the contralateral testis was normal.

Scrotal ultrasonography suggested a right testicular neoplasm with teratomatous features. Staging imaging demonstrated:

● Multiple rounded pulmonary "cannon-ball" metastases

● Pleural deposits with bilateral effusions

● A heterogeneously enhancing hepatic lesion (segment IV)

● Abdominal and retroperitoneal lymphadenopathy

These findings indicated disseminated systemic disease, consistent with stage III non-seminomatous GCT in standard classifications (Singla et al., 2025; Keskin et al., 2025; Di Costanzo et al., 2025; Gilligan et al., 2019). Serum tumor markers were markedly elevated: AFP 1100 IU/mL, LDH 1947 IU/L, and β-hCG 5904 mIU/mL, compatible with active non-seminomatous MGCT and aligning with poor-risk criteria when extrapulmonary visceral metastases and very high markers are present (Keskin et al., 2025; Feldman et al., 2008; Alrehaili and Tashkandi, 2020; Gilligan et al., 2019).

Surgical Management:

The patient underwent right radical inguinal orchiectomy, the recommended initial treatment for suspected TGCT to avoid scrotal violation and permit accurate staging (Singla et al., 2025; Gilligan et al., 2019; Laguna et al., 2001). Intraoperatively, a 10×6 cm testicular tumor was identified, with multiple discrete nodular deposits along the spermatic cord, spatially separate from the primary intratesticular mass.

Pathological Findings:

Grossly, the tumor was nodular with variegated yellow brown and grey white solid areas, hemorrhage, & necrosis, extending into mediastinum testis, epididymis, and the base of the cord—patterns typical of advanced mixed tumors (Chen et al., 2018; Yılmaz et al., 2013; Lobo et al., 2018).

Histology confirmed MGCT composed of:

● Seminoma – 40% (classic "fried-egg" cells with lymphocytic infiltrate)

● Yolk sac tumor – 40%

● Teratoma – 20%

The neoplasm infiltrated the rete testis. Rete testis and hilar invasion have been linked to higher clinical stage in non-seminomatous tumors and are recommended reporting elements in contemporary protocols (Verrill et al., 2017; Yılmaz et al., 2013; Lobo et al., 2018). In this case, multiple discontinuous spermatic cord soft-tissue deposits, rather than direct contiguous extension, were identified, fulfilling criteria for discontinuous involvement.

Discontinuous Spermatic Cord Involvement and Staging:

Large multi institutional series have clarified the clinicopa--thologic significance of spermatic cord patterns:

● Discontinuous soft tissue involvement is strongly associated with advanced clinical stage and distant metastasis, with 67–100% of such patients presenting with stage II/III disease (Pena et al., 2021; Alì et al., 2020).

● Compared with continuous cord extension, discontinuous deposits correlate with higher frequency of lymph-node involvement, distant metastases, and advanced disease at diagnosis, even after adjustment for other factors (Pena et al., 2021; Alì et al., 2020; Sanfrancesco et al., 2018).

● These data underpin the AJCC 8th edition designation of discontinuous cord involvement as metastatic (pM1), in contrast to direct extension (pT3) or isolated cord lymphovascular invasion (Pena et al., 2021; Alì et al., 2020; Sanfrancesco et al., 2018; Portillo, Rais-Bahrami and Magi-Galluzzi, 2022).

Consensus recommendations emphasize careful gross sampling of the cord and explicit reporting of cord invasion subtype, margin status, and percentage tumor components to ensure accurate TNM assignment and risk stratification (Verrill et al., 2017; Portillo, Rais-Bahrami and Magi-Galluzzi, 2022; Gilligan et al., 2019). The present case typifies the strong association between discontinuous cord deposits and widely metastatic MGCT, reinforcing their staging as metastatic rather than purely local extension.

Therapeutic Considerations:

For metastatic non-seminomatous & mixed GCTs, cisplatin based combination chemotherapy (typically BEP or EP) is the cornerstone of systemic therapy, guided by IGCCCG risk stratification (Keskin et al., 2025; Di Costanzo et al., 2025; Feldman et al., 2008; Gilligan et al., 2019; Laguna et al., 2001).

High volume centers report 5-year overall survival of ~65–75% in poor risk patients with extrapulmonary visceral disease and very high tumor marker levels (Keskin et al., 2025; Di Costanzo et al., 2025; Feldman et al., 2008; Alrehaili and Tashkandi, 2020). Post chemotherapy management of residual masses often includes retroperit--oneal lymph node dissection, particularly in non semin--omatous disease (Di Costanzo et al., 2025; Feldman et al., 2008; Chen et al., 2018; Gilligan et al., 2019). In this patient, extensive pulmonary, pleural, hepatic, and nodal metastases, combined with markedly elevated AFP and β-hCG, indicate a high risk category necessitating prompt, guideline directed cisplatin based chemotherapy, with subsequent evaluation for residual disease resection in line with contemporary recommendations (Keskin et al., 2025; Di Costanzo et al., 2025; Feldman et al., 2008; Alrehaili and Tashkandi, 2020; Gilligan et al., 2019; Laguna et al., 2001).

Key Clinical and Pathologic Features in This Case:

Feature	Relevance	Citations
Young age (23 years)	Typical demographic for	(Singla et al., 2025; Keskin et al., 2025;
Mixed seminoma/non-se	Managed as non-seminoma,	(Singla et al., 2025; Chen et al., 2018;
Markedly elevated AFP, β-hCG, LDH	Indicates active non-seminomatou	(Singla et al., 2025; Keskin et al., 2025;
Rete testis invasion	Associated with advanced stage in	(Scandura et al., 2023; Yılmaz et al.,
Discontinuous spermatic cord	Strongly linked to advanced stage;	(Pena et al., 2021; Ali et al., 2020;
Extensive visceral metastases (lung,	Defines stage III disease; still often	(Singla et al., 2025; Keskin et al., 2025;

Figure 1: Key demographic, pathologic and staging factors in this case

Conclusion:

This case describes an aggressively behaving testicular MGCT in a young man, presenting with high burden systemic metastases and discontinuous spermatic cord soft tissue deposits. The constellation of mixed histology, markedly elevated tumor markers, rete testis invasion, and discontinuous cord metastases exemplifies multiple adverse prognostic features now recognized in contemporary staging systems. Radical inguinal orchiectomy, meticulous pathol--ogic staging including precise characterization of cord involvement & timely initiation of cisplatin based combina--tion chemotherapy, with consideration of residual mass surgery, remain essential to optimize outcomes in such advanced presentations.

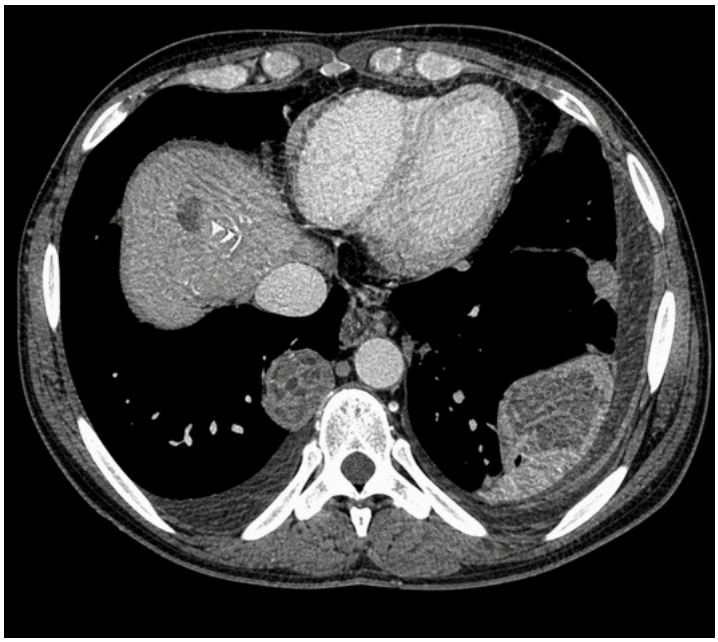

Axial section of cect showing Heterogeneously enhancing lesion in liver segment 4

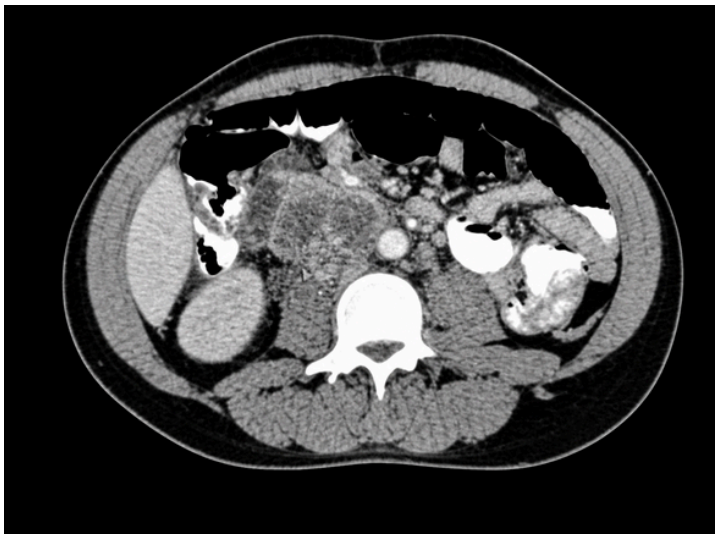

Axial section of the CECT at abdominal level are seen multiple discrete as well as conglomerated heterogenously) enhancing Lymphnodes

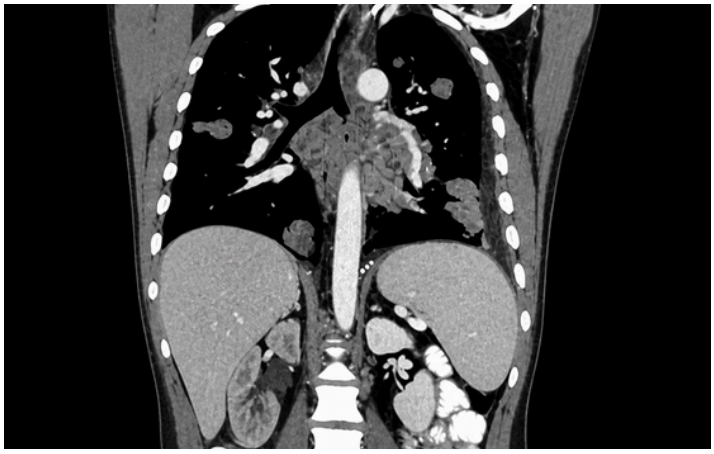

This is a coronal CT scan of the chest and upper abdomen showing a mediastinal mass, possibly compressing nearby structures. Further evaluation is needed for diagnosis.

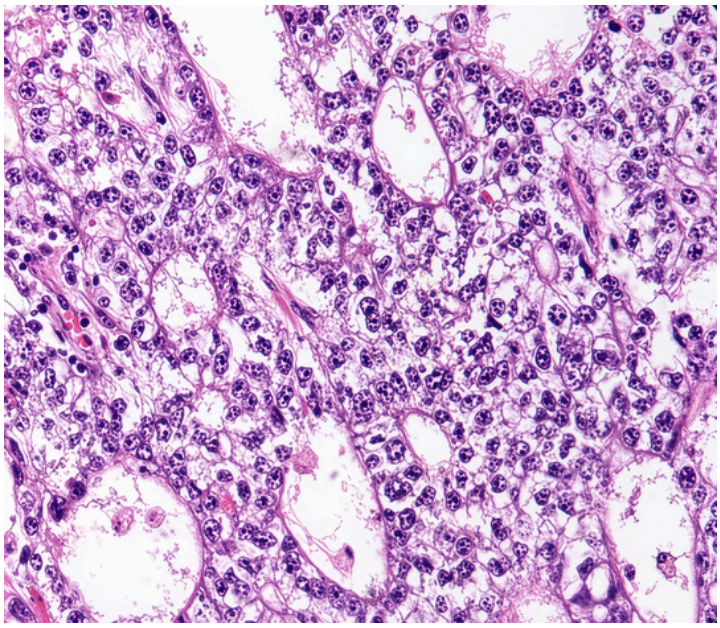

The image shows an H&E-stained section with atypical cells and hyperchromatic nuclei, suggestive of a malignant tumor. Further evaluation with clinical correlation and additional tests is required for confirmation.

The image shows an enlarged scrotal swelling suggestive of an underlying testicular or scrotal pathology.

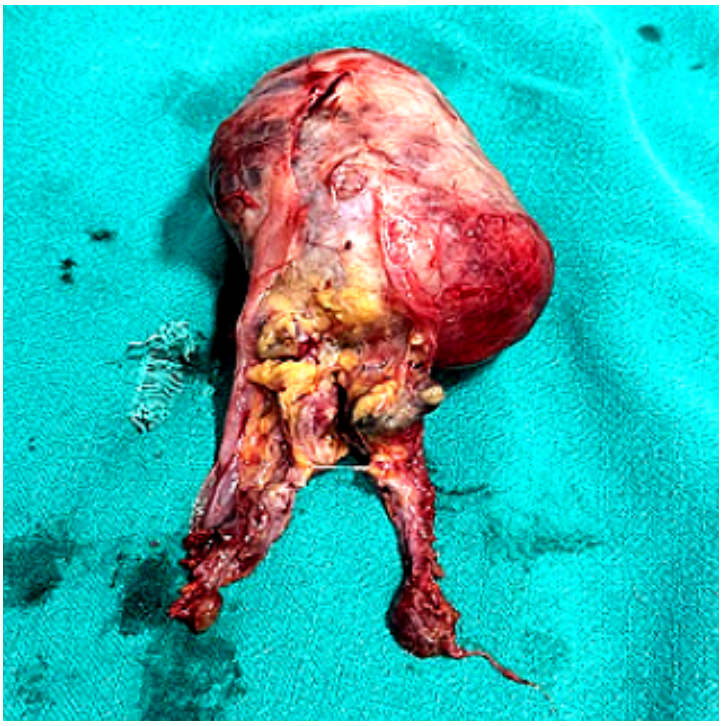

The image shows a gross surgical specimen of a tumor mass with attached cord-like structures, likely representing an excised testicular lesion.

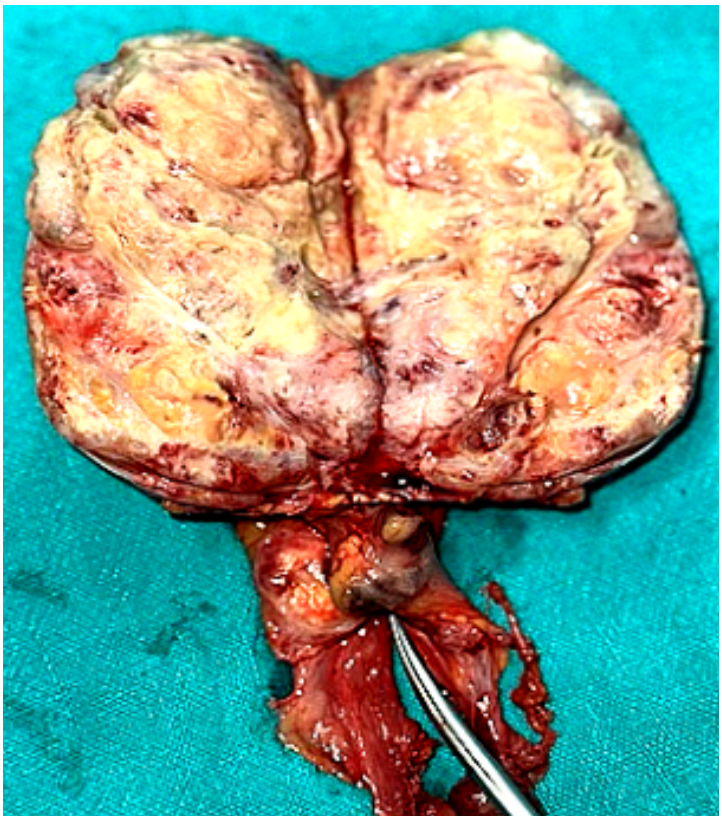

The image shows a cut section of a testicular tumor with heterogeneous solid areas and attached spermatic cord structures.

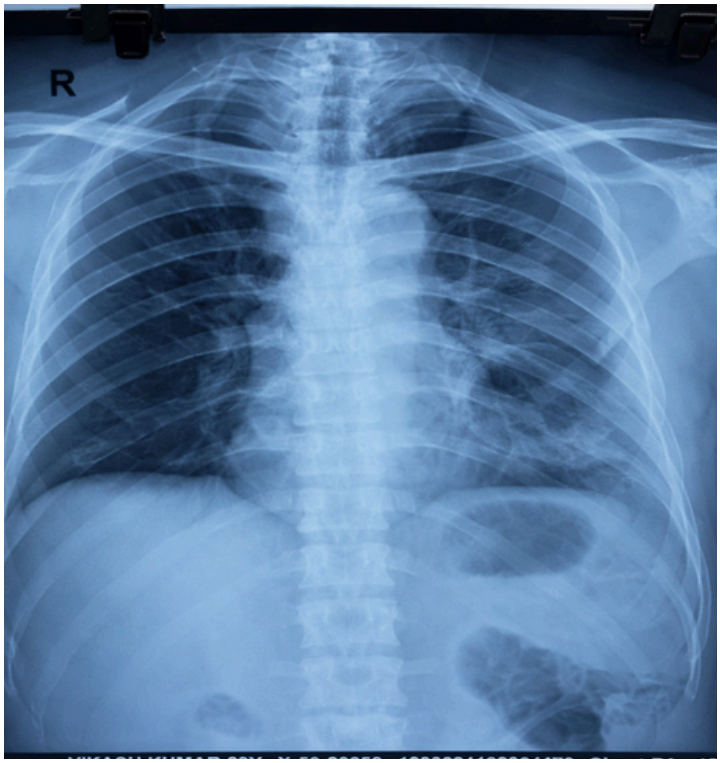

A chest X-ray showing the rib cage, lungs, and heart silhouette, used to assess thoracic structures and detect pulmonary or cardiac abnormalities.

References :

1. Alì, A., So, J., Khani, F., Kvetoslava, M., Miyamoto, H., Osunkoya, A., Peña, M., Magi-Galluzzi, C., Raspollini, M., Scarfò, F. and Zynger, D. (2020). Discontinuous Involv- -ement of Spermatic Cord Soft Tissue in Testicular Germ Cell Tumors: A Multi-Institution Experience. American Journal of Clinical Pathology, 154. doi: 10.1093/ajcp/aqaa161.339.

2. Alrehaili, M. and Tashkandi, E. (2020). Testicular Mixed Germ Cell Tumor Combined with Malignant Transfor- -mation to Chondrosarcoma: A Very Rare and Aggressive Disease. The American Journal of Case Reports, 21, pp. e922933-1 - e922933-5. doi: 10.12659/ajcr.922933.

3. Chen, L., Liu, Z., Wang, H. and Liu, S. (2018). [Diagnosis and treatment of testicular mixed germ cell tumors: A report of 27 cases].. Zhonghua nan ke xue = National journal of andrology, 24 11, pp. 987-991.

4. Di Costanzo, F., Rescigno, P., Seidel, C., Morrall, T., Oliveira, P., Hentrich, M. and Oing, C. (2025). Management of Advanced Germ Cell Tumors.. Oncology research and treatment, pp. 1-26. doi: 10.1159/000546798.

5. Feldman, D., Bosl, G., Sheinfeld, J. and Motzer, R. (2008). Medical treatment of advanced testicular cancer.. JAMA, 299 6, pp. 672-84. doi: 10.1001/jama.299.6.672.

6. Farooq, A., Jordá, M., Whittington, E., Kryvenko, O., Braunhut, B., Pavan, N., Procházková, K., Zhang, L., Rai, S., Miller, T., Liu, J., Szabo, A. and Iczkowski, K. (2018). Rete Testis Invasion Is Consistent With Pathologic Stage T1 in Germ Cell Tumors. American Journal of Clinical Pathology, 151, pp. 479–485. doi: 10.1093/ajcp/aqy168.

7. Gilligan, T., Lin, D., Aggarwal, R., Chism, D., Cost, N., Derweesh, I., Emamekhoo, H., Feldman, D., Geynisman, D., Hancock, S., LaGrange, C., Levine, E., Longo, T., Lowrance, W., McGregor, B., Monk, P., Picus, J., Pierorazio, P., Rais-Bahrami, S., Saylor, P., Sircar, K., Smith, D., Tzou, K., Vaena, D., Vaughn, D., Yamoah, K., Yamzon, J., Johnson-Chilla, A., Keller, J. and Pluchino, L. (2019). Testicular Cancer, Version 2.2020, NCCN Clinical Practice Guidelines in Oncology.. Journal of the National Comprehensive Cancer Network : JNCCN, 17 12, pp. 1529-1554. doi: 10.6004/jnccn.2019.0058.

8. Keskin, G., Yetginoglu, O., Vurgun, S., Guzel, E., Ozkan, F., Yılmaz, M., Soylemez, C., Ağyol, Y., Akbaş, S., Sagıroglu, M., Yıldırım, G., Semiz, H., Tatlı, A., Ekinci, F., Coşar, R., Acar, R., Aykan, M., Erturk, I. and Karadurmuş, N. (2025). Survival Outcomes in Metastatic Germ Cell Tumors: A Multicenter Study from Turkey. Medicina, 61. doi: 10.3390/medicina61060951.

9. Laguna, M., Pizzocaro, G., Klepp, O., Algaba, F., Kisbenedek, L. and Leiva, O. (2001). EAU Guidelines on Testicular Cancer. European Urology, 40, pp. 102 - 110. doi: 10.1159/000049759.

10. Lobo, J., Costa, A., Vilela-Salgueiro, B., Rodrigues, Â., Guimarães, R., Cantante, M., Lopes, P., Antunes, L., Jerónimo, C. and Henrique, R. (2018). Testicular germ cell tumors: revisiting a series in light of the new WHO classification and AJCC staging systems, focusing on challenges for pathologists.. Human pathology, 82, pp. 113-124. doi: 10.1016/j.humpath.2018.07.016.

11. Pena, M., Canete-Portillo, S., Amin, A., Aron, M., Colombo, P., Cox, R., Baydar, D., Gallegos, I., Khani, F., Michalová, K., Lucianò, R., Miyamoto, H., Osunkoya, A., Raspollini, M., Sánchez, D., Scarfò, F., So, J., Zynger, D., Wei, S., Netto, G. and Magi-Galluzzi, C. (2021). Testicular Germ-Cell Tumors with Spermatic Cord Involvement: A Retrospective International Multi-Institutional Experience. Modern Pathology, 35, pp. 249-255. doi: 10.1038/s41379-021-00912-9.

12. Portillo, S., Rais-Bahrami, S. and Magi-Galluzzi, C. (2022). Updates in 2022 on the Staging of Testicular Germ Cell Tumors.. Human pathology. doi: 10.1016/j.humpath.2022.07.009.

13. Sanfrancesco, J., Trevino, K., Xu, H., Ulbright, T. and Idrees, M. (2018). The Significance of Spermatic Cord Involvement by Testicular Germ Cell Tumors: Should We Be Staging Discontinuous Invasion From Involved Lymphov--ascular Spaces Differently From Direct Extension?. The American Journal of Surgical Pathology, 42, pp. 306–311. doi: 10.1097/pas.0000000000001008.

14. Scandura, G., Wagner, T., Beltrán, L., Alifrangis, C., Shamash, J. and Berney, D. (2023). Corrigendum to "Pathological predictors of metastatic disease in testicular non-seminomatous germ cell tumors: which tumor-node-metastasis staging system?": [Modern Pathology 34 (2021) 834-841].. Modern pathology : an official journal of the United States and Canadian Academy of Pathology, Inc, 36 4, pp. 100105. doi: 10.1016/j.modpat.2023.100105.

15. Singla, N., Bagrodia, A., Baraban, E., Fankhauser, C. and Ged, Y. (2025). Testicular Germ Cell Tumors: A Review.. JAMA. doi: 10.1001/jama.2024.27122.

16. Yılmaz, A., Cheng, T., Zhang, J. and Trpkov, K. (2013). Testicular hilum and vascular invasion predict advanced clinical stage in nonseminomatous germ cell tumors. Modern Pathology, 26, pp. 579-586. doi: 10.1038/mod pathol.2012.189.

17. Verrill, C., Yılmaz, A., Srigley, J., Amin, M., Compérat, E., Egevad, L., Ulbright, T., Tickoo, S., Berney, D. and Epstein, J. (2017). Reporting and Staging of Testicular Germ Cell Tumors: The International Society of Urological Pathology (ISUP) Testicular Cancer Consultation Confere--nce Recommendations.. The American journal of surgical pathology, 41 6, pp. e22-e32. doi: 10.1097/pas.0000000000 000844.