Received: September 30, 2023 | Accepted: October 10, 2023 | Published : October 17, 2023

Crossref PEERCITE PUBLISHERS Open Access

Peercite - Journal of Surgery and Medicine

ORIGINAL RESEARCH

Preoperative Indicators of Ossicular Necrosis in Mucosal Chronic Suppurative Otitis Media

Dr. Sowmya[1] , Dr. Sriranga Prasad [2], Dr. Sai Sarath [3]

Department of Biomedical Sciences, Post-Doctoral Research, University at Albany, SUNY Newyork, USA

[1] Assistant Professor, Department of ENT , Rajarajeswari Medical College, Bangalore.

[2] Professor, Department of ENT, Rajarajeswari Medical College , Bangalore.

[3] Resident, Department of ENT, Rajarajeswari Medical College , Bangalore.

★*Corresponding Author : Dr. Sowmya (sowmyareddy1189@gmail.com)*

DOI :https://doi.org/10.61641/pjsm.2023.1.2.7501-7504

Copyright: © 2023 by the authors. Licensee MDPI, Basel, Switzerland. This article is an open access article distributed under the terms and conditions of the Creative Commons Attribution (CC BY) license (https:// peercite.org).

Abstract:

Chronic suppurative otitis media (COM) refers to chronic infection of the middle ear cleft in the presence of a persistent tympanic membrane perforation. Ossicular necrosis is usually seen in squamosal type but can also be seen in mucosal type, which can come as a surprise to the surgeon. Objectives of the study was to know the relation between pre-operative clinical findings with ossicular necrosis and PTA evaluation and ossicular necrosis.

Methods :

A prospective study was conducted in the department of Otolaryngology, between November 2019 and May 2021. All 75 consecutive patients with Mucosal COM underwent preoperative clinical evaluation and intraoperative findings noted.

Results :

In this study the incus (14 cases) was most frequently eroded. A raised pure tone audiometric average threshold of more than 40-50 dB hearing loss (HL) and presence of granulation was found to be statistically significant.

Conclusion :

The presence of granulation tissue and a raised pure tone audiometric average threshold is more likely to be associated with ossicular erosion. Preoperative identification of these indicators can help the surgeon for counseling about the outcome of surgery.

Introduction :

Chronic suppurative otitis media (COM) refers to a chronic inflammation of the mucosa lining the middle ear cleft. COM is defined by otorrhea of at least 12 weeks duration in the presence of a chronic tympanic membrane perforation1.COM is classified into Tub-tympanic Disease (safe type/mucosal) and Attico-antral Disease (Unsafe type/squamosal). The Mucosal COM is known as safe type as serious complications are very rare in this type of COM.

COM is referred to as mucosal type if there is a perforation of the pars tensa and squamous type if there is a perforation perforation or retraction of the pars flaccida with retained debris of squamous epithelium2 .

Active mucosal COM is often associated with resorption of parts or all of the ossicular chain (resorptive osteitis)3. Bone resorption is a feature of both active mucosal and squamosal types of COM. The ossicles affected show hyperemia with capillary proliferation and prominent histiocytes4 .

The lenticular process of the incus, stapes crura, body of the incus and manubrium are involved in that order of frequency 3.

Although ossicular erosion can occur in both types of COM, the incidence of ossicular erosion in Mucosal COM is low. 3D High resolution computer tomography can help define the middle ear and identify ossicular chain discontinuity. This is not a routine investigation for patients with COM without cholesteatoma and hence ossicular chain erosion is confirmed only during surgery and may come as a surprise.

Pre-operative knowledge of ossicular necrosis enables thesurgeon to plan the operative scheduling, allowing a longer duration for surgery and arrange for specific equipment and materials required for ossiculoplasty. Anesthetists would also use a longer acting anesthetic according to the surgeon's estimate of the duration of surgery.

The surgeon can discuss the probability of performing an ossiculoplasty, the surgical complications and the expected outcome with the patient prior to surgery and obtain consent. Hence this study is intended to identify the relation between a series of common pre-operative clinical signs and investigations with ossicular necrosis in patients with Mucosal COM.

OBJECTIVES:

1. To study the relation between pre-operative clinical findings with ossicular necrosis.

2. To study the relation between PTA evaluation and ossicular necrosis

MATERIALS AND METHODOLOGY:

Study was conducted after receiving the institutional ethics committee approval. Patients undergoing elective tympanoplasty in inpatient department of ENT in were screened and the study was conducted between 2019 –2021. This is an observational, prospective, cross-sectional study.

Samplesize : 75 Yamane equation (for known population size) margin of error (For 95 % confidence level, Margin rror=0.05).

Inclusion Criteria:

1. Age above15 years of age

2. Unilateral/Bilateral COM mucosal type.

3. Patients undergoing tympanoplasty with or without mastoidectomy

4. Patient willing to give informed consent

Exclusion Criteria :

1. Previous history of surgery of any ear

2. Unsafe chronic suppurative otitis media

3. Patients who have marginal perforation

Methodology :

This is a diagnostic study where all patients with a clinical diagnosis of mucosal COM underwent a detailed clinical examination including otoscopic and microscopic examination and all findings are recorded. Pure tone audiogram was also done. All patients underwent tympanoplasty with or without cortical mastoidectomy under general anesthesia. All patients were operated by well experienced senior surgeons and all intraoperative findings like tympanosclerosis, status of middle ear mucosa, presence of polyps, ossicular necrosis and granulation tissue were noted. In patients who underwent cortical mastoidectomy additional findings like pneumatization of mastoid air cells, status of antrum and patency of aditus were also documented.

Statistical Software:

The Statistical software namely SPSS 22.0, and R environmentver.3.2.2 were used for the analysis of the data and Microsoft word and Excel have been used to generate graphs, tables etc.

RESULTS :

The study group consisted of seventy-five patients with COM – mucosal type. Out of the seventy-five patients, 17 patients were found to have ossicular necrosis during surgery. The various factors which can influence ossicular necrosis were analysed and the following observations were made.

In the present study, the age range was from 15 years onwards. Majority of the patients were in the age group of 21-30 years (34.5%). 29.4% of patients with ossicular erosion were between 21-30 years. 41 patients were females, out of which 52.9 % had ossicular erosion and 34 patients were male out of which 47.1% had ossicular erosion. 39 cases (52%) had unilateral left COM and 32 cases (42.7%) had unilateral right COM,4 cases (5.3%) had bilateral COM.

9 of the 17 (52.9%) cases with ossicular necrosis had COM for >10 years duration and 8 out of 17(47.1%) have COM for 5-10years duration. Among the 58 cases with no ossicular erosion, 52 patients had COM for duration of<10 years.

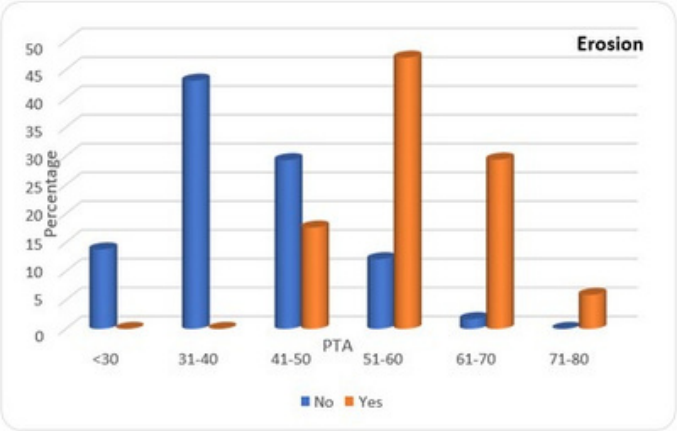

Figure1: PTA-Frequency distribution in relation to erosion

Ossicular necrosis was seen in patients with PTA of more than 40dB hearing loss, with maximum number of cases 8 out of 17 seen around 51-60 dB (47.1%) with a p value of p<0.001, which was statistically significant. Patients with ossicular chain erosion had COM for13.35±5.45 years on an average and patients with no erosion had COM for 5.04 ±4.26 on an average with p value<0.001, which was statistically significant.

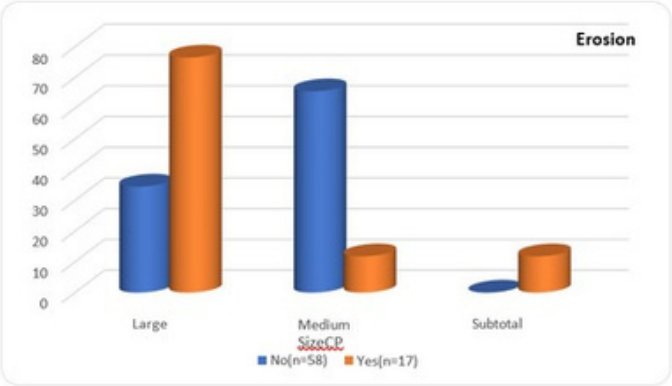

Figure 2: Correlation of size of perforation with ossicular erosion

Most of the cases with ossicular erosion had large central perforation (76.5%) with p <0.001, which is statistically significant. In the present study, 8 (47.1%) patients out of 17 had polypoidal mucosa, all 17 patients had no tympanosclerosis.

Granulation	Erosion	No erosion	total
yes	10(90.9%)	1(9.1%)	11
no	7(10.9%)	57(89.06%)	64
total	17	58	75

Table 1: Ossicular erosion with granulation tissue

It was observed that 90.9% of cases with granulation tissue in the middle ear had ossicular necrosis, whereas only10.9% of those with no granulation tissue seen at the time of surgery had ossicular erosion. A total of 14 cases had erosion of incus out of which the lenticular process was eroded in 9(64.2 %), long process in 3 (21.4%) and the entire incus was eroded in 2 (14.2 %).

DISCUSSION :

Chronic otitis media (COM) refers to chronic infection (more than 12 weeks) of the middle ear cleft in the presence of a persistent TM perforation. Defects of the ossicular chain may occur in all chronic middle ear diseases with or without cholesteatoma. Discontinuity of the ossicular chain is confirmed only during an operation. The ability to predict the presence of ossicular discontinuity in a patient using certain pre-operative factors would be of benefit in allowing the surgeon to plan ahead with regard to the need for an ossiculoplasty and also to give the patient a realistic explanation of the expected outcome. In the present study a total of 75 cases with chronic otitis media–mucosal type was studied out of whom 17 had ossicular necrosis as observed during surgery accounting for 23%. J.Ebenezerand V. Rupa studied a total of 150 patients and found that the incidence of ossicular necrosis was 16% (24patients).

A total of 14 cases had erosion of incus out of which the lenticular process was eroded in 9(64.2 %), long process in 3 (21.4%) and the entire incus was eroded in 2 (14%). According to literature, most commonly the long process of incus and sometimes the stapes superstructure was eroded 6 , 7 ,8. Handle of malleus was found to be eroded in 6 cases and head of stapes was eroded in 2 cases. Tos9 in his study found that incus and stapes were most frequently eroded. He studied 674 cases out of which only 56(8.3%)had necrosis of long process of incus.

The body of incus was eroded in 2 cases and stapes suprastructure in 15 cases. Sade et.al.1 0 found that both malleus and incus could be equally affected.

We found that presence of granulation tissue was associated with ossicular necrosis in 90.9 % of the cases. This was found to be highly significant. This correlates with literature which states that middle ear granulations are known to cause ossicular resorption. Chole and Choo**1 1** found that when the perforation edges adhere to the promontory, it confines the granulation tissue and inflammatory products in small, dead spaces of the middle ear cleft which could lead to significant bone erosion over a period of time. Other studies**1 2 ,1 3** have also proved that granulation tissue is significantly associated with ossicular discontinuity and this possibility increased by 7.95times when the edges of the perforation were adherent to the promontory.

Oedematous mucosa encasing the incus could compromise its blood supply or cause persistence of infection around the vulnerable long process of incus. In the present study, 8 (47.1%) patients out of 17 with ossicular necrosis had polypoidal mucosa. In the study by Jeng et al 8, 76% of patients with ossicular discontinuity had polypoidal middle ear mucosa. Here too, this risk factor was found to be a significant one. We also found out in our most of the cases with ossicular erosion had large central perforation (76.5%) with $p < 0.001$, which is statistically significant. This has not been found significant in either of the studies by Tos 9 and Jeng et al 8. The size of the perforation is determined to some extent by this verity of the initial infection. However, it appears that the extent of damage to the tympanic membrane does not correlate with damage to the ossicles.

CONCLUSION :

Ossicular necrosis is associated with the presence ofmiddle ear granulations and an elevated pure tone audiometric threshold of more than 40-50 dB. All patients withmucosal chronic otitis media can be assessed preoperatively for the indicators of ossicular erosion. This preoperative knowledge can influence the surgical decision and also help the surgeon be prepared for reconstruction of the hearing mechanism or ossiculoplasty.

keywords:

chronic suppurative otitis media, perforation, impedance, ossicular tissue.tympanic membrane erosion, granulation

References :

1. Bluestone CD, Gates GA, Klein JO, et al. 1Definitions, Terminology, and Classification of Otitis Media. Annals of Otology, Rhinology & Laryngology. 2002;111(3_suppl):8-18.

2. Faris C. Scott-Brown's Otorhinolaryngology, Head and Neck Surgery, 7th edn. Ann R Coll Surg Engl. 2011 Oct;93(7):559.

3. Baloh RW. Harold Schuknecht and pathology of the ear. Otol Neurotol. 2001 Jan;22(1):113-122.

4. Thomsen, J., Jorgensen, M.B., Bretlaw, P. and Kirstensen, H.K. (1974) Bone Resorption in Chronic Otitis Media. The Journal of Laryngology & Otology, 88, 975-981.

5. Ebenezer J, Rupa V. Preoperative predictors of incudal necrosis in chronic suppurative otitis media. Otolaryngol Head Neck Surg. 2010 Mar;142(3):415-420.

6 Lin YS, Lin LC, Lee FP, Lee KJ. The prevalence of chronic otitis media and its complication rates in teenagers and adult patients. Otolaryngol Head Neck Surg. 2009 Feb;140(2):165-170.

7. Bernáldez, P.C., Morales, G., & Hernandez, C.M. (2005). Chronic Suppurative Otitis Media in HIV - Infected Children. Otolaryngology-Head and Neck Surgery, 133.

8. Jeng FC, Tsai MH, Brown CJ. Relationship of preoperative findings and ossicular discontinuity in chronic otitis media. Otol Neurotol. 2003 Jan;24(1):29-32.

9. Tos M. Pathology of the ossicular chain in various chronic middle ear diseases. J Laryngol Otol. 1979 Aug;93(8):769-780.

10. Sade J, Berco E, Buyanover D, Brown M. Ossicular damage in chronic middle ear inflammation. Acta Otolaryngol. 1981 Sep-Oct;92(3-4):273-283.

11. Chole, Richard & Sudhoff, Holger. (2010). Chronic otitis media, mastoiditis, and petrositis. Cummings Otolaryngology: Head and Neck Surgery. 1963-1978.

12. Gulya AJ. Anatomy of the Temporal Bone with Surgical Implications. Otolaryngology–Head and Neck Surgery. 1995;112(5):P165-P165.

13. Borg E, Nilsson R, Engström B. Effect of the acoustic reflex on inner ear damage induced by industrial noise. Acta Otolaryngol. 1983 Nov-Dec;96(5-6):361-369.