Tracheobronchial transplantation with a stem-cell-seeded bioartificial nanocomposite: a proof-of-concept study

Philipp Jungebluth, Evren Alici, Silvia Baiguera, Pontus Blomberg, Béla Bozóky, Claire Crowley, Oskar Einarsson, Tomas Gudbjartsson, Sylvie Le Guyader, Gert Henriksson, Ola Hermanson, Jan Erik Juto, Bertil Leidner, Tobias Lilja, Jan Liska, Tom Luedde, Vanessa Lundin, Guido [illegible] Christoph Roderburg, Staffan Strömblad, Tolga Sutlu, Emma Watz, Alexander Seifalian, Paolo Macchiarini

Summary

Background Tracheal tumours can be surgically resected but most are an inoperable size at the t[illegible] of diagn[illegible] therefore, new therapeutic options are needed. We report the clinical transplantation of the tra[illegible] bronc[illegible] airwa[illegible] with a stem-cell-seeded bioartificial nanocomposite.

Methods A 36-year-old male patient, previously treated with debulking surgery and radi[illegible]n therapy, [illegible] sen[illegible] with recurrent primary cancer of the distal trachea and main bronchi. After complete t[illegible] resection, t[illegible]way was replaced with a tailored bioartificial nanocomposite previously seeded with auto[illegible]ous b[illegible] marrow mononuclear cells via a bioreactor for 36 h. Postoperative granulocyte colony-stimulating factor filgrastim [illegible]ug/kg) and epoetin beta (40 000 UI) were given over 14 days. We undertook flow cytometry [illegible]ng electron [illegible]oscopy, confocal microscopy epigenetics, multiplex, miRNA, and gene expression analyse[illegible]

Findings We noted an extracellular matrix-like coating and proliferating [illegible]s includin[illegible] CD105+ subpopulation in the scaffold after the reseeding and bioreactor process. There were no m[illegible] com[illegible]tions, and the patient was asymptomatic and tumour free 5 months after transpla[illegible] The bio[illegible]al nanocomposite has patent anastomoses, lined with a vascularised neomucosa, and w[illegible]ba[illegible]ered by nearly healthy epithelium. Post-operatively, we detected a mobilisation of peripheral cells displ[illegible]g in[illegible]esenchymal stromal cell phenotype, and upregulation of epoetin receptors, antiapoptotic genes, an[illegible]54 and miR-449 biomarkers. These findings, together with increased levels of regenerative-ass[illegible]lasma [illegible]ors, strongly suggest stem-cell homing and cell-mediated wound repair, extracellular matrix re[illegible]ellin[illegible]nd neov[illegible]ularisation of the graft.

Interpretation Tailor-made bioartificial [illegible]affo[illegible] be us[illegible] replace complex airway defects. The bioreactor reseeding process and pharmacologic[illegible]duced s[illegible]ecific and graft-specific regeneration and tissue protection are key factors for successful clinical [illegible]e.

Funding European Commis[illegible]n, Knut an[illegible]ice Wallenberg Foundation, Swedish Research Council, StratRegen, Vinnova Foundation, Ra[illegible]nhemmet, Clin[illegible] EU Network of Excellence, Swedish Cancer Society, Centre for Biosciences (The Live [illegible]imagi[illegible] Unit), and UCL Business.

RETRACTED

Introduction

Primary trach[illegible]ncers [illegible] rar[illegible]eoplastic lesions characteris[illegible]y a h[illegible] morta[illegible]e. The gold standard treatme[illegible]or th[illegible] lesions is surgical resection with prim[illegible] However, epidemiological studies have [illegible]own that, because of difficulties in the definitive [illegible]nosis, most patients with primary malignant trachea[illegible]ncers present with local inoperable disease (exceeding 6 cm or >50% of the total tracheal length) and are, therefore, treated with palliative measures. For these patients, prognosis is poor with a reported 5-year survival rate of about 5%.[2] Moreover, because safe reconstruction of the trachea is not possible, even in patients with operable tumours, the proportion of complete tumour resection is less than 60%.[3] This outcome would be greatly improved if a trachea substitute with similar anatomical, physiological, and biomechanical properties of the native trachea were available.

In 2008, we reported the first fully tissue-engineered tracheal transplantation with a non-immunogenic decellularised human donor trachea reseeded with bone-marrow-derived mesenchymal stem cells (MSCs) and respiratory cells.[4] However, this approach is limited by the shortage of donor organs of an appropriate size and has other disadvantages (webappendix p 9). As a result, an alternative, tailor-made synthetic tracheal scaffold is an urgent clinical need. We report the clinical transplantation of the tracheobronchial airway in a patient with recurrent primary trachea cancer, with use of a tailor-made artificial scaffold reseeded ex vivo with mononuclear cells (MNCs)[5] and a growth factor-induced endogenous stem cells mobilisation.

Methods

The recipient

Webappendix pp 2–9 provides a detailed description of the methods. A 36-year-old man presented in May, 2011, at the Karolinska University Hospital (Huddinge, Sweden) with stridor, cough, and respiratory difficulties. The patient, previously treated elsewhere with tumoral

Lancet 2011; 378: 1997–2004

Published Online November 24, 2011 DOI:10.1016/S0140-6736(11)61715-7

This online publication has been corrected. The corrected version first appeared at thelancet.com on March 3, 2016. The second corrected version appeared at thelancet.com on March 31, 2016.

See Comment page 1977

Advanced Center for Translational Regenerative Medicine (P Jungebluth MD, S Baiguera PhD, Prof P Macchiarini MD), **Cell and Gene Therapy Centre, Department of Medicine, Division of Hematology** (E Alici MD, T Sutlu BSc), **Departments of Medicine and Laboratory Medicine** (G Moll MS, E Watz MD), **Center for Biosciences, Department of Biosciences and Nutrition** (S Le Guyader PhD, Prof S Strömblad PhD), **Linnaeus Center in Developmental Biology for Regenerative Medicine, Department of Neuroscience** (O Hermanson PhD, T Lilja PhD), **Department for Clinical Science, Intervention and Technology** (B Leidner MD), **Department of Cell and Molecular Biology** (V Lundin MS), **and European Airway Institute** (Prof P Macchiarini), **Karolinska Institutet, Stockholm, Sweden; Division of Ear, Nose and Throat** (P Jungebluth, Prof P Macchiarini, G Henriksson MD, J E Juto MD), **Vecura, Clinical Research Center** (P Blomberg PhD), **Division of Pathology** (B Bozóky MD), **Department of Cardiothoracic Surgery and Anesthesiology** (J Liska MD), **Department of Radiology (Huddinge)** (B Leidner MD), **and Department of Clinical Immunology and Transfusion**

Medicine (E Watz), **Karolinska University Hospital, Stockholm, Sweden; Centre for Nanotechnology and Regenerative Medicine, University College London, London, UK** (C Crowley MSc, Prof A Seifalian PhD); **Department of Pulmonology** (O Einarsson MD) **and Department of Cardiothoracic Surgery** (Prof T Gudbjartsson MD), **Landspitali University Hospital, Faculty of Medicine, University of Iceland, Reykjavik, Iceland; Department of Medicine 3, University Hospital RWTH Aachen, Aachen, Germany** (T Luedde MD, C Roderburg MD)

Correspondence to: Prof Paolo Macchiarini, Advanced Center for Translational Regenerative Medicine (ACTREM), European Airway Institute, Division of Ear, Nose and Throat (CLINTEC), Karolinska Institutet, Alfred Nobels Allé 8, Huddinge, SE-141 86 Stockholm, Sweden **paolo.macchiarini@ki.se**

See Online for webappendix

See Online for webvideo

debulking surgery and postoperative regional radiation (70 Gy),[6] presented with a recurrence of a primary tracheal mucoepidermoid carcinoma affecting the distal trachea and both main bronchi (figure 1A). The patient underwent an extensive staging,[1] including ^{18}F-fluorodeoxyglucose (^{18}F-FDG) PET scan, multistage biopsies of the respiratory mucosa proximal and distal to the macroscopic tumour burden, and bone marrow biopsy and aspiration. Results showed no local or distant lymphatic or systemic metastasis, and normal stromal cells. The tumour extended from 5 cm above the right tracheobronchial angle into the first 1·3 cm of the right main bronchus, leaving the origins of the upper and intermedius take-offs tumour free, and the first 1·5 cm of the origin of the left main bronchus (webvideo 1). On the basis of surgical standards,[3] this extension was deemed beyond resectability; therefore a transplant procedure, with an artificial biomaterial, was offered to the patient.

We obtained written informed consent from the patient, and the transplant procedure was approved by the local scientific ethics committee.

Pretransplant preparation

We manufactured a tailor-made trachea from preoperative chest CT and three-dimensional volume rendered images of the patient with a nanocomposite polymer (POSS-PCU; polyhedral oligomeric silsesquioxane [POSS] covalently bonded with [carbonate-urea] urethane [PCU]) through an emulsion-phase-inversion method. On the basis of our previous experience with physical and mechanical properties of human trachea (webappendix p 11)[8] and the patient's preoperative CT scan (figure 1B), we developed a POSS-PCU nanocomposite polymeric airway of appropiate size and morphology, reproducing the exact dimensions of the patient's tracheobronchial structure (webappendix p 1). Y-shaped three-dimensional glass mandrel was fabricated, and ring-shaped rings of POSS-PCU, analogous to the cartilaginous rings of tracheobronchial tissue, were manufactured with casted methodologies and placed around the mandrel. The entire mould was then placed in the POSS-PCU solution to form a coagulated porous scaffold.

A bioreactor to accommodate precisely the maturation requirements of the Y-shaped synthetic windpipe construct used in the transplantation was developed (Hugo Sachs Elektronik-Harvard Apparatus GmbH, March-Hugstetten, Germany; figure 1C, D). The design was based on a sterilisable rotating-construct bioreactor, previously validated but with novel elements to drive a recirculating fluid flow within and around the developing graft,[5] enabling consistent and uniform delivery of cells, nutrients, gases, and hydrodynamic shear forces within the bioreactor. This process is accomplished without external fluid pumps and packaged within the bioreactor assembly so that ease of handling and simplicity of use in good manufacturing practice and clinical environments is not compromised.

Autologous MNCs were obtained 2 days before transplantation from a bone marrow aspirate through density gradient separation. Analyses of white blood cells, mononuclear cells, CD34+ cells, viability, colony-forming unit-fibroblast, flow cytometric characterisation, and sterility were done. To obtain the synthetic bioengineered tracheobronchial construct, cells were resuspended in low glucose Dulbecco's modified Eagle's medium (Invitrogen, Stockholm, Sweden) and seeded onto the synthetic graft by incubation of the construct in the bioreactor for 36 h before transplantation.

Immediately before transplantation, a second bone marrow harvest was done and MNCs were separated and transferred to the operating theatre. Immediately before implantation the airway construct was transported to the operating theatre, reseeded with the obtained MNCs, and conditioned with growth and regenerative factors—namely, recombinant human transforming growth factor-β3 (R&D Systems, Minneapolis, MN, USA; 10 μg/cm²), granulocyte-colony stimulating factor filgrastim (G-CSF, Neupogen; Amgen Europe BV, Breda, Netherlands; 10 μg/kg), and epoetin beta (analogous synthetics of Erythropoietin Roche, Grenzach-Wyhlen, Germany; 40 000 UI). We assessed sections of the graft, surplus to clinical need, by scanning electron microscopy, fluorescence, and bright field light microscopy and confocal live cell imaging (webappendix pp 14–15; webvideo 2).

Transplantation

Under general anaesthesia and orotracheal intubation, a redo sternotomy was done and the tumour-burden area dissected and mobilised, according to the principles of tracheal surgery.[1–3] Because of the previous postsurgical and radiation-induced scar tissue formation, the tumour had to be resected along with the right intrapericardial pulmonary artery, and subsequently revascularised with a Dacron 8F graft (Gelsoft, Vascutek, Terumo, Ann Arbor, MI, USA). The graft was interposed between the retroaortic and the extrapleural origin of the pulmonary artery, clamping both vena cavae for 26 min and without use of cardiopulmonary bypass. Tumour resection included the postlateral and mediastinal aspect of the distal truncus of the superior vena cava via lateral clampage and direct suture. The resected trachea included its distal intrathoracic 6 cm, the entire right main bronchus, and first 2 cm of the left main bronchus. All tumour margins were negative on frozen section, and a complete mediastinal lymph-node dissection was done. The airway was then reconstructed by implantation of the reseeded nanocomposite end-to-end, first to the right and left main bronchi and then to the proximal trachea, with standard techniques.[3] Finally, the omentum major was wrapped around the construct and the median sternotomy and laparotomy closed in a

RETRACTED

RETRACTED

standard manner. From our past experience with carinal surgery when cough reflex, mucous clearance, and patient's full mobilisation are suboptimal in the early postoperative course, a temporary tracheotomy above the implanted graft was made at the end of the procedure.[9]

Regenerative boosting therapy

To enhance the regenerative process, the patient was treated pharmacologically by subcutaneous injections of G-CSF (10 µg/kg) and epoetin-alpha (40 000 UI), with a loading dose given the day before transplantation and every other day for 2 weeks during the postoperative period.

Follow-up assessment

Control endoscopies were done postoperatively daily for the first 7 days, for inspection of the graft and anastomoses. Bronchoscopies were then done once a week during admission to hospital, and once a month thereafter. Postoperative biopsies of the bioartificial graft were assessed by immunohistochemistry, haematoxylin-eosin stain, periodic acid-Schiff stain, and Masson's trichrome stain. Micro-RNA assessment in serum and analyses of soluble factors in plasma (multiplex cytokine assay and ELISA) were done every second day for 2 weeks after transplantation.

Peripheral blood mononuclear cells (PBM[illegible]) wer[illegible] isolated by gradient centrifugation, with [illegible]hop[illegible] (Nyegaard, Oslo, Norway) and wash[illegible] tw[illegible] phosphate-buffered saline (Gibco, [illegible]d Islan[illegible]Y, USA). We assessed cell count and [illegible] assays by [illegible] and trypan blue dye exclusion or [illegible]unter NC-10[illegible] (ChemoMetec A/S, Allerød, D[illegible]mark). We [illegible]ysed gene expression, chromatin im[illegible]oprecipitation, a[illegible]alyses of PBMC subsets and [illegible]otypi[illegible] days before surgery, and for 2 weeks posto[illegible]tivel[illegible]

Statistical ana[illegible]

We under[illegible] da[illegible]analysis [illegible]paration of graphs, and st[illegible]cal c[illegible]parisons with Prism software (Graphpa[illegible]a) and three-dimensional surface mod[illegible] with Microsoft Excel 2010.

Role of the fundin[illegible]urce

The sponsors of the study had no role in study design, data collection, data analysis, data interpretation, or writing of the report. The corresponding author had full access to all the data in the study and had final responsibility for the decision to submit for publication.

Results

The patient was awake 24 h after transplantation. The immediate postoperative course was characterised by a right upper lobe pneumonia (day 2); *Candida albicans* (>10 000 CFU/mL) and *Stenotrophomonas maltophilia* (>10 000 CFU/mL) were isolated and treated with broad spectrum antibiotics and intensive physiotherapy. Other than this complication, the patient improved gradually and was weaned from the mechanical ventilation on day 5 postoperatively.

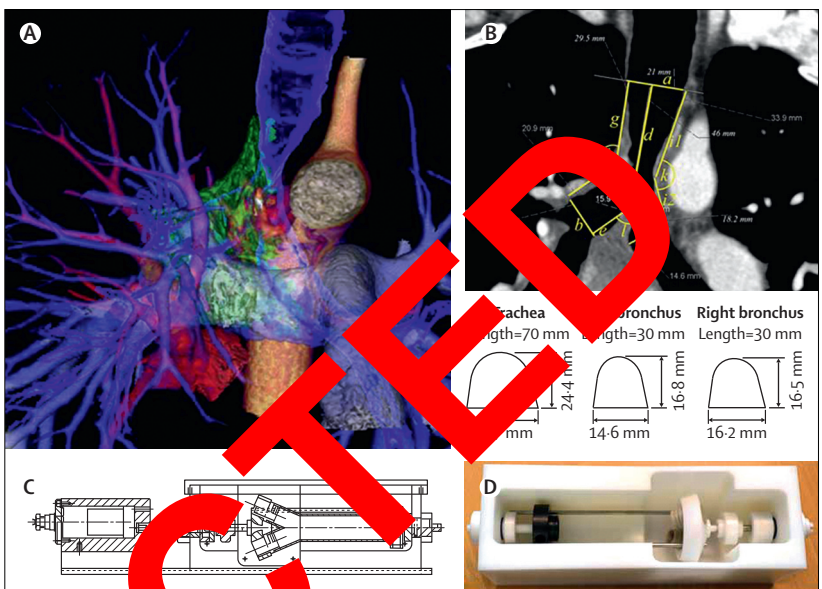

Figure 1: **CT scan a[illegible]ee-dimensio[illegible]olume rendered (VR) images**
(A) Preoperative VR i[illegible]lane i[illegible] Extension of tumour is shown in green. Tracheal and bronchial tree air s[illegible]own in bright [illegible]ge shows the relation between tumour and right main pulmonary artery. ([illegible]ent image. An angulated 2 mm thick CT image is used for measurements for individualised sca[illegible] produ[illegible]mage was optimised for concurrent visualisation of the tumour involvement of trachea inclu[illegible]of ca[illegible]mal bronchi aligned parallel to tracheal longitudinal axis. Yellow lines mark proximal trache[illegible]istal right (b) and left (c) bronchi free from tumour involvement, and measurement of the transve[illegible]men diameters. Sagittal diameter was calculated from angulated transverse image perpendicular to the cent[illegible]men line (not shown). (d) Trachea free from tumour (carina); (e) right bronchus free from tumour (carina); ([illegible] bronchus free from tumour (carina); (g) trachea free from tumour, angle of trachea and right main [illegible] (h) angle of trachea and right main bronchus, right main bronchus free from tumour; (i) 1+2 [illegible]onding left side measurements; (j) angle of trachea and right bronchus; (k) angle of trachea and left bronchus; (l) carinal angle. (B, bottom) Cross section of mandrel for (a) trachea, (b) left bronchus, and (c) right bronchus. (C) Frontal cutaway view of the improved bioreactor. (D) Macroscopic view showing bioreactor without the lid.

1 week after surgery, the bronchoscopy (webvideo 3, figure 2A) showed a normal and patent airway bleeding from its inner layer at the contact with the scope; the obtained biopsy samples showed the presence of necrotic connective tissue associated with fungi contamination and neoformed vessels (figure 2B). The temporary tracheotomy cannula was removed 18 days later. The patient was then transferred to a normal ward and discharged to the referral hospital 1 month after surgery. The biopsy sample 2 months after transplantation showed large granulation areas with initial signs of epithelialisation and more organised vessel formations, and no bacterial or fungi contamination (figure 2B). The patient was discharged from the referring hospital to start rehabilitation and later resumed his university studies. 5 months after transplantation, the patient is asymptomatic, breathes normally, is tumour free, and has an almost normal airway (figure 2C) and improved lung function compared with preoperatively (table, webappendix p 16).

RETRACTED

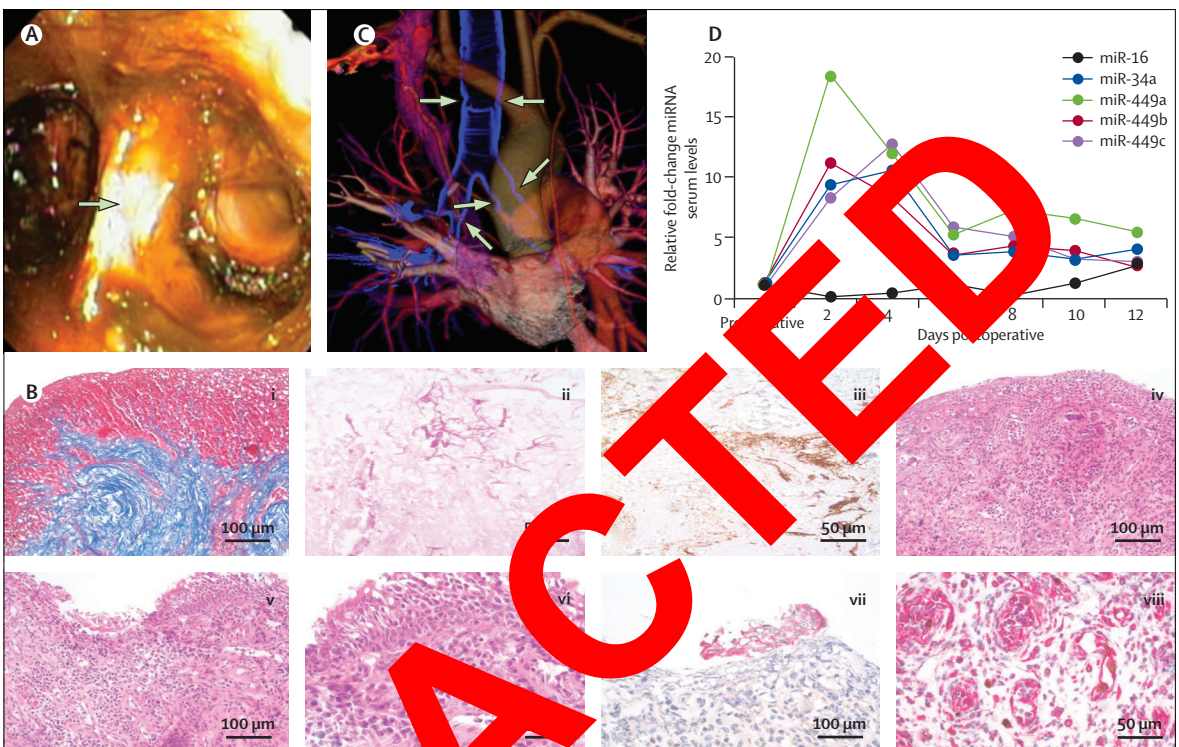

Figure 2: **Postoperative follow-up**

(A) Bronchoscopy image showing the [illegible] plant[illegible] engineer[illegible] [illegible]struct integrated with surrounding tissues. (B) Histological evaluation (Masson) of the first postoperatively obtained biopsy s[illegible] (at day 7) [illegible]n the distal [illegible] of the graft showed necrotic connective tissue (i) with fungi contamination (periodic acid-Schiff stain; ii) but developed vascular s[illegible]e (CD1[illegible] [illegible] Polym[illegible] Refine Detection brown colour; NGFR with Bond Polymer Refine Red Detection red colour [without stained structures]; immun[illegible] belling[illegible] [illegible]ax automated immunostainer; iii). By contrast, the follow-up biopsy at 2 months (haematoxylin-eosin stain) showed ulceratio[illegible] granulati[illegible]e (iv) and still inflammation, but also respiratory epithelium with mucus secreting cells (haematoxylin-eosin stain; v and vi). Additionally, P63-DA[illegible]7 staining show[illegible]ached metaplastic squamous epithelium (red; vii) and Mib1-DAB/Vimentin staining showing proliferating (brown) endothelial struct[illegible]llaries. (C) Postop[illegible] volume rendered (VR) image. Air in airways is shown in bright blue. Note that the VR technique displays only the factual air and [illegible]e sca[illegible]aterial. Yellow ar[illegible]ws show borders for scaffold insertion. (D) Serum levels of miR-16, miR-34, miR-449b, and miR-449c were measured by quantit[illegible]e PCR in serum [illegible]s gained at the indicated timepoints before and after surgery.

	May, 2011 (before surgery)	October, 2011 (4 months after surgery)
FV[illegible]	3·80	2·63
FEV_1 (L)	1·52	1·95
FEV_1:FVC (%	40·02%	74·37%

[illegible]d vital capacity. FEV_1=forced expiratory volume in 1 s.

Table: **Lung function tests**

Analyses by micro-RNA expression have shown that serum levels of miR-34 and miR-449 members are potential biomarkers for promotion of terminal differentiation of airway epithelium.[10] Compared with preoperative levels, we noted upregulation 2 days after transplantation, which gradually decreased (figure 2D). By contrast, serum levels of miR-16—a ubiquitous miRNA frequently used for normalisation of serum miRNA levels[11]—remained unchanged.

The autologous bone marrow MNCs were seeded on the synthetic graft and incubated in the bioreactor (webappendix p 14), resulting in a bioengineered tracheobronchial construct suitable for transplantation (webappendix p 17). Scanning electron microscopy of cells incubated in the bioreactor and confocal microscopy of live cells statically exposed to the biomaterial identified cells of different morphologies inside the scaffold, including long processes, filopodia, and lamellipodia (webappendix pp 16–17), whose formation requires anchorage to the scaffold. Although a shortage in material prevented us from undertaking a thorough analysis of cell division, some of the observed cells seemed to be newly divided (webappendix p 17) and cells exposed to the bioreactor aggregated in dense clusters, suggesting clonal expansion. Staining with the CD105 marker showed a subpopulation of cells of mesenchymal lineage (webappendix p 17). Flow cytometric phenotyping of the bioreactor medium showed a selective reduction of MSCs and haemopoietic stem cells (HSCs) after the reseeding process, with a particular decrease in CD90 high and CD59 dim cells (webappendix p 17), suggesting their preferential attachment and engraftment to the scaffold.

Monitoring of patient cell counts and plasma markers showed formation of typical acute phase reactants,

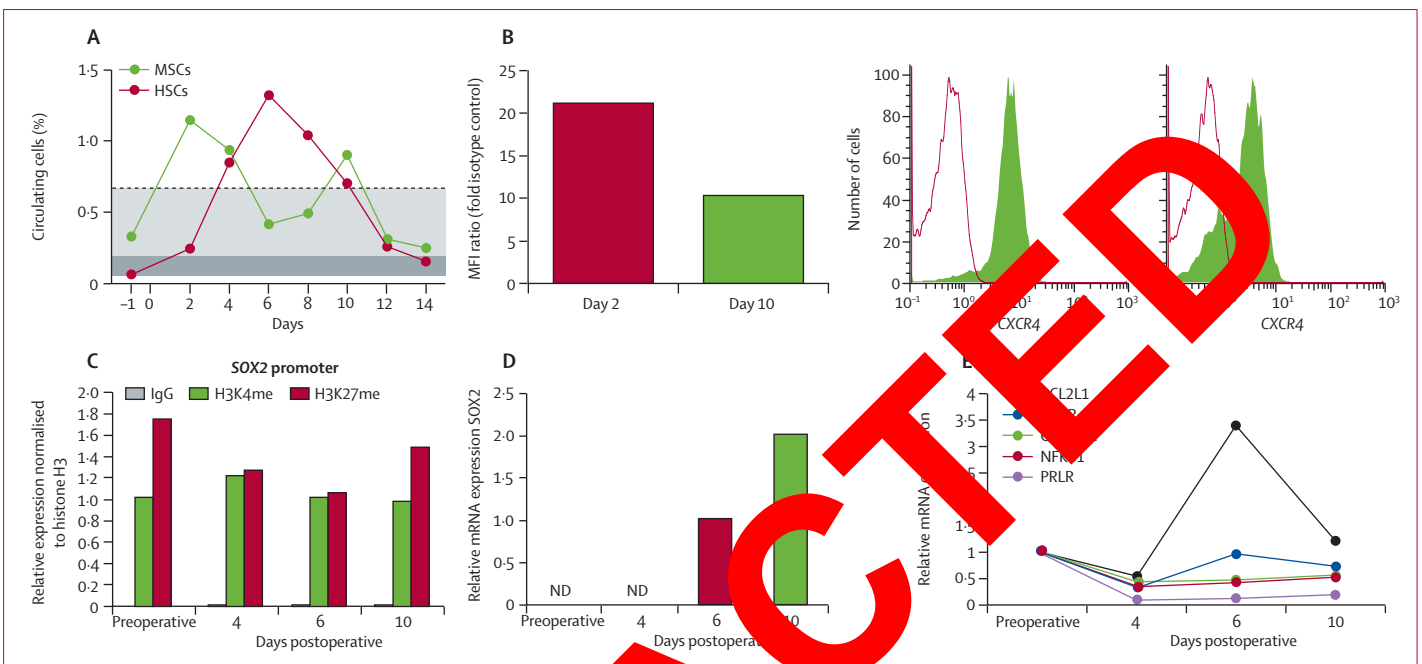

RETRACTED

Figure 3: **Analysis of peripheral blood mononuclear cells after surgery (flow cytome[illegible]ion, and epigenetic regulation)**
(A) Dynamics of circulating MSCs and haemopoietic stem cells (HSCs) as analysed by high [illegible]lution [illegible]try. MSCs in circulation reached a peak level 2 days after surgery and subsequently decreased, and thereafter reached a secondary peak at day 10. The detection ranges from fo[illegible]ealth[illegible]ched for age and sex (male donors aged from 32–39 years, randomly selected at the Karolinska Institutet, Stockholm, Sweden) are shown in light grey. The per[illegible]e of circula[illegible]increased and reached to a plateau at day 6 but then rapidly decreased to normal levels at day 14. Reference ranges assessed from four donors are shown in dark grey. (B[illegible]f CXCR4 [illegible]ulating MSCs on days 2 and 10 as acquired by flow cytometry. Left panel: comparison of mean fluorescence intensity (MFI) ratios on days 2 and 10. Right and cent[illegible]els: red[illegible]s indicate [illegible]e controls and green histograms indicate MSCs. (C) Quantitative PCR results after chromatin immunoprecipitation procedure using antibodies against histo[illegible] for norm[illegible]tion), trimet[illegible]ted lysine 4 (H3K4me3), and trimethylated lysine 27 (H3K27me3) on histone 3 at the promoter regions of the gene *SOX2*. (D) Expression of the SOX2 gene relati[illegible]APDH[illegible]itative RT-PCR. (E) Fold change of genes with antiapoptotic function, relative to the preoperative condition, analysed by quantitative RT-PCR array. ND=no[illegible]ectab[illegible]

wounding, tissue remodelling, [illegible] reg[illegible]ative factor[illegible] after surgery (webappendix [illegible]18–19). We[illegible]ndix p 19 shows results of a heat[illegible]p analysis wit[illegible] exact kinetics and numeric[illegible]values [illegible] individual factors. Findings from a flow [illegible]metri[illegible]alysis of the peripheral blood showed an incre[illegible] HSCs [illegible]day 6, with a particular in[illegible] of [illegible]CD[illegible] subpopulation (webappen[illegible]pp 20[illegible]1). We [illegible]n increased amount of circul[illegible]g MSC[illegible] day 2, to 1[illegible]-fold higher levels than the age an[illegible]y donor range (figure 3A), possibly as a [illegible]t of the boosting therapy before surgery; this increase wa[illegible]owed by a three-fold decrease at day 4 and 6, to show a se[illegible]dary two-fold increase at day 10. In line with these findings, the relative gene expression of homing-associated factor SDF-1 receptor CXCR4 was two-fold higher in MSCs at day 2 than at day 10 (figure 3B).

We then undertook a molecular analysis of the stem-cell phenotype. Chromatin immunoprecipitation showed that the *SOX2* gene, encoding a progenitor-associated transcription factor, showed stable concentrations of the H3K4me3 activity mark throughout the postoperative analysis. However, the H3K27me3 repressive mark was decreased in samples retrieved 4 and 6 days after surgery, showing an increased activity and decreased repression at these timepoints (figure 3C). Accordingly, this increased total activity preceded an induction of SOX2 gene expression at day 6 and a further increase at day 10 (figure 3D). Another progenitor-associated gene, GNL3, also displayed an increasing ratio of active and repressive marks H3K4me3 and H3K27me3 at day 6, correlating with increased gene expression (data not shown). These results on chromatin state and gene expression lend support to the flow cytometric analysis indicating a second wave of circulating MSCs (figure 3A, webappendix p 20).

We investigated the expression in PBMCs of genes involved in the JAK/STAT pathway—a major signalling transduction pathway activated by epoetin beta. Most genes showed a consistent trend of downregulation at day 4 postoperatively, compared with the preoperative condition, with subsequent progressive recovery of the expression levels at days 6 and 10 (webappendix p 22). Analysis of antiapoptotic genes showed a peak in the expression of BCL2L1 and EPOR at day 6, suggesting increased antiapoptotic activity in PBMCs at that time (figure 3E).

Discussion

Findings from this proof-of-concept case study show the feasibility of tracheal transplantation with an artificial nanocomposite reseeded with autologous stromal cells.

RETRACTED

Panel: Research in context

Systematic review

We searched Medline and PubMed without date or language restrictions for articles with the following terms: "trachea", "tracheal replacement", "tracheal cancer", "tracheal surgery", "transplantation", "stem cells", "cell mobilization", "tissue engineering", "scaffold", and "synthetic material". We identified several relevant articles showing challenges and outcome of tracheal reconstruction and replacement, published between 1997 and 2011.[3,4,9,10,20,21,23–25] However, we could not locate any report showing the successful transplantation of a cell-seeded synthetic scaffold-based tracheal transplantation in human beings. Moreover, we identified no publication showing detailed insights into active stem-cell mobilisation in tracheal transplanted patients.

Interpretation

Our study is the first to describe a successful transplantati of a synthetic-based stem-cell seeded scaffold in a patien Our data were collected from preoperative and postopera in-vivo measurements and in-vitro studies. We applied complementary methods to confirm findin n though we now describe only one case of tissue-eng eal transplantation, the magnitude of data and t alidat a specific mechanism suggest solid evidence. O findings are verified and discu sively i on to earlier findings from indep nt inv gators. I over, our data provide novel i ts into lar pathwa s.

We have shown the ibility of stem-cell mobilisati and dynamic patterns and profile of monon lear cells peripheral blood circulation. Des much progres the clinical translation of ti e engi red organs and complex tissues,[12,13] no safe suit e solution has been identified to successfully re the tra .[14,15] With a human decellularised trach natri epopulated with in-vitro expanded and ifferent autologous chondrocytes of MSC origin and autologous epithelial cells via a novel bioreactor the first-in-man completely tissue-engineered trachea replacement was successfully done.[5] This strategy, improved by intraoperative graft seeding with autologous cells (bone marrow MSCs and respiratory cells) and conditioning with differentiation and tissue-protective factors,[16] was subsequently successfully used in patients with both benign and malign airway diseases. However, this approach has limitations—eg, a long period for the decellularisation process (15–20 days), the need for different patient-specific sizes, the risks for altering long-term natural matrix mechanical properties, bacterial contamination during the in-vitro natural graft manipulation, and, most importantly, the absolute requirement of obtaining a donor organ.

The primary tumour of our patient involved the last 5 cm of the distal trachea along with the tracheobronchial bifurcation, which represents an absolute contraindication to any surgical resection. Because the patient had a tumour recurrence with severe stridor, despite 70 Gy of radiation therapy, and the waiting time for a donation would have been unpredictable, we decided to attempt a curative surgery by replacement of t d airway with an artificial POSS-PCU-based ocompo ombined with a novel pharmacological ting strateg This decision was based on the fac at the S-PCU i ocompatible, non-toxic, non-bi gradable, has negligible immunoreacti . Add nally, plays mechanical properties, i ch cal stability, and nanostructural features whic oach th eal for a bioengineered trach mplant. A it is ent specific, since it could be ed to replac only the trachea but also the nchi, a combination of both. Lastly, it can be produced i pid and clinically appropriate timeframe.

Previous at ts to replace the airways of patients with tracheal cancer with synthetic materials have been unsu sful because of graft's limited cell seeding, infec , migration, stenosis, necrosis, and ultimately dea f the patients.[4] These drawbacks are clearly related e fact that the trachea is not located in a mesenchymal environment, but is in direct contact with the breathing air, making infection and contamination more likely to occur. Thus we used a bioreactor environment to reseed the bioartifical scaffold with autologous mononuclear cells. Results showed that 36 h of dynamic incubation of the mononuclear cells in the bioreactor was sufficient for them to adhere to the biomaterial. 2 days after seeding, the cells exposed to the bioreactor formed dense clusters, whereas those statically incubated were more evenly distributed (webappendix p 17), indicating that the bioreactor might help nested cells to proliferate. Antibody labelling and morphological analysis showed the presence of proliferating CD105+ cells with mesenchymal but not haemopoietic phenotype within the graft. Although an extracellular matrix (ECM)-like structure was observed on the scaffold (webappendix p 17) after the reseeding and bioreactor process, whether this structure is related to the autologous serum or the production of ECM by engrafted cells is unclear.

The most frequently reported airway complications after lung transplantation are necrosis, dehiscence, and stenosis, probably related to ischaemia of the transplanted bronchus during the immediate period after transplantation.[20–22] In this report, an avascularised, Y-shaped nanocomposite was implanted and the initial fungal infection had resolved within 4 months from transplantation; later the endoluminal surface was partly lined with respiratory mucosa, at which we noted nearly healthy epithelium and proliferating endothelium. This finding provides evidence that a bioengineered synthetic tracheobronchial nanocomposite can be recellularised in vivo with site-specific cells to become a living and functional scaffold completely integrated into the adjacent tissues. The measured levels of miR-34/449

micro-RNAs, which have been proposed as potential biomarkers of terminal differentiation of airway epithelium,[10] suggest the presence of postoperative airway epithelial differentiation in the patient.[11]

One of the key issues in a synthetic transplantation setting is the recruitment of repair cells that promote the integration and remodelling of the newly transplanted material. The cellular components contributing to regeneration can be recruited either from local tissue or from circulating progenitor cells. We observed HSC mobilisation together with increased amounts of circulating MSCs, which contrasts with previous findings[23] of no mobilisation of MSCs, when G-CSF was used as mobilising agent alone. Indeed, surgery-induced inflammation and chemokine and anaphylatoxin release at the implantation site could be the reason for the observed MSC mobilisation in our patient. We detected release of a large array of soluble mediators associated with wound healing, which could promote MSC mobilisation, as previously reported by other investigators.[24,25] Additionally, G-CSF induced neutrophil expansion, and release of proteases, which we also detected, could have promoted progenitor mobilisation.[26] Progenitor mobilisation presumably occurs by weakening their anchoring within the niche, either by degradation of the anchoring ECM components or their retention factor SDF-1a itself.[26] Bone [illegible] progenitor cell activation, recruitment, tiss[illegible] repair and local immune suppression at the surge[illegible]te co[illegible] be enhanced by blood activation pr[illegible]cts, [illegible]as C3a and thrombin,[26–28] which were fo[illegible]d upon s[illegible]ld implantation. We detected a stro[illegible]emic releas[illegible] growth factors and matrix m[illegible]opr[illegible]ases, which are probably produced by re[illegible]ited progen[illegible] and other immune cells. Furtherm[illegible], we recorded a [illegible]tantial and very early increase [illegible]e epo[illegible]-receptor expression with simultaneous u[illegible]ulati[illegible] of antiapoptotic genes, such as *BCL2L1*. During [illegible]mation[illegible]uma cytokines are released [illegible]upreg[illegible] e[illegible]n receptors but inhibit tis[illegible] pro[illegible]ion by [illegible]regulation of local epoetin [illegible]ductio[illegible] and antiapoptotic downstream pathways, [illegible]ptosis. To avoid this early postoperativ[illegible]ence of local epoetin production, we administered r[illegible]erative (500 UI/Kg) epoetin doses, aiming to favour a[illegible]trigger early local tissue protection and regeneration.

Taken together, these results provide evidence that a successful organ regeneration strategy has been accomplished (panel). The successful overall clinical outcome of this first-in-man bioengineered artificial tracheobronchial transplantation provides ongoing proof of the viability of this approach, in which a cell-seeded synthetic graft is fabricated to patient-specific anatomical requirements and incubated to maturity within the environment of a bioreactor. Additionally, in-depth cellular biochemistry analyses have provided new insight into the mechanisms by which the so-called pharmacological boosting factors contribute to cell mobilisation, differentiation, and ultrastructural organisation of the fully engrafted tracheobronchial construct.

Contributors

PJ was responsible for the bioreactor-based cell seeding; assisted the surgery and with collection of secondary data; and wrote corresp[illegible] methods, results, and interpretation sections. EA and TS unde[illegible] all flow cytometry characterisation of the cells, interpreted the [illegible]s, and wrote corresponding methods. SB provided preclinical data r[illegible]an tracheal biomechanics, and helped to write the report[illegible]M desig[illegible] undertook, and assessed the multiplex analyses an[illegible]te corresp[illegible] methods. PB organised and supervised standar[illegible] the good manufacturing practice facility. BB did histo[illegible]l evalua[illegible]CC and AS designed and developed the three-dimens[illegible]nap[illegible]posite trachea, and wrote corresponding met[illegible] OE [illegible]re respon[illegible] for the clinical follow-up of the pati[illegible]d provide[illegible]y ma[illegible] and blood samples; TG also particip[illegible] the surgery an[illegible] corresponding methods. JL as[illegible]rgery. SLG and [illegible]d all cell imaging and wrote correspon[illegible]g meth[illegible]OH and TL undertook and assessed all epigenetic analyses and wrote [illegible]ponding methods. JEJ and GH assisted in [illegible]erative and post[illegible]ive care. BL did all radiological imag[illegible]nterpretation, and three-d[illegible]ensional reconstruction, [illegible] wrote corresponding methods. TL and CR undertook and a[illegible]sed the miR[illegible]dies, and wrote corresponding methods. VL und[illegible]k and analys[illegible]ene expression experiments, and wrote correspondi[illegible]thods. E[illegible]lated the mononuclear cells. PM wa[illegible]e primary inve[illegible]ding author of the report, indicated [illegible]he three-dim[illegible]nal nanocomposite, was leading surgeon an[illegible] for the preoperative and postoperative course, and ove[illegible] the re[illegible]s. All authors provided primary data for mod[illegible]rios, and assisted with interpretation of results and report[illegible]n.

Conflicts [illegible]terest

We decla[illegible]at we have no conflicts of interest.

[illegible]edgments

The European Commission (FP7 EU Project: 280584-2BIOtracheaCP-FPFP7-NMP-2011-SMALL-5), the Knut and Alice Wallenberg Foundation, Swedish Research Council, and the StratRegen funded preclinical and postoperative in-vitro studies, gene expression, cell characterisation, and imaging. The Vinnova Foundation, Radiumhemmet, and Clinigene EU Network of Excellence funded multiplex and flow cytometric analyses. The Swedish Cancer Society supported the epigenetic studies. The Centre for Biosciences, the Knut and Alice Wallenberg Foundation, and the Swedish Research Council supported the Live Cell imaging Unit at the Department of Biosciences and Nutrition, Karolinska Institutet, used for live cell imaging. ERC-2007-Stg/208237-Luedde-Med3-Aachen funded the miRNA studies. The UCL Business supported the development of the three-dimensional nanocomposite scaffold. We thank all the health professionals of the Karolinska University Hospital in Huddinge, Stockholm, Sweden, without whom the transplantation could not have been done; Harvard Apparatus (Hollison, MA, USA) and Hugo Sachs Elektronik-Harvard Apparatus GmbH (March-Hugstetten, Germany) for supporting us with the bioreactor and the supervision of its use; Peter Güntner, for image analysis and measurements for scaffold production, and Anders Svensson, for three-dimensional volume image rendering, both from the Department of Radiology, Karolinska University Hospital Huddinge, Stockholm, Sweden; all the staff of the Landspitali University Hospital in Reykjavik, for the excellent support with the preoperative and postoperative care of the patient; Alessandra Bianco and Costantino Del Gaudio from Department of Science and Chemical Technologies, Intrauniversitary Consortium for Material Science Technology (INSTM), Research Unit Tor Vergata, Rome, Italy, for bi-dimensional and three-dimensional mathematical model for tracheal lateral area assessment; Iyadh Douagi from the Center of Hematology and Regenerative Medicine, Department of Medicine, Karolinska Insitutet for his assistance with flow cytometry; and Ulrika Felldin from ACTREM, Karolinska Institutet for her assistance with cell isolation.

RETRACTED

RETRACTED

References

1 Macchiarini P. Primary tracheal tumours. *Lancet Oncol* 2006; **7:** 83–91.

2 Gaissert HA, Burns J. The compromised airway: tumors, strictures, and tracheomalacia. *Surg Clin North Am* 2010; **90:** 1065–89.

3 Grillo HC. Primary tracheal tumours. In: HC Grillo, ed. Surgery of the trachea and bronchi. Hamilton: BC Decker, 2004: 791–802.

4 Macchiarini P, Jungebluth P, Go T, et al. Clinical transplantation of a tissue-engineered airway. *Lancet* 2008; **372:** 2023–30.

5 Go T, Jungebluth P, Baiguera S, et al. Both epithelial cells and mesenchymal stem cell derived chondrocytes contribute to the survival of tissue-engineered airway transplants in pigs. *J Thorac Cardiovasc Surg* 2010; **139:** 437–43.

6 Sigurdsson MI, Sigurdsson H, Hreinsson K, Simonardottir L, Gudbjartsson T. Bronchiovenous fistula causing bleeding and air embolism: an unusual complication of bronchoscopic tumor resection. *Am J Respir Crit Care Med* 2011; **183:** 681–82.

7 Ahmed M, Ghanbari H, Cousins BG, Hamilton G, Seifalian AM. Small calibre polyhedral oligomeric silsesquioxane nanocomposite cardiovascular grafts: influence of porosity on the structure, haemocompatibility and mechanical properties. *Acta Biomater* 2011; **7:** 3857–67.

8 Baiguera S, Jungebluth P, Burns A, et al. Tissue engineered hu[illegible] tracheas for in vivo implantation. *Biomaterials* 2010; **31:** 8931–[illegible]

9 Macchiarini P, Altmayer M, Go T, et al. Technical innovation[illegible] carinal resection for nonsmall-cell lung cancer. *Ann Thorac [illegible]* 2006; **82:** 1989–97.

10 Lizé M, Herr C, Klimke A, Bals R, Dobbelstein M. MicroRNA-[illegible] levels increase by several orders of magnitude [illegible]ing mucociliary differentiation of airway epithelia. *Cell Cycle* [illegible]–83.

11 Bihrer V, Friedrich-Rust M, Kronenberger B, e[illegible] Ser[illegible]22 as a biomarker of necroinflammation in patien[illegible]th chr[illegible] hepatitis C virus infection. *Am J Gastroenterol* 20[illegible]06; [illegible]–69.

12 Atala A, Bauer SB, Soker S, Yoo [illegible] AB. Tiss[illegible]neered autologous bladders for patie[illegible]ystoplast[illegible]*ncet* 2006; **367:** 1241–46.

13 Pham C, Greenwood J, [illegible]d H, W[illegible]uff P, Madd[illegible] G. Bioengineered skin subst[illegible] for [illegible]f burns: a systematic revie[illegible]*rns* 2[illegible]46–57.

14 Behrend M, Kl[illegible], Von Wasi[illegible]i R, Klempnauer J. The mecha[illegible]luence of tissu[illegible]neering techniques on trache[illegible]n experimenta[illegible]y on sheep trachea. *J Invest S[illegible]g* 2002; [illegible]7–36.

15 Gil[illegible]TW, Gilbert S, [illegible]en M, Reynolds SD, Badylak SF. M[illegible]nologic assessment [illegible]racellular matrix scaffolds for patch [illegible]cheopla[illegible]y in a canine m[illegible]el. *Ann Thorac Surg* 2008; **86:** 967–74.

16 Bader A, Macchiarini P. Moving towards in situ tracheal regeneration: the bionic tissue engineered transplantation approach. *J Cell Mol Med* 2010; **14:** 1877–89.

17 de Mel A, Punshon G, Ramesh B, et al. In situ endothelialization potential of a biofunctionalised nanocomposite biomaterial-based small diameter bypass graft. *Biomed Mater Eng* 2009; **19:** 317–31.

18 Seifalian AM, Salacinski HJ, Tiw[illegible]ls A, Bowald S, Hamilton G. In vivo biostabili[illegible] poly([illegible]te-urea) urethane graft. *Biomaterials* [illegible], **24:** 2549–5[illegible]

19 Kannan RY, Salacinski HJ, [illegible]PE, Seifalian [illegible] Polyhedral oligomeric [illegible]ilsesqu[illegible]e nanocomp[illegible]es: the next generatio[illegible]erial for [illegible]dical ap[illegible]tions. *Acc Chem Res* 20[illegible]8: 879–84.

20 Kshettry VR, [illegible]nus TJ, [illegible]z MI, H[illegible]W, Shumway SJ, Bolman R[illegible] Early a[illegible]e airway co[illegible]plications after lung transpl[illegible]tatio[illegible] and ma[illegible]ement. *Ann Thorac Surg* 1997; [illegible]576–8[illegible]

21 S[illegible]ruz JF, Meh[illegible] Air[illegible]omplications and management [illegible]g transplanta[illegible]emia, dehiscence, and stenosis. *[illegible]roc[illegible]Thorac Soc* 2009; [illegible]9–93.

22 Puchal[illegible]ee HJ, Sterman DH. Airway complications following [illegible]ransplantation. *Clin Chest Med* 2011; **32:** 357–66.

23 Pitchford SC, [illegible] RC, Jones CP, Wengner AM, Rankin SM. Differential mo[illegible]ization of subsets of progenitor cells from the bone marrow. *Cell Stem Cell* 2009; **4:** 62–72.

24 M[illegible]lla E, Marin GH, Drago H, et al. Bloodstream cells p[illegible]typically identical to human mesenchymal bone marrow s[illegible]cells circulate in large amounts under the influence of acute [illegible]e skin damage: new evidence for their use in regenerative medicine. *Transplant Proc* 2006; **38:** 967–69.

25 Hannoush EJ, Sifri ZC, Elhassan IO, et al. Impact of enhanced mobilization of bone marrow derived cells to site of injury. *J Trauma* 2011; **71:** 283–91.

26 Marquez-Curtis LA, Turner AR, Sridharan S, Ratajczak MZ, Janowska-Wieczorek A. The ins and outs of hematopoietic stem cells: studies to improve transplantation outcomes. *Stem Cell Rev* 2011; **7:** 590–607.

27 Schraufstatter IU, Discipio RG, Zhao M, Khaldoyanidi SK. C3a and C5a are chemotactic factors for human mesenchymal stem cells, which cause prolonged ERK1/2 phosphorylation. *J Immunol* 2009; **182:** 3827–36.

28 Moll G, Jitschin R, von Bahr L, et al. Mesenchymal stromal cells engage complement and complement receptor bearing innate effector cells to modulate immune responses. *PLoS One* 2011; **6:** e21703.