If using NGT tube with a guidewire or introducer, leave guidewire in place until x-ray taken to improve tube visibility but remove and dispose of after correct position confirmed and documented.

- Put NOTHING down the tube before x-ray interpreted (not even water to release the guidewire).
- X-ray should be interpreted by person competent in the 'four criteria.'

ASSESS WHETHER THE TUBE IS FULLY RADIOPAQUE THROUGHOUT ITS LENGTH AND TIP WITH REGULAR CM MARKINGS

YES → CAN YOU SEE THE TUBE ON CHEST X-RAY?

NO → RADIOLOGY MAY NOT BE BENIFICIAL **DO NOT FEED**

CAN YOU SEE THE TUBE ON CHEST X-RAY?

YES → IS THE PATIENT ROTATED ON X-RAY?

NO → HAS THE TUBE COME OUT? IS IT COILED IN THE MOUTH/PHARYNX? **DO NOT FEED**

IS THE PATIENT ROTATED ON X-RAY?

I DON'T KNOW → SEEK SENIOR ADVICE

YES → ARE YOU HAPPY TO TAKE PATIENT ROTATION INTO ACCOUNT

NO → **DOES THE TUBE PATH FOLLOW THE OESOPHAGUS/AVOID THE CONTOURS OF THE BRONCHI?**

ARE YOU HAPPY TO TAKE PATIENT ROTATION INTO ACCOUNT

NO → SEEK SENIOR ADVICE

YES → **DOES THE TUBE PATH FOLLOW THE OESOPHAGUS/AVOID THE CONTOURS OF THE BRONCHI?**

DOES THE TUBE PATH FOLLOW THE OESOPHAGUS/AVOID THE CONTOURS OF THE BRONCHI?

NO → REMOVE TUBE **DO NOT FEED**

YES → **DOES THE TUBE CLEARLY BISECT THE CARINA OR THE BRONCHI?**

DOES THE TUBE CLEARLY BISECT THE CARINA OR THE BRONCHI?

NO → REMOVE TUBE **DO NOT FEED**

YES → **DOES IT CROSS THE DIAPHRAGM IN THE MIDLINE?**

DOES IT CROSS THE DIAPHRAGM IN THE MIDLINE?

NO → REMOVE TUBE **DO NOT FEED**

YES → **IS THE TIP CLEARLY VISIBLE BELOW THE LEFT HEMI-DIAPHRAGM?**

IS THE TIP CLEARLY VISIBLE BELOW THE LEFT HEMI-DIAPHRAGM?

NO → REMOVE TUBE **DO NOT FEED**

YES → **PROCEED TO FEED ONLY IF ALL CRITERIA ARE MET.**

IF IN ANY DOUBT REPEAT X-RAY OR CALL FOR SENIOR HELP.

To confirm gastric position of the nasogastric tube, ask:

Does the tube path follow the oesophagus/avoid the contours of the bronchi?

Does the tube clearly bisect the carina or the bronchi?

Does it cross the diaphragm in the midline?

Is the tip clearly visible below the left hemi-diaphragm?

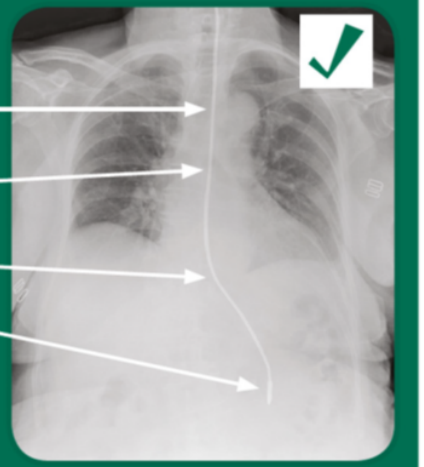

Proceed to feed only if all criteria are met. If in any doubt repeat x-ray or call for senior help.