2022 International Conference on Computational Modelling, Simulation and Optimization (ICCMSO) | 979-8-3503-3288-9/22/$31.00 ©2022 IEEE | DOI: 10.1109/ICCMSO58359.2022.00068

Bone Cancer Detection techniques using Machine Learning

Er. Charnpreet Kaur
Department of Computer Science and Engineering
Chandigarh University
Mohali, India
Charnpreet.cse@cumail.in

Dr. Urvashi Garg
Department of Computer Science and Engineering
Chandigarh University
Mohali, India
urvashi.mittal80@gmail.com

***Abstract*— Bone cancer is one of the prevalent cancers, any fracture or abnormalities (Cancer) need to be predicted at early stage like other cancers because it spreads to the other parts of body or organs is known as metastasis. Bone cancer is also known as Osteosarcoma, which is malignant primitive bone tumor. Bone cancer is of two types primary and secondary where primary bone cancer originates from Bone and spreads to the other parts of body. On the other hand Secondary bone cancer is also called bone metastasis it occurs when cancerous cell spreads from other parts of body towards bone. This paper presents the different types of Bone cancer such as bone sarcoma and bone metastasis and their stages. As different acquisition techniques plays vital role in the detection of the bone cancer or any type of cancer so this work also discussed different image acquisition techniques. Secondly, this work discussed different classification techniques and their comparison for bone cancer detection. This paper discussed regarding the work done in the field of Bone cancer detection using different feature selection, segmentation and classification techniques on different types of images such as MRI, X-ray and CT Scan and also discussed the challenges and opportunities for Bone cancer detection.**

Keywords— Bone cancer Detection, CT, MRI, X-ray

I. Introduction

Bone cancer is an uncommon kind of cancer that is the leading cause of death in many people. A precise approach for the identification and categorization of bone tumors is required to identify cancer at an early stage[1]. X-rays, Computer Tomography, Magnetic Resonance Imaging, and Ultrasound are examples of image acquisition techniques. MRI, in particular, has a high level of accuracy[1][2]. Deep learning is a strong way for classifying and diagnosing medical pictures, and CNN is used to execute it (Convolution Neural Network)[3]. Bone Cancer is categorized into four different stages where in stage1: The tumor is non-aggressive and not spread out of the bone, in stage2: the tumor is activated in nature, in stage3: Tumor start growing to different body parts and in Stage4: tumor spreads to the other body parts[4]. Primary bone tumors (sarcomas) and secondary bone tumors (metastasis) are the two forms of cancer. Primary bone tumors can be benign or malignant, and primary bone cancer starts in the bone, whereas secondary bone cancer spreads from other regions of the body to the bone.[5]. The most common type of sarcomas are osteo-sarcomas, chondro-sarcomas, and Ewing sarcomas[6]. Osteo-sarcomas is prevalent type of bone cancer that most commonly occur on adolescents and young adults[7]. Osteosarcoma is especially prevalent longer bones. It's a very aggressive tumour in which malignant cells build abnormal bone and have a tendency to spread. Chondro-sarcoma is a rare mesenchymal malignancy that looks like cartilage and is characterized by differently differentiated cells that produce chondroid matrix.[8]. Aggressive bone tumours such as osteo-sarcomas and Ewing sarcomas are common in adolescents, but conventional and differentiated chondro-sarcomas primarily affect persons in their middle age.[9]. In children and adolescents, Ewing sarcoma is the second most prevalent malignant bone tumor. It primarily affects people in their 30 years of life and develops as a tiny spherical blue cell tumor. Localized Ewing sarcoma has a five-year survival rate in most cases however patients with pelvic involvement, big tumors, or partial tumor regression following treatment have much poorer results. [8][10][11][12]. Cancer that originates from other regions of the body and spread towards bone is called metastasis bone metastases have a short prediction and a high death rate. This occurs as the illness is rarely curable after tumor cells have taken up residence in the bones. Treatment, on the other hand, is suggested for reducing discomfort and halting its progression. Breast and prostate malignancies, which are more common than sarcomas in the adult population, produce the majority of bone metastases. [13].

II. Types of Bone Cancer

Sarcomas are a form of cancer that includes primary bone tumours. Sarcomas are cancerous tumours that start in the bone, muscles, connective tissue, blood vessels, or fat and spread throughout the body.

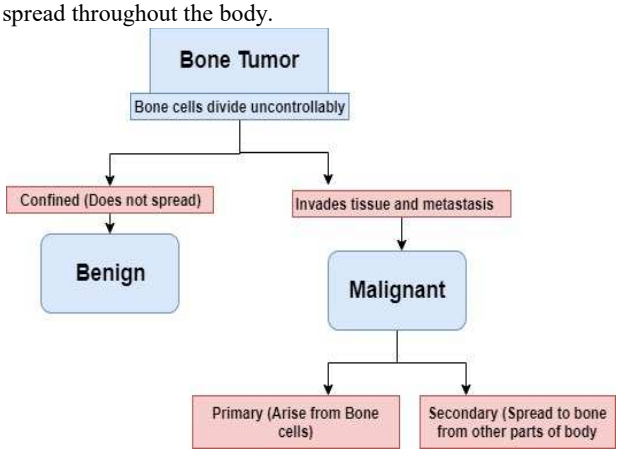

Figure 1: Types of Bone Tumor

Authorized licensed use limited to: UNIVERSIDADE FEDERAL DO PIAUI. Downloaded on September 14,2025 at 16:47:06 UTC from IEEE Xplore. Restrictions apply.

2.1 Osteosarcoma

It is a malignant tumour that initially grows in long bones of body but it can spread to any part of the skeleton. As this cancer is originated from the bone itself so the X-Ray images are more suitable for the detection of osteosarcoma[14]. It mostly affects the children and young adults. Classification of osteosarcoma is done based on its location, tumour grade and involved cell types. X-ray images with high special resolution helpful to display the size, location and the extent of destruction caused by the tumour[15].

2.2 Chondrosarcoma

Chondrosarcoma is common primary bone cancer that mostly grows in cartilage areas of pelvic, humerus and femur. Cartilage is a flexible tissue between the bones and the joints that prevent the bones from rubbing and jerks. Chondrosrcoma is divided into three parts central, periosteal, and peripheral tumours it depend upon the lesion site[16]. Central condrosarcoma usually occur in long bones whereas peripheral tumour occurs in pelvis and vertebrae[17]. As far as the imaging of Chondrosarcoma is concerned, plain film, CT scan and MRI images are used for Chondrosarcoma detection. Plain film is able to depict the tumour, size of tumour and cartilage nature of tumour. CT scan detects the destruction of the bone, calcification (calcium build in the body tissues that cause the hardening of tissues) and extent of benign and malignant. MRI is useful for depicting the stage of tumour, inner region and structure of soft tissues[17].

2.3 Ewing tumor

Ewing sarcoma is highly aggressive and soft tissue bone cancer that can occur in any part of the body. It is usually detected at the second stage and its patients are from new born to late eighties[18]. X-ray, MRI and CT scan can be used for Ewing sarcoma detection. MRI images give the detail tumor visualization (information about structure of tumor) so it works better as compared to X-ray images. The CT images are useful to evaluate the degree of bone destruction[18]. For the Ewing sarcoma staging hybrid PET/CT performs better as compared to PET[19].

2.4 Fibrosarcoma

Fibrosarcoma ia a rare and highly aggressive type of soft tissue sarcoma. This is always challenging to detect this tumour type due to its spindle cell shaped structure. This tumour usually occur either in deep soft tissues or adjacent to bones[20]. CT and MRI images are used for the detection of Fibrosarcoma detection whereas combination of both works well for soft tissues lesion detection[21].

III. Related work

M, Ranjitha M 2019 K mean clustering technique is used for bone image segmentation and by measuring the mean intensity of the indicated area, the image is further processed for bone cancer diagnosis. This dataset used in this work is ultrasound images and also applicable for DIACOM(Digital imaging communication of medicine[23]. Sharma et al. 2021 worked on a edge detection method for classification of healthy and cancerous bone on the basis of two feature sets with hog or another without hog. The SVM (support vector machine) and the RF (Random forest) classification algorithms are used and the results shows that features set with hog provides an F1-score of 0.92 performs better than the random forest[24]. Rachmawati et al. 2020 Image segmentation: This is very essential step before the detection or recognition process. In this process image is divided into four different regions and result of the segmentation process notably influence the results of metastasis process. D. Shrivastava et al. 2020 reviewed several machine learning algorithms for image categorization, including ultrasound, magnetic resonance imaging (MRI), computed tomography (CT), histology, and microscopy. This paper also explored the advantages and disadvantages of several machine learning algorithms. Xia et al., 2018 worked with SVM algorithm for bone tumour detection by using different texture features of x-ray images[25].

IV. Image acquisition techniques for Bone Cancer Detection

A. X-rays

X-ray images are commonly used to capture the inside of the body images by using radiations. X-ray are the most common image acquisition techniques for bone cancer. The technical operation of X-ray is simple and user friendly as single examination of X-ray cause minimal damage to the body. It is affordable by most of the patients and usually reveals the new bone growth and bone affected by the some other reasons. It also detect the symptoms are due to fractured bone or cancer[2][26]. X-ray Examination have several pros and cons as it has low density resolution it do not clearly display the small damage and soft tissue masses and surrounding structure or details of bone[15][27].

B. CT scans

Computed tomography integrates several X-ray pictures to provide detailed cross-sectional views of the body's internal organs. When it comes to displaying the detail in and around bone tumours, CT scans are not always as effective as MRIs. However, they are frequently performed to check for the spread of cancer to other regions of the body, such as the lungs, liver, or other organs[2][28]. CT Images are preferred over other imaging because it has more clarity, less distortion and more reliable. CT images have high spatial resolution and shorter scanning time[29].CT is best imaging method to visualize complex bones and as it works well with soft tissues so it performs effectively for the detection of metastasis. CT has one limitation that it not performs well when the lesion size is less than 5 mm[15].

Authorized licensed use limited to: UNIVERSIDADE FEDERAL DO PIAUI. Downloaded on September 14,2025 at 16:47:06 UTC from IEEE Xplore. Restrictions apply.

C. MRI scans

An MRI is frequently used to provide a more thorough look at a bone abnormality by using magnetic field effect and radio waves. MRI images do not use radiations so it is safe as compared to MRI scan is a significant tool for determining the affected area and spread of any malignant tumor in the bone or around the bones. Small bone tumors that are several inches apart from the primary tumor can also be seen on an MRI (called skip metastases)[26].

D. Bone scans

Bone scan is used to detect the numerous bone conditions such as bone inflation, fracture, and metastasis and bone infections. Bone scan provide the complete information of the bones as compared to X-ray. Radioactive material is injected into patients veins during a bone scan and the portion of bone which is malignant absorbs the material more quickly than the healthy bones. As a result, in scan it provides hot spots on the affected areas [28].

V. Detection Methods

A. Decision Tree Algorithm

This algorithm use supervised learning technique. It is used to determine if the cancer that has been detected is benign or malignant. This algorithm is used in a variety of medical fields for producing stable and effective decisions with high classification accuracy. The divide and conquer method is used to create a decision tree from a set of training items, from root to leaf node; a categorization rule may be derived. The tree is made up of nodes and leaves, with nodes representing attributes or test nodes and leaves representing classes for checking conditions to make a decision. All of the attributes that define each instance are called input data, and one attribute is selected to represent a decision for the problem is called output data[30][31].

B. Support Vector Machine (SVM)

SVM method is used for classification which uses supervised machine learning technique. The purpose of this technique is to find the best line or decision boundary that divides the n-dimensional space (number of features) into classes so that extra data points may be placed in the proper category for decision making. The classification is done by locating the hyperplane that separates the two groups. SVM selects the vectors or extreme points that aid in the creation of the hyperplane; they are referred to as support vectors[31][32][25].

C. Random Forest

It is popular supervised machine learning algorithm that is used for classification. This approach employs the idea of ensemble learning (integrated) technique, which combines the findings of number of classifiers in order to solve a complex problem and improve the performance of model. It comprises a numerous of decision trees on different subsets of provided data sets, and it averages the decision tree outputs to get more accurate results in less time than other classification algorithms. When a considerable amount of the data is missing, it also produces effective outcomes[33][24].

D. Genetic Algorithm

GA is a stochastic and evolutionary approach for finding optimal solutions to huge and complicated problems. GA uses natural selection to create a population of encoded candidates (called "chromosomes") across generations, employing genetic processes such as crossover and mutation. Solutions for generating children and developing the next generation are chosen at each generation based on fitness function. The starting population is created at random, and possible solutions are compared and assessed against an objective function at each generation in order to obtain a fitness function score. The candidate accuracy over the training set is measured using the objective function[33].

E. K nearest neighbour

This technique is based on the supervised learning method and is one of the basic Machine Learning algorithms. It is used for assigning the missing values and the KNN approach assumes that the new data and old cases are compared and place the new case data in the most similar category to the existing categories. The KNN method saves all available data and classifies a new data point based on its resemblance to the existing data. This means that utilising the KNN approach, new data may be quickly sorted into a well defined category. It is also known as a lazy learner algorithm since it doesn't learn from the training set directly instead, it saves the dataset and at the time of classification, it performs an action on the dataset[34][35].

TABLE I COMPARATIVE ANALYSIS OF BONE CANCER DETECTION TECHNIQUES

S.No	Techniques Used	Purpose of work	Dataset used (Image type)	References
1	Feature Extraction: GLCM (Gray Level Co-occurrence Matrix) Classification: Random forest and Support vector machine (SVM)	Detected the cancerous and non cancerous bone cell	X-ray images	[24]
2	Segmentation Techniques: Edge based and Region based K-mean clustering algorithm	Solve the dilemma of Osteo-sarcoma and Ewing sarcoma – both are types of bone cancer	X-ray and MRI images	[36]

Authorized licensed use limited to: UNIVERSIDADE FEDERAL DO PIAUI. Downloaded on September 14,2025 at 16:47:06 UTC from IEEE Xplore. Restrictions apply.

3	Used median filter for noise removal, for classification Convolution Neural Network (ConvNet/CNN) is used	Detecting the cancerous and non cancerous cells in bone Determine the stage of Bone Cancer	X- ray and CT Scan	[33]
4	Used CAD Framework Segmentation: K-means Classification: KNN classifer	Cancer identification	X- ray and CT Scan and MRI	[23]
5	For segmentation: Region growing algorithm For clustering: K-mean algorithm is used	Region of bone cancer is detection	MRI Images	[37]
6	Segmentation: k-mean Algorithm Genetic Algorithm (GA)	GA is used to detect type of cancer	MRI Image	[38]
7	Feature Extraction: GLCM (Gray Level Co-occurrence Matrix) Classification: Random Forest	To improve the sensitivity, specificity and accuracy detection of bone cancer	CT Scans	[39]
8	For Segmentation: Region growing algorithm is used	Detected size and stage of bone tumor	MRI Images	[40]
9	Feature extraction: GLCM (gray level co-occurrence matrix) Classifier used: k-nearest neighbour (KNN)	Detection of Bone tumor	MRI Images	[41]
10	Segmentation: K-mean and Region growing algorithm (ROI) is used.	Detection of Bone cancer and its types	X-ray and MRI Images	[26]

V. OPPORTUNITIES OF BONE CANCER DETECTION USING DEEP LEARNING

Bone tumor is an anaplastic growth of tissue in the bone and it was categorized as primary tumors whose effect began in the bone or from bone, derived cells and tissues, the secondary tumors which initiate in other locations and extend metastasis to the skeleton. To predict and identify size and the stage as well the region of the tumor so that it will be treated effectively by the therapists. To classify that tumor is benign or malignant. To develop a system which is helpful to differentiate the type of sarcoma like chondroma, Ewing sarcoma, and chondrosarcoma osteosarcoma, chondrosarcoma, ewing's sarcoma, pleomorphic sarcoma, fibrosarcoma, so that it can be treated separately as per disease requirement.

VI. CHALLENGES FOR BONE CANCER DETECTION

To integrate it with a CAD system of whole body diagnosis with CNN and also provide evidence that the clinical decision support system could be generalized across the globe. For Bone cancer detection, Researchers have worked with different medical imaging test such as MRI, X-ray, CT scan etc. So there is need to develop a common platform that work with different types of images. Many researchers have worked on comparison of different CNN techniques but it is not clear that which type of CNN is suitable for the detection of particular Bone cancer, So it is required to compare the performance of different CNN (Convolution Neural Networks) types. Furthermore it need to work more specifically on particular type of cancer by using different segmentation and classification techniques for the efficient and effective detection so that Bone tumor can be detected and treated timely. External validation, generalizability and dataset size are the key factors that need to be considered while designing new process or system for cancer detection.

VII. CONCLUSIONS

Bone cancer detection is used to detect the benign and malignant cells. The different work has been done for bone cancer detection by using different images types, different feature selection and different classification techniques. This paper discussed different types of bone cancer and their characteristics. Moreover this work also discussed different image acquisition techniques for bone cancer and their specific uses and it also discussed different classification techniques used for bone cancer detection and their comparative analysis. For the future scope still many work need to be done for efficient results such as firstly, one common platform is required for bone cancer detection where different image types can be used for cancer detection. Secondly, even after so much research in this area, inter-observer invariability due to different algorithm so standardization is mandatory to establish large dataset. More work need to be done on the External validation, generalizability and dataset size for the effective outcomes.

REFERENCES

[1] S. T. Santhanalakshmi, R. Abinaya, T. V Affina, and P. Dimple, “Deep Learning Based Bone Tumor Detection With Real Time Datasets,” pp. 2391–2394, 2020.

[2] C. Kaur and U. Garg, “Artificial intelligence techniques for cancer detection in medical image processing: A review,” *Mater. Today Proc.*, May 2021, doi: 10.1016/J.MATPR.2021.04.241.

[3] N. Papandrianos, E. Papageorgiou, A. Anagnostis, and A. Feleki, “A deep-learning approach for diagnosis of metastatic breast cancer in bones from whole-body scans,” *Appl. Sci.*, vol. 10, no. 3, 2020, doi: 10.3390/app10030997.

[4] D. Shrivastava, S. Sanyal, A. K. Maji, and D. Kandar, *Bone cancer*

Authorized licensed use limited to: UNIVERSIDADE FEDERAL DO PIAUI. Downloaded on September 14,2025 at 16:47:06 UTC from IEEE Xplore. Restrictions apply.

detection using machine learning techniques. 2020. doi: 10.1016/B978-0-12-817913-0.00017-1.

[5] S. T. Santhanalakshmi, R. Abinaya, T. V Affina, and P. Dimple, "DEEP LEARNING BASED BONE TUMOR DETECTION WITH REAL TIME DATASETS," pp. 2391–2394, 2020.

[6] M. Cortini, N. Baldini, and S. Avnet, "New advances in the study of bone tumors: A lesson from the 3D environment," *Front. Physiol.*, vol. 10, no. JUN, pp. 1–8, 2019, doi: 10.3389/fphys.2019.00814.

[7] T. Fujiwara and T. Ozaki, "Overcoming Therapeutic Resistance of Bone Sarcomas: Overview of the Molecular Mechanisms and Therapeutic Targets for Bone Sarcoma Stem Cells," *Stem Cells Int.*, vol. 2016, 2016, doi: 10.1155/2016/2603092.

[8] R. Rajani and C. P. Gibbs, "Treatment of Bone Tumors," *Surg. Pathol. Clin.*, vol. 5, no. 1, pp. 301–318, 2012, doi: 10.1016/j.path.2011.07.015.

[9] K. A. Boehme, S. B. Schleicher, F. Traub, and B. Rolauffs, "Chondrosarcoma: A rare misfortune in aging human cartilage? The role of stem and progenitor cells in proliferation, malignant degeneration and therapeutic resistance," *Int. J. Mol. Sci.*, vol. 19, no. 1, 2018, doi: 10.3390/ijms19010311.

[10] P. Thanindratarn, D. C. Dean, S. D. Nelson, F. J. Hornicek, and Z. Duan, "Advances in immune checkpoint inhibitors for bone sarcoma therapy," *J. Bone Oncol.*, vol. 15, no. January, p. 100221, 2019, doi: 10.1016/j.jbo.2019.100221.

[11] G. N. Tzanakakis *et al.*, "The role of igf/igf-ir-signaling and extracellular matrix effectors in bone sarcoma pathogenesis," *Cancers (Basel).*, vol. 13, no. 10, pp. 1–27, 2021, doi: 10.3390/cancers13102478.

[12] C. Thévenin-Lemoine *et al.*, "Planning for bone excision in ewing sarcoma post-Chemotherapy MRI more accurate than pre-Chemotherapy MRI assessment," *J. Bone Jt. Surg. - Am. Vol.*, vol. 100, no. 1, pp. 13–20, 2018, doi: 10.2106/JBJS.16.01461.

[13] A. E. Bădilă, D. M. Rădulescu, A. G. Niculescu, A. M. Grumezescu, M. Rădulescu, and A. R. Rădulescu, "Recent advances in the treatment of bone metastases and primary bone tumors: An up-to-date review," *Cancers (Basel).*, vol. 13, no. 16, pp. 1–27, 2021, doi: 10.3390/cancers13164229.

[14] A. Misaghi, A. Goldin, M. Awad, and A. A. Kulidjian, "Osteosarcoma: A comprehensive review," *Sicot-J*, vol. 4, 2018, doi: 10.1051/sicotj/2017028.

[15] X. Zhao, Q. Wu, X. Gong, J. Liu, and Y. Ma, "Osteosarcoma: a review of current and future therapeutic approaches," *Biomed. Eng. Online*, vol. 20, no. 1, pp. 1–14, 2021, doi: 10.1186/s12938-021-00860-0.

[16] H. Douis and A. Saifuddin, "The imaging of cartilaginous bone tumours. II. Chondrosarcoma," *Skeletal Radiol.*, vol. 42, no. 5, pp. 611–626, 2013, doi: 10.1007/s00256-012-1521-3.

[17] L. Ollivier, D. Vanel, and J. Leclère, "Imaging of chondrosarcomas," *Cancer Imaging*, vol. 4, no. 1, pp. 36–38, 2003, doi: 10.1102/1470-7330.2003.0022.

[18] S. K. Zöllner *et al.*, "Ewing sarcoma—diagnosis, treatment, clinical challenges and future perspectives," *J. Clin. Med.*, vol. 10, no. 8, 2021, doi: 10.3390/jcm10081685.

[19] H. U. Gerth, K. U. Juergens, U. Dirksen, J. Gerss, O. Schober, and C. Franzius, "Significant Benefit of Multimodal Imaging : PET / CT Compared with PET Alone in Staging and Follow-up of Patients with Ewing Tumors," no. December, 2007, doi: 10.2967/jnumed.107.045286.

[20] D. Augsburger *et al.*, "Current diagnostics and treatment of fibrosarcoma – perspectives for future therapeutic targets and strategies," vol. 8, no. 61, pp. 104638–104653, 2017.

[21] H. Wang *et al.*, "CT and MRI Findings of Soft Tissue Adult Fibrosarcoma in Extremities," vol. 2018, no. January 2016, 2018, doi: 10.1155/2018/6075705.

[22] A. R. War *et al.*, "Role of cancer stem cells in the development of giant cell tumor of bone," *Cancer Cell Int.*, vol. 20, no. 1, pp. 1–17, 2020, doi: 10.1186/s12935-020-01218-7.

[23] R. M. M, "2019 1 st International Conference on Advances in Information Technology BONE CANCER DETECTION USING K-MEANS SEGMENTATION AND KNN," pp. 76–80, 2019.

[24] A. Sharma, D. P. Yadav, H. Garg, M. Kumar, B. Sharma, and D. Koundal, "Bone Cancer Detection Using Feature Extraction Based Machine Learning Model," *Comput. Math. Methods Med.*, vol. 2021, 2021, doi: 10.1155/2021/7433186.

[25] C. Xia *et al.*, "SVM-Based Bone Tumor Detection by Using the Texture Features of X-Ray Image," *Proc. 2018 6th IEEE Int. Conf. Netw. Infrastruct. Digit. Content, IC-NIDC 2018*, vol. 6, no. 6 2, pp. 130–134, 2018, doi: 10.1109/ICNIDC.2018.8525806.

[26] A. Shukla and A. Patel, "Bone Cancer Detection from X-Ray and MRI Images through Image Segmentation Techniques," *Int. J. Recent Technol. Eng.*, vol. 8, no. 6, pp. 273–278, 2020, doi: 10.35940/ijrte.f7159.038620.

[27] M. Hoch, S. Ali, S. Agrawal, C. Wang, and J. S. Khurana, "Extraskeletal osteosarcoma: A case report and review of the literature," *J. Radiol. Case Rep.*, vol. 7, no. 7, pp. 15–23, 2013, doi: 10.3941/jrcr.v7i7.1245.

[28] C. Bladder *et al.*, "Bladder Cancer Early Detection , Diagnosis , and Staging Can Bladder Cancer Be Found Early ?," *Am. Cancer Soc.*, pp. 1–24, 2020, [Online]. Available: https://www.cancer.org/content/dam/CRC/PDF/Public/8661.00.pdf

[29] S. P. Power, F. Moloney, M. Twomey, K. James, O. J. O'Connor, and M. M. Maher, "Computed tomography and patient risk: Facts, perceptions and uncertainties," *World J. Radiol.*, vol. 8, no. 12, p. 902, 2016, doi: 10.4329/wjr.v8.i12.902.

[30] P. Sathiyanarayanan, S. Pavithra, M. Sai Saranya, and M. Makeswari, "Identification of breast cancer using the decision tree algorithm," *2019 IEEE Int. Conf. Syst. Comput. Autom. Networking, ICSCAN 2019*, pp. 1–6, 2019, doi: 10.1109/ICSCAN.2019.8878757.

[31] A. M.Elsayad and H. A. Elsalamony, "Diagnosis of Breast Cancer using Decision Tree Models and SVM," *Int. J. Comput. Appl.*, vol. 83, no. 5, pp. 19–29, 2013, doi: 10.5120/14445-2604.

[32] K. Polat and S. Güneş, "Breast cancer diagnosis using least square support vector machine," *Digit. Signal Process. A Rev. J.*, vol. 17, no. 4, pp. 694–701, 2007, doi: 10.1016/j.dsp.2006.10.008.

[33] D. Shrivastava, S. Sanyal, A. K. Maji, and D. Kandar, *Bone cancer detection using machine learning techniques*. INC, 2020. doi: 10.1016/B978-0-12-817913-0.00017-1.

[34] B. Satheesh Kumar and B. Sathiyaprasad, *Bone cancer detection using feature extraction with classification using K-nearest neighbor and decision tree algorithm*, vol. 38. 2021. doi: 10.3233/APC210064.

[35] S. M. Ayyad, A. I. Saleh, and L. M. Labib, "Gene expression cancer classification using modified K-Nearest Neighbors technique," *BioSystems*, vol. 176, no. December 2018, pp. 41–51, 2019, doi: 10.1016/j.biosystems.2018.12.009.

[36] A. Shukla and A. Patel, "Bone Cancer Detection from X-Ray and MRI Images through Image Segmentation Techniques," *Int. J. Recent Technol. Eng.*, vol. 8, no. 6, pp. 273–278, 2020, doi: 10.35940/ijrte.f7159.038620.

[37] L. V. N. P. and M. P. R. Madhuri Avula, "Detection of Bone Cancer Using Region Grawing Algorithm and Mean Pixel Intensity Thresholding," *Int. J. Soft Comput. 13*, pp. 69–80, 2018.

[38] K. Sujatha *et al.*, "Screening and Identify the Bone Cancer/Tumor using Image Processing," *Proc. 2018 Int. Conf. Curr. Trends Towar. Converging Technol. ICCTCT 2018*, pp. 1–5, 2018, doi: 10.1109/ICCTCT.2018.8550917.

[39] M. V. Suhas and A. Mishra, "Classification of benign and malignant bone lesions on CT images using random forest," *2016 IEEE Int. Conf. Recent Trends Electron. Inf. Commun. Technol. RTEICT 2016 - Proc.*, pp. 1807–1810, 2017, doi: 10.1109/RTEICT.2016.7808146.

[40] C. K. K. Reddy, P. R. Anisha, and G. V. S. Raju, "A Novel Approach for Detecting the Tumor Size and Bone Cancer Stage Using Region Growing Algorithm," *Proc. - 2015 Int. Conf. Comput. Intell. Commun. Networks, CICN 2015*, pp. 228–233, 2016, doi: 10.1109/CICN.2015.52.

[41] E. Hossain and M. A. Rahaman, "Detection & Classification of Tumor Cells from Bone MR Imagery Using Connected Component Analysis & Neural Network," *2018 Int. Conf. Adv. Electr. Electron. Eng. ICAEEE 2018*, pp. 1–4, 2019, doi: 10.1109/ICAEEE.2018.8642973.

Authorized licensed use limited to: UNIVERSIDADE FEDERAL DO PIAUI. Downloaded on September 14,2025 at 16:47:06 UTC from IEEE Xplore. Restrictions apply.