Journal of ISAKOS 9 (2024) 645–657

Contents lists available at ScienceDirect

Journal of ISAKOS

journal homepage: www.elsevier.com/locate/jisakos

State of the Art Review

Around-the-knee osteotomies part 1: definitions, rationale and planning—state of the art

M. Enes Kayaalp [a,b], Nicholas A. Apseloff [a], Ariana Lott [a], Janina Kaarre [a,c,d], Jonathan D. Hughes [a], Matthieu Ollivier [e], Volker Musahl [a,*]

[a] Department of Orthopaedic Surgery, UPMC Freddie Fu Sports Medicine Center, University of Pittsburgh, Pittsburgh, PA, 15203, USA
[b] Department Orthopaedics and Traumatology, Istanbul Kartal Training and Research Hospital, Istanbul, 34865, Turkiye
[c] Department of Orthopaedics, Institute of Clinical Sciences, Sahlgrenska Academy, University of Gothenburg, Gothenburg, 41345, Sweden
[d] Sahlgrenska Sports Medicine Center, Gothenburg, 41345, Sweden
[e] Aix Marseille Univ, CNRS, ISM, Inst Movement Sci, Marseille, 13009, France

A B S T R A C T

Knee osteotomies are essential orthopedic procedures with the ability to preserve the joint and correct ligament instabilities. Literature supports the correlation between lower limb malalignment and outcomes after knee ligament reconstruction and cartilage procedures. Concepts such as joint line obliquity, posterior tibial slope angle, and intra-articular deformity correction are integral components of both preoperative planning and postoperative evaluations. The concept of preserving and/or restoring joint line congruence during simultaneous correction of varus or valgus deformity can be achieved through several different approaches.

With advancements in osteotomy research and surgical planning technology, the surgical decision-making has increased in complexity. Based upon a patient's specific deformity, decisions need to be made whether to perform a single-level (proximal tibia or distal femur) versus double-level (both proximal tibia and distal femur) osteotomy, and whether to correct deformity in a single plane (coronal or sagittal) or perform a biplanar osteotomy, correcting two of the malalignments in either coronal, sagittal, or axial planes. Osteotomy procedures prioritize safety, reproducibility, precision, and meticulous planning. Equally important is the proactive management of possible complications and the implementation of preventive strategies for complications such as hinge fractures and unintentional changes to alignment in other planes.

This review navigates the intricate landscape of lower limb alignment, commencing with foundational definitions and rationale for performing osteotomies, progressing through the planning phase, and addressing the critical aspect of complication prevention, all while looking ahead to anticipate future advancements in this field. However, rotational osteotomies and tibial tubercle osteotomies in isolation or as an adjunct procedure are beyond the scope of this review.

INTRODUCTION

Osteotomies around the knee for limb alignment correction have been extensively studied [1], but the indications for ligamentous knee instability and unicompartmental osteoarthritis (OA) have gained considerable renewed interest [2]. Total and unicompartmental knee arthroplasty are established procedures for patients with end-stage knee OA, whereas osteotomies are useful for a subset of patients, potentially delaying the need for arthroplasty [3], decreasing the risk of ligamentous knee injury [4], or protecting cartilage-related procedures [5]. The benefits of valgus- and varus-producing or slope changing osteotomies around the knee outweigh the risks when proper indications and techniques are carefully applied to selected patients. Advancements in fixation techniques alongside contemporary postoperative rehabilitation protocols have made osteotomies increasingly appealing [2].

The first part of this review will identify relevant terminology, provide up-to-date classifications of alignment, discuss the biomechanical and clinical rationale for osteotomies, explore the decision-making process in planning for osteotomies, single- versus double-level correction, and single- versus bi-plane correction. Additionally, the preoperative planning required to execute osteotomies safely and effectively will be explored, with a particular focus on hinge fractures.

LOWER EXTREMITY ALIGNMENT

History and current concepts

Osteotomy techniques historically addressed limb deformities resulting from developmental disorders [1]. Over time, a major indication for osteotomies around the knee shifted toward offloading

DOI of original article: https://doi.org/10.1016/j.jisako.2024.04.002.
* Corresponding author. Department of Orthopaedic Surgery, UPMC Freddie Fu Sports Medicine Center, 3200 South Water Street, Pittsburgh, PA, 15203, USA.
E-mail address: musahlv@upmc.edu (V. Musahl).

https://doi.org/10.1016/j.jisako.2024.02.017
Received 30 October 2023; Received in revised form 21 February 2024; Accepted 26 February 2024
Available online 8 March 2024
2059-7754/© 2024 The Author(s). Published by Elsevier Inc. on behalf of International Society of Arthroscopy, Knee Surgery and Orthopedic Sports Medicine. This is an open access article under the CC BY-NC-ND license (http://creativecommons.org/licenses/by-nc-nd/4.0/).

unicompartmental OA [2,6]. Despite advancements in arthroplasty that further reduce knee pain and improve functionality, unicompartmental or total knee arthroplasty procedures are typically reserved for older patients with modest functional expectations. After knee arthroplasty, roughly 20% of patients remain dissatisfied [7]. Efforts to understand the reasons for this dissatisfaction, aided by medical imaging advancements, have yielded new insights into individual alignment classifications, identifying interindividual differences and normal variabilities among healthy cohorts [7,8].

There are established lower extremity alignment population norms [9] with many individual alignment variations [8]. Not all individuals possess "neutrally aligned" knees [10]. To better categorize individual lower extremity alignment, a classification system was developed which incorporates the mismatch between femoral and tibial alignment [11]. Patient-specific alignment philosophy was further refined with other classification attempts incorporating other variables [7,8]. This is a departure from the prior simplistic varus, valgus, or neutral alignment terminologies. New alignment classification systems provide more nuanced definitions of individual knee alignment but lack a grading system for varus or valgus alignment severity seen in knee joint line obliquity [8,6].

Throughout the evolution of osteotomy techniques, a variety of approaches have emerged to approach comprehensive limb malalignment. The various techniques encompass the selection of precise osteotomy locations, either proximal tibia or distal femur, as well as the decision to use an opening- or closing-wedge technique. In historical contexts, proximal tibial osteotomies were primarily employed to rectify varus deformations, while distal femoral osteotomies were the choice for addressing valgus deformities [6].

In contemporary times, the significance of lower extremity alignment and joint line obliquity has been underscored, influencing both the coronal and sagittal planes, with implications for ligamentous injuries and chondral procedures. Consequently, sports medicine/knee surgeons increasingly turned their attention to utilizing proximal tibial osteotomies to manage knee instability [12–15]. Notably, proximal tibia slope-changing osteotomies have recaptured global interest, supported by biomechanical and clinical studies that highlight their impact on the cruciate ligaments [13,16,4].

Alignment-related terminology and definitions

Lower limb alignment can be described based upon anatomic or mechanical axes and is measured on standing anteroposterior (AP) lower extremity radiographs. It is important to take rotational malpositioning into account when assessing alignment radiographs [17]. The anatomic axes of the femur and tibia are derived from a line bisecting the medullary canal of the diaphysis of each bone. The anatomic tibiofemoral angle is defined as the angle between the anatomic axis of the femur and the anatomic axis of the tibia.

In contrast to the anatomic axes, the mechanical axes of the femur and tibia are defined in relation to the center of the hip, knee, and ankle joints. The mechanical axis of the femur (MAF) is defined as a line drawn from the center of the femoral head to the center of the knee. There are multiple different locations defined to describe the "center of the knee" for calculating the MAF, including the center of the intercondylar notch of the femur and the center of the tibial spines [18]. The mechanical axis of the tibia is defined as a line drawn from the center of the tibial spines to the center of the talus (Fig. 1a). The mechanical tibiofemoral angle (mTFA) is defined as the angle between the MAF and mechanical axis of the tibia. The mechanical axis of the lower limb, also known as the Mikulicz line or the weight-bearing line (WBL), is drawn by connecting the center of the femoral head to the center of the ankle (typically the mid-width of the talus). The mechanical lateral distal femur angle (mLDFA) and mechanical medial proximal tibia angle (mMPTA) are frequently used to determine the contribution of the femur or tibia,

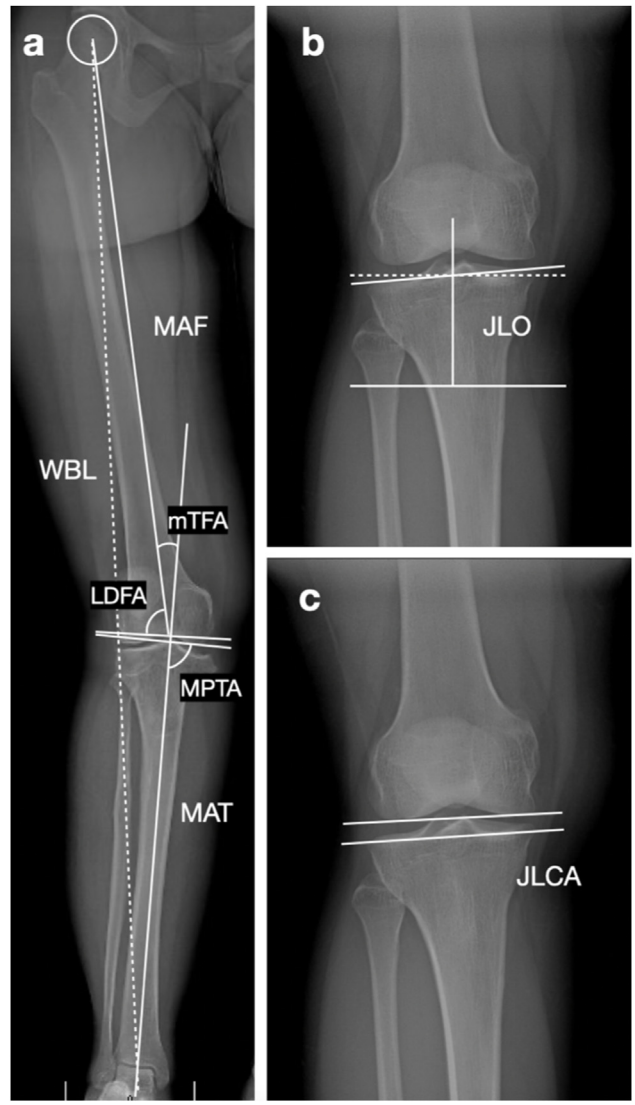

Fig. 1a. The weight-bearing line (WBL) is a line drawn from the center of the femoral head to the middle of the talus. The mechanical axis of the femur (MAF) is a line drawn from the center of the femoral head to the center of the intercondylar notch of the distal femur. The mechanical axis of the tibia (MAT) is defined as a line drawn from the center of the tibial spines to the center of the talus (Fig. 1a). The mechanical tibiofemoral angle (mTFA) is defined as the angle between the MAF and MAT. The mLDFA is measured by the lateral angle formed between the MAF and a line tangential to the distal femoral condyles. The mMPTA is the medial angle formed between the MAT and a line tangential to the tibial plateau.
1b. The joint line obliquity (JLO) is defined as the angle between a line tangential to the tibial plateau and the ground line. 1c. The joint line convergence angle (JLCA) is measured by the angle between lines tangential to the distal femoral condyles and the tibial plateau.

respectively, to a coronal plane deformity. The mLDFA is measured by the lateral angle formed between the MAF and a line tangential to the distal femoral condyles. The normal value of mLDFA is reported as 87 ± 3° [9]. The mMPTA is measured by the medial angle formed between the mechanical axis of the tibia and a line tangential to the tibial plateau, for which the normal value is reported as 87° (range = 85° to 90°) [9], although these values might not be representative of all individual variabilities (Fig. 1a).

The nomenclature used to describe standing native knee joint line orientation (JLO) relative to the ground has been described and

measured in a variety of different ways in the literature, which can lead to confusion. Knee JLO [19], knee JLO angle [20], knee joint line obliquity [21], and knee joint line obliquity angle [22] are all examples of the different terms used to describe the same concept—the orientation or obliquity of the tibiofemoral joint line relative to the ground on standing long-leg radiographs. These terms and others are often used interchangeably in the literature, despite there being several different ways to measure knee JLO.

The JLO has been described in different ways based upon the reference line chosen at the level of the knee. The JLO referencing the tibial plateau, also known as the tibial joint line angle, is the most commonly described method of calculating the JLO, and is defined as the angle between a line tangential to the tibial plateau and the ground line [23] (Fig. 1b). The JLO referencing the distal femur is defined as the angle between a line tangential to the distal femoral condyles and the ground line [24]. The JLO referencing the middle of the knee joint space is defined as the angle between a line connecting the midpoints of the medial and lateral tibiofemoral joint spaces and the ground line [25]. When comparing findings from studies that measure JLO, it is essential to identify the reference points and the context in which they were used. For instance, a recent individual alignment classification system interpreted JLO as the summation of MPTA and LDFA [8] (Fig. 2). However, it is important to exercise caution when applying this interpretation in osteotomy-based approaches, as this classification system was primarily oriented toward OA and arthroplasty, and JLO measurements, as described here, were not utilized.

Additional coronal deformity parameters related to the knee JLO include the joint line convergence angle (JLCA), knee–ankle joint angle, hip–knee–ankle angle, and the femorotibial angle [26]. The JLCA is measured by the angle between lines tangential to the distal femoral condyles and the tibial plateau and is typically parallel in normal knees (0–2°) (Fig. 1c). The JLCA might be considered a measure of intra-articular deformity, influenced by the degree of OA and indirectly by soft tissue laxity, cartilage wear, and meniscal insufficiency

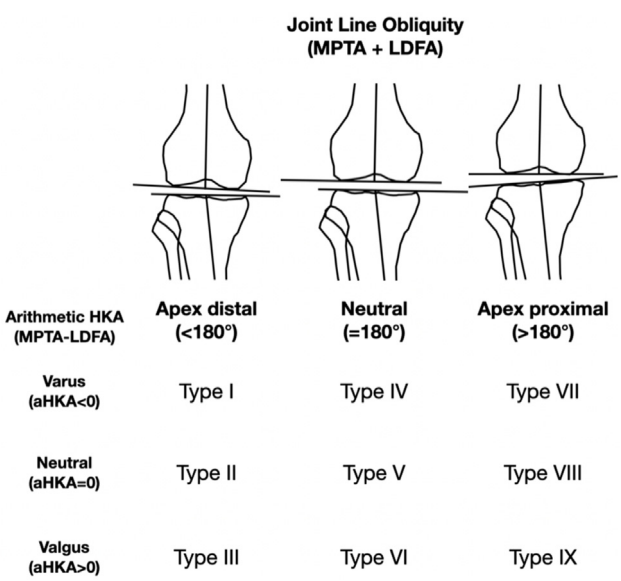

Fig. 2. Coronal Plane Alignment of the Knee (CPAK) classification. This classification categorizes native knees into 9 subgroups based on the arithmetic hip-knee-ankle (aHKA) angle, which can be in varus, neutral, or valgus. It also incorporates a special calculation of joint line obliquity (JLO) determined by the summation of the medial proximal tibial angle (MPTA) and lateral distal femoral angle (LDFA). It categorizes JLO angles <180° as apex distal, equal to 180° as neutral and >180° as apex proximal.

Fig. 3. The anatomic tibiofemoral angle (aTFA) as formed by the angle between the lines determining anatomic axis of femur and tibia (dashed white lines).

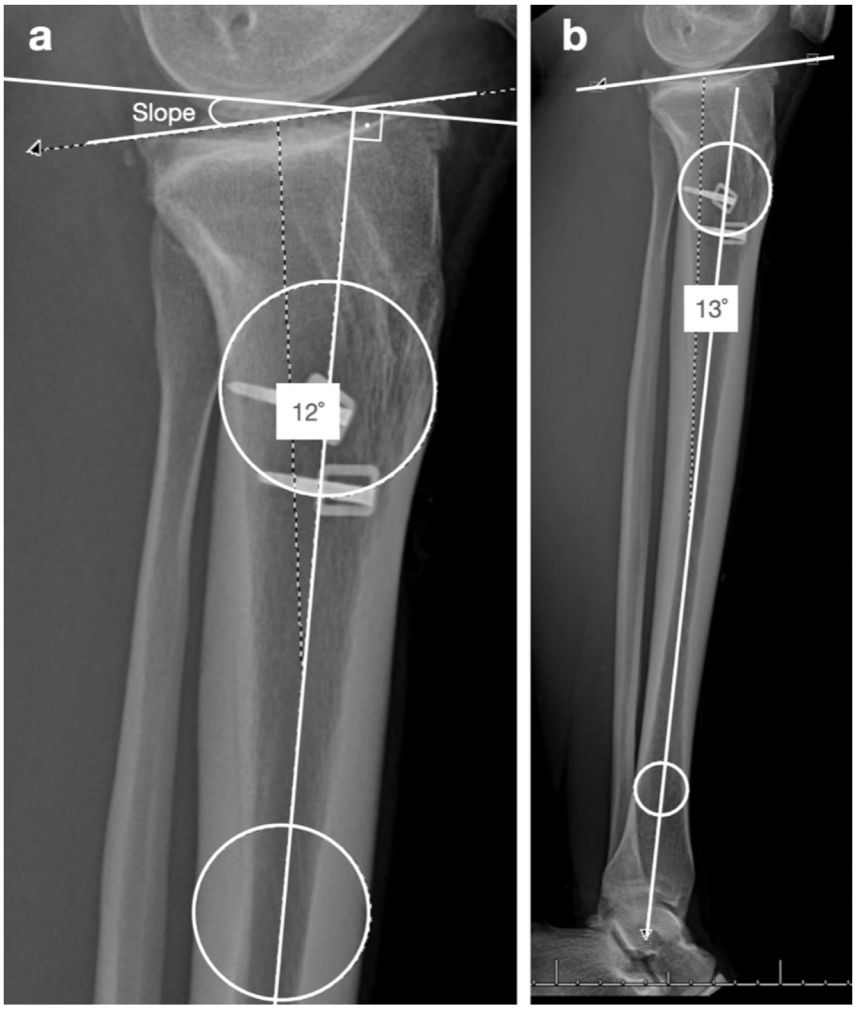

Fig. 4. Fig. 4a shows the measurement of the medial tibial slope angle, recorded as 12°, is depicted on a strict lateral knee radiograph of a left knee. Two circles are positioned: one just below the tubercle and the other 10 cm below it, outlining the most anterior and posterior parts of the cortex. The medial plateau is distinguishable by its more concave shape compared to the convex lateral plateau. The slope angle is defined as the angle between the line outlining the medial slope and the dashed white line perpendicular to the determined proximal tibial axis, connecting the center points of the positioned circles. Fig. 4b shows the full-length tibial radiograph of the same patient, with the slope measured as 13°.

[27]. The knee–ankle joint angle is measured by the angle between lines tangential to the tibial plateau and the distal tibial articular surface. The hip–knee–ankle angle, also referred to in the literature as either the mTFA or the mechanical femorotibial angle (mFTA), is measured by the angle between the mechanical axes of the femur and tibia. In contrast to the mTFA, the anatomic tibiofemoral angle is measured by the angle between the anatomic axes of the femur and tibia (Fig. 3).

Sagittal alignment of the proximal tibia is measured by the posterior tibial slope angle (referred to as "slope") (Fig. 4), defined on a perfect lateral radiograph of the knee with less than 6 mm posterior condylar overlap [28], by the angle formed between the longitudinal axis of the tibia and a line tangential to the tibial plateau. Malrotation during the acquisition of lateral knee radiographs can affect the accurate measurement of the slope [29]. The slope can be further divided into medial and lateral, representing the slope of the medial and lateral tibial plateaus, respectively. Slope can be measured on a lateral radiograph of the knee or by magnetic resonance imaging (MRI). Radiographically, slope is most frequently reported as the angle between the anatomic axis of the tibial diaphysis and a line tangential to the tibial plateau on a lateral radiograph of the knee or full-length tibia. If a lateral radiograph of the knee is used, then the proximal anatomic axis of the tibia can be determined by drawing a line perpendicular to the midpoints of the AP diameter of the tibia 5 cm and 15 cm distal to the joint line [30]. On MRI, the slope is measured by identifying the longitudinal axis of the proximal tibia by drawing two circles (one cranial and one caudal) overlying the tibia in the central sagittal image, and then drawing a line connecting the center of the circles [31]. The medial and lateral slope are then measured by the angle formed between this longitudinal axis of the proximal tibia and the medial and lateral tibial plateaus, respectively. However, MRI measurements result in underestimating bony slope by 5° [29]. Some authors advocate use of a full-length lateral tibial radiograph in determining the slope [32]. However, it must be remembered that diaphyseal deformities might not be addressed with a slope changing osteotomy due to the distance of osteotomy plane to the center of deformity [33]. Therefore, for slope changing surgical planning, a full length lateral tibial radiograph might not be necessarily utilized.

RATIONALE FOR OSTEOTOMY

The following section focuses on the biomechanical, clinical, and biological rationale for osteotomies around the knee. The subsections elaborate on the most recent evidence regarding joint line obliquity, and coronal and sagittal alignment changes.

Biomechanical rationale

The alignment terminologies discussed earlier have garnered increased attention and investigation in recent years, especially within the realm of

biomechanics. With the wide spectrum of lower leg alignment variations, the primary focus of biomechanical research on osteotomy justification revolves around differences before and after surgery in terms of loading patterns. This comparative approach is facilitated through methodologies like computer modeling and biomechanical assessments.

Prior research utilizing diverse methodologies has demonstrated alterations in knee loading distribution along the medial-lateral load distribution, as evidenced by both computer modeling studies [34] and cadaveric investigations [35] with sequential medial meniscus resection [36]. The following sections on biomechanical perspective followed by the clinical overview will further expand on the implications of reducing or distributing load with respect to clinical outcomes.

Joint line obliquity

In cases where the contributions of tibial and/or femoral deformities to overall lower limb malalignment, considering both extra- and intra-articular deformities, are underestimated, the osteotomy technique can unintentionally result in an oblique joint line [37]. Although there is recognition of the considerable variability in native knee joint line obliquity [8], a cadaveric biomechanical study revealed the substantial consequences of small changes in joint line obliquity. A varus or valgus alteration of 4° in joint line obliquity in cadaveric specimens resulted in significant coronal plane subluxation of the knee joint, negatively impacting stress distribution in both the medial and lateral compartments of the knee [38]. Further reinforcement for these findings was furnished by finite element analysis, which highlighted that joint line obliquity exceeding 5° led to an excess of shear stress on the tibial articular cartilage [39].

While not a direct correlation, an instrumental in vivo study examining total knee arthroplasty and dynamic activities unveiled the limitations of static radiographs in predicting dynamic knee kinematics and loading. It was determined that the dynamic orientation of the joint line held minimal significance in mediating mediolateral knee load distribution. Instead, the study unearthed a strong correlation between the external adduction moment and both the medial force and the mediolateral force distribution. This finding suggested a focal point on the external knee adduction moment for preventive and rehabilitative strategies [40].

When defining the acceptable range of joint obliquity for a structurally intact knee, a biomechanical study concluded that greater deviations may be tolerated in varus compared to valgus, with valgus deviations causing a more significant effect on tibial plateau loading [41].

Although the effect of 10° to 15° changes in coronal malalignment was shown to have a tolerable effect on load distribution at the tibial plateau, a resulting joint line obliquity of 5° after a high tibial osteotomy (HTO) may have more detrimental effect on tibial plateau loading, causing excessive shear stress. Analyzing the effects of HTO for varus knee deformities on articular cartilage stresses through a three-dimensional (3D) finite element model, it was demonstrated that joint line obliquity surpassing 5° led to undesirable shear stress on the tibial articular cartilage. Extensive correction in the context of medial opening-wedge high tibial osteotomy (MOWHTO), resulting in joint line obliquity of 5° or more, could engender detrimental stress on the articular cartilage. In such cases, the consideration of a double-level osteotomy (both at the proximal tibia and distal femur) emerged as a surgical option to mitigate these concerns [39].

In summary, cases with an excessive MPTA, i.e. ≥95°, might be operated with a double level osteotomy to limit an excessive change in joint line obliquity after coronal deformity correction. Hence, a more biomechanically favorable environment can be obtained with the preservation of JLO and obtaining an aligned lower extremity.

Coronal alignment

The primary biomechanical rationale behind correcting coronal malalignment of the knee centers on the strategic alteration of the weight-bearing axis. This adjustment serves to relieve the previously overloaded compartment or treated cartilage lesion, while concurrently providing an improved biomechanical environment for ligament stability.

Despite newer classification systems that highlight the prevalence of constitutional varus or valgus knee alignment among healthy individuals [7,8], traditional observations underscore a robust correlation between coronal malalignment and OA [42]. The influence of coronal malalignment on ligaments is evident through the intensified forces the anterior cruciate ligament (ACL) endures. Varus [43,44] or valgus [45] knee malalignment leads to increased force across the ACL. The latter scenario is exacerbated in cases where there is a deficiency in the posteromedial ligament complex [45].

A comparative modeling study supported by joint kinematic data demonstrated successful unloading of the medial compartment with valgus-producing HTO, revealing significantly diminished medial compartment contact forces post-operatively [46]. This observation was corroborated by a cadaveric study employing pressure-sensitive films that confirmed the reduction of medial compartment loading after MOWHTO [47].

Detailed examinations of contact points have shown that the paths of ground reaction force intersections shift laterally on the tibial plateau after MOWHTO [48]. The unloading effect of MOWHTO was particularly pronounced in the anteromedial articular zone of the femur [49]. Through computer-simulated modeling, abnormal knee kinematics during flexion were attributed to an elevated medial joint line and ligament imbalance resulting from elevated medial compartment contact forces. These forces stem from excessively large MPTAs post-MOWHTO [50].

Studies examining the effect of varus-producing distal femoral osteotomy (DFO) showed decrease in lateral compartment pressure [51]. Comparing lateral opening wedge DFO with medial closing wedge DFO, a biomechanical study showed lower tensile forces on the plate, and lower compressive strain on the hinge point in lateral opening wedge HTO [52].

Furthermore, a simulation study postulated that combined valgus and patellar instability may benefit from medial closing wedge DFO as tibial tubercle–trochlear groove distance was linearly reduced by 1 mm for every 1° correction [53].

Sagittal alignment

Within the realm of sagittal alignment parameters, the slope is the most extensively investigated. A increased slope directly induces increased anterior tibial translation [54–56], results in the anterior movement of the tibiofemoral contact point [57], and increases ACL strain [55,46]. Conversely, a lower slope has the potential to reduce native ACL in situ forces [13], though it might lead to an increase in graft forces in the context of ACL reconstruction [55,58]. Investigations have highlighted that as the slope decreases, there is an increase in force across the posterior cruciate ligament (PCL) [59].

In a cadaveric study, the combined valgus-producing osteotomy and slope-reducing osteotomy led to diminished tibial translation in both ACL-deficient and ACL-reconstructed knees. The forces on the ACL graft exhibited a significant decrease following the combined correction of varus deformity and slope [60]. This underscores the interplay between these alignment factors and their impact on knee biomechanics.

Clinical rationale

While not directly related to native knees, an in vivo study using instrumented total knee prostheses elucidated mediolateral force distribution dynamics. This distribution was found to be contingent upon the tibiofemoral alignment and exhibited variations across different weight-bearing tasks such as single-legged stance, ascending and descending stairs, walking and knee flexion, both within and between tasks [61]. This clinical finding aligns well with the biomechanical evidence and provides a relatable context for understanding the clinical rationale behind osteotomies.

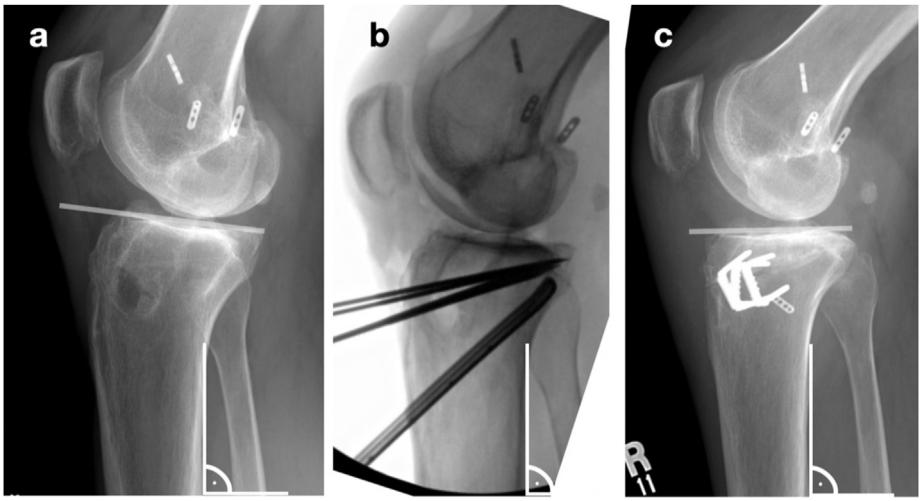

Fig. 5. Preoperative radiograph (a) with three femoral sided suspensory buttons from prior failed ACL reconstructions. The gray line represents a 15° posterior tibial slope of the medial tibial plateau. Intraoperative fluoroscopy image (b) with four Kirschner wires marking the proximal and distal aspect of the anterior closing wedge and desired orientation. A Hohmann retractor is in place. Postoperative lateral knee radiograph (c) after supratuberosity anterior closing wedge osteotomy. Two staples were used for fixation of the osteotomy and a tibial suspensory button is in place for transosseous fixation of the posterior medial meniscus root. The blurred gray line represents a 5° posterior tibial slope of the medial tibial plateau.

Joint line obliquity

Following the initial recognition of significant changes in JLO after osteotomy procedures, its connection to clinical outcomes garnered increased attention. To establish a threshold value for JLO, a clinical study identified that adverse radiological outcomes became evident when JLO reached or exceeded 6°. From a clinical standpoint, inferior outcomes were observed in cases where JLO was 4° or more [62].

Another investigation emphasized the necessity of achieving anatomical correction, particularly by ensuring that the MPTA remained below 90°. This is crucial as an MPTA exceeding 95.2° was associated with a notable increase in JLO, leading to subpar clinical outcomes compared to cases with properly or mildly under-corrected MPTA [63]. Additionally, an elevation in joint obliquity post-MOWHTO was linked to lateral knee pain [64]. In contrast, certain studies observed changes in radiological parameters without establishing a significant clinical correlation between unfavorable outcomes and an increased JLO angle [65–67]. A recent systematic review found no compelling association between postoperative JLO and clinical outcomes following HTO [68], further supporting this diversity of findings. These varied results underscore the complexity of the relationship between JLO and clinical outcomes, calling for further investigation and consideration of multiple factors at play.

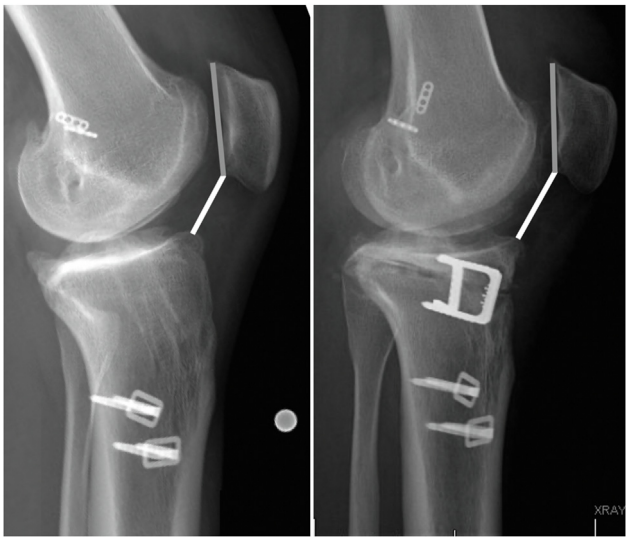

Fig. 6. Pre- and postoperative lateral knee radiographs of a patient who underwent a supratuberosity anterior closing wedge high tibial osteotomy. An increase in patellar height, measured using the Caton-Deschamps method, is evident.

Coronal alignment

The scientific literature offers robust evidence regarding the enhanced clinical outcomes resulting from knee osteotomies. These benefits are evident not only in cases of isolated varus [69–72] or valgus [73,74] deformity corrections, but also when osteotomies are combined with other procedures like meniscal root repair [75] or chondral procedures [76].

In the context of proximal tibia deformities, MOWHTO demonstrated both improved clinical results and no significant alteration in joint line obliquity in a carefully selected patient group [77]. Similarly, addressing varus deformity originating in the proximal tibia or distal femur through MOWHTO or lateral closing wedge DFO resulted in substantial clinical enhancements in International Knee Documentation Committee (IKDC) and Lysholm scores [78]. Utilizing a selective approach based on the deformity characteristics for either HTO, DFO, or double-level osteotomy, it was demonstrated that all procedures were associated with high rates of return to sport and satisfactory outcomes [72].

Although the ideal position of the WBL in relation to tibial plateau width remains a subject of debate, a clinical study involving 142 patients established a noteworthy association between its position and cartilage degeneration. Specifically, a WBL position of 62% of the plateau width was linked to cartilage regeneration following MOWHTO, thereby contributing to improved clinical outcomes [79] (Fig. 7). The target values of correction are discussed in more detail in the corresponding section below.

Sagittal alignment

The consideration of sagittal alignment in the context of proximal tibial osteotomies is not a novel concept [80]. However, it has witnessed renewed interest in recent years, resulting in a limited number of clinical studies with midterm follow-up [4]. As a result, much of the existing literature is primarily driven by technical reports.

Research has established a clear link between an increased slope and an increased risk of ACL graft failure [81]. A systematic review, though based on a restricted number of available articles, reinforced the notion that a slope-reducing HTO combined with ACL reconstruction restores AP knee stability and function, ultimately yielding improved outcomes in terms of better IKDC, Tegner, and Lysholm scores [82].

Despite variations observed in slope measurements between MRI and radiographs [83], as well as discrepancies stemming from different radiograph acquisition and measurement techniques [84], a tendency has developed on the cut-off value for slope-reducing osteotomies. This

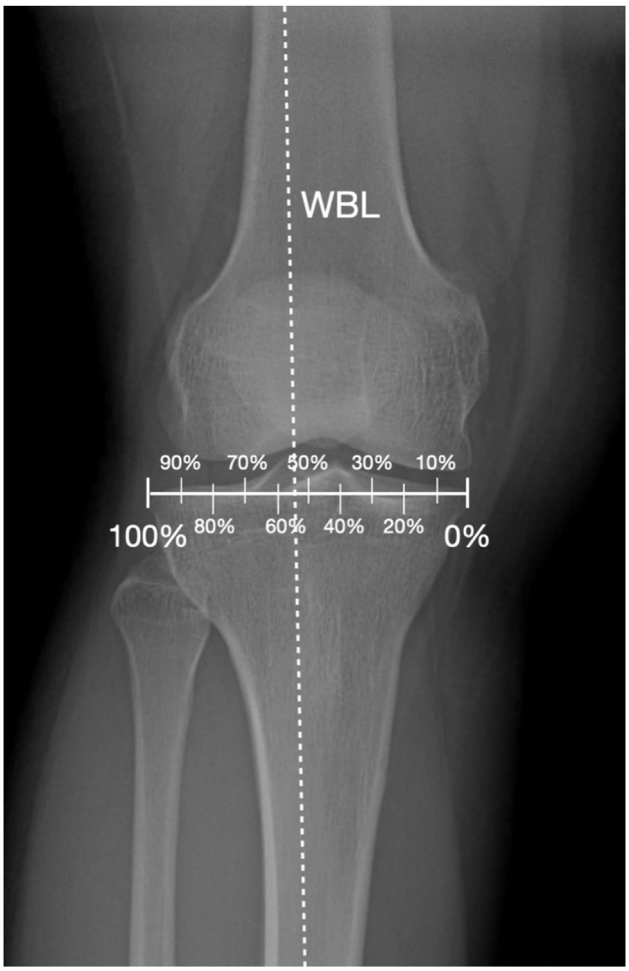

Fig. 7. Illustration of the percentage-wise position of the weight-bearing line (WBL) relative to the knee joint. At 0%, it corresponds to the most medial part of the tibial plateau, while at 100%, it corresponds to the most lateral part. An example WBL crosses the knee at 55% as suggested by the most recent biomechanical and clinical evidence [105–108].

value is accepted as 12° [85–87]. A large multicenter randomized clinical trial had shown an association between high grade pivot shift and a slope of >9° [88].

Numerous investigations indicated significantly increased slope among revision or re-revision ACL reconstruction patients compared to their primary ACL reconstruction counterparts [89,90,28]. Utilizing diverse techniques, a slope-reducing osteotomy emerged as a highly effective approach in the context of revision ACL reconstruction and increased slope [4,70,82–84] (Fig. 5).

Conversely, a decreased tibial slope angle heightens the risk of PCL graft failure [91,14,92]. Employing an anterior opening wedge osteotomy to augment the slope in patients with chronically deficient PCL was found to result in improved outcomes [93]. This interplay between sagittal alignment and ligament function underscores the critical role of slope adjustment in knee osteotomies.

Biological rationale

Further insights into the joint environment post-osteotomy were gained through biological analyses. The investigators obtained synovia and synovial fluid from patients undergoing an osteotomy and their analyses demonstrated a reduction in synovial volume and interleukin-6 (IL-6) concentrations within the synovial fluid, indicative of reduced inflammation following knee osteotomy [94]. These findings underscore the multifaceted benefits of knee osteotomies, not only in terms of mechanical correction but also in modulating the biological aspects of joint health.

PLANNING

Planning knee osteotomies requires a comprehensive assessment of patient-specific coronal malalignment in both the tibia and/or femur, along with any associated sagittal malalignment. This section will delve into the decision-making rationale behind opening vs closing wedge osteotomies, and single- versus double-level osteotomies. Subsequently, the aims of osteotomies will be explored, followed by an examination of techniques used in anterior closing wedge osteotomies. The discussion will then shift to adverse events and complications, with a specific emphasis on preventing hinge fractures.

Coronal alignment

Historically, osteotomies were approached with a dogmatic method, focusing solely on a single bone location for each coronal deformity: HTO for varus deformity and DFO for valgus deformity [95,6]. However, our understanding of the cause of malalignment has evolved, recognizing that varus alignment is not exclusively due to proximal tibial deformity [85], and valgus alignment is not solely attributed to distal femur deformity [95]. This realization challenged the once-prevailing notion of relying solely on HTO for correcting varus malalignment or DFO for valgus malalignment [95,96].

A closer examination of patients with varus alignment unveiled a diverse landscape: 28% had tibial deformities, 23% had femoral deformities, 4% exhibited both tibial and femoral deformities, and 45% displayed no bony deformities [96]. Simulation of osteotomy scenarios showed that excessive varus deformity was more frequently linked with femoral-side deformities, although tibial deformities remained consistent across varus severity groups. Consequently, it was deduced that only 12% of patients could be corrected via isolated HTO, while 63% necessitated a double-level osteotomy for achieving anatomic correction (mMPTA ≤90°). If slight overcorrection was deemed acceptable (mMPTA ≤95°), 57% could be corrected via isolated HTO [96]. However, another radiological study demonstrated that changes in JLO cannot solely be attributed to anticipated shifts in MPTA in preoperative planning, as postoperative lower extremity posture changes can also influence JLO [19].

A range of osteotomy techniques—HTO, DFO, or double-level—when applied with accurate indications and consideration for the location of deformity, were found to yield similar outcomes in young and active patients with varus malalignment. Lateral closing wedge DFO was associated with a quicker return to sports [72]. This was echoed by various studies reporting satisfying outcomes with DFO in midterm follow-up, although with a preference shift toward lower-impact sports [97].

Due to concerns linked to JLO the recommendation was to opt for double-level correction for higher correction angles or deformities affecting both sites. Double-level osteotomies also proved effective in treating bifocal valgus malaligned knees without compromising JLO [98]. Similarly, a comparative study demonstrated that double-level osteotomy enabled the acquisition of physiological JLO compared with MOWHTO alone [66].

When performing coronal alignment osteotomies, it should be considered that slope and leg length changes will vary depending on the technique used. A study showed that slope decreased by 2.5° in closing wedge HTO, while the slope remained unchanged in MOWHTO. Moreover, mean leg length decreased more in closing versus MOWHTO [99]. A meta-analysis showed that slope increased after MOWHTO and decreased after CWHTO [100].

Rotational changes should also be factored in preoperative planning, as internal rotation of the distal fragment and external rotation of the proximal fragment, along with increased tibial tubercle–trochlear groove distance, were noted after MOWHTO in postoperative CT images [101].

These considerations underscore the necessity for personalized preoperative planning, accounting for individual anatomical factors and potential multifaceted malalignments.

Sagittal alignment

To address the challenge of increased slope in patients with otherwise normal coronal alignment, several techniques have been introduced, including supratubercle, tubercle, and infratubercle slope-reducing HTOs [102–104]. Due to the lack of comparative studies, surgical preference plays a key role in decision making for these techniques. However, each approach has distinct considerations. For instance, supratubercle osteotomies may lead to patella alta (Fig. 6). There is currently no clear evidence to choose one level over another, as both techniques were shown to provide improved outcome in patients undergoing a slope reducing osteotomy [105,106,4,15].

A case report underlined the significance of a rigid construct in fixing the osteotomy, as varus collapse occurred following a supratubercle anterior closing wedge slope osteotomy. This emphasizes the importance of evaluating factors related to the patient, bone healing, and postoperative rehabilitation that could influence the outcome [107].

Additionally, closing wedge slope osteotomies can potentially result in knee hyperextension [84]. It is thus imperative to conduct thorough preoperative evaluations of patellar height and the risk of knee hyperextension and incorporate these factors into decision-making. In the context of infratubercle anterior closing wedge slope osteotomies, a recent study highlighted a decrease in MPTA angle [108].

Overall, when addressing increased slope in coronally aligned patients, careful consideration of the chosen technique's potential effects on patellar height, knee hyperextension, and MPTA is crucial. Additionally, the choice of fixation method must be tailored to the patient's characteristics and anticipated healing process to ensure a successful outcome and minimize potential complications.

Biplanar correction

When deformities with clinical implications exist in both the coronal and sagittal planes, a biplanar osteotomy can be performed to correct both planes during a single procedure. An example of this is in an ACL-deficient knee with both varus malalignment and increased slope. If a revision ACL reconstruction is planned in this patient, then correcting both the varus and slope deformities would be desired to reduce the risk of ACL graft failure. The components of the biplanar osteotomy for this scenario would be a valgus-producing HTO (e.g., MOWHTO) in addition to a slope-reducing HTO (e.g., anterior closing wedge HTO) [109]. A meta-analysis demonstrated that isolated MOWHTO increases the slope by 2° on average [100], making it critical to assess the slope preoperatively and consider a biplanar osteotomy in patients with combined varus and increased slope (>12°).

While biplanar HTOs have been primarily described for genu varum with instability or early medial unicompartmental arthritis, they may also be used to treat genu valgum with combined sagittal-plane deformities. In patients with genu valgum and recurvatum from a relatively decreased slope, a biplanar varus-producing, slope-increasing anterolateral opening wedge HTO may be indicated [110].

Although patient-specific instrumentation may contribute to enhancing the accuracy and reproducibility of procedures [111], additional evidence is necessary to determine its effectiveness in biplanar osteotomies.

Aim of correction

The overall goal of an osteotomy around the knee is to impart stability and/or unload an affected compartment. Controversy remains over the precise correction goals for knee malalignment. Historically, the varus knee was corrected via HTO to place the WBL to 62.5% of the width of the tibial plateau (with 0% being the medial edge of the plateau and 100% being the lateral edge of the plateau), also known as the "Fujisawa point" [112]. Recent biomechanical and clinical evidence and a consensus statement support correction to 55% [113–116] (Fig. 7).

Computational modeling with finite element analyses proposed placing the WBL at 55% (less overcorrection into valgus) to optimally distribute joint stresses [113]. Data support patient-specific correction goals based upon concomitant intra-articular lesions and procedures being performed. A previous study proposed a target correction of postoperative WBL for HTOs in the varus knee that varies based on concomitant pathologies, ranging from 50 to 55% for conditions without chondral defects or OA to 60–65% for grade III or IV medial compartment OA [117]. A recent consensus statement on osteotomy emphasized the importance of achieving a JLO of ≤5° and an MPTA of less than 94° [116].

In the valgus knee, correction to neutral alignment (rather than overcorrection into varus) is currently recommended throughout the literature. This is partly because the medial compartment already bears three-fourths of the load in neutral alignment [9]. Additionally, a previous gait analysis study demonstrated that following varus-producing osteotomy with a neutral alignment strategy, patients exhibited similar characteristics to those of a healthy comparison group in terms of kinematics and kinetics [118]. In the ACL-deficient knee with increased slope, the goal of an anterior closing wedge HTO is to reduce the slope to less than 10° [119], although overcorrecting is an area of debate [120].

CONCLUSION AND FUTURE PERSPECTIVES

Coronal alignment corrections have undergone a paradigm shift, acknowledging the multifaceted nature of varus and valgus malalignment. The conventional methods of single-site corrections have evolved into more personalized approaches, considering both proximal tibial and distal femoral osteotomies to achieve optimal outcomes. With a growing awareness of joint line obliquity and its clinical implications, the balance between anatomical correction and joint stability is highlighted.

In addressing sagittal alignment, surgical decisions must be carefully tailored to each patient's unique anatomical characteristics, factoring in potential impacts on patellar height and hyperextension.

In conclusion, the contemporary approach to lower extremity alignment osteotomies is a testament to the integration of biomechanical insights, clinical acumen, and innovative techniques. As the field continues to evolve, a personalized and holistic approach to planning, execution, and complication prevention remains pivotal in achieving successful outcomes for patients requiring these procedures.

In the future, there will be an increasing emphasis on tailoring osteotomy procedures to suit the unique characteristics of individual patients. The quest for a comprehensive understanding of joint biomechanics will persist, with a specific focus on elucidating the influence of alignment on joint health. This knowledge will help for the development of innovative osteotomy techniques and the refinement of materials, all aimed at achieving the best possible long-term clinical outcomes.

The ongoing evolution of minimally invasive approaches, potentially incorporating robotic-assisted surgery and patient-specific implants, is anticipated. These advancements are expected to lead to fine-tuning corrections in multiple planes, improved corrections, and subsequently, enhanced patient outcomes and joint preservation.

Key articles

1. Willinger L, Lang JJ, Berthold D, Muench LN, Achtnich A, Forkel P, Imhoff AB, Burgkart R, von Deimling C. Varus alignment aggravates tibiofemoral contact pressure rise after sequential medial meniscus resection. Knee Surg Sports Traumatol Arthrosc. 2020 Apr; 28(4):1055–1063. https://doi.org/10.1007/s00167-019-05654-5. Epub 2019 Aug 3. PMID: 31377827.
2. Wang D, Willinger L, Athwal KK, Williams A, Amis AA. Knee Joint Line Obliquity Causes Tibiofemoral Subluxation That Alters Contact Areas and Meniscal Loading. Am J Sports Med. 2021 Jul; 49(9):2351–2360. https://doi.org/10.1177/03635465211020478. Epub 2021 Jun 14. PMID: 34125619; PMCID: PMC8283183.
3. Dawson MJ, Ollivier M, Menetrey J, Beaufils P. Osteotomy around the painful degenerative varus knee: a 2022 ESSKA formal consensus. Knee Surg Sports Traumatol Arthrosc. 2023 Aug; 31(8):3041–3043. https://doi.org/10.1007/s00167-022-07024-0. Epub 2022 Jun 13. PMID: 35697873.
4. Xie T, Brouwer RW, van den Akker-Scheek I, van der Veen HC. Clinical relevance of joint line obliquity after high tibial osteotomy for medial knee osteoarthritis remains controversial: a systematic review. Knee Surg Sports Traumatol Arthrosc. 2023 Oct; 31(10):4355–4367. https://doi.org/10.1007/s00167-023-07486-w. Epub 2023 Jun 20. PMID: 37340220; PMCID: PMC10471655.
5. Pioger C, Mabrouk A, Siboni R, Jacquet C, Seil R, Ollivier M. Double-level knee osteotomy accurately corrects lower limb deformity and provides satisfactory functional outcomes in bifocal (femur and tibia) valgus malaligned knees. Knee Surg Sports Traumatol Arthrosc. 2023 Jul; 31(7):3007–3014. https://doi.org/10.1007/s00167-023-07325-y. Epub 2023 Jan 27. PMID: 36705689.
6. Gulagaci F, Jacquet C, Ehlinger M, Sharma A, Kley K, Wilson A, Parratte S, Ollivier M. A protective hinge wire, intersecting the osteotomy plane, can reduce the occurrence of perioperative hinge fractures in medial opening wedge osteotomy. Knee Surg Sports Traumatol Arthrosc. 2020 Oct; 28(10):3173–3182. https://doi.org/10.1007/s00167-019-05806-7. Epub 2019 Nov 26. PMID: 31773202.
7. Agneskirchner JD, Hurschler C, Stukenborg-Colsman C, Imhoff AB, Lobenhoffer P. Effect of high tibial flexion osteotomy on cartilage pressure and joint kinematics: a biomechanical study in human cadaveric knees. Winner of the AGA-DonJoy Award 2004. Arch Orthop Trauma Surg. 2004 Nov; 124(9):575-84. https://doi.org/10.1007/s00402-004-0728-8. Epub 2004 Aug 3. PMID: 15480717.
8. Giffin JR, Vogrin TM, Zantop T, Woo SL, Harner CD. Effects of increasing tibial slope on the biomechanics of the knee. Am J Sports Med. 2004 Mar; 32(2):376-82. https://doi.org/10.1177/0363546503258880. PMID: 14977661.
9. Imhoff FB, Comer B, Obopilwe E, Beitzel K, Arciero RA, Mehl JT. Effect of Slope and Varus Correction High Tibial Osteotomy in the ACL-Deficient and ACL-Reconstructed Knee on Kinematics and ACL Graft Force: A Biomechanical Analysis. Am J Sports Med. 2021 Feb; 49(2):410–416. https://doi.org/10.1177/0363546520976147. Epub 2020 Dec 3. PMID: 33270464.
10. Smith JO, Wilson AJ, Thomas NP. Osteotomy around the knee: evolution, principles and results. Knee Surg Sports Traumatol Arthrosc. 2013 Jan; 21(1):3–22. https://doi.org/10.1007/s00167-012-2206-0. Epub 2012 Sep 29. PMID: 23052110.

Essentials of biomechanical rationale

- A small alteration in joint line obliquity can result in significant subluxations and changes in the distribution of contact pressure areas within the medial and lateral compartments of the knee.
- Static radiographs may not accurately predict dynamic kinematics and loading in knee joint.
- Coronal malalignment of the knee, whether in varus or valgus, has a significant impact on ligaments and compartment loading.
- Corrective procedures like valgus-producing high tibial osteotomy can successfully unload the medial compartment and reduce medial compartment contact forces.
- The posterior tibial slope angle plays a crucial role in knee biomechanics.
- Increased posterior tibial slope angles increase anterior tibial translation: A slope of greater 9° on MRI is associated with a high-grade pivot shift.
- Correcting varus deformity and slope together can lead to reduced tibial translation and decreased forces on the anterior cruciate ligament graft.

Essentials of clinical rationale

- The relationship between joint line obliquity and clinical outcomes remains complex and varied among different studies, emphasizing the need for further investigation.
- Knee osteotomies, whether for varus or valgus deformity corrections, have shown improved clinical outcomes.
- Osteotomy benefits extend to cases where they are combined with other procedures like meniscal repair, ligament reconstruction or chondral procedures.
- Knee osteotomies not only provide mechanical correction but also have biological benefits, such as reduced inflammation following knee osteotomies.
- Increased slope is associated with an increased risk of anterior cruciate ligament graft failure.
- Slope-reducing osteotomies combined with anterior cruciate ligament reconstruction have been shown to restore knee stability and improve outcomes.
- The consensus cutoff value for slope reduction is widely accepted as 12°.
- Decreased slope increase the risk of posterior cruciate ligament graft failure. Utilizing anterior opening wedge osteotomies has been found to result in improved outcomes.

Major pitfalls of surgical planning

- Failure to consider individual factors when determining the choice between high tibial osteotomy, distal femur osteotomy, or double-level osteotomies may lead to clinical failure.
- Neglecting to account for joint line obliquity in preoperative planning can result in excessive changes in joint line obliquity, which may compromise anatomic correction and clinical outcomes.
- Biplanar osteotomies are particularly relevant in cases of combined varus or valgus and increased posterior tibial slope, which can increase the risk of anterior cruciate ligament graft failure.
- Correction goals can vary based on individual factors, concomitant intra-articular lesions and procedures being performed.

Major pearls of surgical planning

- For slope-reducing osteotomies, the surgical indication cut-off is a slope of 12° measured on lateral knee radiographs with 15 cm of proximal tibia involved. Shorter radiographs may overestimate the slope, while magnetic resonance imaging measurements may underestimate it, leading to incorrect indications and planning for correction.
- When performing coronal alignment osteotomies, factors like slope and leg length changes should be considered.
- A recent consensus statement on osteotomy emphasized the importance of achieving a JLO of ≤5° and an MPTA of less than 94°.
- Addressing increased slope in patients with normal coronal alignment requires careful consideration of different techniques, such as supra-tubercle, tubercle, and infratubercle slope-reducing high tibial osteotomies.
- Preoperative evaluations of patellar height and the risk of hyperextension are crucial in decision-making prior to slope osteotomy.

Declaration of competing interest

The authors declare the following financial interests/personal relationships which may be considered as potential competing interests: Matthieu Ollivier reports a relationship with Newclip Technics that includes: consulting or advisory. Matthieu Ollivier reports a relationship with Stryker that includes: consulting or advisory. Matthieu Ollivier reports a relationship with Zimmer Inc that includes: consulting or advisory. Volker Musahl reports a relationship with Smith and Nephew Inc that includes: consulting or advisory, funding grants, and speaking and lecture fees. Volker Musahl reports a relationship with Arthrex Inc that includes: funding grants. Volker Musahl reports a relationship with DePuy Synthes that includes: funding grants. Volker Musahl reports a relationship with Newclip Technics that includes: consulting or advisory. Volker Musahl reports a relationship with International Society of Arthroscopy Knee Surgery and Orthopaedic Sports Medicine that includes board membership. Volker Musahl has patent #9,949,684 issued to U.S. Patent. Matthieu Ollivier reports royalties from Newclip, Stryker, and Zimmer. Volker Musahl is deputy editor-in-chief of Knee Surgery, Sports Traumatology, Arthroscopy (KSSTA). If there are other authors, they declare that they have no known competing financial interests or personal relationships that could have appeared to influence the work reported in this paper.

References

[1] Smith JO, Wilson AJ, Thomas NP. Osteotomy around the knee: evolution, principles and results. Knee Surg Sports Traumatol Arthrosc 2013;21(1):3–22. https://doi.org/10.1007/s00167-012-2206-0.
[2] Ferrera A, Menetrey J. Optimizing indications and technique in osteotomies around the knee. EFORT Open Rev 2022;7(6):396–403. https://doi.org/10.1530/EOR-22-0057.
[3] Primeau CA, Birmingham TB, Leitch KM, Willits KR, Litchfield RB, Fowler PJ, et al. Total knee replacement after high tibial osteotomy: time-to-event analysis and predictors. CMAJ (Can Med Assoc J) 2021;193(5):E158–66. https://doi.org/10.1503/cmaj.200934.
[4] Dejour D, Rozinthe A, Demey G, ReSurg.. First revision ACL reconstruction combined with tibial deflexion osteotomy improves clinical scores at 2 to 7 years follow-up. Knee Surg Sports Traumatol Arthrosc 2023 Oct;31(10):4467-4473. https://doi.org/10.1007/s00167-023-07493-x.
[5] Ackermann J, Merkely G, Arango D, Mestriner AB, Gomoll AH. The effect of mechanical leg alignment on cartilage restoration with and without concomitant high tibial osteotomy. Arthroscopy 2020;36(8):2204–14. https://doi.org/10.1016/j.arthro.2020.04.019.
[6] Miozzari HH. Osteotomies around the knee are not just space oddities. Knee Surg Sports Traumatol Arthrosc 2023 Nov;31(11):4639-4641. https://doi.org/10.1007/s00167-023-07436-6.
[7] Hirschmann MT, Moser LB, Amsler F, Behrend H, Leclerq V, Hess S. Functional knee phenotypes: a novel classification for phenotyping the coronal lower limb alignment based on the native alignment in young non-osteoarthritic patients. Knee Surg Sports Traumatol Arthrosc 2019;27(5):1394–402. https://doi.org/10.1007/s00167-019-05509-z.
[8] MacDessi SJ, Griffiths-Jones W, Harris IA, Bellemans J, Chen DB. Coronal plane alignment of the knee (CPAK) classification. Bone Joint Lett J 2021;103-B(2):329–37. https://doi.org/10.1302/0301-620X.103B2.BJJ-2020-1050.R1.
[9] Paley D. Normal lower limb alignment and joint orientation. In: Paley D, editor. Principles of deformity correction. Berlin, Heidelberg: Springer Berlin Heidelberg; 2002. p. 1–18. https://doi.org/10.1007/978-3-642-59373-4_1.
[10] Bellemans J, Colyn W, Vandenneucker H, Victor J. The Chitranjan Ranawat award: is neutral mechanical alignment normal for all patients? The concept of constitutional varus. Clin Orthop Relat Res 2012;470(1):45–53. https://doi.org/10.1007/s11999-011-1936-5.
[11] Lin YH, Chang FS, Chen KH, Huang KC, Su KC. Mismatch between femur and tibia coronal alignment in the knee joint: classification of five lower limb types according to femoral and tibial mechanical alignment. BMC Muscoskel Disord 2018;19(1):411. https://doi.org/10.1186/s12891-018-2335-9.
[12] Nazzal EM, Zsidai B, Pujol O, Kaarre J, Curley AJ, Musahl V. Considerations of the posterior tibial slope in anterior cruciate ligament reconstruction: a scoping review. Curr Rev Musculoskelet Med 2022;15(4):291–9. https://doi.org/10.1007/s12178-022-09767-2.
[13] Winkler PW, Chan CK, Lucidi GA, Polamalu SK, Wagala NN, Hughes JD, et al. Increasing the posterior tibial slope lowers in situ forces in the native ACL primarily at deep flexion angles. J Orthop Res 2022;41(7):1430–8. https://doi.org/10.1002/jor.25484.
[14] Li L, Li J, Zhou P, He Y, Li Y, Deng X, et al. Decreased medial posterior tibial slope is associated with an increased risk of posterior cruciate ligament rupture. Knee Surg Sports Traumatol Arthrosc 2023;31(7):2966–73. https://doi.org/10.1007/s00167-023-07308-z.
[15] Vivacqua T, Thomassen S, Winkler PW, Lucidi GA, Rousseau-Saine A, Firth AD, et al. Closing-wedge posterior tibial slope-reducing osteotomy in complex revision ACL reconstruction. Orthop J Sports Med 2023;11(1):23259671221144786. https://doi.org/10.1177/23259671221144786.
[16] Beel W, Schuster P, Michalski S, Mayer P, Schlumberger M, Hielscher L, et al. High prevalence of increased posterior tibial slope in ACL revision surgery demands a patient-specific approach. Knee Surg Sports Traumatol Arthrosc 2023 Jul;31(7):2974-2982. https://doi.org/10.1007/s00167-023-07313-2.

[17] Maderbacher G, Schaumburger J, Baier C, Zeman F, Springorum HR, Dornia C, et al. Predicting knee rotation by the projection overlap of the proximal fibula and tibia in long-leg radiographs. Knee Surg Sports Traumatol Arthrosc 2014;22(12): 2982–8. https://doi.org/10.1007/s00167-014-3327-4.
[18] Marques Luís N, Varatojo R. Radiological assessment of lower limb alignment. EFORT Open Rev 2021;6(6):487–94. https://doi.org/10.1302/2058-5241.6.210015.
[19] Bartholomeeusen S, Van den Bempt M, van Beek N, Claes T, Claes S. Changes in knee joint line orientation after high tibial osteotomy are the result of adaptation of the lower limb to the new alignment. Knee 2020;27(3):777–86. https://doi.org/10.1016/j.knee.2020.04.018.
[20] Park SB, Lee YS. Association of the joint line orientation angle of the contralateral limb with the alignment change of the unilateral and bilateral opening-wedge high tibial osteotomy. Knee Surg Sports Traumatol Arthrosc 2023;31(4): 1593–602. https://doi.org/10.1007/s00167-022-07123-y.
[21] Hsu RW, Himeno S, Coventry MB, Chao EY. Normal axial alignment of the lower extremity and load-bearing distribution at the knee. Clin Orthop Relat Res 1990; 255:215–27.
[22] Malavolta M, Compagnoni R, Mezzari S, Calanna F, Pastrone A, Randelli P. Good clinical results using a modified kinematic alignment technique with a cruciate sacrificing medially stabilised total knee arthroplasty. Knee Surg Sports Traumatol Arthrosc 2022;30(2):500–6. https://doi.org/10.1007/s00167-020-06196-x.
[23] Victor JM, Bassens D, Bellemans J, Gürsu S, Dhollander AA, Verdonk PC. Constitutional varus does not affect joint line orientation in the coronal plane. Clin Orthop Relat Res 2014;472(1):98–104. https://doi.org/10.1007/s11999-013-2898-6.
[24] Akamatsu Y, Kumagai K, Kobayashi H, Tsuji M, Saito T. Effect of increased coronal inclination of the tibial plateau after opening-wedge high tibial osteotomy. Arthroscopy 2018;34(7):2158–2169.e2152. https://doi.org/10.1016/j.arthro.2018.01.055.
[25] Lee KM, Chang CB, Park MS, Kang SB, Kim TK, Chung CY. Changes of knee joint and ankle joint orientations after high tibial osteotomy. Osteoarthritis Cartilage 2015;23(2):232–8. https://doi.org/10.1016/j.joca.2014.11.001.
[26] Xie T, van der Veen HC, van den Akker-Scheek I, Brouwer RW. Assessment of joint line obliquity and its related frontal deformity using long-standing radiographs. J Orthop 2023;40:57–64. https://doi.org/10.1016/j.jor.2023.04.014.
[27] Micicoi G, Khakha R, Kley K, Wilson A, Cerciello S, Ollivier M. Managing intra-articular deformity in high Tibial osteotomy: a narrative review. J Exp Orthop 2020;7(1):65. https://doi.org/10.1186/s40634-020-00283-1.
[28] Winkler PW, Wagala NN, Hughes JD, Lesniak BP, Musahl V. A high tibial slope, allograft use, and poor patient-reported outcome scores are associated with multiple ACL graft failures. Knee Surg Sports Traumatol Arthrosc 2022;30(1): 139–48. https://doi.org/10.1007/s00167-021-06460-8.
[29] Gwinner C, Fuchs M, Sentuerk U, Perka CF, Walter TC, Schatka I, et al. Assessment of the tibial slope is highly dependent on the type and accuracy of the preceding acquisition. Arch Orthop Trauma Surg 2019;139(12):1691–7. https://doi.org/10.1007/s00402-019-03201-y.
[30] Dejour H, Bonnin M. Tibial translation after anterior cruciate ligament rupture. Two radiological tests compared. J Bone Joint Surg Br 1994;76-B(5):745–9. https://doi.org/10.1302/0301-620x.76b5.8083263.
[31] Hashemi J, Chandrashekar N, Gill B, Beynnon BD, Slauterbeck JR, Schutt Jr RC, et al. The geometry of the tibial plateau and its influence on the biomechanics of the tibiofemoral joint. J Bone Joint Surg Am 2008;90(12):2724–34. https://doi.org/10.2106/JBJS.G.01358.
[32] Faschingbauer M, Sgroi M, Juchems M, Reichel H, Kappe T. Can the tibial slope be measured on lateral knee radiographs? Knee Surg Sports Traumatol Arthrosc 2014;22(12):3163–7. https://doi.org/10.1007/s00167-014-2864-1.
[33] Paley D. Realignment for mono-compartment osteoarthritis of the knee. In: Paley D, editor. Principles of deformity correction. Berlin, Heidelberg: Springer Berlin Heidelberg; 2002. p. 479–507. https://doi.org/10.1007/978-3-642-59373-4_16.
[34] Van Rossom S, Wesseling M, Smith CR, Thelen DG, Vanwanseele B, Dieter VA, et al. The influence of knee joint geometry and alignment on the tibiofemoral load distribution: a computational study. Knee 2019;26(4):813–23. https://doi.org/10.1016/j.knee.2019.06.002.
[35] Willinger L, Lang JJ, von Deimling C, Diermeier T, Petersen W, Imhoff AB, et al. Varus alignment increases medial meniscus extrusion and peak contact pressure: a biomechanical study. Knee Surg Sports Traumatol Arthrosc 2020;28(4):1092–8. https://doi.org/10.1007/s00167-019-05701-1.
[36] Willinger L, Lang JJ, Berthold D, Muench LN, Achtnich A, Forkel P, et al. Varus alignment aggravates tibiofemoral contact pressure rise after sequential medial meniscus resection. Knee Surg Sports Traumatol Arthrosc 2020;28(4):1055–63. https://doi.org/10.1007/s00167-019-05654-5.
[37] Micicoi G, Grasso F, Kley K, Favreau H, Khakha R, Ehlinger M, et al. Osteotomy around the knee is planned toward an anatomical bone correction in less than half of patients. Orthop Traumatol Surg Res 2021;107(4):102897. https://doi.org/10.1016/j.otsr.2021.102897.
[38] Wang D, Willinger L, Athwal KK, Williams A, Amis AA. Knee joint line obliquity causes tibiofemoral subluxation that Alters contact areas and meniscal loading. Am J Sports Med 2021;49(9):2351–60. https://doi.org/10.1177/03635465211020478.
[39] Nakayama H, Schroter S, Yamamoto C, Iseki T, Kanto R, Kurosaka K, et al. Large correction in opening wedge high tibial osteotomy with resultant joint-line obliquity induces excessive shear stress on the articular cartilage. Knee Surg Sports Traumatol Arthrosc 2018;26(6):1873–8. https://doi.org/10.1007/s00167-017-4680-x.
[40] Trepczynski A, Moewis P, Damm P, Schutz P, Dymke J, Hommel H, et al. Dynamic knee joint line orientation is not predictive of tibio-femoral load distribution during walking. Front Bioeng Biotechnol 2021;9:754715. https://doi.org/10.3389/fbioe.2021.754715.
[41] Hooper JM, Walker P, Hsu TT, Kurtz A, Reynolds R, Hennessy D, et al. Biomechanical implications of an oblique knee joint line. J Knee Surg 2018;31(8): 761–6. https://doi.org/10.1055/s-0037-1608821.
[42] Brouwer GM, van Tol AW, Bergink AP, Belo JN, Bernsen RM, Reijman M, et al. Association between valgus and varus alignment and the development and progression of radiographic osteoarthritis of the knee. Arthritis Rheum 2007; 56(4):1204–11. https://doi.org/10.1002/art.22515.
[43] van de Pol GJ, Arnold MP, Verdonschot N, van Kampen A. Varus alignment leads to increased forces in the anterior cruciate ligament. Am J Sports Med 2009;37(3): 481–7. https://doi.org/10.1177/0363546508326715.
[44] Hinckel BB, Demange MK, Gobbi RG, Pecora JR, Camanho GL. The effect of mechanical varus on anterior cruciate ligament and lateral collateral ligament stress: finite element analyses. Orthopedics 2016;39(4):e729–36. https://doi.org/10.3928/01477447-20160421-02.
[45] Mehl J, Otto A, Kia C, Murphy M, Obopilwe E, Imhoff FB, et al. Osseous valgus alignment and posteromedial ligament complex deficiency lead to increased ACL graft forces. Knee Surg Sports Traumatol Arthrosc 2020;28(4):1119–29. https://doi.org/10.1007/s00167-019-05770-2.
[46] Bowd J, Van Rossom S, Williams D, Elson D, Wilson C, Whatling G, et al. Using musculoskeletal modelling to estimate knee joint loading pre and post high tibial osteotomy. Clin Biomech 2023;101:105855. https://doi.org/10.1016/j.clinbiomech.2022.105855.
[47] Kloos F, Becher C, Fleischer B, Ettinger M, Bode L, Schmal H, et al. Discharging the medial knee compartment: comparison of pressure distribution and kinematic shifting after implantation of an extra-capsular absorber system (ATLAS) and open-wedge high tibial osteotomy-a biomechanical in vitro analysis. Arch Orthop Trauma Surg 2023;143(6):2929–41. https://doi.org/10.1007/s00402-022-04496-0.
[48] Ruggeri M, Gill HS, Leardini A, Zaffagnini S, MacLeod A, Ortolani M, et al. Superimposition of ground reaction force on tibial-plateau supporting diagnostics and post-operative evaluations in high-tibial osteotomy. A novel methodology. Gait Posture 2022;94:144–52. https://doi.org/10.1016/j.gaitpost.2022.02.028.
[49] Jeong HW, Song YS, Kim JS, Nam HS, Lee WW, Lee YS. Serial quantitative assessment of load redistribution after medial open-wedge high tibial osteotomy. Orthop J Sports Med 2023;11(4):23259671231156188. https://doi.org/10.1177/23259671231156188.
[50] Kuriyama S, Watanabe M, Nakamura S, Nishitani K, Tanaka Y, Sekiguchi K, et al. Large medial proximal tibial angles cause excessively medial tibiofemoral contact forces and abnormal knee kinematics following open-wedge high tibial osteotomy. Clin Biomech 2020;80:105190. https://doi.org/10.1016/j.clinbiomech.2020.105190.
[51] Wylie JD, Scheiderer B, Obopilwe E, Baldino JB, Pavano C, Macken CJ, et al. The effect of lateral opening wedge distal femoral varus osteotomy on tibiofemoral contact mechanics through knee flexion. Am J Sports Med 2018;46(13):3237–44. https://doi.org/10.1177/0363546518799353.
[52] Ogawa H, Matsumoto K, Akiyama H. Effects of lateral opening wedge and medial closing wedge distal femoral osteotomies on axial load stability. Knee 2020;27(3): 760–6. https://doi.org/10.1016/j.knee.2020.04.019.
[53] Watrinet J, Joergens M, Blum P, Ehmann Y, Augat P, Stuby F, et al. Tibial tuberosity-trochlear groove distance is significantly decreased by medial closing wedge distal femoral osteotomy. Knee Surg Sports Traumatol Arthrosc 2024; 32(2):287–94. https://doi.org/10.1002/ksa.12053.
[54] Giffin JR, Vogrin TM, Zantop T, Woo SL, Harner CD. Effects of increasing tibial slope on the biomechanics of the knee. Am J Sports Med 2004;32(2):376–82. https://doi.org/10.1177/0363546503258880.
[55] Bernhardson AS, Aman ZS, Dornan GJ, Kemler BR, Storaci HW, Brady AW, et al. Tibial slope and its effect on force in anterior cruciate ligament grafts: anterior cruciate ligament force increases linearly as posterior tibial slope increases. Am J Sports Med 2019;47(2):296–302. https://doi.org/10.1177/0363546518820302.
[56] Baek SY, Beaulieu ML, Wojtys EM, Ashton-Miller JA. Relationship between lateral tibial posterior slope and tibiofemoral kinematics during simulated jump landings in male cadaveric knees. Orthop J Sports Med 2023;11(6):23259671231160213. https://doi.org/10.1177/23259671231160213.
[57] Agneskirchner JD, Hurschler C, Stukenborg-Colsman C, Imhoff AB, Lobenhoffer P. Effect of high tibial flexion osteotomy on cartilage pressure and joint kinematics: a biomechanical study in human cadaveric knees. Winner of the AGA-DonJoy Award 2004. Arch Orthop Trauma Surg 2004;124(9):575–84. https://doi.org/10.1007/s00402-004-0728-8.
[58] Pearce SL, Bryniarski AR, Brown JR, Brady AW, Gruskay JA, Dornan GJ, et al. Biomechanical analysis of tibial motion and ACL graft forces after ACLR with and without LET at varying tibial slopes. Am J Sports Med 2023;51(10):2583–8. https://doi.org/10.1177/03635465231184389.
[59] Bernhardson AS, Aman ZS, DePhillipo NN, Dornan GJ, Storaci HW, Brady AW, et al. Tibial slope and its effect on graft force in posterior cruciate ligament reconstructions. Am J Sports Med 2019;47(5):1168–74. https://doi.org/10.1177/0363546519827958.
[60] Imhoff FB, Comer B, Obopilwe E, Beitzel K, Arciero RA, Mehl JT. Effect of slope and varus correction high tibial osteotomy in the ACL-deficient and ACL-reconstructed knee on kinematics and ACL graft force: a biomechanical analysis.

Am J Sports Med 2021;49(2):410–6. https://doi.org/10.1177/0363546520976147.
[61] Kutzner I, Bender A, Dymke J, Duda G, von Roth P, Bergmann G. Mediolateral force distribution at the knee joint shifts across activities and is driven by tibiofemoral alignment. Bone Joint Lett J 2017;99-B(6):779–87. https://doi.org/10.1302/0301-620X.99B6.BJJ-2016-0713.R1.
[62] Song JH, Bin SI, Kim JM, Lee BS. What is an acceptable limit of joint-line obliquity after medial open wedge high tibial osteotomy? Analysis based on midterm results. Am J Sports Med 2020;48(12):3028–35. https://doi.org/10.1177/0363546520949552.
[63] Kim JS, Lim JK, Choi HG, Jeong HW, Park SB, Shim SJ, et al. Excessively increased joint-line obliquity after medial opening-wedge high tibial osteotomy is associated with inferior radiologic and clinical outcomes: what is permissible joint-line obliquity. Arthroscopy 2022;38(6):1904–15. https://doi.org/10.1016/j.arthro.2021.11.004.
[64] Kim GW, Kang JK, Song EK, Seon JK. Increased joint obliquity after open-wedge high tibial osteotomy induces pain in the lateral compartment: a comparative analysis of the minimum 4-year follow-up outcomes using propensity score matching. Knee Surg Sports Traumatol Arthrosc 2021;29(10):3495–502. https://doi.org/10.1007/s00167-020-06342-5.
[65] Kubota M, Kim Y, Sato T, Yamaguchi J, Ohno R, Kaneko K, et al. The actual knee function was not influenced by joint line obliquity after open-wedge high tibial osteotomy. SICOT J 2020;6:4. https://doi.org/10.1051/sicotj/2020001.
[66] Akamatsu Y, Nejima S, Tsuji M, Kobayashi H, Muramatsu S. Joint line obliquity was maintained after double-level osteotomy, but was increased after open-wedge high tibial osteotomy. Knee Surg Sports Traumatol Arthrosc 2022;30(2):688–97. https://doi.org/10.1007/s00167-020-06430-6.
[67] Xie T, Huizinga MR, van den Akker-Scheek I, van der Veen HC, Brouwer RW. Joint line obliquity after lateral closing-wedge high tibial osteotomy does not adversely affect clinical and radiological outcome: a 5-year follow-up study. Knee Surg Sports Traumatol Arthrosc 2023 Nov;31(11):4851-4860. https://doi.org/10.1007/s00167-023-07532-7.
[68] Xie T, Brouwer RW, van den Akker-Scheek I, van der Veen HC. Clinical relevance of joint line obliquity after high tibial osteotomy for medial knee osteoarthritis remains controversial: a systematic review. Knee Surg Sports Traumatol Arthrosc 2023 Oct;31(10):4355-4367. https://doi.org/10.1007/s00167-023-07486-w.
[69] Ollivier B, Berger P, Depuydt C, Vandenneucker H. Good long-term survival and patient-reported outcomes after high tibial osteotomy for medial compartment osteoarthritis. Knee Surg Sports Traumatol Arthrosc 2021;29(11):3569–84. https://doi.org/10.1007/s00167-020-06262-4.
[70] Tawy G, Shahbaz H, McNicholas M, Biant L. The relationships between coronal plane alignments and patient-reported outcomes following high tibial osteotomy: a systematic review. Cartilage 2021;13(1_suppl):132S–46S. https://doi.org/10.1177/19476035211007903.
[71] Elbardesy H, McLeod A, Ghaith HS, Hakeem S, Housden P. Outcomes of double level osteotomy for osteoarthritic knees with severe varus deformity. A systematic review. SICOT J 2022;8:7. https://doi.org/10.1051/sicotj/2022009.
[72] An JS, Mabrouk A, Khakha R, Kley K, Koga H, Jacquet C, et al. Assessment of return to sport and functional outcomes following distal femoral, double level and high tibial osteotomies for active patients with symptomatic varus malalignment. Knee Surg Sports Traumatol Arthrosc 2023 Oct;31(10):4285-4291. https://doi.org/10.1007/s00167-023-07457-1.
[73] Abdel Khalik H, Lameire DL, Rubinger L, Ekhtiari S, Khanna V, Ayeni OR. Return to sport and work following distal femoral varus osteotomy: a systematic review. HSS J 2022;18(2):297–306. https://doi.org/10.1177/15563316211051295.
[74] Coakley A, McNicholas M, Biant L, Tawy G. A systematic review of outcomes of high tibial osteotomy for the valgus knee. Knee 2023;40:97–110. https://doi.org/10.1016/j.knee.2022.11.007.
[75] Wang H, Man Q, Gao Y, Xu L, Zhang J, Ma Y, et al. The efficacy of medial meniscal posterior Root tear Repair with or without high tibial osteotomy: a systematic review. BMC Muscoskel Disord 2023;24(1):464. https://doi.org/10.1186/s12891-023-06520-9.
[76] Faber S, Angele P, Zellner J, Bode G, Hochrein A, Niemeyer P. Comparison of clinical outcome following cartilage repair for patients with underlying varus deformity with or without additional high tibial osteotomy: a propensity score-matched study based on the German cartilage registry (KnorpelRegister dgou). Cartilage 2021;13(1_suppl):1206S–16S. https://doi.org/10.1177/1947603520982347.
[77] Machado A, Micicoi L, Ernat J, Schippers P, Bernard de Dompsure R, Bronsard N, et al. Normo-or slightly overcorrection show better results after medial closing wedge high tibial osteotomy. Knee Surg Sports Traumatol Arthrosc 2023 Oct;31(10):4276-4284. https://doi.org/10.1007/s00167-023-07465-1.
[78] Rupp MC, Lindner F, Winkler PW, Muench LN, Mehl J, Imhoff AB, et al. Clinical effect of isolated lateral closing wedge distal femoral osteotomy compared to medial opening wedge high tibial osteotomy for the correction of varus malalignment: a propensity score-matched analysis. Am J Sports Med 2023;51(2):437–45. https://doi.org/10.1177/03635465221142615.
[79] Otsuki S, Ikeda K, Ishitani T, Okamoto Y, Wakama H, Matsuyama J, et al. Impact of the weightbearing line on cartilage regeneration of the medial knee compartment after open-wedge high tibial osteotomy, based on second-look arthroscopy. Cartilage 2022;13(4):87–93. https://doi.org/10.1177/19476035221137724.
[80] Dejour D, Saffarini M, Demey G, Baverel L. Tibial slope correction combined with second revision ACL produces good knee stability and prevents graft rupture. Knee Surg Sports Traumatol Arthrosc 2015;23(10):2846–52. https://doi.org/10.1007/s00167-015-3758-6.
[81] Liu Z, Jiang J, Yi Q, Teng Y, Liu X, He J, et al. An increased posterior tibial slope is associated with a higher risk of graft failure following ACL reconstruction: a systematic review. Knee Surg Sports Traumatol Arthrosc 2022;30(7):2377–87. https://doi.org/10.1007/s00167-022-06888-6.
[82] Bosco F, Giustra F, Giai Via R, Lavia AD, Capella M, Sabatini L, et al. Could anterior closed-wedge high tibial osteotomy be a viable option in patients with high posterior tibial slope who undergo anterior cruciate ligament reconstruction? A systematic review and meta-analysis. Eur J Orthop Surg Traumatol 2023;33(6):2201–14. https://doi.org/10.1007/s00590-022-03419-4.
[83] Jahn R, Cooper JD, Juhan T, Kang HP, Bolia IK, Gamradt SC, et al. Reliability of plain radiographs versus magnetic resonance imaging to measure tibial slope in sports medicine patients: can they Be used interchangeably? Orthop J Sports Med 2021;9(10):23259671211033882. https://doi.org/10.1177/23259671211033882.
[84] Alaia MJ, Kaplan DJ, Mannino BJ, Strauss EJ. Tibial sagittal slope in anterior cruciate ligament injury and treatment. J Am Acad Orthop Surg 2021;29(21):e1045–56. https://doi.org/10.5435/JAAOS-D-21-00143.
[85] Webb JM, Salmon LJ, Leclerc E, Pinczewski LA, Roe JP. Posterior tibial slope and further anterior cruciate ligament injuries in the anterior cruciate ligament-reconstructed patient. Am J Sports Med 2013;41(12):2800–4. https://doi.org/10.1177/0363546513503288.
[86] Lee CC, Youm YS, Cho SD, Jung SH, Bae MH, Park SJ, et al. Does posterior tibial slope affect graft rupture following anterior cruciate ligament reconstruction? Arthroscopy 2018;34(7):2152–5. https://doi.org/10.1016/j.arthro.2018.01.058.
[87] Grassi A, Pizza N, Zambon Bertoja J, Macchiarola L, Lucidi GA, Dal Fabbro G, et al. Higher risk of contralateral anterior cruciate ligament (ACL) injury within 2 years after ACL reconstruction in under-18-year-old patients with steep tibial plateau slope. Knee Surg Sports Traumatol Arthrosc 2021;29(6):1690–700. https://doi.org/10.1007/s00167-020-06195-y.
[88] Batty LM, Firth A, Moatshe G, Bryant DM, Heard M, McCormack RG, et al. Association of ligamentous laxity, male sex, chronicity, meniscal injury, and posterior tibial slope with a high-grade preoperative pivot shift: a post hoc analysis of the stability study. Orthop J Sports Med 2021;9(4):23259671211000038. https://doi.org/10.1177/23259671211000038.
[89] Christensen JJ, Krych AJ, Engasser WM, Vanhees MK, Collins MS, Dahm DL. Lateral tibial posterior slope is increased in patients with early graft failure after anterior cruciate ligament reconstruction. Am J Sports Med 2015;43(10):2510–4. https://doi.org/10.1177/0363546515597664.
[90] Yoon KH, Kim JH, Kwon YB, Kim EJ, Kim SG. Re-revision anterior cruciate ligament reconstruction showed more laxity than revision anterior cruciate ligament reconstruction at a minimum 2-year follow-up. Knee Surg Sports Traumatol Arthrosc 2020;28(6):1909–18. https://doi.org/10.1007/s00167-019-05653-6.
[91] Bernhardson AS, DePhillipo NN, Daney BT, Kennedy MI, Aman ZS, LaPrade RF. Posterior tibial slope and risk of posterior cruciate ligament injury. Am J Sports Med 2019;47(2):312–7. https://doi.org/10.1177/0363546518819176.
[92] Yoon KH, Lee JH, Kim SG, Park JY, Lee HS, Kim SJ, et al. Effect of posterior tibial slopes on graft survival rates at 10 Years after primary single-bundle posterior cruciate ligament reconstruction. Am J Sports Med 2023;51(5):1194–201. https://doi.org/10.1177/03635465231156621.
[93] Weiler A, Dickschas J, Gwinner C. Anterior open-wedge osteotomy in posterior cruciate ligament deficient knees: from a historical perspective to first clinical results. J Knee Surg 2021;34(6):592–8. https://doi.org/10.1055/s-0041-1723983.
[94] Watanabe S, Matsushita T, Nishida K, Nagai K, Hoshino Y, Matsumoto T, et al. Knee osteotomy decreases joint inflammation based on synovial histology and synovial fluid analysis. Arthroscopy 2024 Mar;40(3):830–43. https://doi.org/10.1016/j.arthro.2023.07.008. Epub 2023 Jul 18.
[95] Eberbach H, Mehl J, Feucht MJ, Bode G, Sudkamp NP, Niemeyer P. Geometry of the valgus knee: contradicting the dogma of a femoral-based deformity. Am J Sports Med 2017;45(4):909–14. https://doi.org/10.1177/0363546516676266.
[96] Feucht MJ, Winkler PW, Mehl J, Bode G, Forkel P, Imhoff AB, et al. Isolated high tibial osteotomy is appropriate in less than two-thirds of varus knees if excessive overcorrection of the medial proximal tibial angle should be avoided. Knee Surg Sports Traumatol Arthrosc 2021;29(10):3299–309. https://doi.org/10.1007/s00167-020-06166-3.
[97] Rupp MC, Muench LN, Ehmann YJ, Themessl A, Winkler PW, Mehl J, et al. Improved clinical outcome and high rate of return to low-impact sport and work after knee double level osteotomy for bifocal varus malalignment. Arthroscopy 2022;38(6):1944–53. https://doi.org/10.1016/j.arthro.2021.12.004.
[98] Pioger C, Mabrouk A, Siboni R, Jacquet C, Seil R, Ollivier M. Double-level knee osteotomy accurately corrects lower limb deformity and provides satisfactory functional outcomes in bifocal (femur and tibia) valgus malaligned knees. Knee Surg Sports Traumatol Arthrosc 2023;31(7):3007–14. https://doi.org/10.1007/s00167-023-07325-y.
[99] Nerhus TK, Ekeland A, Solberg G, Sivertsen EA, Madsen JE, Heir S. Radiological outcomes in a randomized trial comparing opening wedge and closing wedge

techniques of high tibial osteotomy. Knee Surg Sports Traumatol Arthrosc 2017; 25(3):910–7. https://doi.org/10.1007/s00167-015-3817-z.
[100] Nha KW, Kim HJ, Ahn HS, Lee DH. Change in posterior tibial slope after open-wedge and closed-wedge high tibial osteotomy: a meta-analysis. Am J Sports Med 2016;44(11):3006–13. https://doi.org/10.1177/0363546515626172.
[101] Kim JI, Kim BH, Han HS, Lee MC. Rotational changes in the tibia after high tibial valgus osteotomy: a comparative study of lateral closing versus medial opening wedge osteotomy. Am J Sports Med 2020;48(14):3549–56. https://doi.org/10.1177/0363546520960114.
[102] Sonnery-Cottet B, Mogos S, Thaunat M, Archbold P, Fayard JM, Freychet B, et al. Proximal tibial anterior closing wedge osteotomy in repeat revision of anterior cruciate ligament reconstruction. Am J Sports Med 2014;42(8):1873–80. https://doi.org/10.1177/0363546514534938.
[103] Hees T, Petersen W. Anterior closing-wedge osteotomy for posterior slope correction. Arthrosc Tech 2018;7(11):e1079–87. https://doi.org/10.1016/j.eats.2018.07.003.
[104] DePhillipo NN, Kennedy MI, Dekker TJ, Aman ZS, Grantham WJ, LaPrade RF. Anterior closing wedge proximal tibial osteotomy for slope correction in failed ACL reconstructions. Arthrosc Tech 2019;8(5):e451–7. https://doi.org/10.1016/j.eats.2019.01.001.
[105] Song GY, Ni QK, Zheng T, Zhang ZJ, Feng H, Zhang H. Slope-reducing tibial osteotomy combined with primary anterior cruciate ligament reconstruction produces improved knee stability in patients with steep posterior tibial slope, excessive anterior tibial subluxation in extension, and chronic meniscal posterior horn tears. Am J Sports Med 2020;48(14):3486–94. https://doi.org/10.1177/0363546520963083.
[106] Weiler A, Gwinner C, Wagner M, Ferner F, Strobel MJ, Dickschas J. Significant slope reduction in ACL deficiency can be achieved both by anterior closing-wedge and medial open-wedge high tibial osteotomies: early experiences in 76 cases. Knee Surg Sports Traumatol Arthrosc 2022;30(6):1967–75. https://doi.org/10.1007/s00167-022-06861-3.
[107] MacLean IS, Tyndall WA, Schenck RC, Miller MD. Varus collapse following anterior closing wedge proximal tibial osteotomy for ACL revision reconstruction: a case series. J Exp Orthop 2022;9(1):100. https://doi.org/10.1186/s40634-022-00539-y.
[108] Mayer P, Schuster P, Schlumberger M, Michalski S, Gesslein M, Beel W, et al. Effect of anterior tibial closing wedge osteotomy on coronal tibial alignment in relation to preoperative medial proximal tibial angle and wedge height. Am J Sports Med 2023;51(10):2567–73. https://doi.org/10.1177/03635465231181553.
[109] Müller S, Frosch KH, Frings J, Berninger M, Krause M. Biplanar high tibial osteotomy for the combined correction of varus and posterior tibial slope malalignment. Orthop Traumatol Surg Res 2023;109(4):103339. https://doi.org/10.1016/j.otsr.2022.103339.
[110] Dean CS, Chahla J, Moulton SG, Nitri M, Serra Cruz R, LaPrade RF. Anterolateral biplanar proximal tibial opening-wedge osteotomy. Arthrosc Tech 2016;5(3):e531–40. https://doi.org/10.1016/j.eats.2016.02.015.
[111] Avellan S, Mabrouk A, Taillebot V, Pithioux M, Ollivier M. Using a patient-specific cutting guide enables identical knee osteotomies: an evaluation of accuracy on sawbones. Orthop Traumatol Surg Res 2024:103813. https://doi.org/10.1016/j.otsr.2024.103813.
[112] Kobayashi H, Saito S, Akamatsu Y, Kumagai K, Nejima S, Inaba Y. The relationship between the "Fujisawa point" and anatomical femorotibial angle following simulated open wedge high tibial osteotomy. BMC Muscoskel Disord 2022;23(1):776. https://doi.org/10.1186/s12891-022-05734-7.
[113] Martay JL, Palmer AJ, Bangerter NK, Clare S, Monk AP, Brown CP, et al. A preliminary modeling investigation into the safe correction zone for high tibial osteotomy. Knee 2018;25(2):286–95. https://doi.org/10.1016/j.knee.2017.12.006.
[114] Rupp M-C, Mehl J, Feucht MJ, Imhoff AB. Biomechanical rationale of correction osteotomy and overcorrection. Operat Tech Sports Med 2022;30(3):150930. https://doi.org/10.1016/j.otsm.2022.150930.
[115] Tripon M, Sautet P, Argenson JN, Jacquet C, Martz P, Ollivier M. Is the lateral tibial spine a reliable landmark for planning tibial or femoral valgus osteotomies? Orthop Traumatol Surg Res 2022;108(3):103253. https://doi.org/10.1016/j.otsr.2022.103253.
[116] Dawson MJ, Ollivier M, Menetrey J, Beaufils P. Osteotomy around the painful degenerative varus knee: a 2022 ESSKA formal consensus. Knee Surg Sports Traumatol Arthrosc 2023;31(8):3041–3. https://doi.org/10.1007/s00167-022-07024-0.
[117] Rupp M-C, Mehl J, Feucht MJ, Imhoff AB. Biomechanical rationale of correction osteotomy and overcorrection. Operat Tech Sports Med 2022;30(3):150930. https://doi.org/10.1016/j.otsm.2022.150930.
[118] van Egmond N, Stolwijk N, van Heerwaarden R, van Kampen A, Keijsers NLW. Gait analysis before and after corrective osteotomy in patients with knee osteoarthritis and a valgus deformity. Knee Surg Sports Traumatol Arthrosc 2017;25(9):2904–13. https://doi.org/10.1007/s00167-016-4045-x.
[119] Vadhera AS, Knapik DM, Gursoy S, Farivar D, Perry AK, Cole BJ, et al. Current concepts in anterior tibial closing wedge osteotomies for anterior cruciate ligament deficient knees. Curr Rev Musculoskelet Med 2021;14(6):485–92. https://doi.org/10.1007/s12178-021-09729-0.
[120] Dan MJ, Cance N, Pineda T, Demey G, Dejour DH. Four to 6 degrees is the target posterior tibial slope after tibial deflection osteotomy according to the knee static anterior tibial translation. Arthroscopy 2024 Mar;40(3):846–54. https://doi.org/10.1016/j.arthro.2023.07.007. Epub 2023 Jul 19.