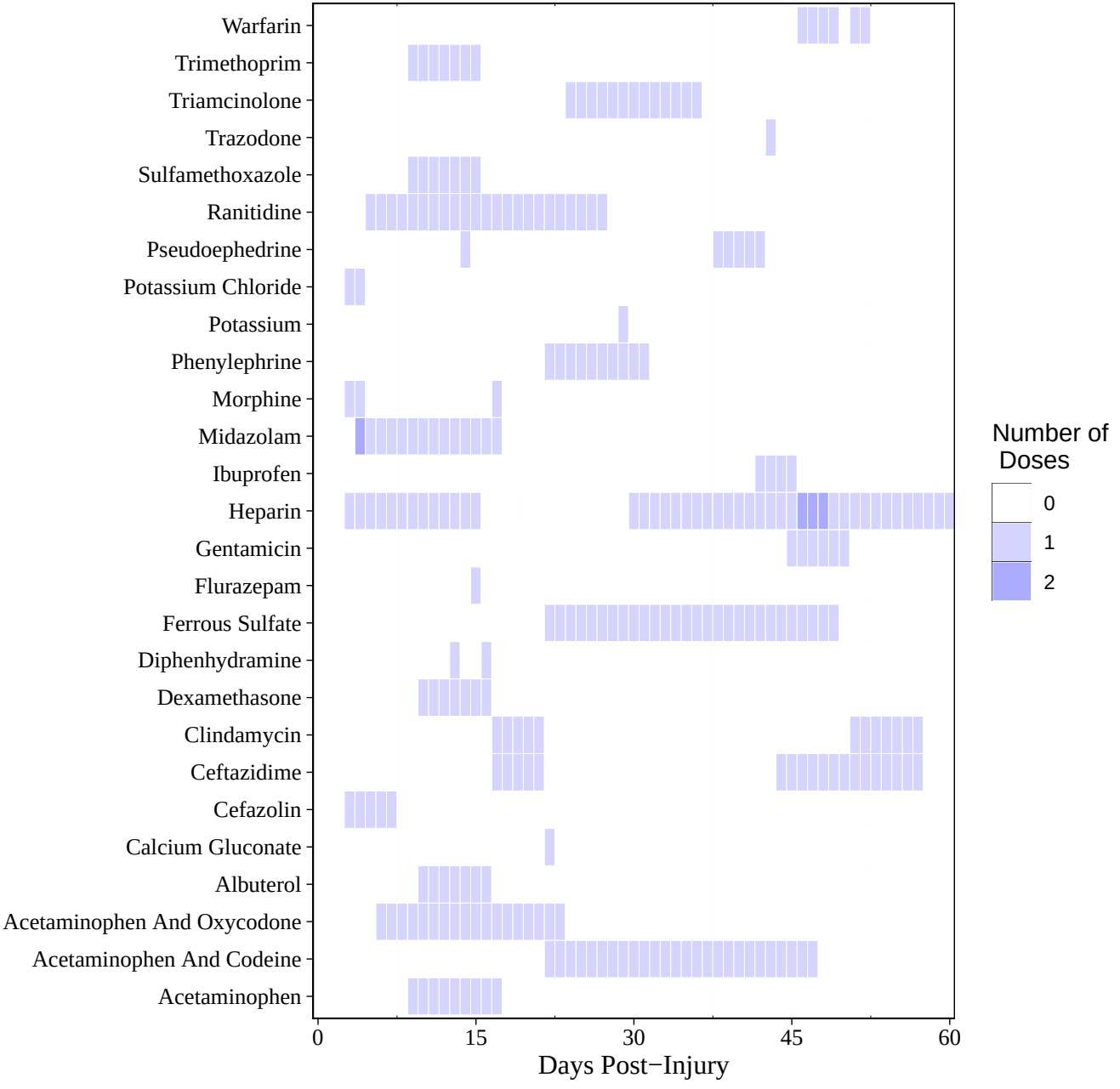Male, AIS A, Thoracic (T04), Gun shot wound