Full-scale vs. Abbreviated Sequences in MR Mammography – the Best of Both Worlds

Clemens Kaiser, M.D.

Department of Radiology and Nuclear Medicine, University Medical Center Mannheim, Germany

Background

According to the current state of the literature, MR Mammography detects breast cancer with the highest accuracy of all imaging techniques. Since 1984, when the first scientific results were published, more than 15,000 publications have followed, proving the diagnostic benefit of this method [1].

MRI offers unique soft-tissue contrast that can be enhanced using contrast agents to reliably detect tumor-angiogenic processes and carcinomas from a size of 2–3 mm [2, 3]. A significant portion of carcinomas are verifiable by MR Mammography only [4–6]. In addition, this method enables the dependable detection of carcinomas in an early stage [6–8]. This can be prognostically very important for patients.

Literature has shown that preoperative staging with MR Mammography reduces the local rate of recurrence and influences therapy decisions significantly [9–12]. In 3% of all cases, this led to detection of contra-lateral carcinomas, too.

With a negative predictive value of 100% [13], MR Mammography can, moreover, exclude invasive carcinomas with certainty, impacting on biopsy rates and leading to reduced patient stress due to a more reliable diagnosis.

Screening women with dense breast tissue

Despite these well-known diagnostic benefits, only a few patients get to profit from MR Mammography in Germany (and many other countries) because the examination is currently only indicated and reimbursed in a few exceptional indications, e.g., high-risk screening collectives [14].

At the same time, conventional breast cancer screening programs have not managed to decrease mortality

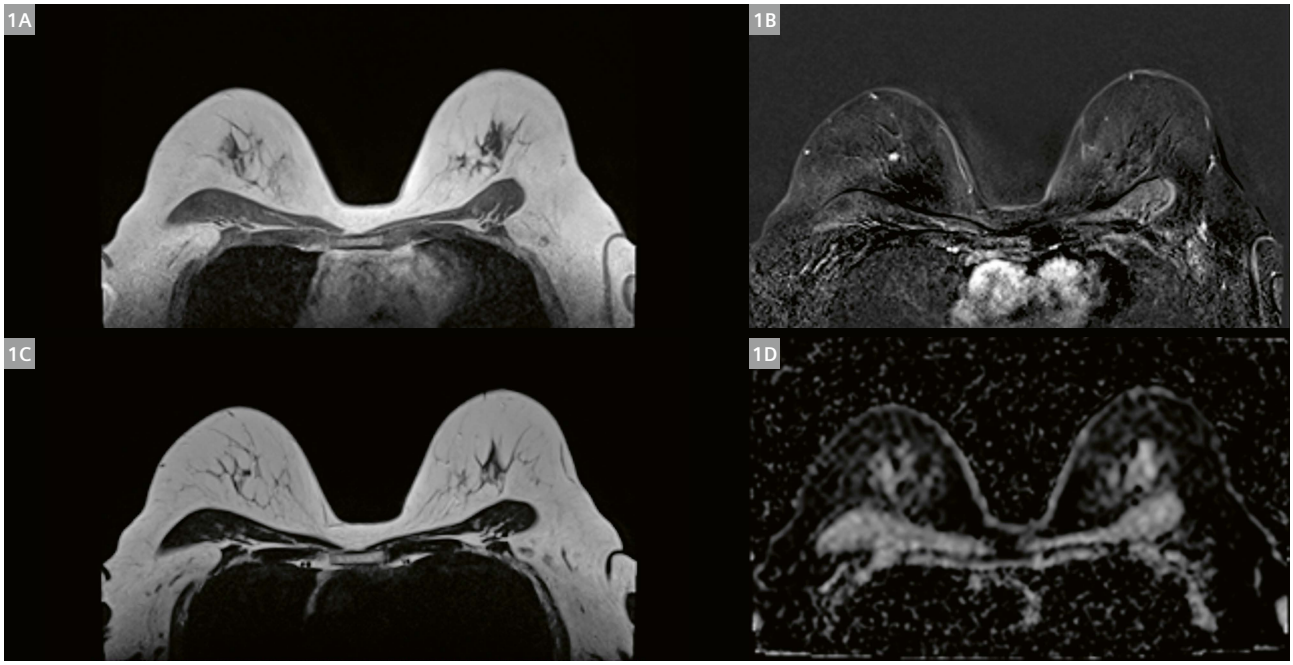

1 **(1A)** First minute post application of 1 mmol/kg Gd; **(1B)** First min subtraction, **(1C)** T2-weighted scan; **(1D)** ADC map. The scan reveals a 3 mm carcinoma in the upper inner quadrant. The lesion shows a type 3 curve, pos. Root Sign and hypointensity in T2. Due to its size and the resolution it is not visible in the ADC map.

rates from breast cancer significantly – neither nationally nor internationally [15]. This could indicate a possible new diagnostic role for MR Mammography, especially as a screening tool for women of average risk of developing breast cancer but with dense breast tissue, following the experience of, for example, Dutch screening algorithms.

There has, however, been critical discussion in the past of the financial aspects in particular, as these present the main barriers to the acceptance of MR Mammography as a screening tool.

In 2019, extensive new data on the screening of women with dense breast tissue using MR Mammography was published, indicating a significant reduction in interval carcinomas [7, 8] and giving a first hint of evidence of a reduction in mortality through the use of MR Mammography as a screening tool with interval carcinomas as an accepted surrogate marker for mortality.

Cost-effective MR Mammography

In addition to delivering gratifying clinical results, these data also enabled a cost-effectiveness analysis that showed that MR Mammography is cost-effective [16].

Early detection of small carcinomas in the breast saves on subsequent additional therapy costs. Especially for women with breast tissue of high density, MR Mammography offers a cost-efficient and accurate screening tool. That is why its role in prevention should be reconsidered.

An additional approach to reduce the costs of examination with MRI, is "abbreviated protocol magnetic resonance imaging" (AB-MRI). The aim of AB-MRI is to reduce scan time and thereby the costs of examinations by omitting some sequences for better use in high-throughput screening settings.

As early as 2012, Fischer et al. proposed [17] that acquiring just pre- and post-gadolinium (Gd) injection T1-weighted sequences could reduce scan times and costs significantly while at the same time benefiting from the high negative predictive value of MR Mammography as breast cancer could be excluded without evidence of Gd enhancement. In cases when gadolinium enhancement is visible, a full-scale examination, including T2-weighted images and a complete dynamic series is required. This results in additional costs and nevertheless a second charge of contrast medium.

Further publications, for example by Kuhl et al. [18], showed that such an approach represents a full-featured alternative to conventional diagnostic mammography and is at least equivalently cost-effective in comparison.

Over the last 10 years, more and more publications have investigated various approaches to reducing costs by applying different sets of selected sequences, sometimes relying on diffusion-weighted images only, and have reported varying results.

Abbreviated vs. full-scale protocols

As of today, there is still a lack of definition of abbreviated protocols. The major studies commonly agree on a pre-contrast and a post-contrast image as well as T2-weighted images if the total length of the protocol does not exceed 10 minutes in total length [19].

While the study has impressively demonstrated that AB-MRI allows to detect significantly more invasive carcinomas at an earlier point in time than digital breast tomosynthesis (DBT) in women with dense breast [19] it remains unknown how the overall performance characteristics would have been improved with a full scale MR Mammography protocol.

MR scanners from Siemens Healthineers with NumarisX software now offer new acquisition techniques that enable radiologists to perform a full-scale MR examination in under 10 minutes, the time frame of abbreviated protocols and far below regular acquisition times of full-scale protocols.

The best of both worlds

At University Hospital Mannheim, a 1.5T MAGNETOM Sola is being used for standard MR Mammography examinations. This scanner is equipped with the Turbo Suite Excelerate package that includes the Simultaneous Multi-Slice (SMS) acquisition technique.

With SMS, it is possible to excite and readout multiple slices simultaneously, effecting a remarkable acceleration. SMS can be used for TSE sequences as well as for diffusion-weighted imaging (DWI) and can also be combined with iPAT.

MR Mammography for clinical diagnostic routine was set up with the following protocols:

- 3 mm axial T2 TSE with iPAT 2 and SMS 2.
  Inplane resolution: 0.8 × 0.8 mm², 56 slices,
  TA: 1:36 min.
- 3 mm axial EPI Diffusion (b-values 50 s/mm² and 800 s/mm²) 3-scan trace with iPAT 2 and SMS 2.
  Inplane resolution: 1.5 × 1.5 mm² (interpolated), 56 sl.,
  TA: 1:46 min.
- 1.5 mm axial T1 fl3d as dynamic series
  (1+5, 20s delay), with iPAT 3.
  Inplane resolution: 0.9 × 0.9 mm², 112 sl., TA: 6:21 min.

The .exar1 protocol is available for download at:
www.siemens-healthineers.com/magnetom-world
> Clinical Corner > Protocols > Breast MRI

At our institution we are using a 18-channel BI Mammography coil; the program, however, may also be used with other (high-channel) MR Mammography coils with very similar or the same parameters.

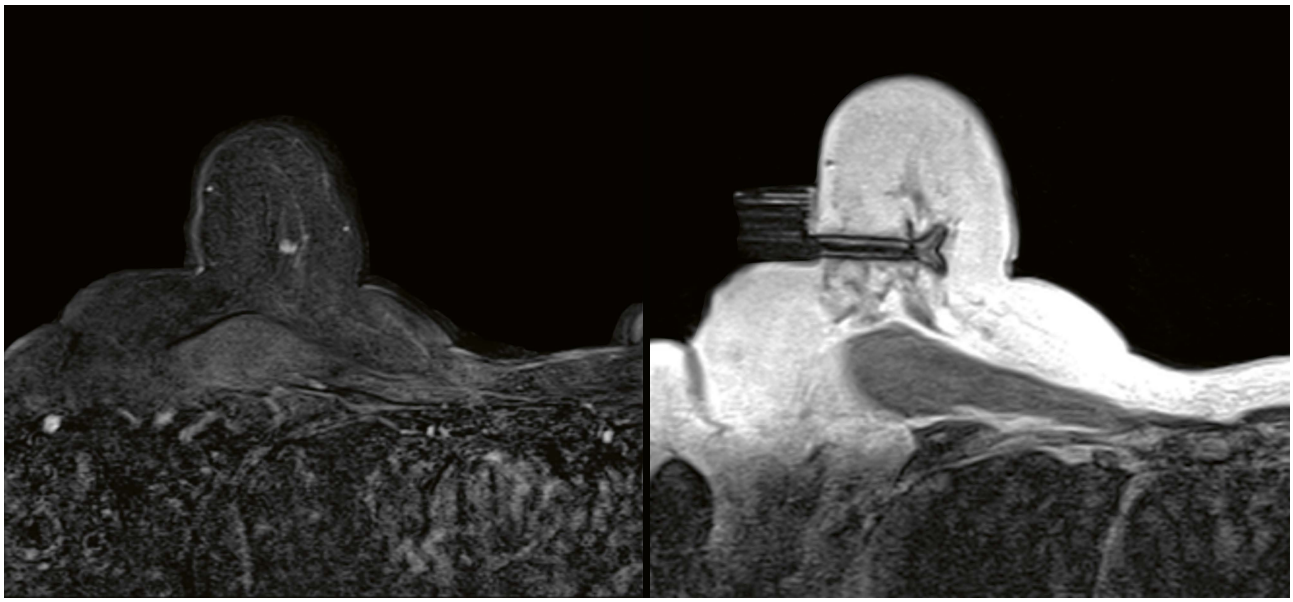

2 MR-guided wire localization before open surgical excision.

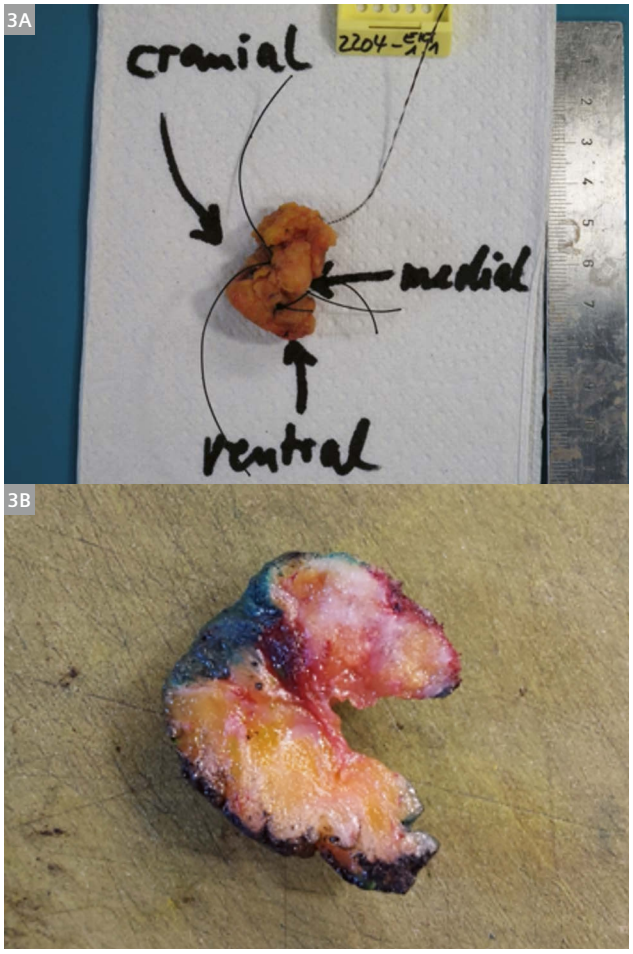

3 **(3A)** Excised specimen, **(3B)** excised specimen after coloring.

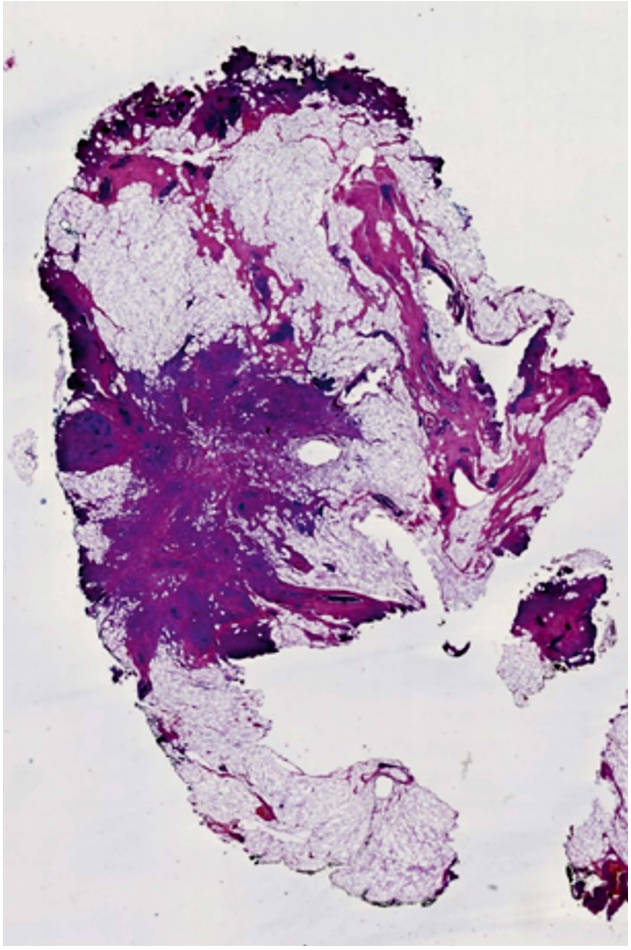

4 Histopathological slice revealing an invasive ductal carcinoma, 3 mm.

The full set of dynamic T1-weighted sequences (pre-injection and 5 minutes post injection of 1 mmol/kg Gd) with a time resolution of exactly 1 minute each is hereby adopted from standing protocols as suggested in the BIRADS Lexicon. The full dynamic set covering 6 minutes enables the reader to evaluate kinetic details in depth, a key requirement in optimizing the specificity of MR Mammography. Depicting all 6 minutes has been considered most time-consuming in the formation of abbreviated sequences and was therefore the main subject of protocol abbreviation.

T2-weighted sequences – as they are indicated in abbreviated as well as in full-scale protocols – are essential in assessing morphological aspects of lesions as they usually cover the field of view with a significantly higher resolution. T2-weighted sequences also deliver highly important diagnostic information, such as micro bleeding, perifocal, or prepectoral edema [20, 21].

Diffusion-weighted imaging enables the assessment of diffusibility and offers additional room to increase specificity [22–25], although a certain resolution bias makes assessing small and non-focal lesions difficult.

Both T2- and diffusion-weighted sequences can be acquired without significant loss of image quality in half the acquisition time using SMS [26], paving the way to a full-scale protocol in under 10 minutes and making screening women outside current indications feasible.

Conclusion

With SMS the need for abbreviated protocols may be overrated. You no longer need to decide between full-scale or abbreviated protocols, because the measurement time is now so short that you can confidently run a full-scale protocol just as efficiently as an abbreviated one.

This should be a giant step towards a feasible solution for screening women outside current indications.

Acknowledgments

I highly appreciate the support of Thomas Illigen, Siemens Healthineers, Erlangen, Germany, in setting up the protocol and supporting this manuscript.

References

1 Kaiser WA, Zeitler E (1989) MR imaging of the breast: fast imaging sequences with and without Gd-DTPA. Preliminary observations. Radiology 170:681–686.
2 Folkman J, Watson K, Ingber D, Hanahan D (1989) Induction of angiogenesis during the transition from hyperplasia to neoplasia. Nature 339:58–61.
3 Buadu LD, Murakami J, Murayama S, et al. (1996) Breast lesions: correlation of contrast medium enhancement patterns on MR images with histopathologic findings and tumor angiogenesis. Radiology 200:639–649.
4 Kuhl C, Weigel S, Schrading S, et al. (2010) Prospective multicenter cohort study to refine management recommendations for women at elevated familial risk of breast cancer: the EVA trial. J Clin Oncol Off J Am Soc Clin Oncol 28:1450–1457.
5 Sardanelli F, Podo F, Santoro F, et al. (2011) Multicenter surveillance of women at high genetic breast cancer risk using mammography, ultrasonography, and contrast-enhanced magnetic resonance imaging (the high breast cancer risk italian 1 study): final results. Invest Radiol 46:94–105.
6 Riedl CC, Luft N, Bernhart C, et al. (2015) Triple-modality screening trial for familial breast cancer underlines the importance of magnetic resonance imaging and questions the role of mammography and ultrasound regardless of patient mutation status, age, and breast density. J Clin Oncol Off J Am Soc Clin Oncol 33:1128–1135.
7 Bakker MF, de Lange SV, Pijnappel RM, et al (2019) Supplemental MRI Screening for Women with Extremely Dense Breast Tissue. N Engl J Med 381:2091–2102.
8 Veenhuizen SGA, de Lange SV, Bakker MF, et al. (2021) Supplemental Breast MRI for Women with Extremely Dense Breasts: Results of the Second Screening Round of the DENSE Trial. Radiol 299(2):278-286.
9 Fisher B, Anderson S, Redmond CK, et al. (1995) Reanalysis and results after 12 years of follow-up in a randomized clinical trial comparing total mastectomy with lumpectomy with or without irradiation in the treatment of breast cancer. N Engl J Med 333:1456–1461.
10 Jacobson JA, Danforth DN, Cowan KH, et al. (1995) Ten-year results of a comparison of conservation with mastectomy in the treatment of stage I and II breast cancer. N Engl J Med 332:907–911.
11 Fowble BL, Solin LJ, Schultz DJ, Goodman RL (1991) Ten year results of conservative surgery and irradiation for stage I and II breast cancer. Int J Radiat Oncol Biol Phys 21:269–277.
12 Haffty BG, Goldberg NB, Rose M, et al. (1989) Conservative surgery with radiation therapy in clinical stage I and II breast cancer. Results of a 20-year experience. Arch Surg Chic Ill 1960 124:1266–1270.
13 Bennani-Baiti B, Baltzer PA (2017) MR Imaging for Diagnosis of Malignancy in Mammographic Microcalcifications: A Systematic Review and Meta-Analysis. Radiology 283:692–701.
14 (2020) S3-Leitlinie Mammakarzinom. 453
15 Krebs - Brustkrebs. https://www.krebsdaten.de/Krebs/DE/Content/Krebsarten/Brustkrebs/brustkrebs_node.html Accessed 3 Mar 2020
16 Kaiser CG, Dietzel M, Vag T, Froelich MF (2020) Cost-effectiveness of MR-Mammography vs. conventional Mammography in screening patients at intermediate risk of breast cancer - A model-based economic evaluation. Eur J Radiol. 136:109355.
17 Fischer U, Korthauer A, Baum F, et al. (2012) Short first-pass MRI of the breast. Acta Radiol 53:267–269.
18 Kuhl CK, Schrading S, Strobel K, et al. (2014) Abbreviated breast magnetic resonance imaging (MRI): first postcontrast subtracted images and maximum-intensity projection-a novel approach to breast cancer screening with MRI. J Clin Oncol Off J Am Soc Clin Oncol 32:2304–2310.

19 Comstock CE, Gatsonis C, Newstead GM, et al. (2020) Comparison of Abbreviated Breast MRI vs Digital Breast Tomosynthesis for Breast Cancer Detection Among Women With Dense Breasts Undergoing Screening. JAMA 323:746–756.

20 Baltzer P a. T, Dietzel M, Gajda null, et al. (2012) A systematic comparison of two pulse sequences for edema assessment in MR-mammography. Eur J Radiol 81:1500–1503.

21 Kaiser CG, Herold M, Baltzer PAT, et al. (2015) Is "prepectoral edema" a morphologic sign for malignant breast tumors? Acad Radiol 22:684–689.

22 Hatakenaka M, Soeda H, Yabuuchi H, et al. (2008) Apparent diffusion coefficients of breast tumors: clinical application. Magn Reson Med Sci MRMS Off J Jpn Soc Magn Reson Med 7:23–29.

23 Kuroki Y, Nasu K (2008) Advances in breast MRI: diffusion-weighted imaging of the breast. Breast Cancer Tokyo Jpn 15:212–217.

24 Wenkel E, Geppert C, Schulz-Wendtland R, et al. (2007) Diffusion weighted imaging in breast MRI: comparison of two different pulse sequences. Acad Radiol 14:1077–1083.

25 Woodhams R, Matsunaga K, Iwabuchi K, et al. (2005) Diffusion-weighted imaging of malignant breast tumors: the usefulness of apparent diffusion coefficient (ADC) value and ADC map for the detection of malignant breast tumors and evaluation of cancer extension. J Comput Assist Tomogr 29:644–649.

26 Riffel J, Kannengiesser S, Schoenberg SO, et al. (2021) T2-weighted Imaging of the Breast at 1.5T Using Simultaneous Multi-slice Acceleration. Anticancer Res 41:4423–4429.

Contact

PD Dr. med. Clemens Kaiser, M.D.
Section Chief Breast
Department of Radiology
and Nuclear Medicine
University Medical Center Mannheim
Theodor-Kutzer-Ufer 1–3
68167 Mannheim
Phone: +49 (0)621 383-0
clemens.kaiser@umm.de

Advertisement

View the Women's Health Session from the 11th MAGNETOM World Summit

DENSE Trial – Implications for Breast Cancer Screening
Carla van Gils (University Medical Center Utrecht, The Netherlands)

Repetitive HR-MRI of the Breast at Intervals of 24 Months – a way to Reduce Mortality?
Uwe Fischer (Diagnostisches Brustzentrum Göttingen, Germany)

Implementing Abbreviated MRI Screening into a Breast Imaging Practice
Donna Plecha (University Hospitals Cleveland, OH, USA)

Abbreviated Breast MRI. The Royal Melbourne Journey
Angela Agostinelli (The Royal Melbourne Hospital, Parkville, Victoria, Australia)

Treatment Response Assessment with MRI
Susan Weinstein (Penn Medicine, University of Pennsylvania, Philadelphia, PA, USA)

MRI in Breast Cancer: From Bench to Bedside & Beyond. MRI-derived Parameters for Hormone Receptors
Katja Pinker-Domenig (Medical University Vienna, Austria / Memorial Sloan Kettering Cancer Center, New York, NY, USA)

Siemens-Healthineers.com/MWS2020-recordings



Graphic recording: www.gabriele-heinzel.com