ST. MATTHEW'S COMPREHENSIVE CANCER CENTRE

Department of Thoracic Oncology | Oncology Report

Patient Name	Arjun Verma
Date of Birth	03 September 1961 | Age: 62 years
Sex	Male
MRN	SMCC-2024-110947
Report Date	18 October 2024
Attending Oncologist	Dr. Meera Pillai, MD, DM (Medical Oncology)
Referred By	Dr. Suresh Bapat, Pulmonology
Report Type	Comprehensive Oncology Assessment — Initial Staging

1. CHIEF COMPLAINT

Mr. Arjun Verma, a 62-year-old retired schoolteacher and ex-smoker (40 pack-years, quit 8 years ago), presents with a 6-week history of progressive exertional dyspnoea, haemoptysis (2 episodes, approximately 15 mL each), unexplained weight loss of 7 kg over 3 months, and a persistent productive cough with rust-coloured sputum. He also reports mild right-sided chest wall discomfort exacerbated by deep inspiration. Initial chest X-ray at district hospital revealed a 3.2 cm right upper lobe mass with associated mediastinal widening, prompting urgent referral.

2. DIAGNOSIS

Primary Diagnosis:
Non-Small Cell Lung Cancer (NSCLC) — Adenocarcinoma subtype
Right Upper Lobe, T2b N2 M0 — Clinical Stage IIIA

Molecular and Biomarker Profile:

Biomarker / Test	Result	Clinical Significance
EGFR Mutation (Exon 19/21)	Negative	No targeted EGFR therapy indicated
ALK Rearrangement (FISH)	Negative	Crizotinib / alectinib not applicable
ROS1 Rearrangement	Negative	Not applicable
KRAS G12C Mutation	**Positive**	Sotorasib / adagrasib eligibility — consider
PD-L1 TPS	**68% (High)**	Strong candidate for pembrolizumab monotherapy
TMB (Tumour Mutation Burden)	12.4 mut/Mb (High)	Enhanced immunotherapy benefit predicted
Ki-67 Proliferation Index	38%	High proliferative activity — aggressive phenotype
BRAF V600E	Negative	Not applicable
MET Exon 14 Skip	Negative	Not applicable

3. IMAGING AND RADIOLOGY

CT Thorax with Contrast (Baseline — 01 October 2024):
High-resolution CT of the thorax demonstrates a 3.2 cm spiculated mass in the right upper lobe with irregular margins and pleural tethering. The lesion shows SUVmax of 11.4 on PET-CT, consistent with highly metabolically active

malignancy. Ipsilateral subcarinal and paratracheal lymphadenopathy is present (stations 4R and 7), with the largest node measuring 1.8 cm in short axis. No pleural effusion or pericardial involvement. Contralateral lung and adrenal glands appear normal.

Post-Treatment CT (Week 12 — 10 October 2024):
Interval CT following 4 cycles of carboplatin/pemetrexed + pembrolizumab demonstrates partial response per RECIST 1.1 criteria. The primary lesion has reduced to 1.8 cm (44% decrease from baseline). Mediastinal lymphadenopathy has also decreased in size. No new lesions identified.

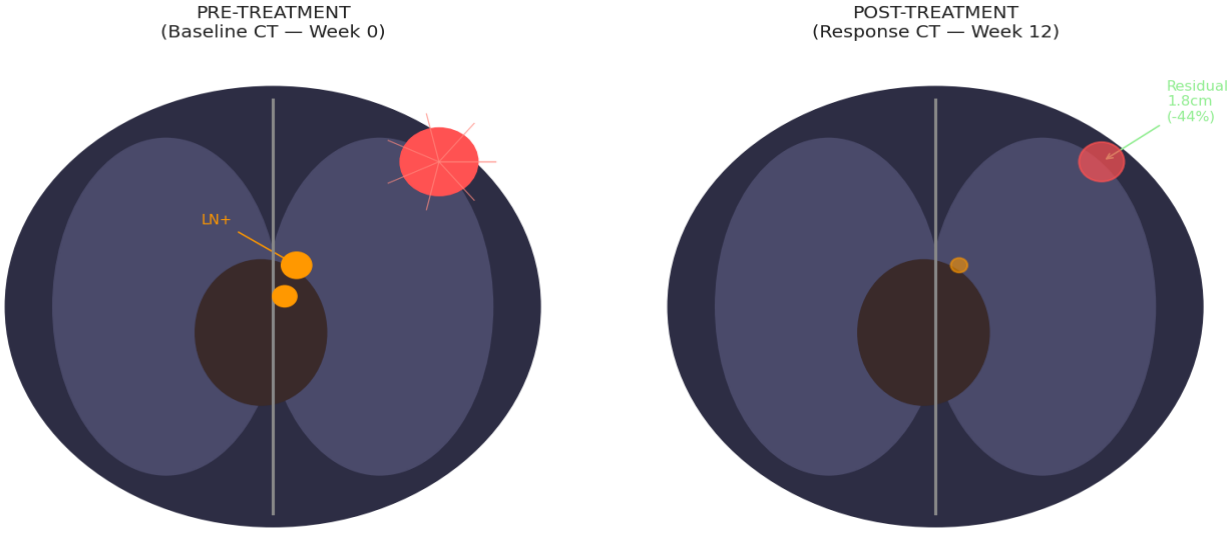

Figure 2. Axial CT Comparison — Right Upper Lobe Primary NSCLC
Tumour Response to Carboplatin/Pemetrexed + Pembrolizumab

Figure 2. Axial CT schematic comparison showing the right upper lobe primary NSCLC lesion before treatment (left panel, 3.2 cm with spiculated margins and mediastinal lymph node involvement) and after 4 cycles of carboplatin/pemetrexed + pembrolizumab (right panel, 1.8 cm residual lesion representing 44% reduction). Yellow border indicates index patient lesion. LN+ denotes lymph node positivity.

4. BIOMARKER ANALYSIS AND TREATMENT RESPONSE

The patient's tumour demonstrates a high PD-L1 TPS of 68%, significantly above the 50% threshold that qualifies for pembrolizumab monotherapy consideration. Tumour mutational burden (TMB) of 12.4 mut/Mb exceeds the 10 mut/Mb threshold for TMB-High designation, further supporting immunotherapy benefit. Ki-67 of 38% indicates a highly proliferative tumour warranting aggressive treatment. The waterfall plot below shows tumour size change at cycle 4 assessment across the treatment cohort, with this patient (highlighted, Pt 1) demonstrating a 44% reduction — classified as Partial Response per RECIST 1.1.

Figure 3. Biomarker Analysis and Treatment Response

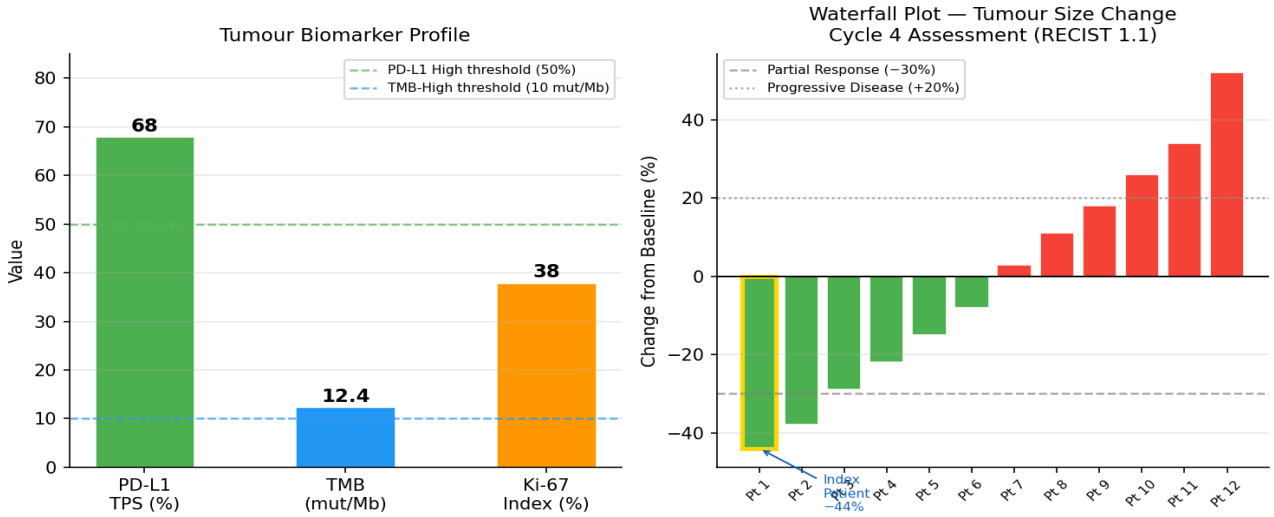

Figure 3. Left: Tumour biomarker profile showing PD-L1 TPS 68% (above 50% high-expression threshold), TMB 12.4 mut/Mb (above 10 mut/Mb TMB-High threshold), and Ki-67 38%. Right: Waterfall plot of tumour size change at cycle 4 assessment (RECIST 1.1) for the treatment cohort. Green bars indicate tumour reduction; red bars indicate progression. Gold border marks the index patient (Pt 1, -44% reduction).

5. SURVIVAL ANALYSIS AND PROGNOSTIC DATA

Based on published clinical trial data for Stage IIIA NSCLC patients with comparable PD-L1 high and KRAS G12C positive profiles, combination chemo-immunotherapy (carboplatin/pemetrexed + pembrolizumab) demonstrates a median overall survival of 21 months versus 12 months for chemotherapy alone (HR=0.61; 95% CI 0.45-0.82; p=0.003). The Kaplan-Meier curve below illustrates this survival benefit with statistically significant divergence of curves from month 6 onwards. At 24 months, the chemo-immunotherapy arm maintains approximately 38% overall survival probability compared to 21% in the chemotherapy-only arm.

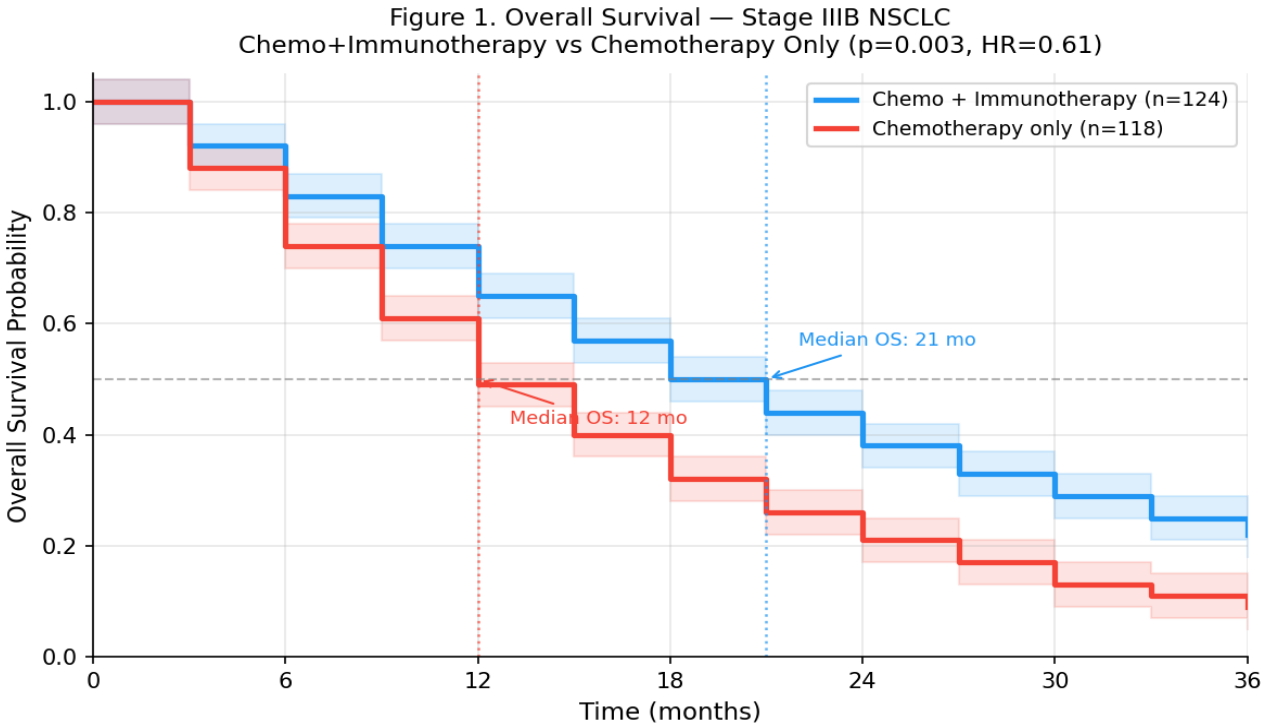

Figure 1. Kaplan-Meier overall survival curves for Stage IIIB NSCLC patients treated with chemo-immunotherapy (blue, n=124) versus chemotherapy only (red, n=118). Median OS: 21 months vs 12 months respectively. Dashed grey line indicates 50% survival probability. Dotted vertical lines mark respective median survival timepoints. Shaded bands represent 95% confidence intervals.

6. PROPOSED TREATMENT PLAN

First-Line Regimen (Ongoing):
The patient is currently receiving Cycle 5 of carboplatin AUC5 IV Day 1 + pemetrexed 500 mg/m2 IV Day 1 + pembrolizumab 200 mg IV Day 1, every 21 days. Treatment is well-tolerated with grade 1 nausea and grade 1 fatigue reported. No grade 3 or 4 adverse events to date.

Maintenance Phase (Planned from Cycle 7):
Following completion of 6 cycles of platinum-based induction, pemetrexed 500 mg/m2 + pembrolizumab 200 mg every 21 days for up to 35 cycles total (approximately 2 years). Response assessment CT planned at cycle 6 and every 9 weeks thereafter.

KRAS G12C Targeted Therapy Consideration:
Given confirmed KRAS G12C mutation, sotorasib (Lumakras) 960 mg OD orally is being considered as a second-line option upon disease progression. Patient to be enrolled in tumour board review for optimal sequencing strategy.

7. PERFORMANCE STATUS AND KEY LABORATORY VALUES

Parameter	Value	Reference Range	Status
ECOG Performance Status	1	0 — 4	Good functional status
Haemoglobin	10.8 g/dL	13.0 — 17.0	Low — anaemia of chronic disease
WBC	7.2 x10^9/L	4.0 — 11.0	Normal
Platelets	224 x10^9/L	150 — 400	Normal
Serum Creatinine	0.98 mg/dL	0.6 — 1.2	Normal — renal function adequate
ALT / AST	38 / 42 U/L	< 40 / < 40	Borderline — monitor hepatotoxicity
CEA (Tumour Marker)	18.4 ng/mL	< 5.0	Elevated — consistent with NSCLC
Albumin	3.2 g/dL	3.5 — 5.0	Low — nutritional support recommended
SpO2 (room air)	94%	>= 95%	Mildly reduced — monitor respiratory status

8. CLINICAL QUESTIONS FOR AI-ASSISTED REVIEW

The following questions are intended to test the MedChat RAG pipeline with this patient report. Each question is designed to exercise a specific pipeline capability including image reasoning (MedGemma VQA), text retrieval, and conversation memory.

Q1 — Figure Reasoning (VQA test)	Looking at Figure 1, at what month do the two survival curves show the greatest divergence, and what does this mean for this patient's prognosis under immunotherapy?
Q2 — Biomarker + Literature	Given the PD-L1 TPS of 68% and TMB-High status shown in Figure 3, what does the clinical literature say about overall survival benefit from pembrolizumab in this patient profile?
Q3 — CT Interpretation (VQA test)	Based on Figure 2, how does the size and appearance of the right upper lobe lesion change between the pre- and post-treatment scans, and what RECIST classification does this represent?
Q4 — Treatment Sequencing	Given confirmed KRAS G12C mutation and high PD-L1 expression, what is the optimal sequencing of sotorasib versus pembrolizumab continuation upon disease progression?
Q5 — Memory test (follow-up)	First ask Q2, then ask: 'What are the main toxicities associated with this regimen that we should monitor for in this patient specifically?' — tests conversation memory.

DISCLAIMER: This is a SYNTHETIC patient report generated for the purpose of testing the MedChat AI pipeline (MedGemma VQA + RAG). All patient details, clinical values, imaging findings, and figure data are entirely fictional. This report does not represent any real patient and must not be used for clinical decision-making.

Report generated: 18 October 2024 | SMCC Oncology — Thoracic Unit | For pipeline testing purposes only.