scientific data

OPEN

DATA DESCRIPTOR

A Radiograph Dataset for the Classification, Localization, and Segmentation of Primary Bone Tumors

Shunhan Yao[1,2], Yuanxiang Huang[3], Xiaoyu Wang[2], Yiwen Zhang[4], Ian Costa Paixao[2], Zhikang Wang[2], Charla Lu Chai[2], Hongtao Wang[5], Dinggui Lu[6], Geoffrey I Webb[7], Shanshan Li[4], Yuming Guo[4], Qingfeng Chen[3,7] ✉ & Jiangning Song[2] ✉

Primary malignant bone tumors are the third highest cause of cancer-related mortality among patients under the age of 20. X-ray scan is the primary tool for detecting bone tumors. However, due to the varying morphologies of bone tumors, it is challenging for radiologists to make a definitive diagnosis based on radiographs. With the recent advancement in deep learning algorithms, there is a surge of interest in computer-aided diagnosis of primary bone tumors. Nonetheless, the development in this field has been hindered by the lack of publicly available X-ray datasets for bone tumors. To tackle this challenge, we established the Bone Tumor X-ray Radiograph dataset (termed BTXRD) in collaboration with multiple medical institutes and hospitals. The BTXRD dataset comprises 3,746 bone images (1,879 normal and 1,867 tumor), with clinical information and global labels available for each image, and distinct mask and annotated bounding box for each tumor instance. This publicly available dataset can support the development and evaluation of deep learning algorithms for the diagnosis of primary bone tumors.

Background & Summary

Recent advances in Artificial Intelligence (AI), especially deep learning, have provided transformative possibilities in computer-aided diagnosis systems. Deep learning-based techniques, such as segmentation, detection, classification, and enhancement, have been successfully applied to medical imaging[1–3]. Existing studies demonstrate the potential of these techniques in identifying and analyzing bone tumors from X-ray images, highlighting a significant advancement in radiology[4]. While these findings are encouraging, integrating existing research into clinical diagnostic workflows still remains a significant challenge[5], due to small sample sizes, limited lesion types, and restricted data sources. Moreover, most existing models overlook several clinical factors like age, gender, and the location of bone lesions that play significant roles in the clinical classification of bone tumors. One of the reasons for the slow progress in computer-aided diagnosis of primary bone tumors is the lack of large, well-annotated, and open-source datasets of bone tumor X-ray images. This deficiency impedes the development of new models and raises doubts about the performance of existing models. However, due to the low incidence rate of primary bone tumors[6] and widely dispersed patients, it is difficult for researchers to access large and diverse medical datasets[7]. Furthermore, annotating bone tumor imaging data can be extremely costly, as it requires the consensus of numerous doctors and radiologists to eliminate biases and human errors[8]. In conclusion, the development of large, well-annotated, open-source bone tumor X-ray image datasets is

[1]Medical College, Guangxi University, Nanning, Guangxi, 530000, China. [2]Biomedicine Discovery Institute and Department of Biochemistry and Molecular Biology, Monash University, Melbourne, VIC, 3800, Australia. [3]School of Computer, Electronic and Information, Guangxi University, Nanning, Guangxi, 530000, China. [4]School of Public Health and Preventive Medicine, Monash University, Level 2, 553 St Kilda Road, Melbourne, VIC, 3004, Australia. [5]Bone and Joint Surgery, The First Affiliated Hospital of Guangxi Medical University, Nanning, Guangxi, 530000, China. [6]Department of Traumatology, The Affiliated Hospital of Youjiang Medical University for Nationalities, Baise, Guangxi, 533000, China. [7]Department of Data Science and AI, Faculty of Information Technology, Monash University, Melbourne, VIC, 3800, Australia. ✉e-mail: qingfeng@gxu.edu.cn; jiangning.song@monash.edu

Dataset	Release year	sources	Samples*	Global labels	Clinical labels	Local labels	Local mask	Multi-locale	Open-source
MedPix[9]	2016	Multicenter	—#	Available	P/A	N/A	N/A	Yes	Yes
Radiopaedia.org[10]	2007	Multicenter	—#	Available	P/A	N/A	N/A	Yes	Yes
IIEST[11]	2020	Single-center	69	Available	N/A	N/A	N/A	Yes	Yes
Yu He[12]	2020	Multicenter	2899	Available	N/A	Available	N/A	Yes	No
CNUH[13]	2021	Single-center	1193	Available	N/A	N/A	Available	No	No
Claudio[14]	2021	Multicenter	1045	Available	N/A	Available	Available	Yes	No
Renyi Liu[15]	2021	Single-center	982	Available	Available	Available	N/A	Yes	No
Dan Yu[18]	2022	Single-center	872	Available	N/A	Available	Available	No	No
Park CW[19]	2022	Single-center	214	Available	N/A	N/A	N/A	No	No
SARAH[20]	2022	Single-center	44	Available	N/A	N/A	N/A	No	No
Zhiyuan Xu[21]	2022	Single-center	119	Available	N/A	N/A	N/A	Yes	No
Jie Li[22]	2023	Multicenter	1085	Available	N/A	Available	N/A	Yes	No
Turkka[23]	2023	Single-center	500	Available	N/A	Available	Available	No	No
Sebastian[24]	2023	Single-center	366	Available	N/A	N/A	N/A	No	No
Jingjing Shao[16]	2024	Multicenter	666	Available	N/A	N/A	N/A	Yes	No
Florian[17]	2024	Single-center	809	Available	Available	N/A	N/A	Yes	No
BTXRD	**2024**	**Multicenter**	**1867**	**Available**	**Available**	**Available**	**Available**	**Yes**	**Yes**

Table 1. An overview of existing X-ray datasets. *Contains only bone tumor image number. #The data cannot be effectively counted.

hindered by significant costs and time constraints. Therefore, no such datasets are currently publicly available on a global scale. Some public datasets including bone tumor X-ray images have been developed, such as MedPix[9], Radiopaedia[10], and IIEST[11]. However, most of them lack annotation or labels, which is important for the training of AI models. MedPix[9] is a free medical image database managed and maintained by the United States (U.S.) National Library of Medicine. It contains thousands of images from various medical fields such as radiology, pathology, and dermatology. We identified 1,157 images related to bone tumors in MedPix. However, these images are a mix of different imaging types such as X-rays, real images, magnetic resonance imaging (MRI), computed tomography (CT) scans, and ultrasound, which prevents us from directly obtaining the specific images needed for model training. Also, some images in this dataset lack tissue annotations or are mislabeled, making them unsuitable for direct use in deep learning. Radiopaedia.org[10] is an open platform dedicated to online radiology education which hosts a large collection of X-ray images with detailed clinical information and satisfactory quality, many of which are bone tumor X-rays. However, they still lack labels or annotations before being used for deep learning. IIEST[11] is an X-ray dataset containing 217 images, but only 69 of which are scans of bone tumors. This useful dataset is still insufficient for training deep learning models constrained by its small size.

Currently, bone tumor studies based on X-ray images, including classification, localization, and segmentation, all use private datasets[12–24]. Yu He *et al.*[12] obtained 2,899 X-ray images of bone tumors from five medical institutions, of which 2,158 were non-malignant and 741 were malignant. However, these images lack clinical information such as gender, age, and location. Von Schacky's CNUH dataset[13] includes 1,195 tumor images and 381 normal images. Although this is a large dataset, it only covers knee bone tumors. Claudio E *et al.*[14] collected 1,045 bone tumor X-ray images (743 benign images and 302 malignant images), without any normal bone images. Renyi Liu *et al.*[15] collected 982 bone tumor X-ray images, demographic information (age, gender, location), and other clinical information from 643 patients. However, this dataset comes from a single center and does not include normal bone X-ray images. Recently, Jingjing Shao *et al.*[16] created a dataset by collecting X-ray images and clinical information from 333 patients with knee joint giant cell tumors or osteolytic osteosarcomas from four centers. Florian *et al.*[17] gathered 1,792 X-ray images of bone tumors from a single center, which provided the anatomical location of the lesions. In addition to the datasets mentioned above, there are several other private datasets (e.g., datasets established by Dan Yu[18], Park CW[19], and SARAH[20]). Although each of these datasets has unique characteristics, none are publicly available. Therefore, it is difficult for researchers to obtain and verify this kind of data, which hinders the development of machine-learning models for bone tumor diagnosis. Table 1 summarizes the existing datasets of bone tumor X-ray images and compares them with the BTXRD dataset.

In summary, the bone tumor X-ray images available in the existing public datasets are limited and cannot be used directly, while private datasets are not publicly accessible. This impedes the development of computer-aided diagnosis of primary bone tumors. To address this research gap, we developed an X-ray image dataset named BTXRD (accessible at figshare.com [https://doi.org/10.6084/m9.figshare.27865398]). The BTXRD was designed to facilitate research on the automatic classification, localization, and segmentation of primary bone tumors in radiographs. This dataset includes 3,746 images, with 1,879 normal bone images, 1,525 benign bone tumor images, and 342 malignant bone tumor images. Each image in the BTXRD dataset is labeled with gender, age, the part of the body imaged, and the shooting angle. Specifically, each bone tumor image is additionally tagged with benign or malignant labels, subtype labels, and anatomical site labels. Furthermore, each bone tumor image

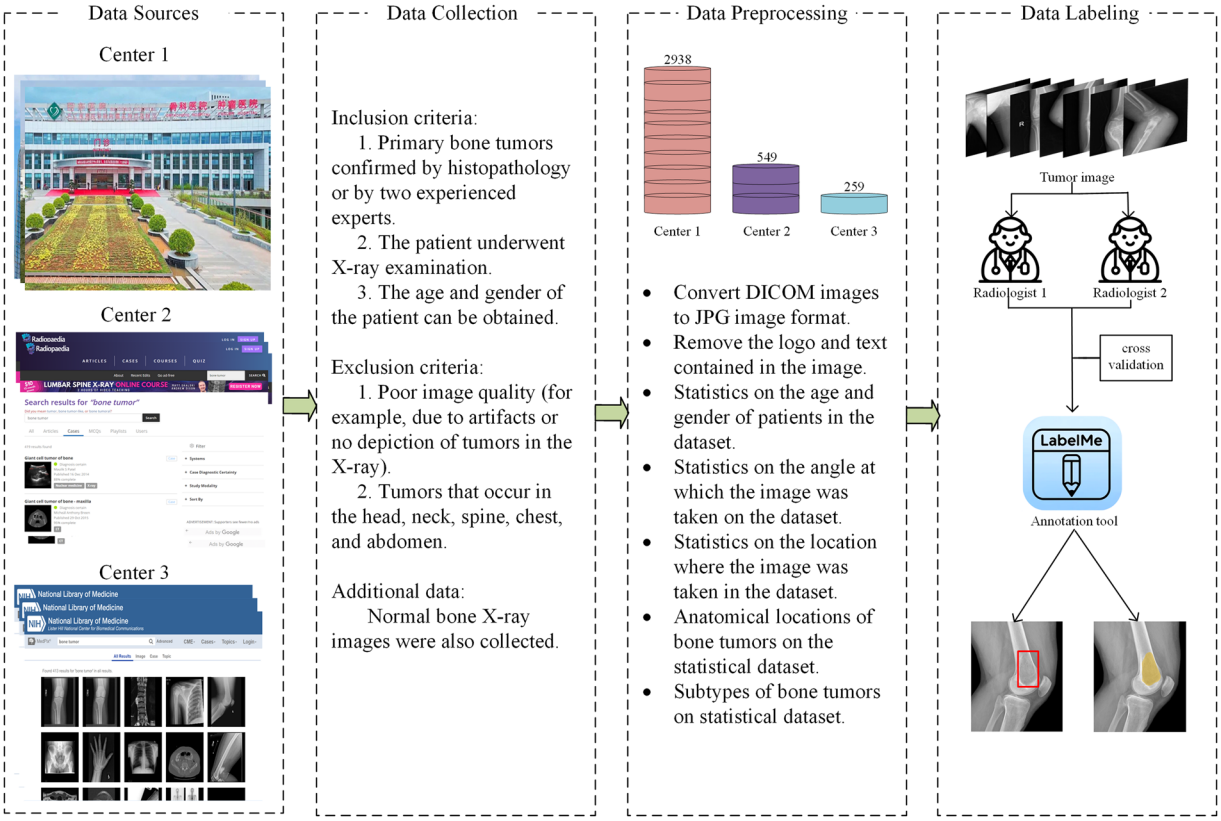

Fig. 1 Workflow for establishing the BTXRD dataset: (1) Collect X-ray images of bone tumors and normal bones from multiple centers. (2) Convert DICOM format images to JPEG, remove all identifiable sensitive information such as names, addresses, and hospital numbers, and manually record only the corresponding gender and age for each image. (3) Annotate the final image set with the help of two radiology experts for use in various deep learning applications.

has been manually annotated with its own mask and bounding box. To confirm the dataset's suitability for deep learning algorithms, we used YOLOv8s, YOLOv8s-seg, and YOLOv8s-cls deep learning networks to validate.

Methods

Ethical clearance. This retrospective study was approved by the Research Ethics Board of the Medical College at Guangxi University (GULL240522). Due to the study's retrospective nature and the non-invasive methods used, as well as the anonymity of the data, the informed consent requirement was waived. The study complies with the image usage terms of MedPix[9] and Radiopaedia.org[10].

Data sources. The BTXRD dataset's images were sourced from three medical image storage centers. Center 1 includes three hospitals in China: the First Affiliated Hospital of Guangxi Medical University, the Affiliated Hospital of Youjiang Medical College for Nationalities, and Baise People's Hospital. Center 2 is the Radiopaedia.org online platform, and Center 3 is the MedPix public database. The BTXRD dataset collected X-ray images of patients with primary bone tumors from Center 1, which were confirmed histologically or by two radiology experts, from July 2013 to July 2023. Additionally, two radiology experts collected X-ray images of bone tumors from Centers 2 and 3 by searching the following keywords: 'bone tumor,' 'osteochondroma,' 'osteosarcoma,' 'bone cyst,' 'fibrous dysplasia,' 'chondroblastoma,' 'fibroma of bone,' 'osteoma,' 'hemangioma,' 'aneurysmal bone cyst,' 'osteolipoma,' 'giant cell tumor of bone,' 'osteoblastoma,' 'chondrosarcoma,' 'Ewing's sarcoma,' 'undifferentiated pleomorphic sarcoma,' 'fibrosarcoma,' 'angiosarcoma,' and 'epithelioid hemangioendothelioma.' Only images that include corresponding gender and age information were included in the dataset. Each image in the dataset is unique, but some may come from the same lesion, as we collected images from different shooting angles (frontal, lateral, and oblique views) for each lesion. The workflow of this study is illustrated in Fig. 1, with the main steps, including data collection, data cleaning, and data annotation.

Data collection and preprocessing. X-ray images obtained from Center 1 were downloaded in the Digital Imaging and Communications in Medicine (DICOM) format from the Picture Archiving and Communication System (PACS, GE Healthcare). These images were then converted from DICOM to 8-bit grayscale JPEG (Joint Photographic Experts Group) format. Images from Centers 2 and 3 were directly downloaded in JPEG format from their official websites, respectively (accessed February 20–28, 2024). In the collected data, we removed primary bone tumor samples from the head, neck, chest, and abdominal regions since their amount was limited and

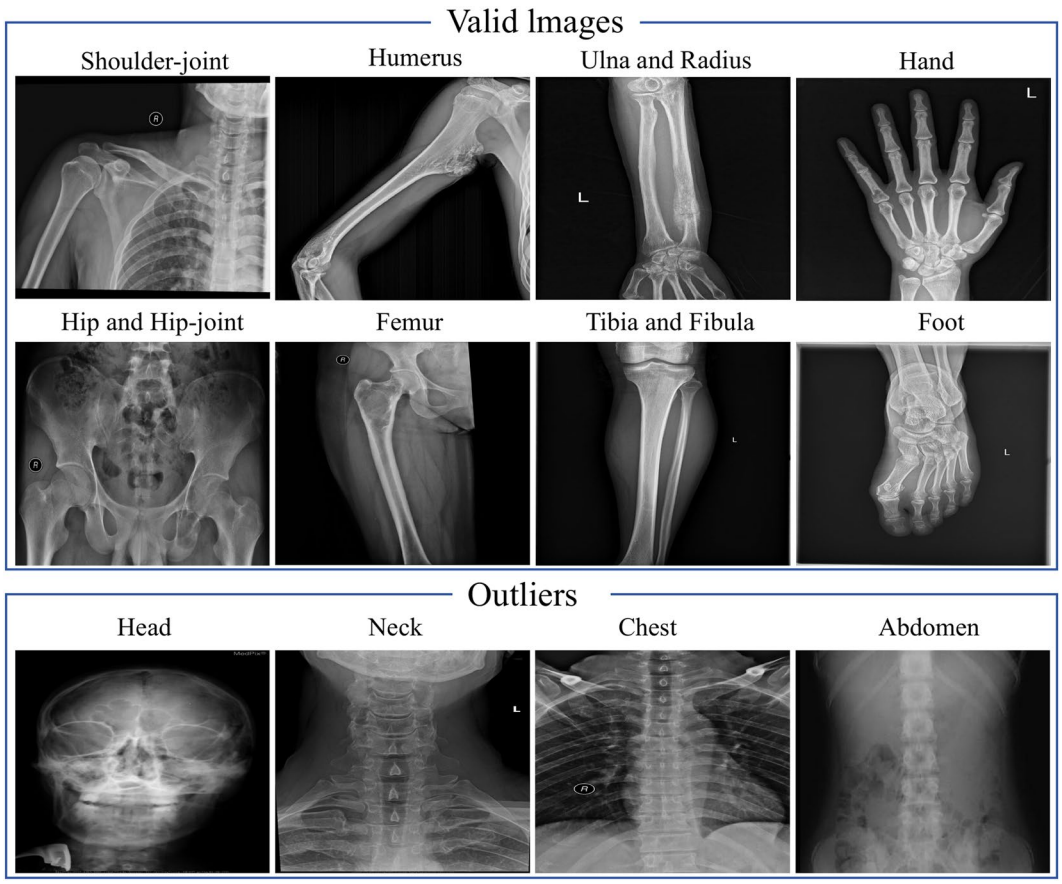

Fig. 2 Examples of valid (upper) vs. outlier (lower) X-ray images. All scans were manually filtered based on the body parts present in the scan, the clarity of the scans, and the resolution. The BTXRD dataset includes only bone tumor images from the upper limbs (hands, ulna, radius, humerus, wrist joints, elbow joints, and shoulder joints), lower limbs (feet, tibia, fibula, femur, ankle joints, and knee joints), and pelvis (hips, hip joints). The BTXRD dataset also collected X-ray images of normal bones from the upper limbs, lower limbs, and pelvis across the three centers.

BTXRD	Age (y)	Gender (M/F)	Normal	B-Tumor*	M-Tumor#	Total
Center 1	40.36 ± 19.23	1600/1338	1593	1110	235	2938
Center 2	22.32 ± 14.57	326/223	259	214	76	549
Center 3	22.58 ± 13.75	172/87	27	201	31	259
Total	37.53 ± 19.58	2098/1648	1879	1525	342	3746

Table 2. The basic characteristics of BTXRD. *B-Tumor refers to benign bone tumor, #M-Tumor refers to malignant bone tumor.

had many artifacts. Consequently, the BTXRD dataset only includes bone tumor images from the upper limbs (hands, ulna, radius, humerus, wrist joints, elbow joints, and shoulder joints), lower limbs (feet, tibia, fibula, femur, ankle joints, and knee joints), and pelvis (hips, hip joints). The BTXRD dataset also collected X-ray images of normal bones from the upper limbs, lower limbs, and pelvis across the three centers. Figure 2 displays some representative and outlier images from the BTXRD dataset.

Data statistics. In the initial phase, the BTXRD dataset included a total of 10,089 images. After data cleaning, 3,746 images were retained. Of these, 2,938 images (1,593 normal, 1,110 benign bone tumors, and 235 malignant bone tumors) are from Center 1; 549 images (259 normal, 214 benign bone tumors, and 76 malignant bone tumors) are from Center 2; and 259 images (27 normal, 201 benign bone tumors, and 31 malignant bone tumors) are from Center 3. The general distribution characteristics of the BTXRD dataset are listed in Table 2.

The age of patients for the images in the BTXRD dataset ranges from 1 to 88 years, with a particular concentration in the age groups of 10–20 years and 50–60 years. The age distribution of the images in the BTXRD dataset is depicted in Fig. 3A. Additionally, as shown in Fig. 3B, the BTXRD dataset contains 1,124 upper limb images (672 normal, 452 tumor), 2,406 lower limb images (1,095 normal, 1,311 tumor), and 216 pelvic images

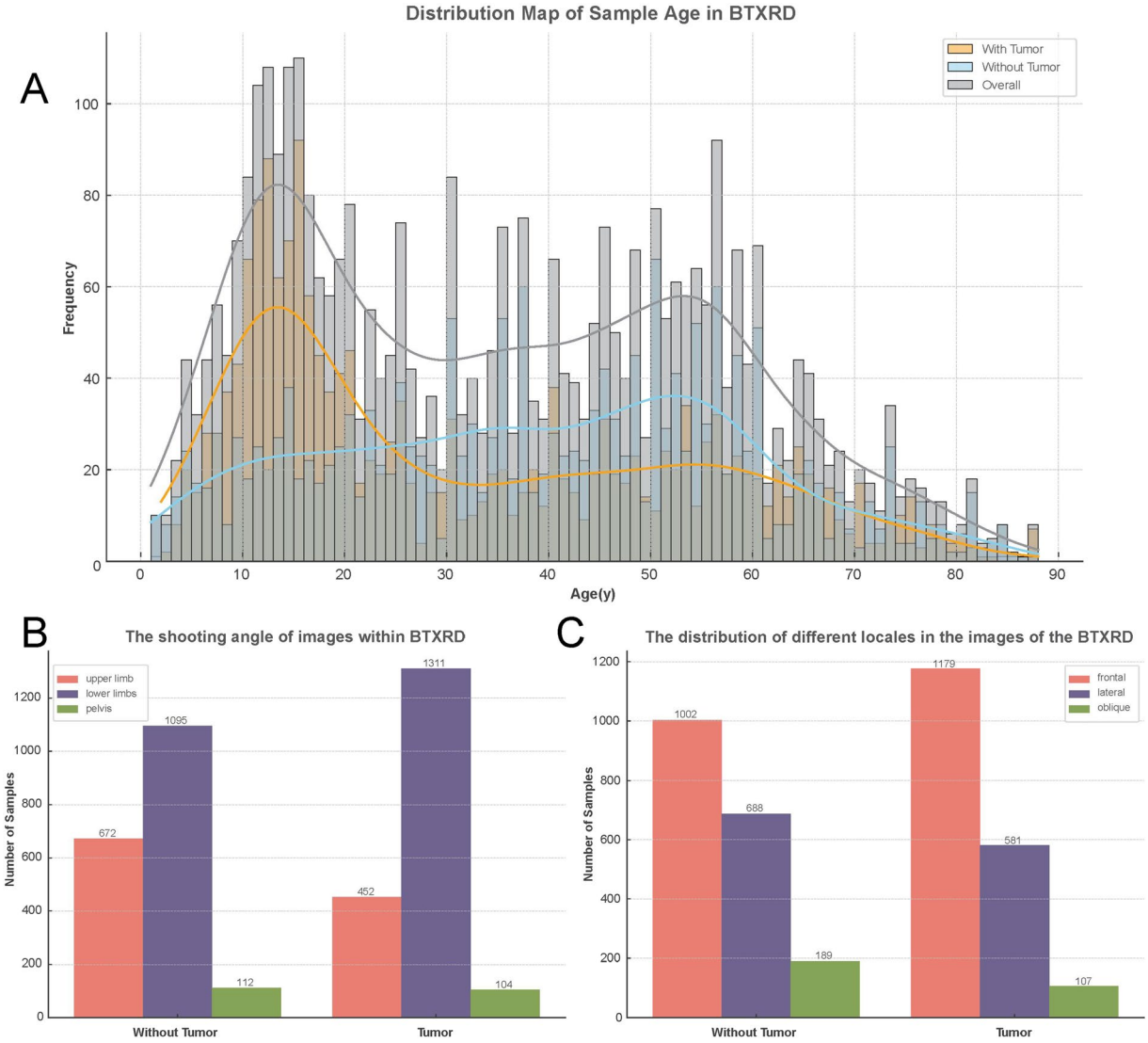

Fig. 3 Distribution of age, region, and viewing angle of images in the BTXRD dataset. (**A**) shows the age distribution of the images in the BTXRD dataset. (**B**) presents the distribution of upper limb, lower limb, and pelvic regions of images in the BTXRD dataset. (**C**) presents the distribution of frontal, lateral, and oblique views of images in the BTXRD dataset.

(112 normal, 104 tumor). As illustrated in Fig. 3C, there are 2,181 frontal images (1,002 normal, 1,179 tumor), 1,269 lateral images (688 normal, 581 tumor), and 296 oblique images (189 normal, 107 tumor) in the BTXRD dataset.

Distribution of tumor subtypes and anatomical locations. We analyzed the anatomical locations of bone tumors in the BTXRD dataset, with the most common sites being the tibia (630 lesions), femur (592 lesions), fibula (259 lesions), and humerus (235 lesions). The detailed distribution of bone tumor anatomical locations is shown in Fig. 4. Additionally, we cataloged the subtypes of bone tumors present in the BTXRD dataset images. The most frequent subtypes were osteochondroma (754 lesions), osteosarcoma (297 lesions), multiple osteochondromatosis (263 lesions), and simple bone cyst (206 lesions). The detailed distribution of bone tumor subtypes is illustrated in Fig. 5.

Data labeling. In the data labeling process, a bone tumor specialist with 10 years of diagnostic experience used the Labelme[25] image annotation tool to segment tumors and outline them with bounding boxes. This initial annotation was subsequently reviewed by another specialist with 20 years of experience. To evaluate the reliability of the annotations, 50 bone tumor images were randomly selected from the dataset and re-segmented with bounding boxes reapplied one month after the initial work. The Dice score for the two segmentations was recorded at 0.90 ± 0.07, and the Intersection over Union (IoU) value for the bounding box placements was 0.91 ± 0.06, indicating high consistency between the two sets of annotations. Labelme is an open-source image annotation tool[25]; in our study, we used it to draw rectangular bounding boxes to indicate the location and boundaries of target

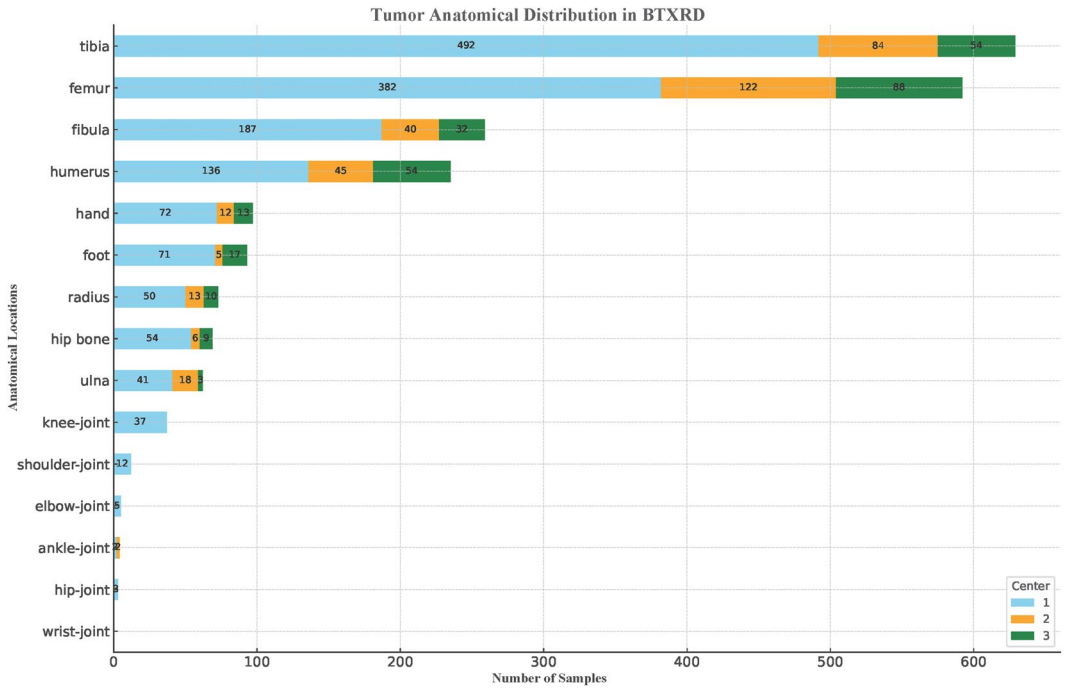

Fig. 4 Distribution of anatomical locations of bone tumors in the BTXRD dataset. This figure illustrates the number of bone tumors occurring in 15 different anatomical locations, along with the data contribution from each of the three centers.

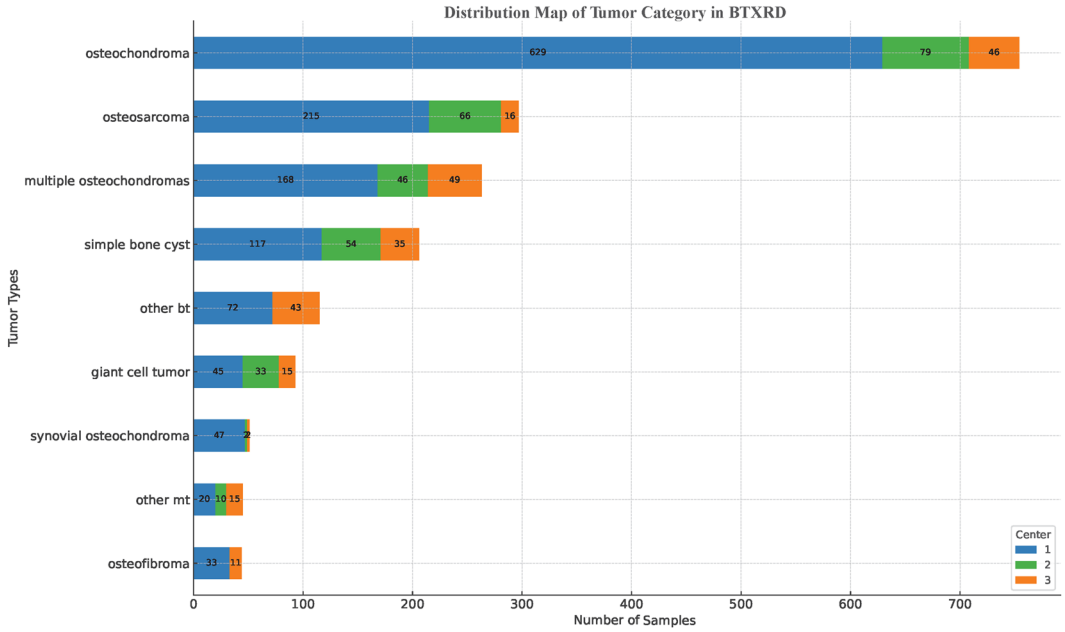

Fig. 5 Distribution of bone tumor subtypes in the BTXRD dataset. The figure shows the number of nine different subtypes of bone tumors, along with the data contribution from each of the three centers. 'other bt' represents a collection of several benign tumors with a small number, while 'other mt' represents a collection of several malignant tumors with a small number.

objects, and polygons for segmenting the target objects. After annotation, all annotation information was saved in the JSON (JavaScript Object Notation) format. Additionally, label information for each image such as gender, age, anatomical site, and shooting location was recorded in Comma Separated Values (CSV) format files. Figure 6 shows the different types of annotations provided in the dataset.

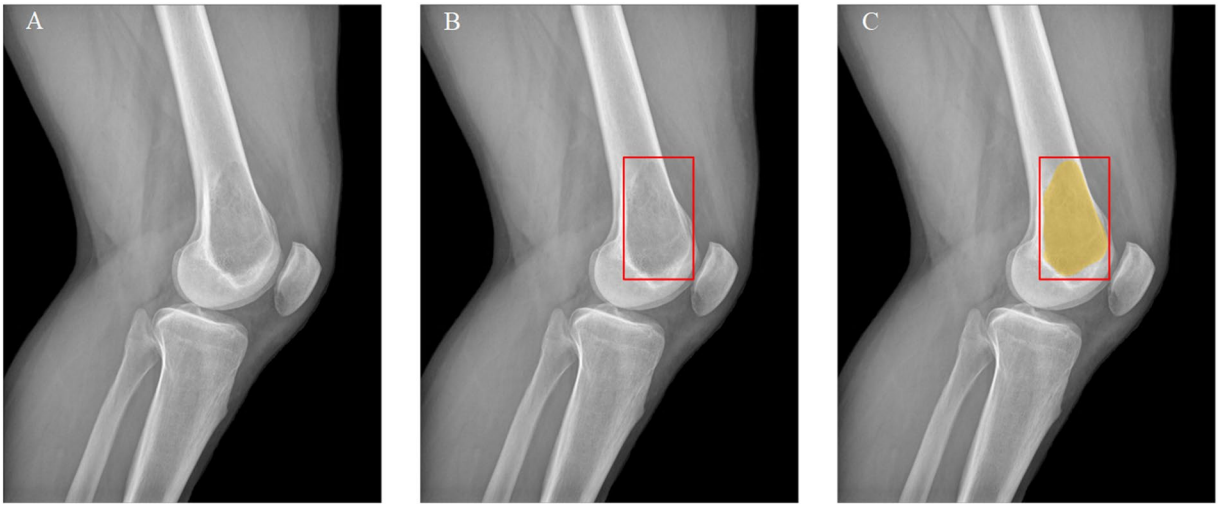

Fig. 6 Labeled sample image. (**A**) Display the original scan, clinically tags with age 32, gender M, and center set to 2; global tags femur, tumor, benign, giant cell tumor, lower limb, and lateral set to 1 (true). Set the remaining markers to 0 (false). (**B**) The boxes mark the local region of the tumor instance for localization tasks. (**C**) The yellow borders mask the tumor regions for segmentation tasks.

No.	column name	Example	No.	column name	Example	No.	column name	Example
1	image_id	IMG0000265.jpeg	14	ankle-joint	0	27	osteofibroma	0
2	center	1	15	knee-joint	0	28	synovial osteochondroma	0
3	age	65	16	hip-joint	0	29	other bt	0
4	gender	F	17	wrist-joint	0	30	osteosarcoma	0
5	hand	0	18	elbow-joint	0	31	other mt	0
6	ulna	0	19	shoulder-joint	0	32	upper limb	1
7	radius	1	20	tumor	1	33	lower limb	0
8	humerus	0	21	benign	1	34	pelvis	0
9	foot	0	22	malignant	0	35	frontal	1
10	tibia	0	23	osteochondroma	0	36	lateral	0
11	fibula	0	24	multiple osteochondromas	0	37	oblique	0
12	femur	0	25	simple bone cyst	0			
13	hip bone	0	26	giant cell tumor	1			

Table 3. Example of a row from the summary file describing the dataset (for better readability, shown as columns).

Data Records

The BTXRD dataset is openly accessible for public use and available on figshare.com (https://doi.org/10.6084/m9.figshare.27865398)[26]. The total size of BTXRD dataset is 801 MB, which can be downloaded without any registration. The file downloaded is in zip format, which includes subfolders "images" and "Annotations," and a "dataset.csv" file. The "images" folder contains all X-ray images, with each image name starting with "IMG" followed by a unique zero-padded six-digit value, and ending with ".jpeg" to indicate the data type. The "Annotations" folder contains ".json" format files with annotation information for segmentation and bounding box placement for each bone tumor image. The "dataset.csv" file contains a summary of the case data for all 3,746 images. Table 3 lists an example row from the summary file.

In creating the BTXRD dataset, researchers carefully selected valuable data from a large volume of mixed and potentially confounding sources, particularly from Centers 2 and 3. The raw data underwent rigorous pre-processing, cleaning and selection to exclude incomplete, low-quality, or redundant images, ensuring that only high-quality data were retained. Clinical and demographic metadata were standardized into a common format to ensure consistency across different sources, facilitating downstream analysis. Additionally, each bone tumor image was manually annotated by expert radiologists to generate segmentation masks and bounding boxes, using a multi-step review process to minimize biases and improve annotation accuracy. These comprehensive efforts have significantly enhanced the value and usability of the BTXRD dataset, providing a valuable resource for developing and validating deep learning models for bone tumor diagnosis.

Task	Model	Type	Class	Precision	Recall	mAP@0.5	Accuracy
Localization	YOLO8s	Box	All	0.768	0.646	0.707	
			B-tumor*	0.689	0.652	0.672	
			M-tumor#	0.847	0.641	0.743	
Segmentation	YOLO8s-seg	Box	All	0.771	0.636	0.687	
			B-tumor	0.716	0.611	0.648	
			M-tumor	0.825	0.662	0.726	
		Mask	All	0.773	0.638	0.691	
			B-tumor	0.722	0.616	0.654	
			M-tumor	0.824	0.661	0.728	
classification	YOLOv8s-cls	Classify	Normal	0.913	0.898		0.904
			B-tumor	0.881	0.875		0.899
			M-tumor	0.734	0.839		0.965

Table 4. Performance results for baseline object detection, segmentation and classification tests on the BTXRD dataset (validation set). *B-Tumor refers to benign tumor, #M-Tumor refers to malignant tumor.

Technical Validation

To examine the suitability of the BTXRD dataset for training deep learning algorithms, we further conducted experiments using YOLOv8[27], a well-established deep learning network commonly used in medical image detection. The images from the BTXRD dataset were randomly divided into training and validation sets at an 8:2 ratio. Annotation information for bone tumor image segmentation and bounding box placement was converted from '.json' to '.txt' format suitable for use with YOLOv8. We utilized YOLOv8s for localization, YOLOv8s-seg for segmentation, and YOLOv8s-cls for benign-malignant classification of primary bone tumors on the autodl cloud platform (www.autodl.com, Zhongke Shituo (Nanjing) Technology Co., Ltd.). The algorithms are implemented using Python 3.8.10, PyTorch 2.0.0 + cu118, and the training process is conducted on an NVIDIA GeForce RTX 4090 with 24GB VRAM, and a 16 vCPU Intel(R) Xeon(R) Gold 6430 processor. The models were trained using standard hyperparameters and official pre-trained weights. The image input size was set to 600 pixels, and the models were run for 300 training epochs. Table 4 lists the relative performance for different tasks. The experimental results demonstrate that the BTXRD dataset is well-suited for application in deep learning algorithms.

Usage Notes

The BTXRD dataset is widely applicable and can be used for various downstream tasks, including validating existing models or developing new ones. Each image in the BTXRD dataset contains information on age, gender, and bone lesion location covering the most common subtypes of primary bone tumors, making it a valuable resource for developing computer-assisted subtype-specific or cross-subtype diagnostic models for primary bone tumors. The significance of this dataset is three-fold: First, it included the well-known clinical importance of age, gender, and the location of bone lesions in the diagnosis of bone tumors. Such clinical information can help clinicians with accurate and comprehensive diagnoses and is crucial for the development of future computer-assisted diagnostic models. Second, most existing models can only be used to perform benign-malignant classification tasks, which is insufficient for clinical applications. Classification of bone tumor subtypes is more clinically relevant. Thus, future development of computer-assisted diagnostic models should focus on the models that can comprehensively classify and diagnose bone tumors. Lastly, the comprehensive annotations in the BTXRD dataset are extremely beneficial for developing future reference and new deep learning models.

During the construction of the BTXRD dataset, we have devoted substantial manpower and methodical effort to identify and annotate bone tumors. However, the quality of the dataset can be further improved from the following perspectives. First, due to the lack of pathological information, some images were diagnosed empirically by two radiology experts, which could potentially result in misdiagnosis. Second, the morphology of some bone tumors on images is very distorted, especially multiple osteochondromas, which may reduce the accuracy of segment annotation. Nevertheless, we consider these limitations acceptable, as improving the quality of the dataset is an ongoing effort, and we will keep reviewing and refining it. Moving forward, we plan to expand multi-center collaboration partnerships to substantially increase the scale of the dataset and engage more experts to review the data, thereby reducing potential diagnostic biases and data errors. Additionally, we also aim to broaden our dataset to include other types of data modalities, including the CT, MRI, and pathological data, and in doing so, we hope to establish and make available a comprehensive multimodal resource to support interdisciplinary, multidimensional research.

Code availability

The code used for technical validation is accessible at: https://github.com/SHUNHANYAO/BTXRD. The annotation software used to generate the dataset, LabelMe, is open source (https://github.com/labelmeai/labelme).

Received: 17 June 2024; Accepted: 17 December 2024;
Published online: 16 January 2025

References

1. Bera, K., Braman, N., Gupta, A., Velcheti, V. & Madabhushi, A. Predicting cancer outcomes with radiomics and artificial intelligence in radiology. *Nat Rev Clin Oncol.* **19**, 132–146 (2022).
2. Chen, P. T. *et al*. Pancreatic Cancer Detection on CT Scans with Deep Learning: A Nationwide Population-based Study. *Radiology.* **306**, 172–182 (2023).
3. Ying, H. *et al*. A multicenter clinical AI system study for detection and diagnosis of focal liver lesions. *Nat Commun.* **15**, 1131 (2024).
4. Meng, Y., Yang, Y., Hu, M., Zhang, Z. & Zhou, X. Artificial intelligence-based radiomics in bone tumors: Technical advances and clinical application. *Seminars in cancer biology.* **95**, 75–87 (2023).
5. Lacroix, M. *et al*. Artificial intelligence in musculoskeletal oncology imaging: A critical review of current applications. *Diagn Interv Imaging.* **104**, 18–23 (2023).
6. Gianferante, D. M., Mirabello, L. & Savage, S. A. Germline and somatic genetics of osteosarcoma - connecting aetiology, biology and therapy. *Nat Rev Endocrinol.* **13**, 480–491 (2017).
7. Maier-Hein *et al*. Surgical data science - from concepts toward clinical translation. *Med Image Anal.* **76**, 102306 (2022).
8. Abedeen, I. *et al*. FracAtlas: A Dataset for Fracture Classification, Localization and Segmentation of Musculoskeletal Radiographs. *Scientific data.* **10**, 521 (2023).
9. NLM, N. Medpix, u.s. national library of medicine. national institutes of health. MedPix. https://medpix.nlm.nih.gov/home.
10. Radiopaedia. http://radiopaedia.org.
11. Yadav, D. & Rathor, S. Bone fracture detection and classification using deep learning approach. In 2020 International Conference on Power Electronics & IoT Applications in Renewable Energy and its Control (PARC), 282–285 (IEEE, 2020).
12. He, Y. *et al*. Deep learning-based classification of primary bone tumors on radiographs: A preliminary study. *EBioMedicine.* **62**, 103121 (2020).
13. Do, N. T., Jung, S. T., Yang, H. J. & Kim, S. H. Multi-Level Seg-Unet Model with Global and Patch-Based X-ray Images for Knee Bone Tumor Detection. *Diagnostics (Basel, Switzerland).* **11**, 691 (2021).
14. von Schacky, C. E. *et al*. Multitask Deep Learning for Segmentation and Classification of Primary Bone Tumors on Radiographs. *Radiology.* **301**, 398–406 (2021).
15. Liu, R. *et al*. A deep learning-machine learning fusion approach for the classification of benign, malignant, and intermediate bone tumors. *Eur Radiol.* **32**, 1371–1383 (2022).
16. Shao, J. *et al*. Deep learning for differentiation of osteolytic osteosarcoma and giant cell tumor around the knee joint on radiographs: a multicenter study. *Insights Imaging.* **15**, 35 (2024).
17. Hinterwimmer, F. *et al*. Recommender-based bone tumour classification with radiographs-a link to the past. *Eur Radiol*. (2024).
18. Yu, D., Hu, J., Feng, Z., Song, M. & Zhu, H. Deep learning based diagnosis for cysts and tumors of jaw with massive healthy samples. *Scientific reports.* **12**, 1855 (2022).
19. Park, C. W. *et al*. Artificial intelligence-based classification of bone tumors in the proximal femur on plain radiographs: System development and validation. *PLoS One.* **17**, e0264140 (2022).
20. Consalvo, S. *et al*. Two-Phase Deep Learning Algorithm for Detection and Differentiation of Ewing Sarcoma and Acute Osteomyelitis in Paediatric Radiographs. *Anticancer research.* **42**, 4371–4380 (2022).
21. Xu, Z. *et al*. Bone tumor necrosis rate detection in few-shot X-rays based on deep learning. *Comput Med Imaging Graph.* **102**, 102141 (2022).
22. Li, J. *et al*. Primary bone tumor detection and classification in full-field bone radiographs via YOLO deep learning model. *Eur Radiol.* **33**, 4237–4248 (2023).
23. Anttila, T. T. *et al*. Enchondroma Detection from Hand Radiographs with an Interactive Deep Learning Segmentation Tool-A Feasibility Study. *Journal of clinical medicine.* **12**, 7129 (2023).
24. Breden, S. *et al*. Deep Learning-Based Detection of Bone Tumors around the Knee in X-rays of Children. *J Clin Med.* **12**, 5960 (2023).
25. Torralba, A., Russell, B. C. & Yuen, J. LabelMe: Online Image Annotation and Applications. *Proceedings of the IEEE.* **98**, 1467–1484 (2010).
26. S. Yao *et al*. A Radiograph Dataset for Training Deep Learning Models for the Classification, Localization, and Segmentation of Primary Bone Tumors. figshare https://doi.org/10.6084/m9.figshare.27865398 (2024).
27. Jocher, G.; Chaurasia, A.; Qiu, J. Ultralytics yolov8. https://github.com/ultralytics/ultralytics (2023).

Acknowledgements

This work was supported by the China Scholarship Council (202306660024) and the Specific Research Project of Guangxi for Research Bases and Talents (GuiKe AD22035057).

Author contributions

S.Y. generated the dataset and collected images from Center 2 and Center 3. H.T. and D.L. collected images from Center 1. S.Y. cleaned the data. S.Y. and Y.H. performed the distribution analysis of the dataset, and conducted the technical analysis of the dataset. S.Y. annotated the images using the labels provided by the radiologists. Q.C. and J.S. supervised the project. S.Y. drafted the paper. X.W., Y.Z., I.C.P., Z.W., C.L.C., G.I.W., S.L., Y.G., Q.C. and J.S. participated actively in manuscript preparation.

Competing interests

The authors declare no competing interests.

Additional information

Correspondence and requests for materials should be addressed to Q.C. or J.S.

Reprints and permissions information is available at www.nature.com/reprints.

Publisher's note Springer Nature remains neutral with regard to jurisdictional claims in published maps and institutional affiliations.

Open Access This article is licensed under a Creative Commons Attribution-NonCommercial-NoDerivatives 4.0 International License, which permits any non-commercial use, sharing, distribution and reproduction in any medium or format, as long as you give appropriate credit to the original author(s) and the source, provide a link to the Creative Commons licence, and indicate if you modified the licensed material. You do not have permission under this licence to share adapted material derived from this article or parts of it. The images or other third party material in this article are included in the article's Creative Commons licence, unless indicated otherwise in a credit line to the material. If material is not included in the article's Creative Commons licence and your intended use is not permitted by statutory regulation or exceeds the permitted use, you will need to obtain permission directly from the copyright holder. To view a copy of this licence, visit http://creativecommons.org/licenses/by-nc-nd/4.0/.

© The Author(s) 2025