EXPERT RADIOLOGY PrecisionPlus v3™ Report
Patent Pending

MRI OF THE CERVICAL SPINE

CLINICAL INDICATION: Neck pain following motor vehicle collision on 03/09/2026.

TECHNIQUE: T1 and T2 weighted images were obtained.

COMPARISON: No prior studies are available for comparison.

FINDINGS:

The posterior fossa structures are normal. There is reversal of the normal lordotic curvature of the cervical spine. In the correct clinical setting, this may reflect injury. Clinical correlation is recommended. No prevertebral or paravertebral masses or fluid collections are identified. Segmental analysis of the cervical spine is as follows:

At C2-3, there is a central disc herniation superimposed on a disc bulge, the combination of which measures 1.5 mm. The ventral thecal sac is indented, and the posterior longitudinal ligament is elevated. There are anterior osteophytes and no posterior osteophytes are seen. There is mild spinal stenosis to 1.0 cm. There is severe left and mild right neural foraminal narrowing. There is facet arthropathy.

At C3-4, there is a central disc herniation superimposed on a disc bulge, the combination of which measures 2 mm. The ventral thecal sac is indented, and the posterior longitudinal ligament is elevated. There are anterior and there are posterior osteophytes, however the disc material extends posterior to the posterior osteophytes. There is moderate spinal stenosis to 0.7 cm. There is mild spinal cord deformity. There is mild bilateral neural foraminal narrowing. There is significant facet arthropathy.

At C4-5, there is a left paracentral disc herniation superimposed on a disc bulge, the combination of which measures 3.5 mm. The ventral thecal sac is indented, and the posterior longitudinal ligament is elevated. This is a contained extrusion-type herniation and has a craniocaudal measurement of 0.9 cm. It extends superiorly beyond the inferior endplate of C4 and inferiorly beyond the superior endplate of C5. There are anterior and there are posterior osteophytes, however the disc material extends posterior to the posterior osteophytes. There is severe spinal stenosis to 0.6 cm with moderate spinal cord deformity. There is severe bilateral neural foraminal narrowing. There is significant facet arthropathy. Modic type 1, acute-type, endplate signal changes and Modic type 2, subacute-type, endplate signal changes are seen.

At C5-6, there is a right paracentral disc herniation superimposed on a disc bulge, the combination of which measures 4 mm. The ventral thecal sac is indented, and the posterior longitudinal ligament is elevated. This is a contained extrusion-type herniation and has a craniocaudal measurement of 0.9 cm. It extends superiorly beyond the inferior endplate of C5 and inferiorly beyond the superior endplate of C6. There are anterior and there are posterior osteophytes, however the disc material extends posterior to the posterior osteophytes. There is severe spinal stenosis to 0.5 cm. **There is deformity of the spinal cord, and on some images there is no CSF seen anterior nor posterior to at least a portion of the cord consistent with cord compression. Clinical correlation is recommended and consider spinal surgical consultation.** There is severe bilateral neural foraminal narrowing. There is significant facet arthropathy. Modic type 1, acute-type, endplate signal changes are seen.

At C6-7, there is a central disc herniation superimposed on a disc bulge, the combination of which measures 3 mm. The ventral thecal sac is indented, and the posterior longitudinal ligament is elevated. This is a contained extrusion-type herniation and has a craniocaudal measurement of 1.0 cm. It extends superiorly beyond the inferior endplate of C6 and inferiorly beyond the superior endplate of C7. There are anterior and there are posterior osteophytes, however the disc material extends posterior to the posterior osteophytes. There is severe spinal stenosis to 0.6 cm with moderate spinal cord deformity. There is severe left and moderate right neural foraminal narrowing. There is facet arthropathy.

At C7-T1, there is a right paracentral disc herniation superimposed on a disc bulge, the combination of which measures 2 mm. The ventral thecal sac is indented, and the posterior longitudinal ligament is elevated. There are anterior and there are posterior osteophytes, however the disc material extends posterior to the posterior osteophytes. There is moderate spinal stenosis to 0.7 cm. There is mild spinal cord deformity. There is moderate right and mild left neural foraminal narrowing. There is facet arthropathy.

At T1-2, there is disc bulge versus herniation measuring 1.5 mm. There are anterior osteophytes and no posterior osteophytes are seen. There is moderate spinal stenosis to 0.8 cm. There is mild spinal cord deformity. There is severe right and mild left neural foraminal narrowing. This is incompletely evaluated due to lack of axial images.

There is multilevel decreased intervertebral disc signal.

There is decreased intervertebral disc space height at C4-5 through C6-7.

There is spinal asymmetry with apex right in the cervical spine.

There are mucosal retention cysts seen in the bilateral maxillary sinuses.

Note is made of medial deviation of the bilateral carotid arteries, a congenital anomaly.

There is increased signal between the clivus and odontoid process of C2 which is nonspecific. This finding can be associated with whiplash-associated disorder in the appropriate clinical setting. Clinical correlation with the patient’s treating physicians is recommended to determine if there is acute ligamentous injury to the alar and/or transverse ligament.

IMPRESSION:

1. There is reversal of the normal lordotic curvature of the cervical spine. In the correct clinical setting, this may reflect injury. Clinical correlation with the patient's treating physician is recommended.
2. At C2-3, there is a central disc herniation superimposed on a disc bulge, the combination of which measures 1.5 mm. The ventral thecal sac is indented, and the posterior longitudinal ligament is elevated. There is mild spinal stenosis to 1.0 cm. There is severe left and mild right neural foraminal narrowing.
3. At C3-4, there is a central disc herniation superimposed on a disc bulge, the combination of which measures 2 mm. The ventral thecal sac is indented, and the posterior longitudinal ligament is elevated. There are anterior and there are posterior osteophytes, however the disc material extends posterior to the posterior osteophytes. There is moderate spinal stenosis to 0.7 cm. There is mild spinal cord deformity. There is mild bilateral neural foraminal narrowing.
4. At C4-5, there is a left paracentral disc herniation superimposed on a disc bulge, the combination of which measures 3.5 mm. The ventral thecal sac is indented, and the posterior longitudinal ligament is elevated. This is a contained extrusion-type herniation and has a

craniocaudal measurement of 0.9 cm. It extends superiorly beyond the inferior endplate of C4 and inferiorly beyond the superior endplate of C5. There are anterior and there are posterior osteophytes, however the disc material extends posterior to the posterior osteophytes. There is severe spinal stenosis to 0.6 cm with moderate spinal cord deformity. There is severe bilateral neural foraminal narrowing. Modic type 1, acute-type, endplate signal changes and Modic type 2, subacute-type, endplate signal changes are seen. *See **Figure 1** Sagittal T2 image #7 shows disc herniation.

5. At C5-6, there is a right paracentral disc herniation superimposed on a disc bulge, the combination of which measures 4 mm. The ventral thecal sac is indented, and the posterior longitudinal ligament is elevated. This is a contained extrusion-type herniation and has a craniocaudal measurement of 0.9 cm. It extends superiorly beyond the inferior endplate of C5 and inferiorly beyond the superior endplate of C6. There are anterior and there are posterior osteophytes, however the disc material extends posterior to the posterior osteophytes. There is severe spinal stenosis to 0.5 cm. **There is deformity of the spinal cord, and on some images there is no CSF seen anterior nor posterior to at least a portion of the cord consistent with cord compression. Clinical correlation is recommended and consider spinal surgical consultation.** There is severe bilateral neural foraminal narrowing. Modic type 1, acute-type, endplate signal changes are seen.
6. At C6-7, there is a central disc herniation superimposed on a disc bulge, the combination of which measures 3 mm. The ventral thecal sac is indented, and the posterior longitudinal ligament is elevated. This is a contained extrusion-type herniation and has a craniocaudal measurement of 1.0 cm. It extends superiorly beyond the inferior endplate of C6 and inferiorly beyond the superior endplate of C7. There are anterior and there are posterior osteophytes, however the disc material extends posterior to the posterior osteophytes. There is severe spinal stenosis to 0.6 cm with moderate spinal cord deformity. There is severe left and moderate right neural foraminal narrowing.
7. At C7-T1, there is a right paracentral disc herniation superimposed on a disc bulge, the combination of which measures 2 mm. The ventral thecal sac is indented, and the posterior longitudinal ligament is elevated. There are anterior and there are posterior osteophytes, however the disc material extends posterior to the posterior osteophytes. There is moderate spinal stenosis to 0.7 cm. There is mild spinal cord deformity. There is moderate right and mild left neural foraminal narrowing.
8. At T1-2, there is disc bulge versus herniation measuring 1.5 mm. There is moderate spinal stenosis to 0.8 cm. There is mild spinal cord deformity. There is severe right and mild left neural foraminal narrowing. This is incompletely evaluated due to lack of axial images.
9. There is spinal asymmetry with apex right in the cervical spine.
10. There is increased signal between the clivus and odontoid process of C2 which is nonspecific. This finding can be associated with whiplash-associated disorder in the appropriate clinical setting. Clinical correlation with the patient's treating physicians is recommended to determine if there is ligamentous injury to the alar and/or transverse ligament. *See **Figure 2** Sagittal STIR image #7. Arrow shows the increased signal between the clivus and odontoid process of C2.
11. Given the patient's indication of pain following trauma, above findings are consistent with findings related to the patient's trauma, and clinical correlation with the patient's treating physicians including symptomatology following injury is recommended. This diagnostic opinion should be used to inform the course and scope of treatment as clinically appropriate in accordance with the findings above.

Expert Radiology has initiated direct communication process with the referring physician's office via telephone.

It should be noted that facetogenic pain is a clinical diagnosis due to the irritation of the facet joints, and MRI is insensitive for symptomology such as facet-related pain.

The definitions in this report, including definitions of disc bulge, disc herniation, protrusion, and extrusion, are from the following peer reviewed journal: Lumbar Disc Nomenclature V2.0, Recommendations of the Combined Task Forces of the North American Spine Society, the American Society of Spine Radiology and the American Society of Neuroradiology, The Spine Journal 14 (2014) 2525 2545. Disc herniations are protrusion type disc herniations unless specifically described as extrusions. A normal MRI should not supersede abnormalities detected with physical exam.

FIGURE 1:

Image shows a left paracentral disc herniation at C4-5 superimposed on a disc bulge, measuring 3.5 mm, with severe spinal stenosis to 0.6 cm and moderate spinal cord deformity. *(Automatic description of image based on radiologist's report)*

FIGURE 2:

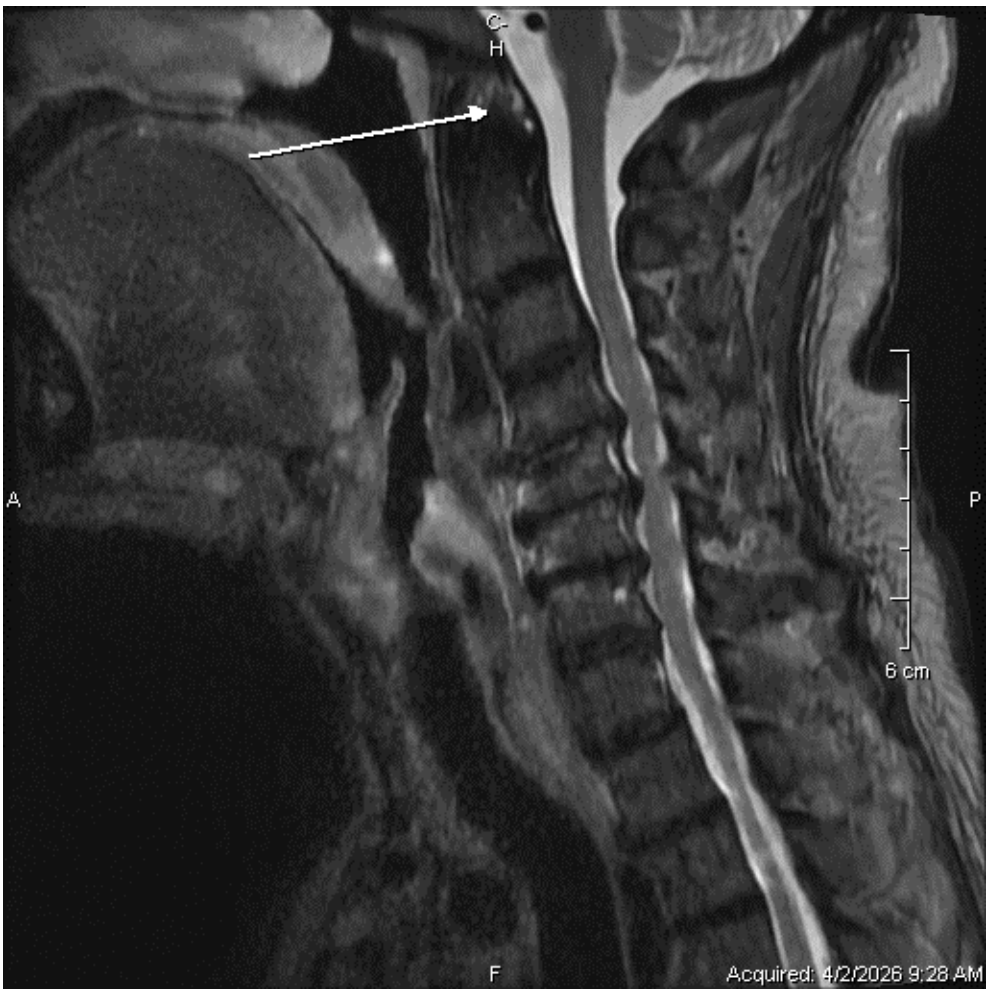

Image shows increased signal between the clivus and odontoid process of C2, associated with whiplash-associated disorder. *(Automatic description of image based on radiologist's report)*

COLORIZATION OF FIGURE 1:

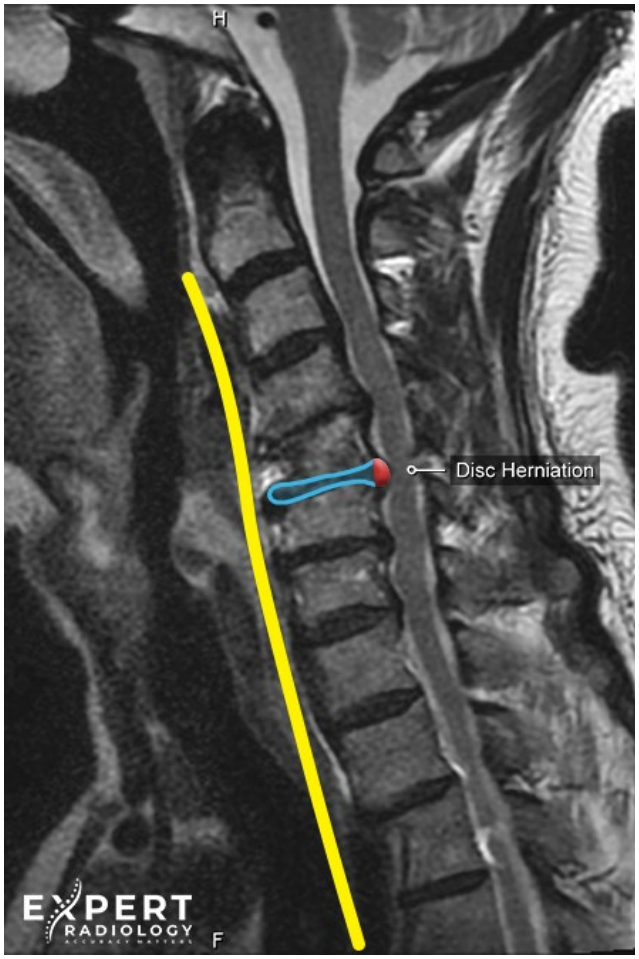

JEAN-FRANCOIS, JACQUES

NORMAL CERVICAL SPINE:

HEALTHY PATIENT

©2026 Expert Radiology™. All Rights Reserved.
The colorized medical images, annotations, and graphical enhancements are the exclusive intellectual property of Expert Radiology™ and are confidential, proprietary, and protected by applicable intellectual property laws. Any unauthorized use, reproduction, or modification of these works is strictly prohibited without prior written consent.
For licensing inquiries or additional information, please contact info@expertradiology.com.

Note: The image on the LEFT is a colorized image of the patient's abnormality for illustrative purposes only, and this colorized image should not be used for medical decision-making

Thank you for the consultation. This MRI report was personally interpreted and finalized by the signing radiologist. To ensure the highest-quality MRI and CT reports with colorized key images and illustrations, please request **Expert Radiology v3™** on future order scripts.

Sincerely,

Lee Hewett, MD
Clinical Neuroradiologist, Expert Radiology™
Board Certified, Diagnostic Radiology, American Board of Radiology
Fellowship Trained, Neuroradiology

Scan to View this Radiologist's CV

Electronically Signed by HEWETT, LEE MD at 04/06/2026 02:16:51 PM UTC-05:00
Transcribed/ S.W

V3

Customized Spine Illustration of patient:
Sagittal View of Cervical Spine

(Based upon Findings in the Report)

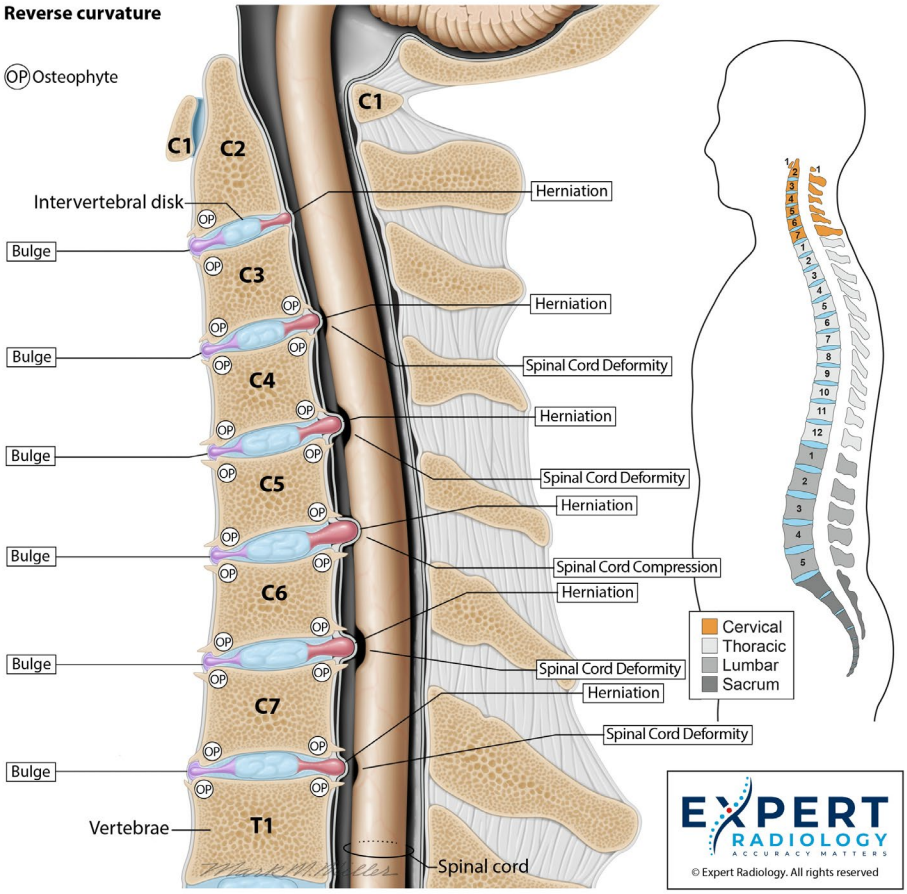

This illustration depicts a Sagittal view (side view) of the spine. It attempts to highlight some of the area(s) of interest as described in the radiology report. This illustration does not necessarily show all the pathology present. Please refer to the original radiologists' report. This illustration attempts to correspond to the level(s) of the pathology specified, providing a visual representation to improve the understanding of the reported findings for the patient. Protrusions and Extrusions are both subtypes of Herniation. The image selection was generated by a computer and has not been reviewed by the radiologist for accuracy, correctness, or completeness. The illustration should NOT be used in medical decision making or diagnostic purposes. The illustration is provided solely as a convenience for the patient and should not be relied upon as a medical diagnosis. If you have questions relating to this illustration please contact your personal physician. The illustration is not intended to be a medical device and is not subject to FDA oversight.

Customized Spine Illustration of patient:
Axial View of Cervical Spine Level C5-6
(Based upon Findings in the Report)

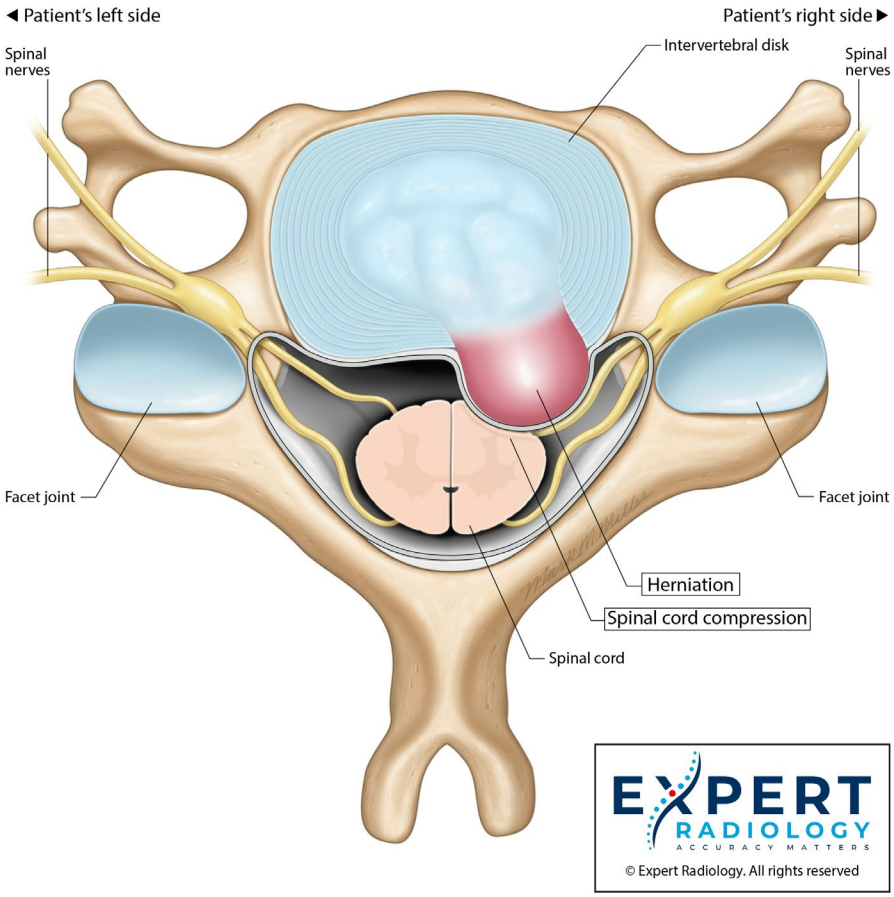

This illustration depicts an Axial view (top down view) of the spine. It attempts to highlight some of the area(s) of interest as described in the radiology report. This illustration does not necessarily show all the pathology present. Please refer to the original radiologists' report. This illustration attempts to correspond to at least one of the position(s) of the pathology specified, providing a visual representation to improve the understanding of the reported findings for the patient. Protrusions and Extrusions are both subtypes of Herniation. The image selection was generated by a computer and has not been reviewed by the radiologist for accuracy, correctness, or completeness. The illustration should NOT be used in medical decision making or diagnostic purposes. The illustration is provided solely as a convenience for the patient and should not be relied upon as a medical diagnosis. If you have questions relating to this illustration please contact your personal physician. The illustration is not intended to be a medical device and is not subject to FDA oversight.

Simplified Patient Explanation of Radiologist's Report*

Not a substitute for the Expert Radiology radiologist's report

Simplified Patient Explanation

MRI of the Neck

Reason for Exam: Neck pain after a car accident on 03/09/2026.

Technique: T1 and T2 images were taken.

Comparison: No previous studies to compare.

Findings:

The back part of the brain looks normal. The curve in the neck is reversed, which might mean injury. No unusual masses or fluid collections were found.

Details by Neck Level:

1. **C2-3:** Central disc herniation and disc bulge together measure 1.5 mm. The front part of the spinal sac is indented, and a ligament is raised. Mild narrowing of the spine to 1.0 cm. Severe narrowing on the left and mild on the right where nerves exit.
2. **C3-4:** Central disc herniation and disc bulge together measure 2 mm. The front part of the spinal sac is indented, and a ligament is raised. Moderate narrowing of the spine to 0.7 cm. Mild deformity of the spinal cord. Mild narrowing on both sides where nerves exit.
3. **C4-5:** Left disc herniation and disc bulge together measure 3.5 mm. The front part of the spinal sac is indented, and a ligament is raised. Severe narrowing of the spine to 0.6 cm with moderate deformity of the spinal cord. Severe narrowing on both sides where nerves exit.
4. **C5-6:** Right disc herniation and disc bulge together measure 4 mm. The front part of the spinal sac is indented, and a ligament is raised. Severe narrowing of the spine to 0.5 cm. Deformity of the spinal cord with no fluid seen around it, suggesting compression. Severe narrowing on both sides where nerves exit.
5. **C6-7:** Central disc herniation and disc bulge together measure 3 mm. The front part of the spinal sac is indented, and a ligament is raised. Severe narrowing of the spine to 0.6 cm with moderate deformity of the spinal cord. Severe narrowing on the left and moderate on the right where nerves exit.
6. **C7-T1:** Right disc herniation and disc bulge together measure 2 mm. The front part of the spinal sac is indented, and a ligament is raised. Moderate narrowing of the spine to 0.7 cm. Mild deformity of the spinal cord. Moderate narrowing on the right and mild on the left where nerves exit.
7. **T1-2:** Disc bulge or herniation measuring 1.5 mm. Moderate narrowing of the spine to 0.8 cm. Mild deformity of the spinal cord. Severe narrowing on the right and mild on the left where nerves exit.

There is less space between the discs from C4-5 to C6-7. The spine is slightly curved to the right. There are small cysts in the sinuses. The carotid arteries are slightly off-center, which is normal for some people. There is a signal change between two bones in the neck that might be related to whiplash. This should be checked by a doctor.

Impression:

The curve in the neck is reversed, which might mean injury. This should be checked by a doctor.

1. **C2-3:** Central disc herniation and disc bulge together measure 1.5 mm. Mild narrowing of the spine to 1.0 cm. Severe narrowing on the left and mild on the right where nerves exit.
2. **C3-4:** Central disc herniation and disc bulge together measure 2 mm. Moderate narrowing of the spine to 0.7 cm. Mild deformity of the spinal cord. Mild narrowing on both sides where nerves exit.
3. **C4-5:** Left disc herniation and disc bulge together measure 3.5 mm. Severe narrowing of the spine to 0.6 cm with moderate deformity of the spinal cord. Severe narrowing on both sides where nerves exit.
4. **C5-6:** Right disc herniation and disc bulge together measure 4 mm. Severe narrowing of the spine to 0.5 cm. Deformity of the spinal cord with no fluid seen around it, suggesting compression. Severe narrowing on both sides where nerves exit.
5. **C6-7:** Central disc herniation and disc bulge together measure 3 mm. Severe narrowing of the spine to 0.6 cm with moderate deformity of the spinal cord. Severe narrowing on the left and moderate on the right where nerves exit.
6. **C7-T1:** Right disc herniation and disc bulge together measure 2 mm. Moderate narrowing of the spine to 0.7 cm. Mild deformity of the spinal cord. Moderate narrowing on the right and mild on the left where nerves exit.
7. **T1-2:** Disc bulge or herniation measuring 1.5 mm. Moderate narrowing of the spine to 0.8 cm. Mild deformity of the spinal cord. Severe narrowing on the right and mild on the left where nerves exit.

Given the patient's pain after the accident, these findings should be checked by a doctor to decide the best treatment.

Simplified Patient Explanation

END OF SIMPLIFIED PATIENT EXPLANATION

**The above is a Simplified Patient Explanation / Artificial Intelligence ("AI") summary generated for the patient (a layperson) of the Radiology Report provided above ("Simplified Patient Explanation"). This Simplified Patient Explanation was generated by a computer and has not been reviewed by the radiologist for accuracy, correctness, or completeness. The Simplified Patient Explanation is not intended for decision making or diagnostic purposes. The Simplified Patient Explanation is provided solely as a convenience for the patient and should not be relied upon as a medical diagnosis. If you have questions relating to this AI Summary please contact your personal physician. The Simplified Patient Explanation by Expert Radiology™ is not intended to be a medical device and is not subject to FDA oversight.*

---

i. Quantitative Evaluation of Large Language Models to Streamline Radiology Report Impressions: A Multimodal Retrospective Analysis. Radiology. https://doi.org/10.1148/radiol.231593

ii. Rahsepar, A. A. (2024). Large Language Models for Enhancing Radiology Report Impressions: Improve Readability While Decreasing Burnout. Radiology. https://doi.org/10.1148/radiol.240498

iii. Park, J., Oh, K., Han, K. et al. (2024). Patient-centered radiology reports with generative artificial intelligence: adding value to radiology reporting. https://doi.org/10.1038/s41598-024-63824-z

Physicians and healthcare providers only: For direct consultation with a radiologist at Expert Radiology™, please call our dedicated hotline at 415-900-2000.