Patient Name:	DOE, JOHN	Exam Date:	09/27/2025 10:07 PM
Patient ID:	A000000	Exam Description:	MRI OF THE BRAIN
Date of Birth:	01/01/1990	Accession:	1234567
Gender:	M		

EXPERT RADIOLOGY

PrecisionPlus v3™ Report

Patent Pending

MRI OF THE BRAIN WITHOUT CONTRAST:

CLINICAL INDICATION: Headache, loss of balance, forgetfulness, slip and fall on 09/29/2025.

TECHNIQUE: T1, T2, FLAIR, diffusion, and GRE images were obtained without contrast.

FINDINGS:

SUPRATENTORIAL STRUCTURES: **There is a large area of encephalomalacia within the lateral left frontal lobe with small areas of hemosiderin deposition within the encephalomalacia.**

There are scattered white matter subcortical and periventricular hyperintensities on T2 and/or FLAIR weighted imaging which are nonspecific. Given the patient's indication, the differential diagnosis includes small vessel ischemic disease, as well as vasculitis or demyelinating disease. This could be a combination, and clinical correlation with the patient's treating physicians is recommended. There is no mass or mass effect.

POSTERIOR FOSSA: The brainstem is normal in signal intensity. The cerebellum appears within normal limits. The cerebellar folia and sulci are unremarkable. The internal auditory canals appear within normal limits. There is no evidence for cerebellopontine angle mass.

VENTRICULAR SYSTEM: The ventricles are normal in size and shape. There is no evidence for hydrocephalus and there is no evidence for transependymal flow of CSF.

SKULL BASE AND OSSEOUS STRUCTURES: The orbits, paranasal sinuses and temporal bones are within normal limits. The sella structures appear within normal limits. There is no evidence for abnormal mass or fluid collection associated with these structures.

VASCULAR STRUCTURES: There is normal signal void within the major vessels of the circle of Willis. The superior sagittal sinus appears unremarkable on this examination.

IMPRESSION:

1. **There is a large area of encephalomalacia within the lateral left frontal lobe with small areas of hemosiderin deposition within the encephalomalacia.** *See **Figure 1** Axial FLAIR series 1005, image #7.

2. There are scattered white matter subcortical and periventricular hyperintensities on T2 and FLAIR weighted imaging which are nonspecific. Given the patient's indication, the differential diagnosis includes small vessel ischemic disease, as well as vasculitis or demyelinating disease. This could be a combination, and clinical correlation with the patient's treating physicians is recommended. *See **Figure 2** Axial FLAIR series 1005, image #12 demonstrates subcortical and periventricular hyperintensities.

FIGURE 1:

Patient Name: DOE, JOHN Exam Date: 09/27/2025 10:07 PM

Image shows a large area of encephalomalacia within the lateral left frontal lobe with small areas of hemosiderin deposition. *(Automatic description of image based on radiologist's report)*

FIGURE 2:

Patient Name: DOE, JOHN Exam Date: 09/27/2025 10:07 PM

Image shows scattered white matter subcortical and periventricular hyperintensities on T2 and FLAIR weighted imaging.
(Automatic description of image based on radiologist's report)

Thank you for the consultation. Please request PrecisionPlus v3™ MRI reports on your order script to ensure the highest quality reports.

Sincerely,

Maureen T. Barry M.D.

Maureen T. Barry, MD
Clinical Neuroradiologist, Expert Radiology™
Board Certified, Diagnostic Radiology, American Board of Radiology
Subspecialty Certification in Neuroradiology

Electronically Signed by BARRY, MAUREEN MD DR. at 10/09/2025 10:20:31 AM UTC-05:00 Transcribed/ D.J

Customized Brain Illustration of patient Gary Ward:

(Based upon Findings in the Report)

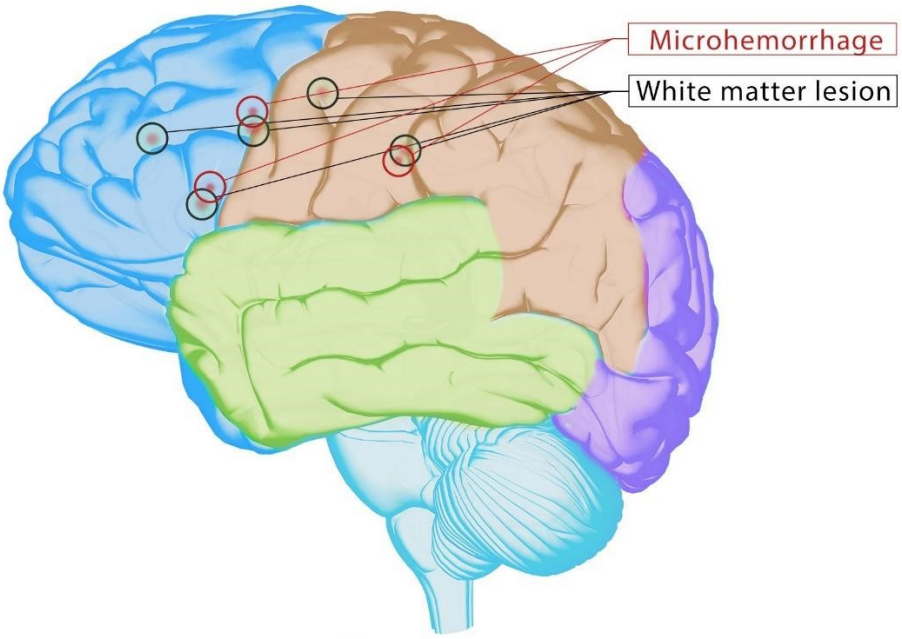

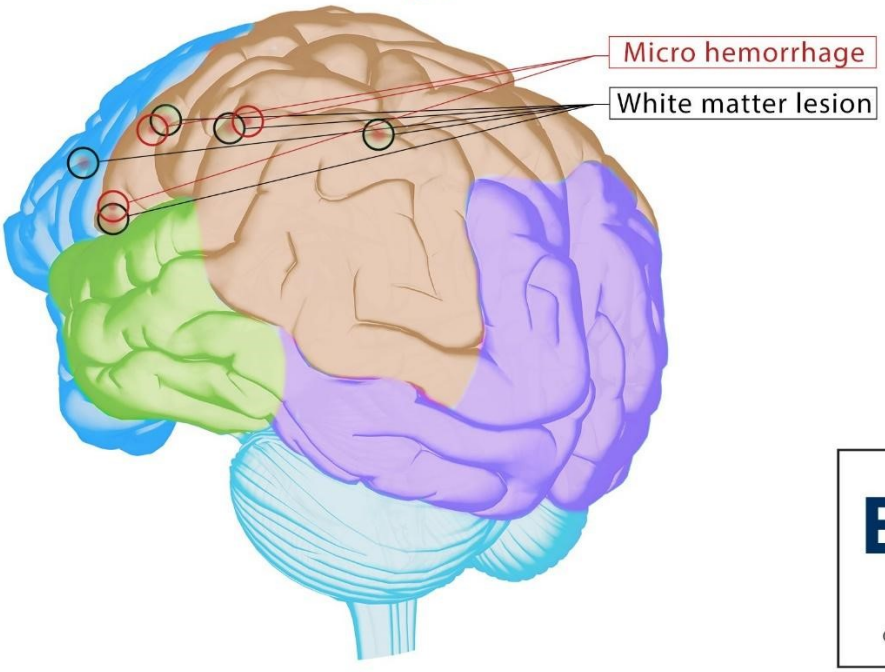

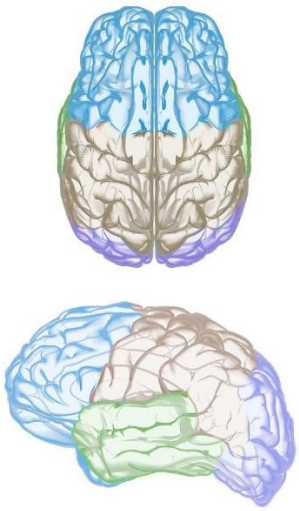

KEY:

- Temporal Lobe
- Occipital Lobe
- Parietal Lobe
- Frontal Lobe
- Micro Hemorrhage
- White Matter Lesion

© Expert Radiology. All rights reserved

This illustration depicts both an oblique view and side view of the brain. It highlights specific areas of interest as described in the radiology report. The lesions do not necessarily exactly correspond to the anatomic location of the abnormalities on the actual patient's MRI of the brain, but are demonstrative for patient education. The illustration provides a visual representation to enhance the patient's understanding of the findings. The image selection was generated by a computer and has not been reviewed by a radiologist for accuracy, correctness, or completeness. This illustration should NOT be used for medical decision-making or diagnostic purposes. It is provided solely as a convenience for the patient and should not be relied upon as a medical diagnosis. If you have any questions regarding this illustration, please contact your physician.. This illustration is not intended to be a medical device and is not subject to FDA oversight.

Simplified Patient Explanation of Radiologist's Report*

Not a substitute for the Expert Radiology radiologist's report

Simplified Patient Explanation

MRI of the Brain Without Contrast Reason for the MRI

The patient has headaches, loss of balance, forgetfulness, and had a slip and fall on 09/29/2025.

Technique

Images were taken using T1, T2, FLAIR, diffusion, and GRE methods without using contrast dye.

Findings Supratentorial Structures

There is a large damaged area in the left frontal lobe of the brain with small spots of old blood. There are also scattered bright spots in the white matter of the brain, which could be due to several reasons like small blood vessel issues, inflammation of blood vessels, or diseases that damage the protective covering of nerve fibers. The exact cause needs to be discussed with the patient's doctors. There is no tumor or pressure on the brain. **Posterior Fossa**

The brainstem and cerebellum look normal. The small folds and grooves in the cerebellum are also normal. The internal auditory canals, which are passages in the skull for nerves related to hearing and balance, are normal. There is no sign of a mass in the area where the cerebellum and brainstem meet.

Ventricular System

The brain's ventricles, which are fluid-filled spaces, are normal in size and shape. There is no sign of excess fluid in the brain.

Skull Base and Bone Structures

The eye sockets, sinuses, and bones around the ears are normal. The area around the pituitary gland is also normal. There are no abnormal masses or fluid collections in these areas. **Vascular Structures**

The major blood vessels in the brain show normal blood flow. The superior sagittal sinus, a large vein in the brain, looks normal.

Impression

There is a large damaged area in the left frontal lobe of the brain with small spots of old blood. There are scattered bright spots in the white matter of the brain, which could be due to several reasons like small blood vessel issues, inflammation of blood vessels, or diseases that damage the protective covering of nerve fibers. The exact cause needs to be discussed with the patient's doctors.

END OF SIMPLIFIED PATIENT EXPLANATION

**The above is a Simplified Patient Explanation / Artificial Intelligence ("AI") summary generated for the patient (a layperson) of the Radiology Report provided above ("Simplified Patient Explanation"). This Simplified Patient Explanation was generated by a computer and has not been reviewed by the radiologist for accuracy, correctness, or completeness. The Simplified Patient Explanation is not intended for decision making or diagnostic purposes. The Simplified Patient Explanation is provided solely as a convenience for the patient and should not be relied upon as a medical diagnosis. If you have questions relating to this AI Summary please contact your personal physician. The Simplified Patient Explanation by Expert Radiology™ is not intended to be a medical device and is not subject to FDA oversight.*

---

i. Quantitative Evaluation of Large Language Models to Streamline Radiology Report Impressions: A Multimodal Retrospective Analysis. Radiology. https://doi.org/10.1148/radiol.231593 ii.

Rahsepar, A. A. (2024). Large Language Models for Enhancing Radiology Report Impressions: Improve Readability While Decreasing Burnout. Radiology. https://doi.org/10.1148/radiol.240498 iii.

Park, J., Oh, K., Han, K. et al. (2024). Patient-centered radiology reports with generative artificial intelligence: adding value to radiology reporting. https://doi.org/10.1038/s41598-024-63824-z

Physicians and healthcare providers only: For direct consultation with a radiologist at Expert Radiology™, please call our dedicated hotline at 415-900-2000