Patient Name:	Exam Date:	
Patient ID:	Exam Description:	MRI KNEE W/O CONTRAST RIGHT
Date of Birth:	Accession:	
Gender:		

EXPERT RADIOLOGY ALL ACCURACY MATTERS — PrecisionPlus v3™ Report
Patent Pending

MRI OF THE RIGHT KNEE

CLINICAL INDICATION: Right knee pain. Pickle ball injury.

TECHNIQUE: Multiplanar, multisequence MR imaging of the right knee performed.

COMPARISON: No prior studies are available for comparison.

FINDINGS:

MEDIAL COMPARTMENT: There is focal Grade III abnormal signal seen at the junction of the body and posterior horn of the medial meniscus. In addition, there is focal blunting along the free edge of the body of the medial meniscus. The MCL is intact. The cartilage overlying the medial compartment is normal.

LATERAL COMPARTMENT: There is a focal Grade II-III chondral defect seen involving the posterolateral tibial plateau. This measures 5 x 5 mm. There is linear high T2 signal seen within the body of the lateral mensicus, but this does not extend to an articular surface. The popliteus muscle and tendon are intact. The fibular collateral ligament is normal.

INTERCONDYLAR NOTCH: The ACL and PCL are intact.

PATELLOFEMORAL COMPARTMENT: The quadriceps and patellar tendons are intact. The patellofemoral cartilage is intact.

ADDITIONAL FINDINGS: There is a moderate joint effusion.

IMPRESSION:

1. Complex tears involving the body and posterior horn of the medial meniscus. There is a free edge component involving the body of the medial meniscus with blunting of the free edge. There is also a horizontal cleavage component involving the posterior horn of the medial meniscus. Suspect that this an unstable tear measuring greater than 1 cm. *See **Figure 1** Coronal PD FS series 7, image #20 and **Figure 2** Sagittal T2 series 5, image #10.
2. Grade II-III chondral defect measuring 5 x 5 mm overlying the posterolateral tibial plateau.
3. Moderate joint effusion.

Patient Name: Exam Date:

FIGURE 1:

Image shows complex tears involving the body and posterior horn of the medial meniscus with a free edge component and blunting of the free edge. *(Automatic description of image based on radiologist's report)*

Patient Name: Exam Date:

FIGURE 2:

Image shows a Grade II-III chondral defect measuring 5 x 5 mm overlying the posterolateral tibial plateau. *(Automatic description of image based on radiologist's report)*

Thank you for the consultation. This MRI report was personally interpreted and finalized by the signing radiologist. To ensure the highest-quality MRI and CT reports with colorized key images and illustrations, please request **Expert Radiology v3™** on future order scripts. This MRI report was personally interpreted and finalized by the signing radiologist. To ensure the highest-quality MRI and CT reports with colorized key images and illustrations, please request Expert Radiology v3™ on future order scripts. This MRI report was personally interpreted and finalized by the signing radiologist. To ensure the highest-quality MRI and CT reports with colorized key images and illustrations, please request Expert Radiology v3™ on future order scripts.

Sincerely,

Jason Kelly, MD
Clinical Musculoskeletal Radiologist, Expert Radiology™
Board Certified, Diagnostic Radiology, American Board of Radiology
Fellowship trained in Musculoskeletal Radiology, Emory University School of Medicine

Electronically Signed by KELLY, JASON MD at 01/28/2026 09:30:10 AM UTC-05:00
Transcribed/ C.Q

V3

Patient Name: Exam Date:

Customized Knee Illustration of patient

Deep View of Right Knee

(Based upon Findings in the Report)

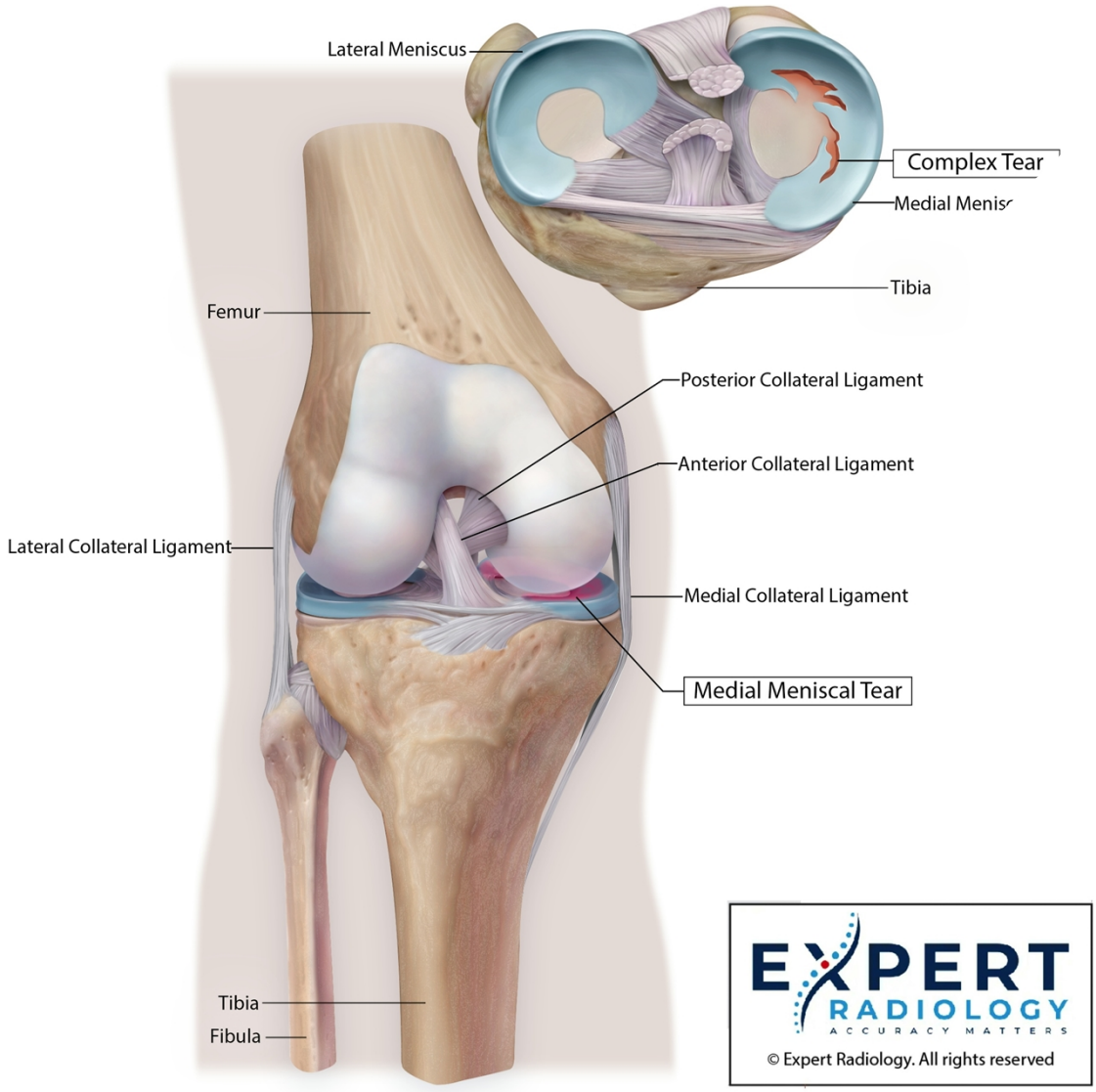

This illustration depicts a Deep view (internal view) of the knee. It attempts to highlight some of the area(s) of interest as described in the radiology report. This illustration does not necessarily show all the pathology present. Please refer to the original radiologists' report. This illustration attempts to correspond to the level(s) of the pathology specified, providing a visual representation to improve the understanding of the reported findings for the patient. The image selection was generated by a computer and has not been reviewed by the radiologist for accuracy, correctness, or completeness. The illustration should NOT be used in medical decision making or diagnostic purposes. The illustration is provided solely as a convenience for the patient and should not be relied upon as a medical diagnosis. If you have questions relating to this illustration please contact your personal physician. The illustration is not intended to be a medical device and is not subject to FDA oversight.

Patient Name: Exam Date:

Customized Knee Illustration of patient
Frontal View of Right Knee
(Based upon Findings in the Report)

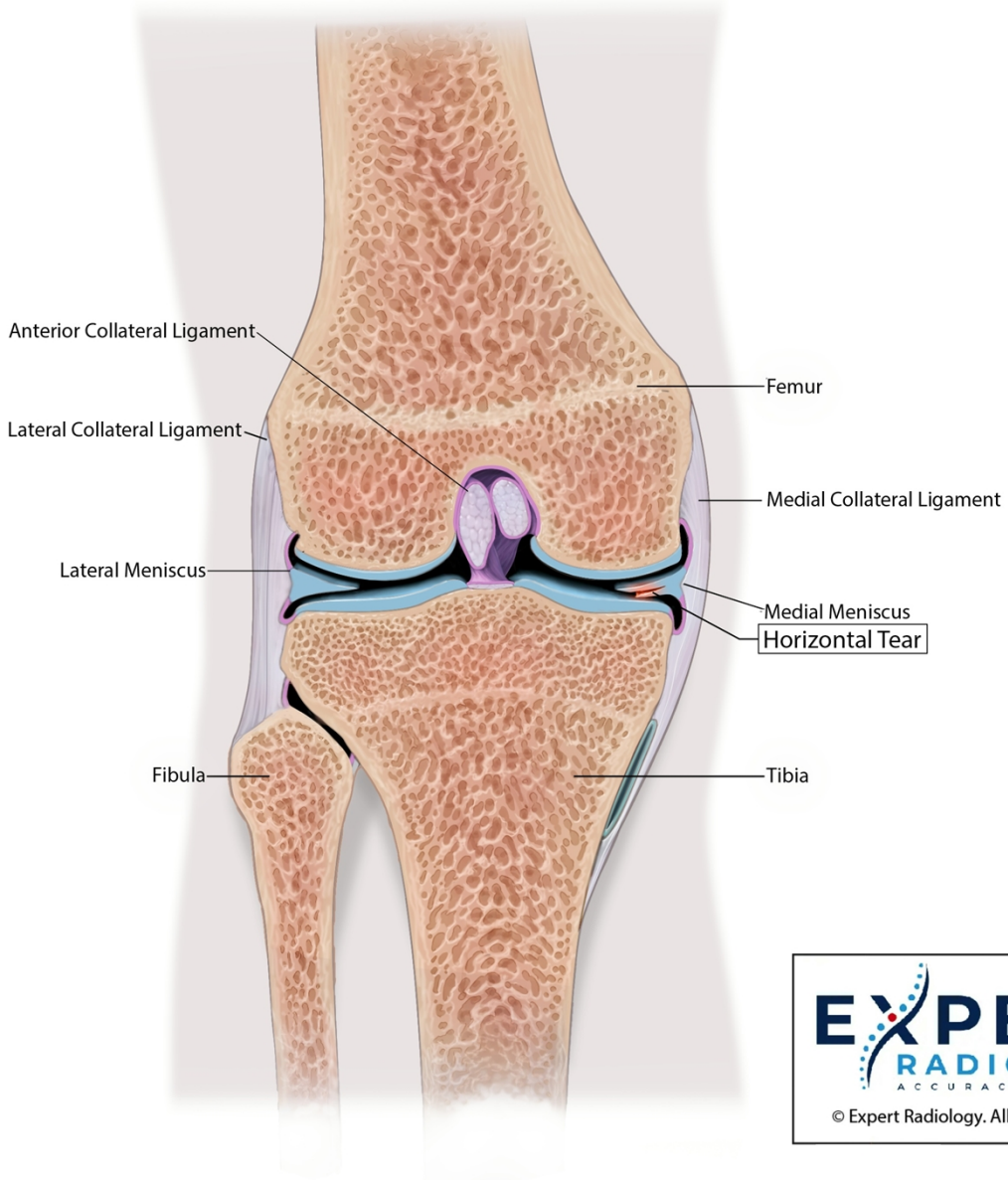

© Expert Radiology. All rights reserved

This illustration depicts a Frontal view (frontwards view) of the knee. It attempts to highlight some of the area(s) of interest as described in the radiology report. This illustration does not necessarily show all the pathology present. Please refer to the original radiologists' report. This illustration attempts to correspond to the level(s) of the pathology specified, providing a visual representation to improve the understanding of the reported findings for the patient. The image selection was generated by a computer and has not been reviewed by the radiologist for accuracy, correctness, or completeness. The illustration should NOT be used in medical decision making or diagnostic purposes. The illustration is provided solely as a convenience for the patient and should not be relied upon as a medical diagnosis. If you have questions relating to this illustration please contact your personal physician. The illustration is not intended to be a medical device and is not subject to FDA oversight.

Patient Name: Exam Date:

Customized Knee Illustration of patient

Lateral View of Right Knee

(Based upon Findings in the Report)

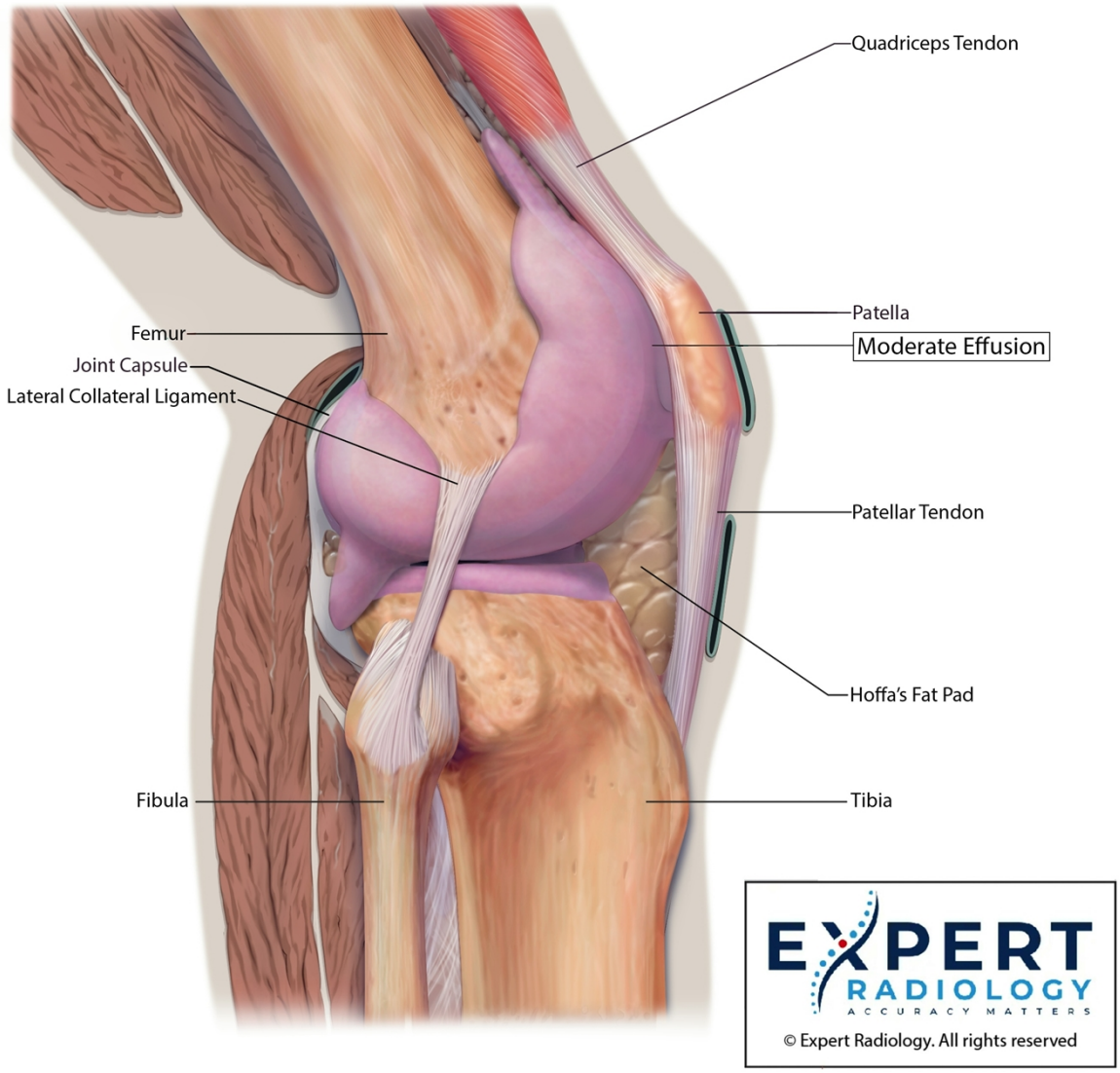

This illustration depicts a Lateral view (side view) of the knee. It attempts to highlight some of the area(s) of interest as described in the radiology report. This illustration does not necessarily show all the pathology present. Please refer to the original radiologists' report. This illustration attempts to correspond to the level(s) of the pathology specified, providing a visual representation to improve the understanding of the reported findings for the patient. The image selection was generated by a computer and has not been reviewed by the radiologist for accuracy, correctness, or completeness. The illustration should NOT be used in medical decision making or diagnostic purposes. The illustration is provided solely as a convenience for the patient and should not be relied upon as a medical diagnosis. If you have questions relating to this illustration please contact your personal physician. The illustration is not intended to be a medical device and is not subject to FDA oversight.