Patient Name:	Exam Date:
Patient ID:	Exam Description:
Date of Birth:	Accession:
Gender:	

EXPERT RADIOLOGY ACCURACY MATTERS PrecisionPlus V3™ Report Patent Pending

MRI OF THE CERVICAL SPINE

CLINICAL INDICATION: Cervical radiculopathy and neck pain after motor vehicle collision on 09/25/2025.

TECHNIQUE: T1 and T2 weighted images were obtained.

COMPARISON: No prior studies are available for comparison.

FINDINGS:

The posterior fossa structures are normal. There is reversal of the normal lordotic curvature of the cervical spine. In the correct clinical setting, this may reflect injury. Clinical correlation is recommended. No prevertebral or paravertebral masses or fluid collections are identified. Segmental analysis of the cervical spine is as follows:

At C2-3, there is no evidence for disc herniation, canal stenosis or neural foraminal stenosis.

At C3-4, there is a 2 mm disc bulge indenting the ventral thecal sac and elevating the posterior longitudinal ligament. There is no spinal stenosis or neural foraminal narrowing.

At C4-5, there is no evidence for disc herniation, canal stenosis or neural foraminal stenosis.

At C5-6, there are bilateral paracentral disc herniations superimposed on a disc bulge, the combination of which measures 3 mm on the left and 3.5 mm on the right. The ventral thecal sac is indented, and the posterior longitudinal ligament is elevated. There are anterior and there are posterior osteophytes, however, the disc material extends posterior to the posterior osteophytes. There is severe bilateral foraminal stenosis. There is no spinal stenosis.

At C6-7, there are bilateral paracentral disc herniations superimposed on a disc bulge, the combination of which measures 2 mm on the right and 2 mm on the left. The ventral thecal sac is indented, and the posterior longitudinal ligament is elevated. There is no spinal stenosis. There is moderate-to-severe left and mild right foraminal stenosis.

At C7-T1, there is no evidence for disc herniation, canal stenosis or neural foraminal stenosis.

There is decreased intervertebral disc signal and height at C5-6. There is decreased intervertebral disc signal at C2-3, C3-4, C4-5, C6-7, and T1-2.

There is an intraosseous hemangioma in the T2 vertebral body.

IMPRESSION:

1. There is reversal of the normal lordotic curvature of the cervical spine. In the correct clinical setting, this may reflect injury. Clinical correlation with the patient's treating physician is recommended.
2. At C3-4, there is a 2 mm disc bulge indenting the ventral thecal sac and elevating the posterior longitudinal ligament.
3. At C5-6, there are bilateral paracentral disc herniations superimposed on a disc bulge, the combination of which measures 3 mm on the left and 3.5 mm on the right. The ventral thecal sac is indented, and the posterior longitudinal ligament is elevated. There are anterior and there are posterior osteophytes, however, the disc material extends posterior to the posterior osteophytes. There is severe bilateral foraminal stenosis. For the right paracentral herniation, see **Figure 1** Sagittal T2 series 301, image #11 and the left, see **Figure 2** Sagittal T2 series 301, image #5.
4. At C6-7, there are bilateral paracentral disc herniations superimposed on a disc bulge, the combination of which measures 2 mm on the right and 2 mm on the left. The ventral thecal sac is indented, and the posterior longitudinal ligament is elevated. There is moderate-to-severe left and mild right foraminal stenosis. *See **Figure 1** Sagittal T2 series 301, image #11 and **Figure 2** Sagittal T2 series 301, image #5.

The definitions in this report, including definitions of disc bulge, disc herniation, protrusion, and extrusion, are from the following peer reviewed journal: Lumbar Disc Nomenclature V2.0, Recommendations of the Combined Task Forces of the North American Spine Society, the American Society of Spine Radiology and the American Society of Neuroradiology, The Spine Journal 14 (2014) 2525 2545. Disc herniations are protrusion type disc herniations unless specifically described as extrusions. A normal MRI should not supersede abnormalities detected with physical exam.

228 Park Ave S #14773, New York, NY 10003
Office: 415-900-2000 - Fax: 815-301-6739

FIGURE 1:

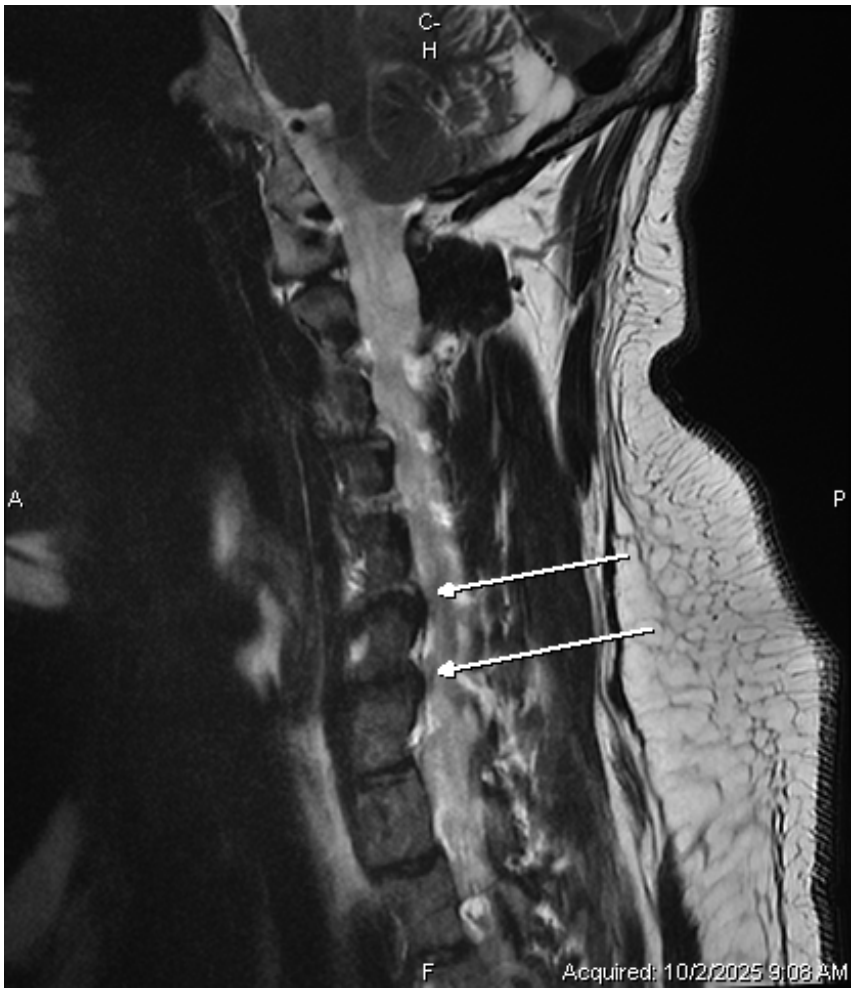

Image shows right paracentral herniation at C5-6 with bilateral paracentral disc herniations superimposed on a disc bulge, measuring 3 mm on the left and 3.5 mm on the right, indenting the ventral thecal sac and elevating the posterior longitudinal ligament. *(Automatic description of image based on radiologist's report)*

228 Park Ave S #14773, New York, NY 10003
Office: 415-900-2000 - Fax: 815-301-6739

FIGURE 2:

Image shows left paracentral herniation at C5-6 with bilateral paracentral disc herniations superimposed on a disc bulge, measuring 3 mm on the left and 3.5 mm on the right, indenting the ventral thecal sac and elevating the posterior longitudinal ligament. *(Automatic description of image based on radiologist's report)*

228 Park Ave S #14773, New York, NY 10003
Office: 415-900-2000 - Fax: 815-301-6739

COLORIZATION OF FIGURE 1:

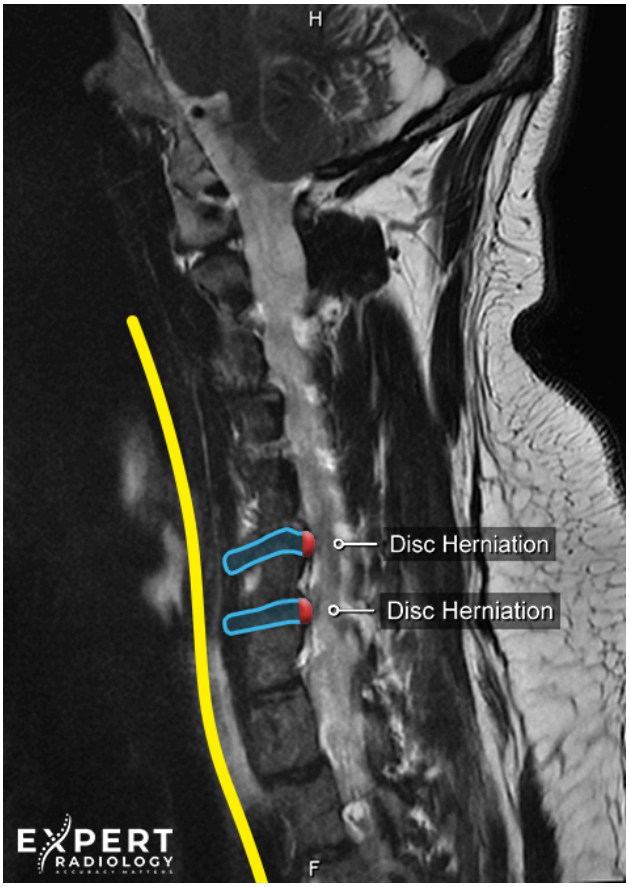

JOHN DOE

NORMAL CERVICAL SPINE:

HEALTHY PATIENT

©2023 Expert Radiology™. All Rights Reserved.
The colorized medical images, annotations, and graphical enhancements are the exclusive intellectual property of Expert Radiology™ and are confidential, proprietary, and protected by applicable intellectual property laws. Any unauthorized use, reproduction, or modification of these works is strictly prohibited without prior written consent.
For licensing inquiries or additional information, please contact info@expertradiology.com.

Note: The image on the LEFT is a colorized image of the patient's abnormality for illustrative purposes only, and this colorized image should not be used for medical decision-making

228 Park Ave S #14773, New York, NY 10003
Office: 415-900-2000 - Fax: 815-301-6739

Thank you for the consultation. Please request PrecisionPlus v3™ MRI reports on your order script to ensure the highest quality reports.

Sincerely,

Roger Jordan, MD
Clinical Neuroradiologist, Expert Radiology™
Board Certified, Diagnostic Radiology, American Board of Radiology
Subspecialty Certification in Neuroradiology
Fellowship Trained, Neuroradiology, Mayo Clinic in Rochester, MN

Electronically Signed by JORDAN, ROGER MD at 10/02/2025 02:42:14 PM UTC-05:00
Transcribed/ M.W

V3

228 Park Ave S #14773, New York, NY 10003
Office: 415-900-2000 - Fax: 815-301-6739

Customized Spine Illustration of patient John Doe:
Sagittal View of Cervical Spine
(Based upon Findings in the Report)

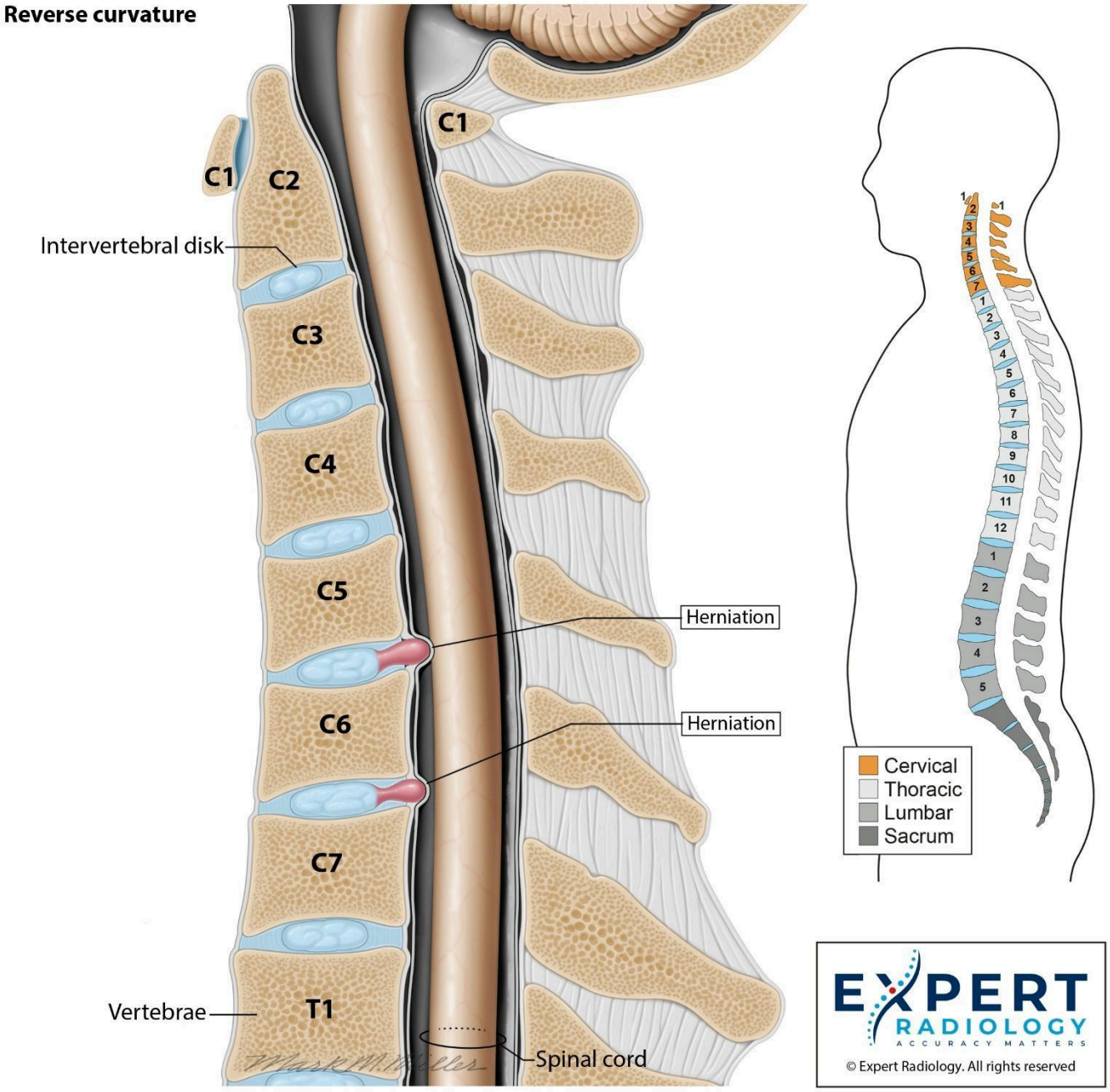

This illustration depicts a Sagittal view (side view) of the spine. It attempts to highlight some of the area(s) of interest as described in the radiology report. This illustration attempts to correspond to the level(s) of the pathology specified, providing a visual representation to improve the understanding of the reported findings for the patient. Protrusions and Extrusions are both subtypes of Herniation. The image selection was generated by a computer and has not been reviewed by the radiologist for accuracy, correctness, or completeness. The illustration should NOT be used in medical decision making or diagnostic purposes. The illustration is provided solely as a convenience for the patient and should not be relied upon as a medical diagnosis. If you have questions relating to this illustration please contact your personal physician. The illustration is not intended to be a medical device and is not subject to FDA oversight.

228 Park Ave S #14773, New York, NY 10003
Office: 415-900-2000 - Fax: 815-301-6739

Customized Spine Illustration of patient John Doe:
Axial View of Cervical Spine Level C5-6
(Based upon Findings in the Report)

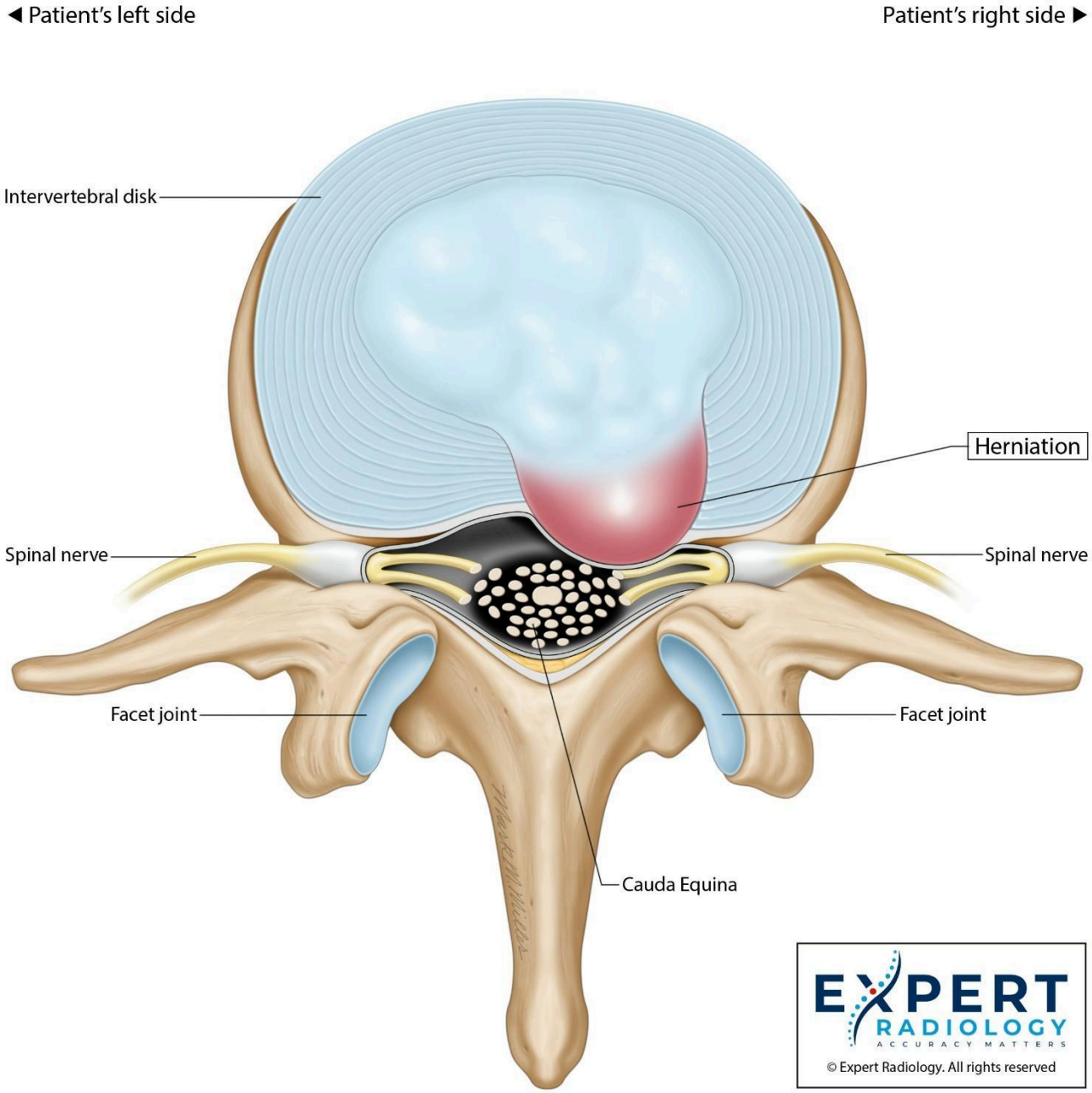

This illustration depicts an Axial view (top down view) of the spine. It attempts to highlight some of the area(s) of interest as described in the radiology report. This illustration attempts to correspond to at least one of the position(s) of the pathology specified, providing a visual representation to improve the understanding of the reported findings for the patient. Protrusions and Extrusions are both subtypes of Herniation. The image selection was generated by a computer and has not been reviewed by the radiologist for accuracy, correctness, or completeness. The illustration should NOT be used in medical decision making or diagnostic purposes. The illustration is provided solely as a convenience for the patient and should not be relied upon as a medical diagnosis. If you have questions relating to this illustration please contact your personal physician. The illustration is not intended to be a medical device and is not subject to FDA oversight.

228 Park Ave S #14773, New York, NY 10003
Office: 415-900-2000 - Fax: 815-301-6739

228 Park Ave S #14773, New York, NY 10003
Office: 415-900-2000 - Fax: 815-301-6739

Simplified Patient Explanation of Radiologist's Report*

Not a substitute for the Expert Radiology radiologist's report

Simplified Patient Explanation

MRI of the Cervical Spine

Clinical Indication: Neck pain and nerve issues after a car accident on 09/25/2025.

Technique: T1 and T2 weighted images were taken.

Comparison: No previous studies to compare with.

Findings:

The back part of the brain looks normal. The normal curve of the neck spine is reversed, which might mean an injury. No abnormal masses or fluid collections are found around the spine.

Segmental Analysis:

1. **C2-3:** No disc herniation, no narrowing of the spinal canal or nerve openings.
2. **C3-4:** A 2 mm disc bulge is pressing on the protective covering of the spinal cord and lifting a ligament. No narrowing of the spinal canal or nerve openings.
3. **C4-5:** No disc herniation, no narrowing of the spinal canal or nerve openings.
4. **C5-6:** Disc herniations on both sides, combined with a disc bulge, measuring 3 mm on the left and 3.5 mm on the right. This is pressing on the protective covering of the spinal cord and lifting a ligament. There are bone spurs in front and back, but the disc material goes behind the back bone spurs. Severe narrowing of the nerve openings on both sides. No narrowing of the spinal canal.
5. **C6-7:** Disc herniations on both sides, combined with a disc bulge, measuring 2 mm on both sides. This is pressing on the protective covering of the spinal cord and lifting a ligament. No narrowing of the spinal canal. Moderate-to-severe narrowing of the left nerve opening and mild narrowing of the right nerve opening.
6. **C7-T1:** No disc herniation, no narrowing of the spinal canal or nerve openings.

There is a decrease in disc signal and height at C5-6. There is also a decrease in disc signal at C2-3, C3-4, C4-5, C6-7, and T1-2. An intraosseous hemangioma is found in the T2 vertebral body.

Impression:

The normal curve of the neck spine is reversed, which might mean an injury. It is recommended to discuss this with the patient's doctor.

At C3-4, there is a 2 mm disc bulge pressing on the protective covering of the spinal cord and lifting a ligament.

At C5-6, there are disc herniations on both sides, combined with a disc bulge, measuring 3 mm on the left and 3.5 mm on the right. This is pressing on the

228 Park Ave S #14773, New York, NY 10003
Office: 415-900-2000 - Fax: 815-301-6739

protective covering of the spinal cord and lifting a ligament. There are bone spurs in front and back, but the disc material goes behind the back bone spurs. Severe narrowing of the nerve openings on both sides.

At C6-7, there are disc herniations on both sides, combined with a disc bulge, measuring 2 mm on both sides. This is pressing on the protective covering of the spinal cord and lifting a ligament. Moderate-to-severe narrowing of the left nerve opening and mild narrowing of the right nerve opening.

END OF SIMPLIFIED PATIENT EXPLANATION

**The above is a Simplified Patient Explanation / Artificial Intelligence ("AI") summary generated for the patient (a layperson) of the Radiology Report provided above ("Simplified Patient Explanation"). This Simplified Patient Explanation was generated by a computer and has not been reviewed by the radiologist for accuracy, correctness, or completeness. The Simplified Patient Explanation is not intended for decision making or diagnostic purposes. The Simplified Patient Explanation is provided solely as a convenience for the patient and should not be relied upon as a medical diagnosis. If you have questions relating to this AI Summary please contact your personal physician. The Simplified Patient Explanation by Expert Radiology™ is not intended to be a medical device and is not subject to FDA oversight.*

---

i. Quantitative Evaluation of Large Language Models to Streamline Radiology Report Impressions: A Multimodal Retrospective Analysis. Radiology. https://doi.org/10.1148/radiol.231593

ii. Rahsepar, A. A. (2024). Large Language Models for Enhancing Radiology Report Impressions: Improve Readability While Decreasing Burnout. Radiology. https://doi.org/10.1148/radiol.240498

iii. Park, J., Oh, K., Han, K. et al. (2024). Patient-centered radiology reports with generative artificial intelligence: adding value to radiology reporting. https://doi.org/10.1038/s41598-024-63824-z

Physicians and healthcare providers only: For direct consultation with a radiologist at Expert Radiology™, please call our dedicated hotline at 415-900-2000

Simplified Patient Explanation

228 Park Ave S #14773, New York, NY 10003
Office: 415-900-2000 - Fax: 815-301-6739