Patient Name:	Exam Date:
Patient ID:	Exam Description:
Date of Birth:	Accession:
Gender:	Referring Physician

EXPERT RADIOLOGY ACCURACY MATTERS — PrecisionPlus V3™ Report — Patent Pending

MRI OF THE LUMBAR SPINE WITHOUT CONTRAST

CLINICAL INDICATION: Lumbar pain after motor vehicle collision 09/19/2025.

TECHNIQUE: T1 and T2 weighted images were obtained without contrast.

COMPARISON: No prior studies are available for comparison.

FINDINGS:

Unless otherwise specified in this report, the lumbar level numbering is based upon the most 5 caudad well-formed vertebral bodies, being numbered L5 through S1. Prior to any possible surgical planning or any possible instrumentation, exact confirmation is required to determine the appropriate level.

The conus medullaris appears normal. The lordotic curvature of the lumbar spine is preserved. No evidence for abnormal solid or cystic lesions is identified. No prevertebral or paravertebral masses or fluid collections are seen and there is no evidence for abnormal marrow replacing lesion. Segmental analysis of the lumbar spine is as follows:

At T10-11, there is a central disc herniation superimposed on a disc bulge, the combination of which measures 3 mm. The ventral thecal sac is indented, and the posterior longitudinal ligament is elevated. There is moderate spinal canal stenosis to 0.8 cm.

At T11-12, there is a left paracentral disc herniation superimposed on a disc bulge, the combination of which measures 3 mm. The ventral thecal sac is indented, and the posterior longitudinal ligament is elevated. There is no spinal stenosis or neural foraminal narrowing. There are anterior osteophytes and no posterior osteophytes are seen.

At T12-L1, there is no evidence for disc herniation, canal stenosis or neural foraminal stenosis. There are anterior osteophytes and no posterior osteophytes are seen.

At L1-2, there is a 2.5 mm bulging disc indenting the ventral thecal sac and elevating the posterior longitudinal ligament. There is no spinal stenosis or neural foraminal narrowing. There are anterior osteophytes and no posterior osteophytes are seen.

At L2-3, there is a left foraminal extrusion type herniation superimposed on a disc bulge, the combination of which measures 6 mm in the anteroposterior dimension x 1.2 cm in the craniocaudal

dimension. The ventral thecal sac is indented, and the posterior longitudinal ligament is elevated. There is an area of hyperintense signal on T2 weighted images suggestive of a more acute herniation of the disc. There is posterior displacement of the exiting left L2 nerve. There is moderate left foraminal stenosis. There is no spinal stenosis or right neural foraminal narrowing.

At L3-4, there is a left paracentral disc herniation superimposed on a disc bulge, the combination of which measures 4 mm. The ventral thecal sac is indented, and the posterior longitudinal ligament is elevated. There is mild bilateral foraminal stenosis. There is mild spinal canal stenosis to 0.9 cm.

At L4-5, there is a left paracentral/foraminal disc herniation superimposed on a disc bulge, the combination of which measures 4 mm. The ventral thecal sac is indented, and the posterior longitudinal ligament is elevated. There is a zone of hyperintensity within the disc consistent with an annular fissure. There is moderate bilateral foraminal stenosis. There is moderate spinal canal stenosis to 0.7 cm. There is facet arthropathy.

At L5-S1, there is a central disc herniation superimposed on a disc bulge, the combination of which measures 3 mm. The ventral thecal sac is indented, and the posterior longitudinal ligament is elevated. There is mild-to-moderate right and mild left foraminal stenosis. There is facet arthropathy.

There is decreased intervertebral disc signal at T12-L1, L1-2, L2-3, L3-4, L4-5 and L5-S1. There is decreased intervertebral disc signal and height at T10-11 and T11-12.

Modic type 1, acute-type, endplate signal changes are seen at T10-11.

There are acute appearing intravertebral disc herniations/Schmorl's nodes at the inferior endplate of L3 and superior endplate of L2 with adjacent bone marrow edema.

IMPRESSION:

1. At T10-11, there is a central disc herniation superimposed on a disc bulge, the combination of which measures 3 mm. The ventral thecal sac is indented, and the posterior longitudinal ligament is elevated. There is moderate spinal canal stenosis to 0.8 cm. *See **Figure 2** Sagittal T2 series 301, image #8.
2. At T11-12, there is a left paracentral disc herniation superimposed on a disc bulge, the combination of which measures 3 mm. The ventral thecal sac is indented, and the posterior longitudinal ligament is elevated. *See **Figure 2** Sagittal T2 series 301, image #7.
3. At L1-2, there is a 2.5 mm bulging disc indenting the ventral thecal sac and elevating the posterior longitudinal ligament.
4. At L2-3, there is a left foraminal extrusion type herniation superimposed on a disc bulge, the combination of which measures 6 mm in the anteroposterior dimension x 1.2 cm in the craniocaudal dimension. The ventral thecal sac is indented, and the posterior longitudinal ligament is elevated. There is an area of hyperintense signal on T2 weighted images suggestive of a more acute herniation of the disc. There is posterior displacement of the exiting left L2 nerve. There is moderate left foraminal stenosis. *See **Figure 3** Sagittal T2 series 301, image #4 and **Figure 4** Axial T2 series 601, image #8.
5. At L3-4, there is a left paracentral disc herniation superimposed on a disc bulge, the combination of which measures 4 mm. The ventral thecal sac is indented, and the posterior longitudinal ligament is elevated. There is mild bilateral foraminal stenosis. There is mild spinal canal stenosis to 0.9 cm. *See **Figure 1** Sagittal T2 series 301, image #7.
6. At L4-5, there is a left paracentral/foraminal disc herniation superimposed on a disc bulge, the combination of which measures 4 mm. The ventral thecal sac is indented, and the posterior longitudinal ligament is elevated. There is a zone of hyperintensity within the disc consistent with

an annular fissure. There is moderate bilateral foraminal stenosis. There is moderate spinal canal stenosis to 0.7 cm. *See **Figure 1** Sagittal T2 series 301, image #7.

7. At L5-S1, there is a central disc herniation superimposed on a disc bulge, the combination of which measures 3 mm. The ventral thecal sac is indented, and the posterior longitudinal ligament is elevated. There is mild-to-moderate right and mild left foraminal stenosis. *See **Figure 2** Sagittal T2 series 301, image #8.
8. There are acute appearing intravertebral disc herniations/Schmorl's nodes at the inferior endplate of L3 and superior endplate of L2 with adjacent bone marrow edema.

The definitions in this report, including definitions of disc bulge, disc herniation, protrusion, and extrusion, are from the following peer reviewed journal: Lumbar Disc Nomenclature V2.0, Recommendations of the Combined Task Forces of the North American Spine Society, the American Society of Spine Radiology and the American Society of Neuroradiology, The Spine Journal 14 (2014) 2525 2545. Disc herniations are protrusion type disc herniations unless specifically described as extrusions. A normal MRI should not supersede abnormalities detected with physical exam.

FIGURE 1:

Image also shows a left paracentral/foraminal disc herniation superimposed on a disc bulge at L4-5, measuring 4 mm, with a zone of hyperintensity within the disc consistent with an annular fissure, moderate bilateral foraminal stenosis, and moderate spinal canal stenosis to 0.7 cm. (Automatic description of image based on radiologist's report)

FIGURE 2:

Image also shows a central disc herniation superimposed on a disc bulge at L5-S1, measuring 3 mm, with mild-to-moderate right and mild left foraminal stenosis. (Automatic description of image based on radiologist's report)

FIGURE 3:

Image shows a left foraminal extrusion type herniation superimposed on a disc bulge at L2-3, measuring 6 mm in the anteroposterior dimension x 1.2 cm in the craniocaudal dimension, with posterior displacement of the exiting left L2 nerve and moderate left foraminal stenosis. (Automatic description of image based on radiologist's report)

FIGURE 4:

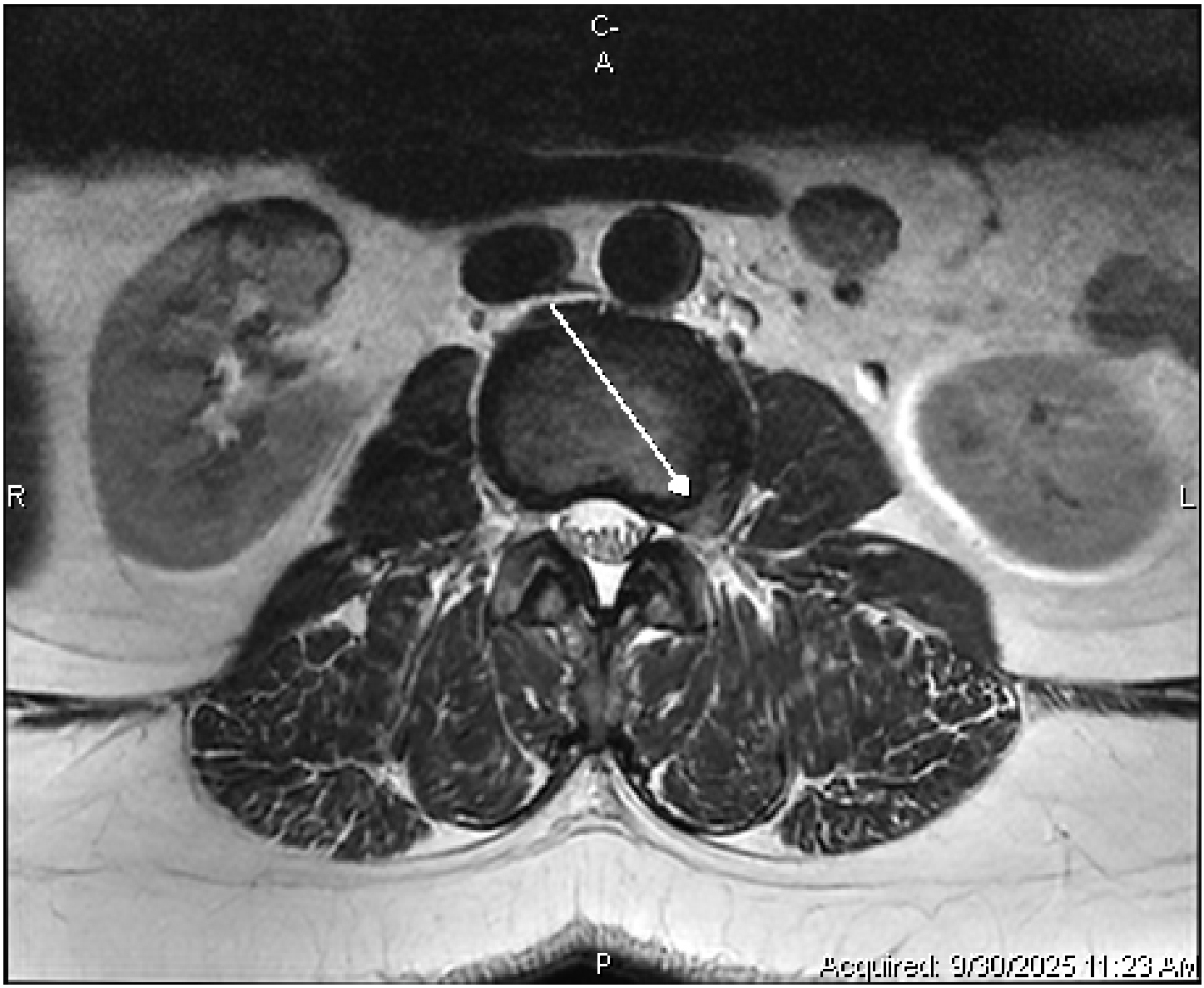

Image shows a left foraminal extrusion type herniation superimposed on a disc bulge at L2-3, measuring 6 mm in the anteroposterior dimension x 1.2 cm in the craniocaudal dimension, with posterior displacement of the exiting left L2 nerve and moderate left foraminal stenosis. (Automatic description of image based on radiologist's report)

COLORIZATION OF FIGURE 1:

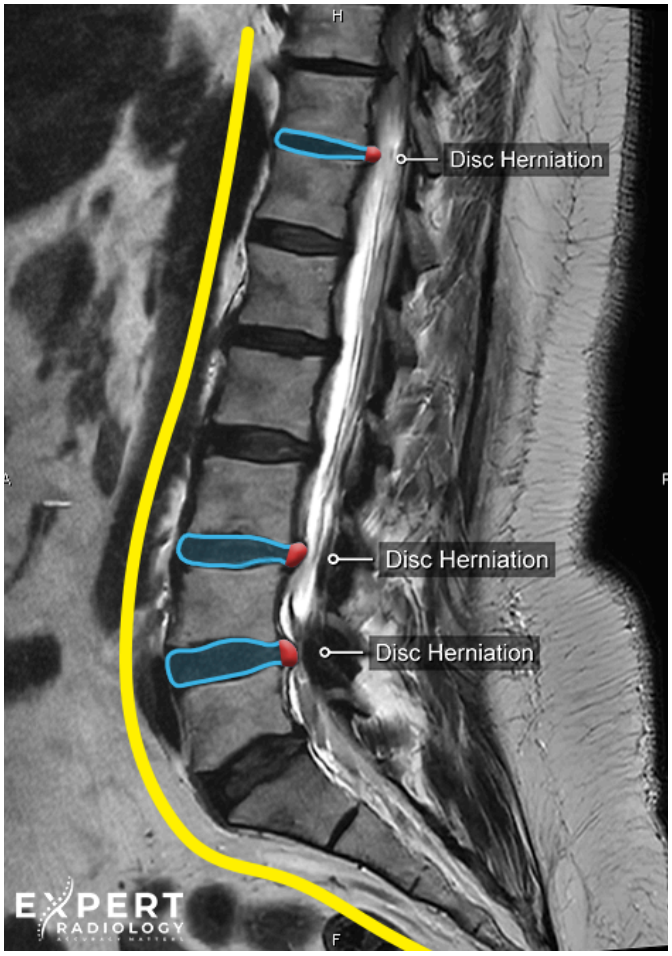

DOE, JOHN

NORMAL LUMBAR SPINE:

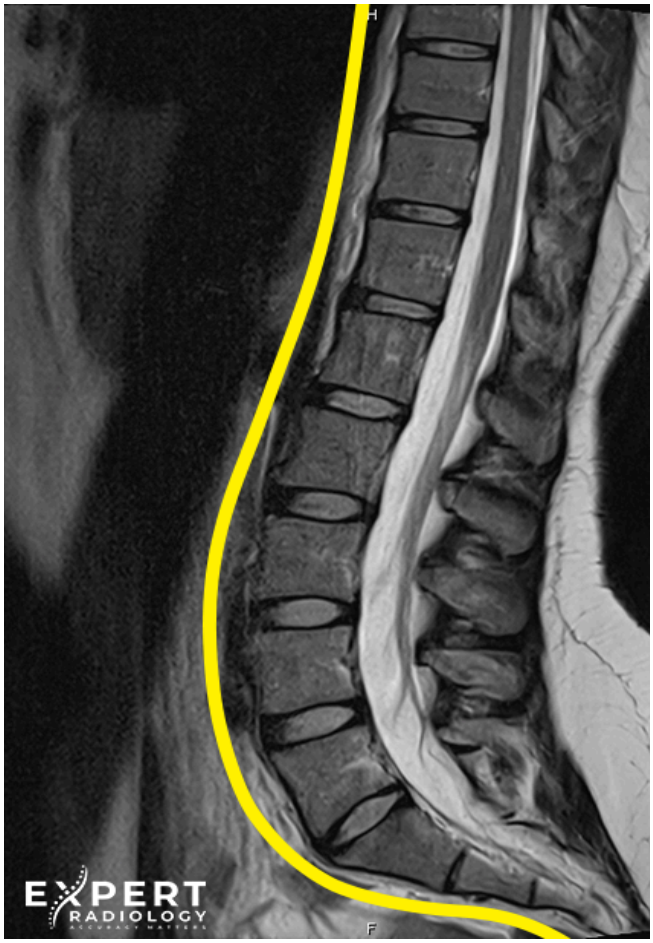

HEALTHY PATIENT

©2023 Expert Radiology™. All Rights Reserved.
The colorized medical images, annotations, and graphical enhancements are the exclusive intellectual property of Expert Radiology™ and are confidential, proprietary, and protected by applicable intellectual property laws. Any unauthorized use, reproduction, or modification of these works is strictly prohibited without prior written consent.
For licensing inquiries or additional information, please contact info@expertradiology.com.

Note: The image on the LEFT is a colorized image of the patient's abnormality for illustrative purposes only, and this colorized image should not be used for medical decision-making

Thank you for the consultation. Please request PrecisionPlus v3™ MRI reports on your order script to ensure the highest quality reports.

Sincerely,

Roger Jordan, MD
Clinical Neuroradiologist, Expert Radiology™
Board Certified, Diagnostic Radiology, American Board of Radiology
Subspecialty Certification in Neuroradiology
Fellowship Trained, Neuroradiology, Mayo Clinic in Rochester, MN

EXPERT RADIOLOGY
ACCURACY MATTERS

Electronically Signed by JORDAN, ROGER MD at 09/30/2025 04:38:16 PM UTC-05:00
Transcribed/ D.J

V3

Customized Spine Illustration of patient John Doe:
Sagittal View of Lumbar Spine
(Based upon Findings in the Report)

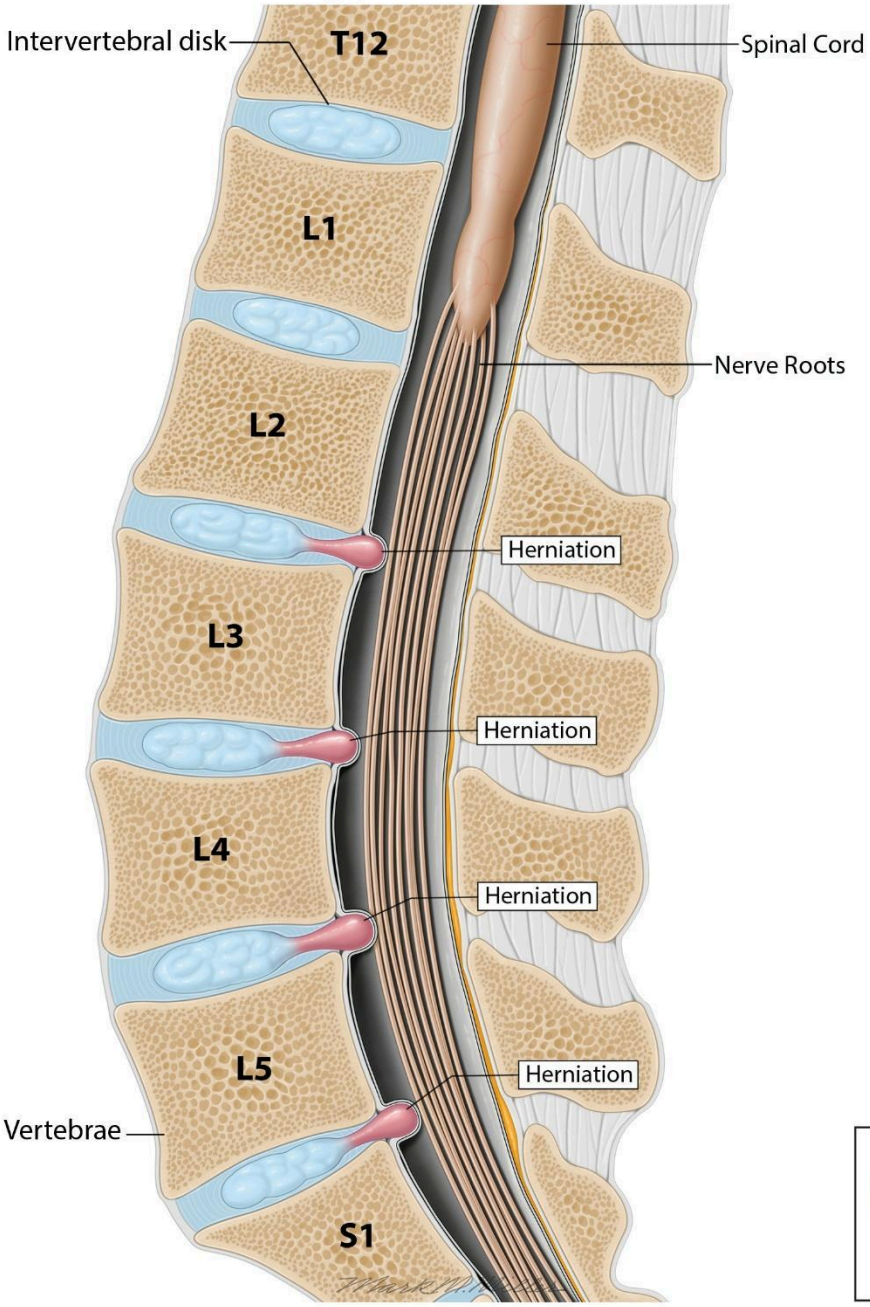

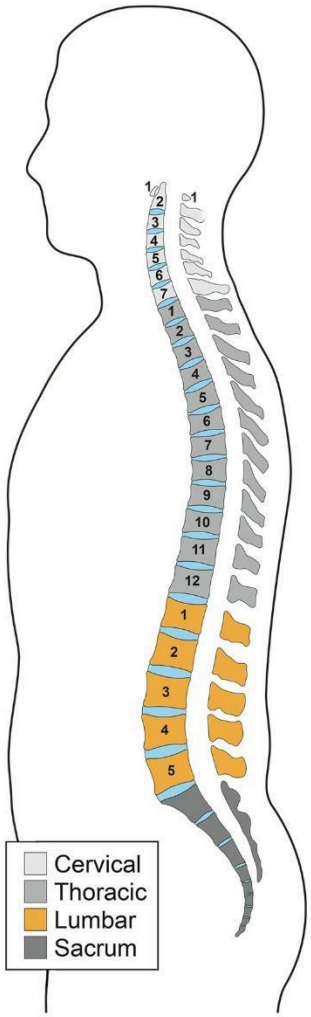

EXPERT RADIOLOGY
ACCURACY MATTERS
© Expert Radiology. All rights reserved

This illustration depicts a Sagittal view (side view) of the spine. It attempts to highlight some of the area(s) of interest as described in the radiology report. This illustration attempts to correspond to the level(s) of the pathology specified, providing a visual representation to improve the understanding of the reported findings for the patient. Protrusions and Extrusions are both subtypes of Herniation. The image selection was generated by a computer and has not been reviewed by the radiologist for accuracy, correctness, or completeness. The illustration should NOT be used in medical decision making or diagnostic purposes. The illustration is provided solely as a convenience for the patient and should not be relied upon as a medical diagnosis. If you have questions relating to this illustration please contact your personal physician. The illustration is not intended to be a medical device and is not subject to FDA oversight.

Customized Spine Illustration of patient John Doe:
Axial View of Lumbar Spine Level L2-3
(Based upon Findings in the Report)

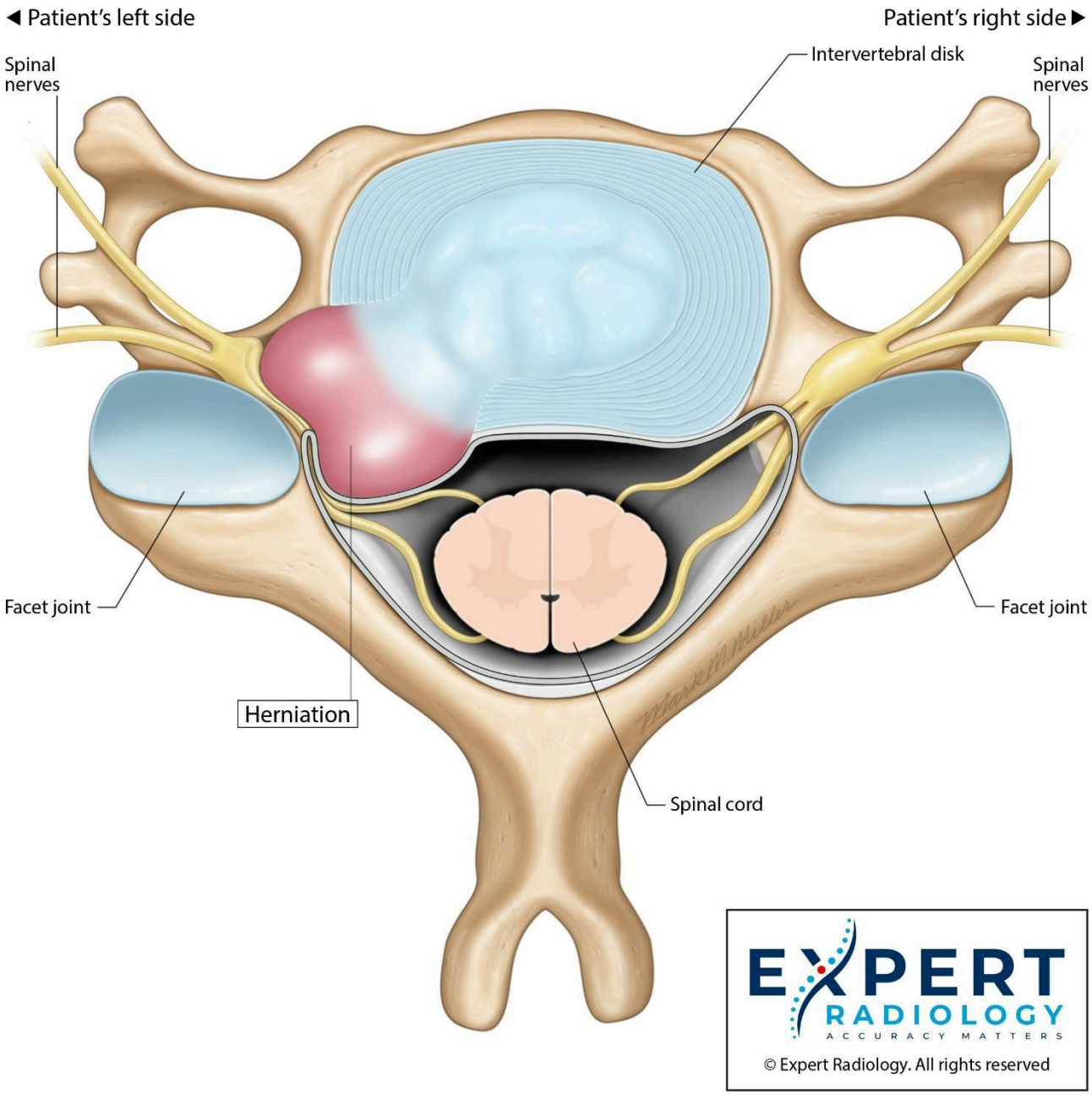

This illustration depicts an Axial view (top down view) of the spine. It attempts to highlight some of the area(s) of interest as described in the radiology report. This illustration attempts to correspond to at least one of the position(s) of the pathology specified, providing a visual representation to improve the understanding of the reported findings for the patient. Protrusions and Extrusions are both subtypes of Herniation. The image selection was generated by a computer and has not been reviewed by the radiologist for accuracy, correctness, or completeness. The illustration should NOT be used in medical decision making or diagnostic purposes. The illustration is provided solely as a convenience for the patient and should not be relied upon as a medical diagnosis. If you have questions relating to this illustration please contact your personal physician. The illustration is not intended to be a medical device and is not subject to FDA oversight.

Simplified Patient Explanation of Radiologist's Report*

Not a substitute for the Expert Radiology radiologist's report

Simplified Patient Explanation

MRI of the Lumbar Spine

Reason for MRI: Lower back pain after a car accident on 09/19/2025.

Technique: MRI images were taken without using contrast dye.

Comparison: No previous MRI scans are available for comparison.

Findings:

The lower back spine looks normal in shape and alignment. No unusual growths or fluid collections were found. The spinal cord ends normally.

Detailed Segment Analysis:

1. **T10-11:** There is a 3 mm disc herniation and bulge pressing on the spinal sac, causing moderate narrowing of the spinal canal to 0.8 cm.
2. **T11-12:** There is a 3 mm disc herniation and bulge pressing on the spinal sac, but no significant narrowing of the spinal canal.
3. **T12-L1:** No disc herniation or narrowing of the spinal canal.
4. **L1-2:** There is a 2.5 mm bulging disc pressing on the spinal sac, but no significant narrowing of the spinal canal.
5. **L2-3:** There is a 6 mm herniation and bulge pressing on the spinal sac, causing moderate narrowing of the left side of the spinal canal. The left L2 nerve is pushed back.
6. **L3-4:** There is a 4 mm herniation and bulge pressing on the spinal sac, causing mild narrowing of the spinal canal on both sides.
7. **L4-5:** There is a 4 mm herniation and bulge pressing on the spinal sac, causing moderate narrowing of the spinal canal on both sides. There is also a small tear in the disc.
8. **L5-S1:** There is a 3 mm herniation and bulge pressing on the spinal sac, causing mild to moderate narrowing of the spinal canal on the right side and mild narrowing on the left side.

There are also some changes in the discs and bones at various levels, indicating some recent damage and inflammation.

Impression:

1. **T10-11:** 3 mm disc herniation and bulge causing moderate narrowing of the spinal canal to 0.8 cm.
2. **T11-12:** 3 mm disc herniation and bulge pressing on the spinal sac.
3. **L1-2:** 2.5 mm bulging disc pressing on the spinal sac.
4. **L2-3:** 6 mm herniation and bulge causing moderate narrowing of the left side of the spinal canal. The left L2 nerve is pushed back.
5. **L3-4:** 4 mm herniation and bulge causing mild narrowing of the spinal canal on both sides.
6. **L4-5:** 4 mm herniation and bulge causing moderate narrowing of the spinal canal

on both sides. Small tear in the disc.

7. **L5-S1:** 3 mm herniation and bulge causing mild to moderate narrowing of the spinal canal on the right side and mild narrowing on the left side.

There are also some recent changes in the discs and bones at various levels, indicating some recent damage and inflammation.

It is recommended to discuss these findings with your doctor to decide the best course of treatment.

END OF SIMPLIFIED PATIENT EXPLANATION

The above is a Simplified Patient Explanation / Artificial Intelligence ("AI") summary generated for the patient (a layperson) of the Radiology Report provided above ("Simplified Patient Explanation"). This Simplified Patient Explanation was generated by a computer and has not been reviewed by the radiologist for accuracy, correctness, or completeness. The Simplified Patient Explanation is not intended for decision making or diagnostic purposes. The Simplified Patient Explanation is provided solely as a convenience for the patient and should not be relied upon as a medical diagnosis. If you have questions relating to this AI Summary please contact your personal physician. The Simplified Patient Explanation by Expert Radiology™ is not intended to be a medical device and is not subject to FDA oversight.

---

i. Quantitative Evaluation of Large Language Models to Streamline Radiology Report Impressions: A Multimodal Retrospective Analysis. Radiology. https://doi.org/10.1148/radiol.231593

ii. Rahsepar, A. A. (2024). Large Language Models for Enhancing Radiology Report Impressions: Improve Readability While Decreasing Burnout. Radiology. https://doi.org/10.1148/radiol.240498

iii. Park, J., Oh, K., Han, K. et al. (2024). Patient-centered radiology reports with generative artificial intelligence: adding value to radiology reporting. https://doi.org/10.1038/s41598-024-63824-z

Physicians and healthcare providers only: For direct consultation with a radiologist at Expert Radiology™, please call our dedicated hotline at 415-900-2000

Simplified Patient Explanation